

# An unusual case of labial cysticercosis with a natural history

Department of ENT, Seth GS Medical College and KEM Hospital, Mumbai, India

Nilam U. Sathe, Rumita G. Acharya, Manoj Patil, Abhijeet Bhatia, Dhanashree Chiplunkar

## ABSTRACT

Cysticercosis is a common disease in developing countries. Labial lesions produced by this parasitic infestation are rare. The most frequently involved oral locations are the tongue, labial or buccal mucosa, and mouth floor. We present here a case report of a 33-year-old-female patient from Maharashtra, who reported to our department with a swelling in the left lower lip, which was diagnosed as cysticercosis on histopathological examination.

### Address for correspondence:

Dr. Nilam U. Sathe,  
Yash. Co-op. Society, 66/1748,  
Kannamwar Nagar, Vikhroli  
(East), Mumbai – 400 083, India.  
E-mail: drneelam\_s@yahoo.co.in

**Key words:** Labial cysticercosis, natural history, unusual case

## INTRODUCTION

The life cycle of *T. solium* involves humans as a definite host and pigs as an intermediate host. Human cestode infection may involve adult mature worms, larval forms or both the parasites can be ingested in the form of larvae from raw or inadequately cooked pork or in the form of eggs through fecally contaminated vegetables, food, or water as well as by lf-contamination or direct contact with another human carrier.<sup>[1,2]</sup> Upon reaching the small intestine, the scolex attaches to the intestinal wall and a proglottid chain grows. *T. solium* releases three to six proglottids per day, bearing 30,000–70,000 eggs (ova) per proglottid, into the intestine. Nearly 250,000 ova are passed daily into the human feces and to the environment, and the cycle continues.<sup>[3,4]</sup> Infections with cysticercus occur after humans consume the ova from exogenous sources or through self-infection via the fecal–oral route. Ova are digested in the stomach and release oncospheres which penetrate the intestinal wall and reach the bloodstream.<sup>[3,4]</sup> These oncospheres

develop into cysticerci in any organ but are common in brain, subcutaneous tissue, or eyes.

Pigs ingest contaminated food or water that contains eggs or proglottids from human’s feces. The ova develop into cysticercus in pig muscles. Humans become infected when they ingest raw or undercooked “measly pork” that contains viable cysticercus. Human cestode infection may involve adult mature worms, larval forms or both. Adult cestodes inhabit the intestines of vertebrates, whereas the larval forms occur in a variety of vertebrate and invertebrate hosts. The larval form is a post-embryonic stage in which internal organs are either developing or are developed. The larvae are only partially functional.<sup>[5]</sup> The parasite can be ingested in the form of larvae from raw or inadequately cooked pork or in the form of eggs through fecally contaminated vegetables, food, or water as well as by self-contamination or direct contact with another human carrier. The larva may develop into an adult tapeworm and colonize the human intestine. The ingested eggs develop into embryos (oncospheres) that can penetrate the intestinal wall and disseminate through vascular or lymphatic circulation to develop into cystic larvae (*Cysticercus cellulosae*). Although any body site can have cysticercosis, the subcutaneous tissues, brain, and skeletal muscles are the most commonly affected.<sup>[6]</sup>

Access this article online	
<b>Quick Response Code:</b> 	<b>Website:</b> www.njms.in
	<b>DOI:</b> 10.4103/0975-5950.85866

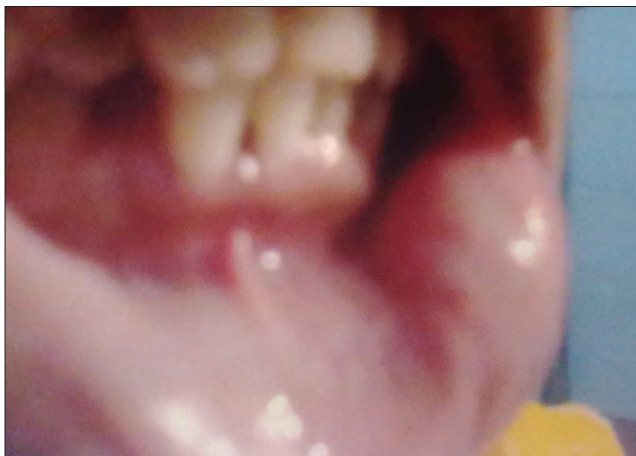
## CASE REPORT

A healthy, 33-year-old female presented with a complaint of swelling over left lower lip since 8–10 years and the swelling gradually increased to the present size of 1.5 × 1 cm in the last 3 months. The patient was a non-vegetarian. The lesions were firm, painless, and not related to any traumatic episode. The patient had no headaches, seizures or any neurological deficits.

On examination, the swelling was smooth and well defined with intact overlying mucosa. A 1.5 × 1 cm cystic swelling was seen over the left lower labial mucosa [Figure 1]. Clinically, the swelling resembled mucocoeles. Fine needle aspiration cytology (FNAC) report showed cystic lesion. An excisional biopsy was performed. Histopathological examination revealed a fibrocartilagenous fibrocartilagenous cyst wall. No epithelial lining was seen. The wall showed lymphocystic inflammatory infiltrate and focal calcification. The lumen showed larval form of cysticercus lined by three layers: inner cuticular, middle granular, and outer loose parenchymatous lining [Figure 2]. The diagnosis of labial cysticercosis was made. Magnetic resonance imaging (MRI) showed no evidence of cysticerci in the brain or eye. Examination of stool showed no ova, cysts, or parasites. An excisional biopsy was performed and histopathological examination revealed a cystic cavity containing the tapeworm.

## DISCUSSION

Cysticercosis is common in endemic areas like India, Southeast Asia, Latin America, China, and sub-Saharan Africa. The incidence in developed countries is also on a rise as a result of migration.<sup>[7]</sup> Wilson *et al.*,<sup>[8]</sup> observed that an individual with cysticercosis need



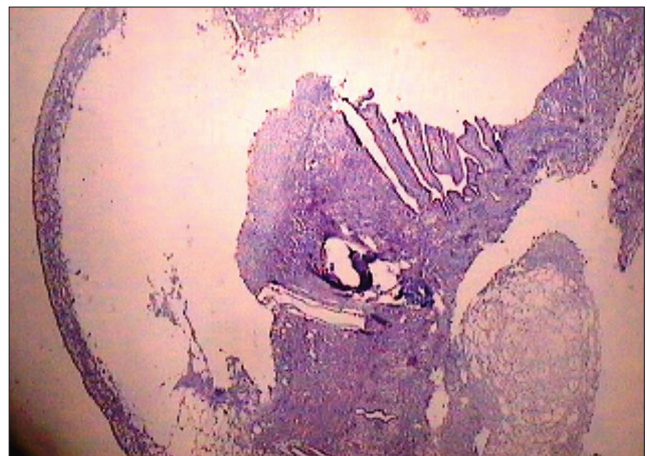
**Figure 1:** Cystic swelling over lower lip

not be a resident of endemic areas or have a history of consumption of beef or pork. Cysticercosis is a parasitic infestation by the larva of pork tapeworm, *T. solium*.<sup>[4,9-11]</sup> Infections with cysticercosis may involve many parts of the body including the subcutaneous tissues, eye, liver, peritoneum, heart, and lungs. However, the skeletal muscle is most commonly affected; the most common site of severe symptomatic infection is the CNS.<sup>[4,9-11]</sup> The most frequently involved oral locations are the tongue, labial or buccal mucosa, and mouth floor 1, 2, 3. The most common complaint of the patients is swelling. Pain is not a frequent feature unless secondarily infected. Most oral presentations are in the form of painless, well-circumscribed, soft swellings that may mimic fluctuant lesions like mucocoeles.<sup>[4,9,10]</sup> Clinical differential diagnoses depend on the site involved and include retention cysts, lipomas, fibromas, neurofibromas, and mucocoeles.<sup>[6]</sup>

Histopathological examination confirms diagnosis of cysticercosis by the detection of a cystic space containing the *C. cellulosae*, lined by three layers: inner cuticular, middle granular, and outer loose parenchymatous lining.

The diagnosis of oral cysticercosis is made by direct histological examination. In every case, detailed study should be done in order to exclude the presence of the parasite in other sites. MRI and computerized tomography (CT) may be used to evaluate CNS involvement. Even in an endemic area, lip is a rare site of involvement in cysticercosis. Confirmative diagnosis of cysticercosis is only made by histopathological examination.

Treatment of oral cysticercosis should be according to the specific needs of the patient and relies on antihelminthic drugs or surgery.



**Figure 2:** Histopathological slide showing cystic space containing the *Cysticercus cellulosae*, Lined by 3 layers inner cuticular, middle granular, and outer loose parenchymatous lining

## CONCLUSIONS

- Lip is a rare site of involvement in cysticercosis.
- Confirmative diagnosis of cysticercosis is only made by histopathological examination.
- In every case, detailed study should be done in order to exclude the presence of the parasite in other sites. MRI and CT may be used to evaluate CNS involvement.

## ACKNOWLEDGMENT

We are thankful to our Dean and Director (ME and MH), Sanjay Oak, for permitting us to publish this paper.

## REFERENCES

1. Prabhu SR, Bhatt AP, Viswanathan R. Helminthic diseases. In: Prabhu SR, Wilson DF, Daftary DK, Johnso NW, editors. Oral diseases in the tropics. Oxford: Oxford Medical Publications; 1993. p. 126-9.
2. Romero De Leon E, Aguirre A. Oral cysticercosis. Oral Surg Oral Med Oral Pathol Oral Radiol Endod 1995;79:572-7.
3. Davis LE. "Neurocysticercosis" Emerging Neurological Infections. In: Power C, Johnson RT, editors. United Kingdom: Taylor and Francis Group; 2005. p. 261-87.
4. Garcia HH, Del Brutto OH. *Taenia solium* cysticercosis. Infect Dis Clin North Am 2000;14:97-119.
5. Delgado-Azañero WA, Mosqueda-Taylor A, Carlos-Bregni R, Del Muro-Delgado R, Díaz-Franco MA, Contreras-Vidaurre E. Oral Cysticercosis: A collaborative study of 16 cases. Oral Surg Oral Med Oral Pathol Oral Radiol Endod 2007;103:528-33.
6. Ribeiro AC, Luvizotto MC, Soubhia AM, de Castro AL. Oral cysticercosis: Case report. Oral Surg Oral Med Oral Pathol Oral Radiol Endod 2007;104:e56-8.
7. Kumar N, Mazhari JN, Jain S. Cysticercosis of oral mucosa: Aspiration cytologic diagnosis. J Oral Pathol Med 2001;30:187-9.
8. de Souza PE, Barreto DC, Foneseca LM, de Paula AM, Silva EC, Gomez RS. Cysticercosis of the oral cavity: Report of seven cases. Oral Dis 2000;6:253-5.
9. de Souza PE, Barreto DC, Foneseca LM, de Paula AM, Silva EC, Gomez RS. Cysticercosis of the oral cavity: Report of seven cases. Oral Dis 2000;6:253-5.
10. Ribeiro AC, Luvizotto MC, Soubhia AM, de Castro AL. Oral cysticercosis: Case report. Oral Surg Oral Med Oral Pathol Oral Radiol Endod 2007;104:e56-8.
11. Sara RK, Rattan V, Rajwanshi A, Nijkawan R, Gupta SK. Cysticercosis of the oral cavity: Report of five cases and review of literature. Int J Paediatr Dent 1998;8:273-8.

**How to cite this article:** Sathe NU, Acharya RG, Patil M, Bhatia A, Chiplunkar D. An unusual case of labial cysticercosis with a natural history. Natl J Maxillofac Surg 2011;2:100-2.

**Source of Support:** Nil. **Conflict of Interest:** None declared.