

## Partial corneal recovery following selective trabeculoplasty-induced keratopathy: Longitudinal analysis through scheimpflug imaging

Ana Elisa Loyola Arancibia<sup>a,b</sup>, Victoria Almeida Corrêa Gontijo<sup>a,b</sup>,  
Ana Luiza Bassoli Scoralick<sup>b,c</sup>, Fabio Nishimura Kanadani<sup>a,d</sup>, Tiago Santos Prata<sup>b,c,d,\*</sup>

<sup>a</sup> Department of Ophthalmology, Instituto de Olhos Ciências Médicas, 407, Pouso Alegre Street, Belo Horizonte, 31015-065, Minas Gerais, Brazil

<sup>b</sup> Glaucoma Unit, Hospital Medicina dos Olhos, 207, Salem Bechara Street, Osasco, São Paulo, 06018-180, Brazil

<sup>c</sup> Department of Ophthalmology, Federal University of São Paulo, 822 – Botucatu Street, São Paulo, 04039-032, Brazil

<sup>d</sup> Department of Ophthalmology, Mayo Clinic, 4500 San Pablo Road, Jacksonville, FL, 32224, USA

### ARTICLE INFO

#### Keywords:

Selective laser trabeculoplasty  
Side effect  
Corneal complication  
Keratopathy

### ABSTRACT

**Purpose:** To report an uncommon case of hyperopic shift and corneal haze, flattening and thinning following a single session of selective laser trabeculoplasty (SLT), and provide longitudinal clinical data and serial analyses of corneal profile through Scheimpflug imaging. Furthermore, a careful literature review was undertaken to determine possible risk factors for this complication.

**Observations:** A 47-year-old woman presented with blurred vision and mild corneal edema and haze three days following routine SLT. Ten days later, corneal edema resolved, but she was still symptomatic. Refraction exam revealed a significant hyperopic shift and high astigmatism (+4.00–6.00 x 80° versus –11.50 –0.75 x 170° at baseline). Scheimpflug imaging revealed a partial collapse of the corneal architecture, with an expressive central cornea flattening (>10 diopters) and thinning (>190µm). Over six months, refractometric and corneal parameters gradually (but not completely) returned to their pre-operative values.

**Conclusions and Importance:** This tetrad of clinical findings - hyperopic shift, corneal haze, flattening and thinning - following SLT is referred herein by the authors as selective trabeculoplasty-induced keratopathy (STIK), which is a rare but serious complication. A critical analysis based on this case findings and on the few others reported so far suggests high-myopic patients to be more predisposed to this complication, as all reported cases had –5.0 diopters or more. Future studies are warranted to determine whether this complication can be prevented.

### 1. Introduction

Glaucoma is a chronic and progressive optic neuropathy, characterized by progressive retinal ganglion cells loss, changes in the appearance of the optic disc and visual field damage.<sup>1</sup> Elevated intraocular pressure (IOP) remains as the most important known risk factor for disease development and progression and until now the only modifiable one.<sup>2,3</sup> Many large randomized clinical trials (RCTs) underscored the importance of an adequate IOP control to slow the rates of disease progression and avoid functional impairment.<sup>2–4</sup>

Treatment options for IOP reduction in glaucoma are usually categorized into three main groups: topical medications, laser surgery, and incisional surgery. Even though topical hypotensive medications have been often used as the first-line treatment option, the indication of laser

trabeculoplasty as an alternative for primary treatment of open-angle glaucoma (OAG) has increased significantly in the past decades, especially after the advent of selective laser trabeculoplasty (SLT) in 1995.<sup>5</sup> SLT lowers IOP by inducing biological changes in the trabecular meshwork resulting in increased aqueous outflow.<sup>5</sup> It is performed with a Q-switched Nd: yttrium-aluminum-garnet (YAG) laser ( $\lambda = 532$  nm), that delivers short burst of low-fluence laser energy to selected melanin-containing cells in the trabecular meshwork, causing intracellular targeting of the pigmented trabecular meshwork cells without damage to adjacent non-pigmented cells or structures.<sup>5</sup> This trend towards laser treatment for initial management in cases of OAG can be explained in part by the numerous studies (including RCTs) reporting primary SLT to be at least as effective as topical hypotensive medication.<sup>6–8</sup> In addition, when adopted as initial therapeutic alternative,

\* Corresponding author. Glaucoma Service - Federal University of São Paulo - Brazil, Rua Dr Jose Rodrigues Alves Sobrinho, 125, Alto de Pinheiros, São Paulo, CEP: 05466-040, Brazil.

E-mail address: [tprata@unifesp.br](mailto:tprata@unifesp.br) (T.S. Prata).

<https://doi.org/10.1016/j.ajoc.2021.101062>

Received 30 May 2020; Received in revised form 18 February 2021; Accepted 21 February 2021

Available online 26 February 2021

2451-9936/© 2021 Published by Elsevier Inc. This is an open access article under the CC BY-NC-ND license (<http://creativecommons.org/licenses/by-nc-nd/4.0/>).

SLT could minimize ocular side effects and compliance issues related to clinical treatment with eye drops.<sup>6-9</sup>

When it comes to its safety profile, side effects related to SLT treatment are uncommon, and when documented, are usually transitory.<sup>6-8,10</sup> Most commonly post-operative side effects include IOP spikes (that can be minimized by adequate laser power settings and pre-operative hypotensive medication) and prolonged ocular inflammation.<sup>6-8,11</sup> Serious corneal complications after SLT are rare.<sup>12</sup> In fact, as a non-invasive and safe procedure, only a few sight-threatening complications have been reported. In the present case report, we provide longitudinal clinical data and serial analyses of anterior axial curvature, posterior axial curvature, posterior elevation Best Fit Toric Aspheric (BFTA) and pachymetry maps (through Scheimpflug imaging) of a case of hyperopic shift, haze, flattening and thinning of the cornea following a single session of SLT treatment. This tetrad of signs and symptoms related to significant corneal changes after SLT, which have been documented in part in few cases in the literature,<sup>13</sup> is referred herein by the authors as selective trabeculoplasty-induced keratopathy (STIK). In this article, we present the results of 6 months follow-up from the laser procedure until partial corneal recovery, and discuss the possible underlying mechanisms related to this rare SLT complication.

## 2. Case report

A 47-year-old white woman was referred to our service with a previous (recent) diagnosis of open-angle glaucoma. She was under topical therapy with a prostaglandin analogue (bimatoprost 0.01%) in both eyes for almost 3 months. At presentation, she complained of redness and ocular discomfort. These symptoms were compatible with her clinical examination (slit-lamp biomicroscopy), which revealed significant conjunctival hyperemia and diffuse punctate keratitis. Corrected distance visual acuity (CDVA) was 20/25 in both eyes (OU), and refraction was  $-11.50 -0.75 \times 170^\circ$  (OD) and  $-11.00 -2.00 \times 180^\circ$  (OS). Treated IOP (Goldmann applanation tonometry) was 12 mmHg OD and 11 mmHg OS at 10am, and central corneal thickness (CCT) was approximately 490 $\mu$ m OU. Fundoscopic exam revealed a cup-to-disc ratio of approximately 0.8 OU. Regarding functional loss, patient was classified as stage 2 according to the Glaucoma Staging System (visual field mean deviation index was  $-7.1$  dB OD and  $-6.7$  dB OS). After a six-week wash-out period, ocular side effects improved significantly, and untreated IOP was 16 mmHg OD and 15 mmHg OS at 9am. Considering patient's age, disease stage and untreated IOP values, SLT treatment was indicated for OU (one eye at a time). The patient underwent routine SLT application (Lightlas SLT Deux; Lightmed Corporation, San Clemente, CA) in the right eye, in which 120 shots (0.8 mJ per pulse) were applied to 360° of the trabecular meshwork.

Three days after the procedure, the patient complained of ocular discomfort and blurred vision in the treated eye. CDVA was 20/80 and IOP was 10 mmHg at 2pm. Biomicroscopy exam showed mild central corneal edema and haze, associated with diffuse keratitis (fluorescein positive) and epithelial irregularity. There was a mild anterior chamber reaction, without any signs of inflammatory process in the posterior pole. Therapeutic contact lens, artificial tears and topical loteprednol 0.5% 4 times daily (q.i.d) were prescribed. Corneal edema and keratitis resolved along the next 10 days, remaining solely a discrete corneal haze in the paracentral area. However, the patient still complained of blurred vision. Additionally, she referred that visual acuity in the lasered eye was better without her glasses than with her usual myopic correction. In fact, refraction exam revealed an extensive hyperopic shift along with the presence of high astigmatism ( $+4.00 -6.00 \times 80^\circ$ ). Corneal profile analysis through Scheimpflug imaging technique (Galilei; Ziemer Ophthalmic Systems, Switzerland) detected a significant flattening and thinning of the central cornea (column A of Fig. 1). Topical treatment with loteprednol was maintained q.i.d. Over the following weeks, changes in refraction, corneal curvature and thickness were documented in every visit. Refractometric and corneal parameters gradually (but not

completely) returned to their pre-operative values (Table 1 and Fig. 1). These changes were non-linear, being more pronounced in the first two months, compared to the last 4 months of follow-up. In fact, there were almost no perceptible changes between months 4–6. At the last follow-up visit (6 months post-operatively), CDVA was 20/30 (refraction of  $-6.00 -4.50 \times 60$ ), the cornea kept a discreet haze, untreated IOP was 12 mmHg and CCT was 443 $\mu$ m in the SLT-treated eye. Even though CCT measurements through ultrasound pachymetry would likely provide more precise measurements in this case, we opted for a non-contact method due to patient's initial discomfort and keratitis. Therefore all follow-up CCT values were obtained through Scheimpflug technique. Endothelial cell count (specular microscopy) dropped from 2681 cells/mm<sup>2</sup> to 2278 cells/mm<sup>2</sup>.

## 3. Discussion

The use of SLT for open-angle glaucoma treatment has increased significantly, both as an adjunctive treatment modality or as a first-line alternative.<sup>6-8</sup> The spread of SLT worldwide can be attributed not only to its relatively good effectiveness, but also to its favorable safety profile.<sup>5-8,10</sup> Nonetheless, previous reports have shown that a few serious complications may occur.<sup>12-15</sup> We believe that the case we report herein may not only help clinicians to recognize STIK as a potential SLT complication and corroborates previous similar findings, but also adds significant information about its clinical course and magnitude of corneal anatomical changes based on quantitative imaging parameters.

Regarding possible underlying mechanisms related to this serious SLT complication, the exact causes that would lead to the partial collapse of the corneal architecture within just a few days after the laser procedure are still unknown. Some causes have been previously postulated, such as reactivation of latent ocular herpes simplex virus, residual alcohol on the gonioscopes and direct laser damage to the cornea.<sup>11,15</sup> Apparently these etiologies do not present a strong rationale in terms of cause-effect relationship, having in mind the type and timing of corneal changes observed in eyes with STIK.<sup>11,15</sup> Another cause that could possibly play a role in this complication is an abnormal corneal tissue response to inflammatory mediators released after SLT.<sup>11,13</sup> The resulting inflammatory response includes release of vasoactive and chemotactic substances, as interleukin-1 alpha, interleukin-1 beta and tumor necrosis factor alpha.<sup>11</sup> It has been proposed that these pro-inflammatory mediators, at the corneal level, could degrade stromal collagen, ultimately leading to corneal thinning, topographic changes and transparency loss.<sup>11,13</sup> A significant increase of matrix metalloproteinase expression (mainly type 2) and free radical production in the aqueous humor following SLT procedure could also affect the corneal tissue.<sup>11,14</sup> Of note, the patient was under topical therapy with a prostaglandin analogue prior to SLT treatment. Even though we were not able to establish any cause-effect relationship in the present study, we believe that a possible association between previous exposure to topical prostaglandin analogues and this post-SLT complication should not be disregarded.

When it comes to risk factors, the very low incidence and small number of reported cases undoubtedly precludes any longitudinal study or cause-effect analysis. As an alternative, one might consider trying to put together any characteristics that were common to the cases developing this post-SLT complication. Looking carefully at each individual case of hyperopic shift and corneal thinning after SLT that has been previously reported, we noticed that most affected patients were myopic (median,  $-10.0$  D; range, from  $-5.25$  D to  $-19.25$  D), middle-aged (median age, 56 years old; range, from 46 to 63 years), Caucasian (5/6) and women (5/6).<sup>13-15</sup> Interestingly, our case fulfills all these characteristics. Even though these patients' specific profile is based on a still small number of observations, we believe it can serve as a possible early warning of those eventually more predisposed to this rare complication, in addition to giving basis for future studies (possibly in non-human



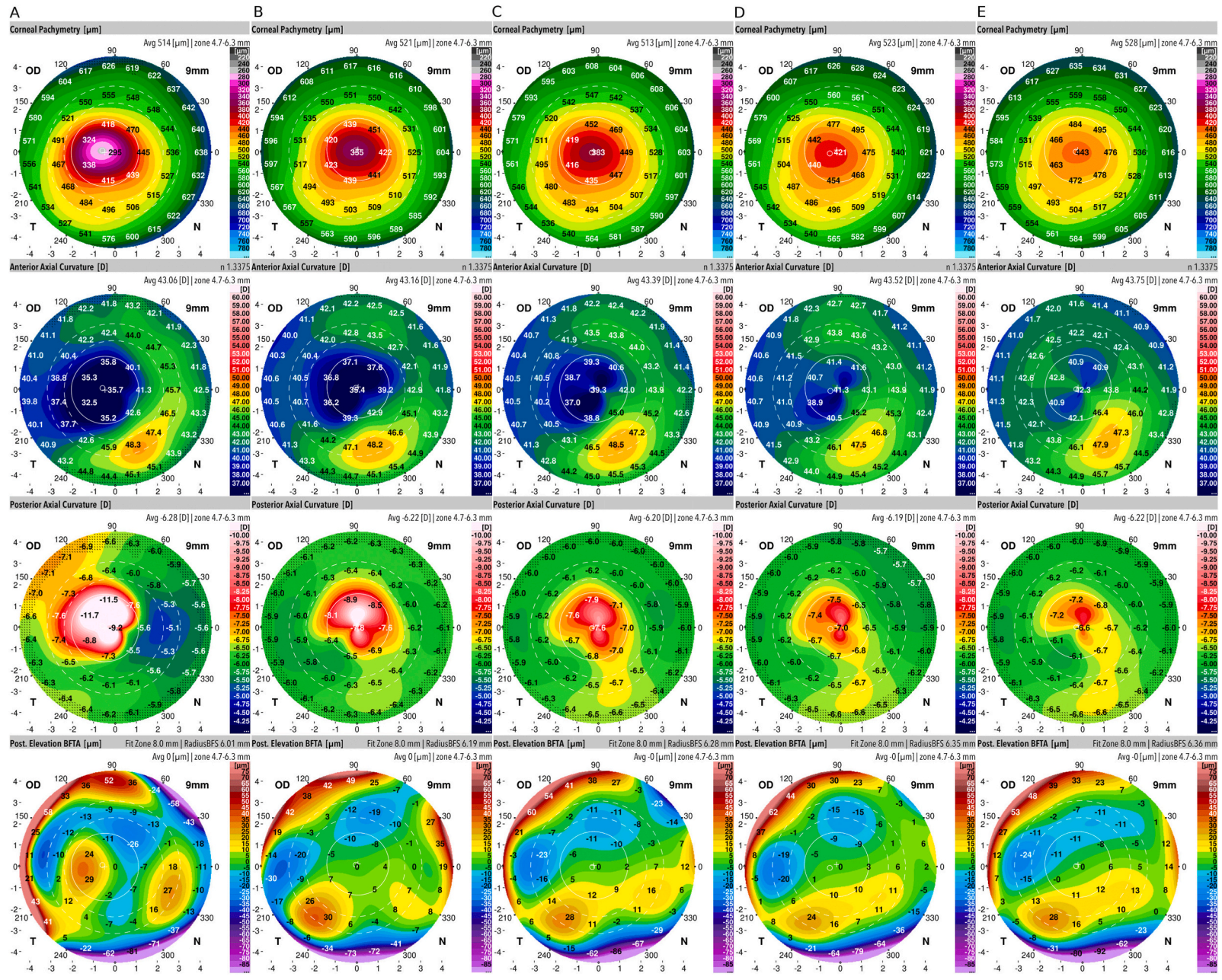


Fig. 1. Corneal tomographic maps at different time points (A, 15 days; B, 30 days; C, 45 days; D, 3 months and E, 6 months) are displayed. Longitudinal data regarding anterior axial curvature, posterior axial curvature, posterior elevation Best Fit Toric Aspheric (BFTA) and pachymetry maps (Scheimpflug imaging) are provided.

**Table 1**

Refraction and corneal parameters of the laser-treated eye at different time points.

	PRE- OP	15 DAYS	6 WEEKS	2 MONTHS	6 MONTHS
Spherical equivalent (diopters)	-12.00	+1.00	-4.00	-6.75	-8.25
Central corneal thickness (microns)	490 <sup>a</sup>	295	397	419	443
Total corneal power (diopters)	44.4 <sup>b</sup>	32.9	38.5	40.3	41.4
Corrected distance visual acuity	20/25	20/80	20/60	20/40	20/30
Endothelial cell count (specular microscopy)	2681	2062	2488	2114	2278

Corneal parameters were obtained through Scheimpflug imaging technique.

<sup>a</sup> Pre-operative measurement was based on ultrasound pachymetry.

<sup>b</sup> Pre-operative value was obtained from the untreated fellow eye (pre-operative refraction was similar between eyes).

models) focusing on the identification of risk factors and pathological mechanisms.

#### 4. Conclusion

Physicians should recognize selective trabeculoplasty-induced keratopathy as a rare but serious SLT complication. Longitudinal analysis suggests that although significant improvement was observed during the first 3 months post-laser, corneal recovery was much slower in the following months, and topographic and thickness changes may only partially resolve over time. Although still a relatively premature assumption rather than a definitive conclusion, myopic, middle-aged women seem to be more predisposed to this complication. In fact, special attention could be given to high-myopic patients while indicating SLT, as all 7 cases were reported in eyes with  $-5.0D$  or more. Objective imaging parameters are useful to quantify corneal topographic and pachymetric changes during follow-up. Finally, future studies are warranted to determine potential risk factors and whether this complication can be prevented.

#### Patient consent

The patient gave written permission to publish their case. IRB approval was not indicated.

#### Funding

No funding or grant support.

#### Authorship

All authors attest that they meet the current ICMJE criteria for Authorship.

#### Declaration of competing interest

All authors have no financial disclosures.

#### Acknowledgements

None.

#### References

- Weinreb RN, Khaw PT. Primary open-angle glaucoma. *Lancet*. 2004;363(9422):1711–1720.
- Kass MA, Heuer DK, Higginbotham EJ, et al. The Ocular Hypertension Treatment Study: a randomized trial determines that topical ocular hypotensive medication delays or prevents the onset of primary open-angle glaucoma. *Arch Ophthalmol*. 2002;120(6):701–713.
- The AGIS Investigators the Advanced Glaucoma Intervention Study (AGIS): 7. The relationship between control of intraocular pressure and visual field deterioration. *Am J Ophthalmol*. 2000;130(4):429–440.
- Heijl A, Leske MC, Bengtsson B, Hyman L, Bengtsson B, Hussein M. Early manifest glaucoma trial G reduction of intraocular pressure and glaucoma progression: results from the early manifest glaucoma trial. *Arch Ophthalmol*. 2002;120(10):1268–1279.
- Latina MA, Sibayan SA, Shin DH, Noecker RJ, Marcellino G. Q-switched 532-nm Nd: YAG laser trabeculoplasty (selective laser trabeculoplasty): a multicenter, pilot, clinical study. *Ophthalmology*. 1998;105(11):2082–2088.
- Freitas AL, Ushida M, Almeida I, et al. Selective laser trabeculoplasty as an initial treatment option for open-angle glaucoma. *Arq Bras Oftalmol*. 2016;79(6):417–421.
- Gazzard G, Konstantakopoulou E, Garway-Heath D, et al, LiGHT Trial Study Group. Selective laser trabeculoplasty versus eye drops for first-line treatment of ocular hypertension and glaucoma (LiGHT): a multicentre randomised controlled trial. *Lancet*. 2019;393(10180):1505–1516.
- Katz LJ, Steinmann WC, Kabir A, et al. Selective laser trabeculoplasty versus medical therapy as initial treatment of glaucoma: a prospective, randomized trial. *J Glaucoma*. 2012;21(7):460–468.
- Olthoff CM, Schouten JS, van de Borne BW, Webers CA. Noncompliance with ocular hypotensive treatment in patients with glaucoma or ocular hypertension: an evidence-based review. *Ophthalmology*. 2005;112(6):953–961.
- Klamann MK, Maier AK, Gonnermann J, Ruokonen PC. Adverse effects and short-term results after selective laser trabeculoplasty. *J Glaucoma*. 2014;23(2):105–108.
- Paiva ACM, da Fonseca AS. Could adverse effects and complications of selective laser trabeculoplasty be decreased by low-power laser therapy? *Int Ophthalmol*. 2019;39(1):243–257.
- Wood SD, Elam A, Moroi S. Rare corneal complication following selective laser trabeculoplasty. *Am J Ophthalmol Case Rep*. 2018;10:28–31.
- Knickerbein JE, Singh A, Flowers BE, et al. Acute corneal edema with subsequent thinning and hyperopic shift following selective laser trabeculoplasty. *J Cataract Refract Surg*. 2014;40(10):1731–1735.
- Song J, Yu D, Song A, Palmares TS, Song H, Song M. Corneal thinning and opacity following selective laser trabeculoplasty: a case report. *J Adv Med Med Res*. 2013;4(1):279–287.
- Regina M, Bunya VY, Orlin SE, Ansari H. Corneal edema and haze after selective laser trabeculoplasty. *J Glaucoma*. 2011;20(5):327–329.