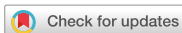

Original Article
Surgery



Surgical outcomes in dogs with tracheal collapse treated with a novel cross-and-hook braided endoluminal stent

Akiko Uemura ^{1,*}, Yusuke Ozai ², Lina Hamabe ², Tomohiko Yoshida ², Ryou Tanaka ²

¹Division of Veterinary Research, Department of Clinical Veterinary Medicine, Obihiro University of Agriculture and Veterinary Medicine, Obihiro 080-8555, Japan

²Department of Veterinary Surgery, Faculty of Veterinary Medicine, Tokyo University of Agriculture and Technology, Tokyo 183-8509, Japan



Received: Nov 5, 2021

Revised: Feb 27, 2022

Accepted: Mar 21, 2022

Published online: Apr 1, 2022

*Corresponding author:

Akiko Uemura

Division of Veterinary Research, Department of Veterinary Surgery, Obihiro University of Agriculture and Veterinary Medicine, 2-11 Inadacho Nishi, Obihiro 080-8555, Japan.

Email: anco@vet.ne.jp

auemura@obihiro.ac.jp

https://orcid.org/0000-0003-2671-5074

ABSTRACT

Background: Stenting is an effective treatment option for tracheal collapse in dogs. Cross-braided tracheal stents are currently the norm in veterinary medicine, but cross-and-hook braided stents have recently been adopted in human medicine. We examined whether stents manufactured using this novel braiding technique provided additional advantages for the treatment of tracheal collapse in dogs.

Objectives: To evaluate the outcomes of cross-and-hook braided stent implantation in the treatment of tracheal collapse in dogs.

Methods: The medical records of 22 client-owned dogs that underwent luminal placement of cross-and-hook braided Fauna Stents for the treatment of tracheal collapse between January 2018 and July 2021 were examined and data on canine signalment, clinical signs, diagnostic test results, surgical outcomes, and postoperative complications were retrieved and analyzed statistically.

Results: Twenty-six stents were surgically implanted, with 20 dogs (90.9%) receiving one stent and the remaining two (9.1%) receiving two or more stents. All dogs survived the procedure. The median survival time at a median follow-up of 990 days was 879 days. At the final follow-up examination, loss or mild improvement of cough was observed in all dogs.

Conclusions: Compared with conventional lumen stents, the cross-and-hook braided Fauna Stent offered a higher survival rate and improved clinical symptoms in all patients. The results of this study suggest that the Fauna Stent may be a promising treatment option for dogs with tracheal collapse.

Keywords: Tracheal diseases; stents; dogs; minimally invasive surgical procedures

INTRODUCTION

Tracheal collapse is more common in small breeds, such as Yorkshire Terriers, Toy Poodles, Pomeranians, Chihuahuas and Pugs, and is often fatal in severe cases [1-4]. Although the disease is most common in middle-aged dogs [1,3,4], it has been reported to be more severe at a younger age [1]. There is no sex difference in the incidence [1,3,4]. Tracheal collapse has

ORCID iDs

Akiko Uemura
<https://orcid.org/0000-0003-2671-5074>
Yusuke Ozai
<https://orcid.org/0000-0001-7191-1483>
Lina Hamabe
<https://orcid.org/0000-0002-5291-925X>
Tomohiko Yoshida
<https://orcid.org/0000-0003-4311-9311>
Ryou Tanaka
<https://orcid.org/0000-0001-9948-6490>

Author Contributions

Conceptualization: Uemura A, Tanaka R; Data curation: Uemura A, Ozai Y, Yoshida T; Formal analysis: Uemura A; Funding acquisition: NA; Investigation: Uemura A, Ozai Y, Yoshida T, Tanaka R; Methodology: Uemura A, Tanaka R; Project administration: Uemura A, Tanaka R; Resources: Uemura A, Tanaka R; Software: Uemura A; Supervision: Tanaka R; Validation: Uemura A, Tanaka R; Visualization: Uemura A; Writing - original draft: Uemura A; Writing - review & editing: Uemura A, Ozai U, Hamabe L, Yoshida T, Tanaka R.

Conflict of Interest

The authors declare no conflicts of interest.

been reported to be the result of congenital predisposition as well as external factors such as obesity, environmental allergens, tobacco, and kennel cough, all of which worsen the clinical signs [3,5]. Tracheal collapse has recently been divided into malformed and traditional types [6], and this classification is based on the degree of reduction of the lumen diameter in the dorsoventral direction, with four discrete stages (I to IV) defined [7].

The available options for treatment of tracheal collapse in dogs can broadly be divided into medical and surgical therapy. Medical therapy is used to manage the disease in mild cases, while surgical therapy is recommended in more severe cases [8,9]. Surgical therapy consists of either suturing a ring of polypropylene or parallel loop line prostheses made from plastic optical fiber from outside the tracheal cavity [10] or placing a metallic stent in the tracheal lumen. Both surgical treatments have been shown to immediately improve clinical symptoms. Since serious postoperative complications such as tracheal lacerations [11] and laryngeal paralysis have frequently been reported with extratracheal therapy [1,12,13], endoluminal stenting therapy has become the technique of choice [12]. Because extraluminal therapy requires exposure of the trachea, the indication is essentially limited to the cervical region, and most tracheal collapse located in the thoracic region are therefore not suitable for the technique. Furthermore, extraluminal therapy is more invasive than stenting due to the longer time required to induce anesthesia and perform the procedure [5,11,12]. In line with this, the length of hospital stay also tends to be longer with extraluminal therapy than with intraluminal stenting [12]. Additional stent therapy has also been reported to be necessary due to continuation or recurrence of tracheal collapse after extraluminal therapy had been performed [12].

Endotracheal stenting has fewer serious complications, but there is still room for improvement in conventional endotracheal stents [12]. Goose honking disappears as narrowing of the airway is alleviated after stent placement. However, stent placement physically irritates the trachea and inhibits the movement of mucus by the ciliated cells, resulting in coughing [14,15]. Postoperative complications associated with conventional endotracheal stents include inflammation, bacterial tracheitis ($\leq 58\%$) [12,14,15], stent failure ($\leq 42\%$) [12,14,16], stent migration ($\leq 37\%$) [12,15,17], and stent shortening ($\leq 27\%$: shortening) [15,17,18]. The extends from the neck to the chest and is subjected to movement not only in the neck but also in the chest, where it accompanies the movement of the esophagus and other intrathoracic organs. In particular, stents implanted in the cervical trachea need to be able to cope with the complex and dynamic movements of the neck. If the stent cannot cope with these movements, inflammation in the area between the stent and the tracheal mucosa and/or breakage, migration, or shortening are likely to occur.

The use of a novel stent that minimizes complications such as stent migration and fracture would greatly contribute to improvement in the prognosis of tracheal collapse in dogs. The purpose of this study was to investigate the potential improvement in postoperative complications and clinical symptoms in 22 dogs with tracheal collapse resulting from the placement of a self-expandable endotracheal stent with cross-braid and hook-braid, which is different from the traditional self-expandable stent featuring exclusively cross-braid.

MATERIALS AND METHODS

Case selection

A retrospective review of 22 dogs referred to the Animal Medical Center of the Tokyo University of Agriculture and Technology and the Obihiro University of Agriculture and Veterinary Medicine Center for tracheal collapse grade [7] III or higher and underwent tracheal stenting between January 2018 and July 2021 was performed. All cases were undergoing medical management at the time of referral and this had proven ineffective. In addition to chest radiography, dynamic airway imaging was used to confirm the diagnosis of tracheal collapse [19]. Dynamic airway imaging (Cios Select FD; Siemens K.K., Japan) was performed in the lower right lateral position while the dog awake. The total duration of the imaging procedure was three to five breaths, until tracheal collapse was observed. Data collected from the medical records included age, sex, breed, weight, radiographic results, and concomitant diseases. The cough and associated clinical status before and after stent placement were scored as follows. 0: No coughing at all, even with vigorous activity such as running. 1: coughing occurs 2–3 days per week, lasting only a few times and not affecting daily life. 2: coughing occurs every day, even at rest, but does not interfere with daily life; 3, coughing occurs every day, even at rest, sometimes interfering with daily life but sleep; and 4, coughing occurs every day, even at rest, and is severe enough to or prevent sleep, breathing difficulties are evident in room air (20% oxygen concentration).

Stent placement

All dogs underwent chest radiography (lateral lower right images on inspiration and expiration, ventrodorsal on inspiration) within 72 hours before and after tracheal stent placement. A Nitinol cross-and-hook braided self-expanding metal stent (Fauna Stent; M. I. Tech Co., Ltd., Korea) was used in all cases (**Fig. 1**). The stent diameter was chosen to be between 10% and 20% of the maximum diameter in the area caudal to the site of tracheal collapse, where no collapse was evident [15]. The length of the stent placed in the first two cases corresponded to the length of the site of collapse [15], whereas in the remaining cases the length was chosen to be equal to the maximum length of the trachea [14]. In this latter case, the stent was placed caudally at a position that prevented contact with the larynx and cranially at a position that prevented contact with the carina [8].

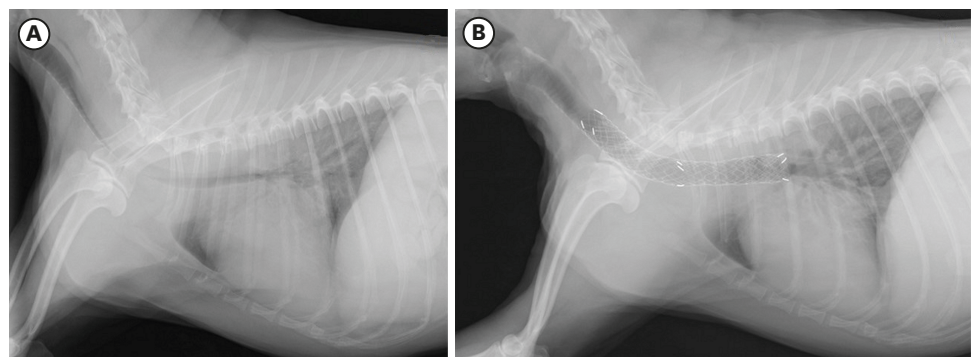


Fig. 1. Chest radiograph of a dog before (A) and after (B) placement of the Fauna Stent. Because this stent is cross-and-hook braided, each cell is not only diamond shaped but also has an independent shape.

Statistical analysis

The Mann-Whitney test was used to determine the statistical significance of the differences in cough scores before and after stenting.

RESULTS

Case characteristics

All the dogs that underwent stenting belonged to small breeds and consisted of ten Pomeranians, three Yorkshire Terriers, three Chihuahuas, two Poodles, and two dogs of mixed breed. Ten of them were male and 12 were female. Their age ranged from 6 to 16 years (median 11 years) and their body weight ranged from 2.4 to 5.4 kg (median 3.7 kg). Preoperative clinical symptoms included cough in all cases, goose honking in seven cases, dyspnea in three cases, and cyanosis in a single case. Seventeen dogs had concomitant diseases: Nine had mitral regurgitation, two had soft palate hyperostosis, three had neoplastic disease, one had pulmonary edema, one had epileptic seizures, and one had chronic renal failure. All the dogs were administered antibiotics (ampicillin 30 mg/kg, intravenously [iv], BID during hospitalization; 15–30 mg/kg, per os [po], twice daily [BID] after discharge) and steroids (prednisolone 1.0 mg/kg, iv, once daily [SID] from the day of surgery). After stent placement, the dosage was gradually decreased and the medication was terminated in approximately 1 week. In addition, postoperative nebulization (Tyloxapol 2.5 mg/head, Alevaire Inhalation Solution 0.125%, Alfresa Pharma Co., Japan; albuterol 2.5 mg/head, Venetlin for Inhalation 0.5%, GlaxoSmithKline K.K., Japan; acetylcysteine 200 mg/head, Mucofilin 20%, Eisai Co., Ltd., Japan; kanamycin 125 mg/head, Kanamycin Sulfate Injection 250 mg/mL; budesonide 0.25 mg/head, Pulmicort Respules 0.25 mg, AstraZeneca K.K., Japan) was administered once or twice a day for several days to a month, depending on the severity of the postoperative cough.

The median cough score before stent placement was 4. The median cough score immediately after stent placement was 1.5, and it persisted at this value 1 week was 1, and 1 month after stent placement was 1. Cough scores were significantly reduced immediately ($p < 0.0001$), 1 week ($p < 0.0001$), and 1 month ($p < 0.0001$) after stent placement compared with before (Fig. 2).

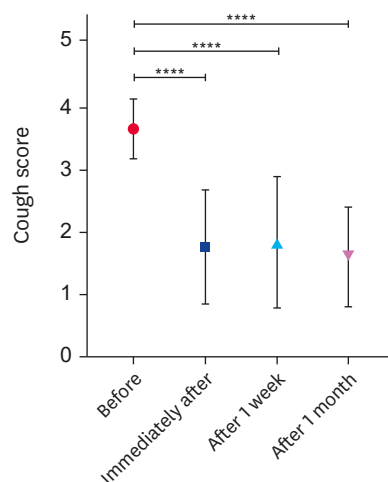


Fig. 2. Cough score before and after stent placement.

Comparing cough scores before, immediately after, one week after, and one month after stent placement, cough scores improved significantly in all cases (**** $p < 0.0001$).

Clinical outcome

Significant improvements in clinical signs and postoperative complications were observed. A total of 26 stents were placed, with 20 dogs (90.9%) receiving one stent and the remaining two dogs (9.1%) receiving two or more stents. All dogs survived the procedure and were eventually discharged. The median survival time at a median follow-up of 990 days was 879 days. At the final follow-up examination, loss or mild healing of cough (100% [22/22]), improvement in goose-honking (100% [7/7]), and dyspnea (100% [3/3]) were reported.

Fractur

Complications requiring additional stenting occurred in two dogs (9.1%) during the follow-up period. One of the cases was due to stent fracture (fractured middle), whereas the other case corresponded to one of the dogs implanted early in the study and required additional stents to be placed due to migration of the originally implanted stent and subsequent tracheal collapse at the anterior and posterior ends of the stent.

DISUCCUSION

In recent years, endoluminal stent therapy has become more common than extraluminal alternative for the treatment of tracheal collapse, and it is the method of choice in small dogs [12]. However, several postoperative complications have been reported with conventional endoluminal tracheal stents [12,14-17], and there is room for further improvement of the technique. Treatment with minimally invasive tracheal stent [5,11,12], which can be used to treat both cervical and thoracic tracheal collapse irrespective of the site the site and requires shorter times for anesthesia induction and surgery, is an effective way to reduce the incidence of complications. If the incidence of these complications can be reduced, minimally invasive and site-specific treatment of tracheal collapse will be achievable. A recent report has also recommended that dogs with severe tracheal collapse refractory to medical treatment should have a tracheal stent placed [20].

Although all self-expanding stents made of Nitinol may seem to have similar properties, it should be noted that the stent properties vary considerably depending on the braiding method. In recent years, cross-and-hook-net Nitinol stents have been adopted in human medicine [21,22]. There are two known weaknesses of the conventional cross-braided tracheal stent: first, they are vulnerable to external forces acting in the direction of the long-axis and are prone to elongation, and second, there is a risk of constant stimulation of the surrounding tissues due to their ability to be restored to their initial shape in response to external forces in the transverse axis and in three dimensions. A photograph of the stent before implantation is shown in **Fig. 3**.

Nitinol stents made of hybrid braiding (with cross-and-hook braiding) have been reported to be more resistant to breakage than the conventional stents [23]. Although limited to a single case report in which the brand name was not explicitly mentioned, there is some evidence suggesting that hybrid Fauna Stents may reduce the risk of stent failure due to their ability to adapt to the shape of the surrounding tissue.

The Fauna Stent is characterized by three potential advantages derived from cross-and-hook knitting of the Nitinol thread. First, it has high tensile strength against tension and pressure and is not prone to migration or shortening, provided that the right size has been chosen.




Fig. 3. Influence of the weaving method on the shape adopted by the stent after being bent. Stents with the same braiding method as the Fauna Stent (A) and with the same braiding method as the conventional bronchial stent (B) are widely used in veterinary medicine. The cross-and-hook braided Fauna Stent can retain its deformed shape when subjected to an external force, whereas the conventional stent returns to its original straight shape when the hand pressure is released. In addition, the Fauna stent is less stretchable than conventional stents when subjected to external forces in the direction of the long axis.

Second, it can change its shape in response to bending, shearing, and twisting forces, which allows it to follow the three-dimensional movement of the trachea and adapt its shape to the tracheal wall. Third, each cell can maintain its independent shape, which allows for stent-in-stent or multi-stent placement, (in which multiple stents are added to the metal gap) if needed [21,22]. However, reported problems such as stent migration, fracture, shortening after implantation, and coughing caused by physical irritation highlight the fact that current tracheal stents still require improvement [6,12,24].

In recent reports, fracture rates have been reported as 19% by Weisse et al. [6] and 25% by Violette et al. [24] for conventional cross-braded single stents. In our study, the incidence of stent migration was 4.5% (1/22 cases), and that of fracture was 9.1% (2/22 cases), whereas no shortening was observed. The fracture rate was comparable or lower than that reported in recent studies. In this study, multiple additional stents were implanted in two cases, one of which required additional implantation because of a rupture in the middle of the stent. Caudal stent breakage has been associated with oversizing in the thoracic cavity [24]; However, the breakage site in this case was in the middle section, and the cause unknown. However, the breakage site in this case was in the middle section, and the cause was unknown. It was noticed that the dog was very excitable and displayed constant barking behavior, which may have contributed to the breakage of the stent. In the other case, a 20-mm stent that was 10 mm longer on the rostral side than the collapsed area on the radiographic image was initially selected, but additional stents were later required to be implanted because of tracheal collapse on the anterior and posterior sides of original stent. Although placing the stent directly on the affected site is not advisable if it is prone to inducing inflammatory reactions, a hybrid Fauna Stent can be placed over a wide area along the rostro-caudal axis, since it does not cause inflammation and can follow the movement of the trachea. This is demonstrated by the good results obtained in the remaining cases in which such a course of action was followed. The absence of migration may have been due to the fact that the stent was placed with care and without excessive tension.

Another feature of these stents is that the Nitinol threads that make up each cell have equal angles at the top, bottom, and sides when they hook or cross. This allows external force to be evenly applied to the Nitinol yarns that make up each cell so that they are not concentrated in a localized area of the stent but dispersed instead, thereby reducing the risk of stent fracture. Hybrid Fauna stents also reduce tissue inflammation because they are less resilient to external forces than conventional stents, and provide a lower risk of migration and shortening because they are less elastic in the direction of the long axis.

One of the limitations of this study was that it did not include cases in which stents with cross-braiding alone were placed instead as a control. It is therefore difficult to conclude that the superior results obtained on this study can be attributed to the unconventional stent braiding method of the stents, which has only been suggested. Therefore, it was not possible to evaluate the effect of the stenting procedure on life expectancy or to determine pathology through an autopsy.

This report describes the use of a novel device (the Fauna Stent, a self-expanding stent featuring cross-and-hook braiding) to treat tracheal collapse in dogs. Significant improvement in clinical signs and low postoperative complications were observed, and it may be useful as a device for endotracheal therapy for canine tracheal collapse in the future.

ACKNOWLEDGEMENTS

The authors would like to express their appreciation to all the people who helped us with this study.

REFERENCES

1. Buback JL, Boothe HW, Hobson HP. Surgical treatment of tracheal collapse in dogs: 90 cases (1983-1993). *J Am Vet Med Assoc.* 1996;208(3):380-384.
[PUBMED](#)
2. Johnson LR, Pollard RE. Tracheal collapse and bronchomalacia in dogs: 58 cases (7 /2001-1 /2008). *J Vet Intern Med.* 2010;24(2):298-305.
[PUBMED](#) | [CROSSREF](#)
3. White RA, Williams JM. Tracheal collapse in the dog - is there really a role for surgery? A survey of 100 cases. *J Small Anim Pract.* 1994;35(4):191-196.
[CROSSREF](#)
4. White RN. Unilateral arytenoid lateralisation and extraluminal polypropylene ring prostheses for correction of tracheal collapse in the dog. *J Small Anim Pract.* 1995;36(4):151-158.
[PUBMED](#) | [CROSSREF](#)
5. Payne JD, Mehler SJ, Weisse C. Tracheal collapse. *Compend Contin Educ Pract Vet.* 2006;28:373-382.
6. Weisse C, Berent A, Violette N, McDougall R, Lamb K. Short-, intermediate-, and long-term results for endoluminal stent placement in dogs with tracheal collapse. *J Am Vet Med Assoc.* 2019;254(3):380-392.
[PUBMED](#) | [CROSSREF](#)
7. Tangner AH, Philhobson H. A retrospective study of 20 surgically managed cases of collapsed trachea. *Vet Surg.* 1982;11(4):146-149.
[CROSSREF](#)
8. Raske M, Weisse C, Berent AC, McDougall R, Lamb K. Immediate, short-, and long-term changes in tracheal stent diameter, length, and positioning after placement in dogs with tracheal collapse syndrome. *J Vet Intern Med.* 2018;32(2):782-791.
[PUBMED](#) | [CROSSREF](#)

9. Della Maggiore A. An update on tracheal and airway collapse in dogs. *Vet Clin North Am Small Anim Pract.* 2020;50(2):419-430.
[PUBMED](#) | [CROSSREF](#)
10. Suematsu M, Suematsu H, Minamoto T, Machida N, Hirao D, Fujiki M. Long-term outcomes of 54 dogs with tracheal collapse treated with a continuous extraluminal tracheal prosthesis. *Vet Surg.* 2019;48(5):825-834.
[PUBMED](#) | [CROSSREF](#)
11. Chisnell HK, Pardo AD. Long-term outcome, complications and disease progression in 23 dogs after placement of tracheal ring prostheses for treatment of extrathoracic tracheal collapse. *Vet Surg.* 2015;44(1):103-113.
[PUBMED](#) | [CROSSREF](#)
12. Tinga S, Thieman Mankin KM, Peycke LE, Cohen ND. Comparison of outcome after use of extra-luminal rings and intra-luminal stents for treatment of tracheal collapse in dogs. *Vet Surg.* 2015;44(7):858-865.
[PUBMED](#) | [CROSSREF](#)
13. Becker WM, Beal M, Stanley BJ, Hauptman JG. Survival after surgery for tracheal collapse and the effect of intrathoracic collapse on survival. *Vet Surg.* 2012;41(4):501-506.
[PUBMED](#) | [CROSSREF](#)
14. Durant AM, Sura P, Rohrbach B, Bohling MW. Use of nitinol stents for end-stage tracheal collapse in dogs. *Vet Surg.* 2012;41(7):807-817.
[PUBMED](#) | [CROSSREF](#)
15. Sura PA, Krahwinkel DJ. Self-expanding nitinol stents for the treatment of tracheal collapse in dogs: 12 cases (2001-2004). *J Am Vet Med Assoc.* 2008;232(2):228-236.
[PUBMED](#) | [CROSSREF](#)
16. Mittleman E, Weisse C, Mehler SJ, Lee JA. Fracture of an endoluminal nitinol stent used in the treatment of tracheal collapse in a dog. *J Am Vet Med Assoc.* 2004;225(8):1217-1221.
[PUBMED](#) | [CROSSREF](#)
17. Radlinsky MG, Fossum TW, Walker MA, Aufdemorte TB, Thompson JA. Evaluation of the Palmaz stent in the trachea and mainstem bronchi of normal dogs. *Vet Surg.* 1997;26(2):99-107.
[PUBMED](#) | [CROSSREF](#)
18. Moritz A, Schneider M, Bauer N. Management of advanced tracheal collapse in dogs using intraluminal self-expanding biliary Wallstents. *J Vet Intern Med.* 2004;18(1):31-42.
[PUBMED](#) | [CROSSREF](#)
19. Clarke DL. Interventional radiology management of tracheal and bronchial collapse. *Vet Clin North Am Small Anim Pract.* 2018;48(5):765-779.
[PUBMED](#) | [CROSSREF](#)
20. Congiusta M, Weisse C, Berent AC, Tozier E. Comparison of short-, intermediate-, and long-term results between dogs with tracheal collapse that underwent multimodal medical management alone and those that underwent tracheal endoluminal stent placement. *J Am Vet Med Assoc.* 2021;258(3):279-289.
[PUBMED](#) | [CROSSREF](#)
21. Hong JB, Kang DH, Nam HS, Choi CW, Kim HW, Park SB, et al. Endoscopic reintervention for stent malfunction after stent-in-stent deployment for malignant hilar obstruction. *Medicine (Baltimore).* 2017;96(48):e8867.
[PUBMED](#) | [CROSSREF](#)
22. Kaino S, Sen-Yo M, Shinoda S, Kawano M, Harima H, Suenaga S, et al. Side-by-side placement of bilateral endoscopic metal stents for the treatment of postoperative biliary stricture. *Clin J Gastroenterol.* 2017;10(1):68-72.
[PUBMED](#) | [CROSSREF](#)
23. Yoon HY, Choi JW, Kim Ji H, Kim Jung H. Use of a double-wire woven uncovered nitinol stent for the treatment of refractory tracheal collapse in a dog: a case report. *Vet Med.* 2017;62(2):98-104.
[CROSSREF](#)
24. Violette NP, Weisse C, Berent AC, Lamb KE. Correlations among tracheal dimensions, tracheal stent dimensions, and major complications after endoluminal stenting of tracheal collapse syndrome in dogs. *J Vet Intern Med.* 2019;33(5):2209-2216.
[PUBMED](#) | [CROSSREF](#)