

Ventricular fibrillation after ablation of a benign arrhythmia. Angry Purkinje syndrome?



Sami Viskin, MD, Arie Lorin Schwartz, MD, Yuval Levi, PE, Aviram Hochstadt, MD, Raphael Rosso, MD

From Tel Aviv Sourasky Medical Center and Sackler School of Medicine, Tel Aviv University, Tel Aviv, Israel.

Introduction

Sudden death from apparently benign ventricular arrhythmias is a nightmare for the treating cardiologist.¹ We present a case in which a patient walked into the catheterization laboratory for an elective ablation procedure that was successful, only to develop cardiac arrest not once, but twice, within the next 48 hours.

Case report

A 52-year-old man with known coronary artery disease was referred for an exercise test as part of his routine follow-up. Surprisingly, the baseline electrocardiogram (ECG) revealed a stable wide QRS tachycardia of 190 beats/min (Figure 1A). The patient recalled having chest discomfort overnight but was asymptomatic at the time. Intravenous amiodarone, infused on-site by ambulance personnel, slowed the ventricular rate to 144 beats/min and the patient was transferred to our hospital. On arrival, we suspected a verapamil-sensitive fascicular ventricular tachycardia (VT)^{2,3} and administered 5 mg of intravenous verapamil. This led to immediate tachycardia termination. The post-conversion ECG (Figure 1B) and echocardiogram were normal. The patient was observed with continuous ECG monitoring for 2 days, was eventually discharged on beta-blocker therapy, and was scheduled for a radiofrequency (RF) ablation procedure.

The patient remained asymptomatic for 3 additional weeks and was then electively readmitted for VT ablation. During the electrophysiologic study, a multielectrode catheter was introduced in the left ventricle through a retrograde transaortic approach and positioned along the interventricular septum. Purkinje potentials we recorded in sinus rhythm at the septal wall of the left ventricle septum (Supplemental Figure S1) and tagged on the CARTO mapping system (Bio-

KEY TEACHING POINTS

- Malignant ventricular arrhythmias may rarely occur after ablation of relatively benign ventricular arrhythmias.
- Injury to Purkinje fibers, or to the myocardial tissue surrounding them, may trigger short-coupled ventricular extrasystoles that may trigger ventricular fibrillation.
- Observation with continuous electrocardiographic monitoring is therefore warranted after ablation of ventricular arrhythmias.

sense Webster, Diamond Bar, CA). No supraventricular arrhythmias were inducible. As expected, a fascicular VT with ventriculoatrial dissociation and similar QRS morphology to that of the clinical arrhythmia was reproducibly induced by rapid ventricular pacing. The VT could not be entrained with rapid atrial pacing owing to physiologic atrioventricular (AV) block at the required pacing rate. Diastolic potentials (P1) were recorded at the mid-distal septum along with presystolic Purkinje (P2) potentials that now appeared in reverse sequence (from distal to proximal; Supplemental Figure S1). These electrograms were also tagged on the CARTO mapping system. RF ablation with an irrigated ablation catheter (up to 30 W, 30 mL/min) was performed during VT at the turnaround point junction of the P2-P1 potentials and in sinus rhythm at the P1 tagged points more proximal along the left ventricle septum. RF ablation at the more basal portion of the left ventricle septum targeting the P1 area resulted in left posterior fascicular block. The total number of RF applications was 10, with a total RF time of 15 minutes.

At this point, the VT could no longer be induced. Intracardiac echocardiography imaging revealed the appearance moderate pericardial effusion. Percutaneous drainage of 400 cc of bloody fluid from the pericardial space was performed prior to any hemodynamic compromise.

Two hours after the ablation procedure, the patient developed ventricular extrasystoles with very short coupling

KEYWORDS Cardiac arrest; Polymorphic ventricular tachycardia; Purkinje fibers; Quinidine; Ventricular fibrillation
(Heart Rhythm Case Reports 2020;6:937–941)

Funding Sources: None. Conflict of Interest Disclosures: None. **Address reprint requests and correspondence:** Dr Sami Viskin, Department of Cardiology, Tel Aviv Sourasky Medical Center, Weizman 6, Tel Aviv 64239, Israel. E-mail address: samiviskin@gmail.com.

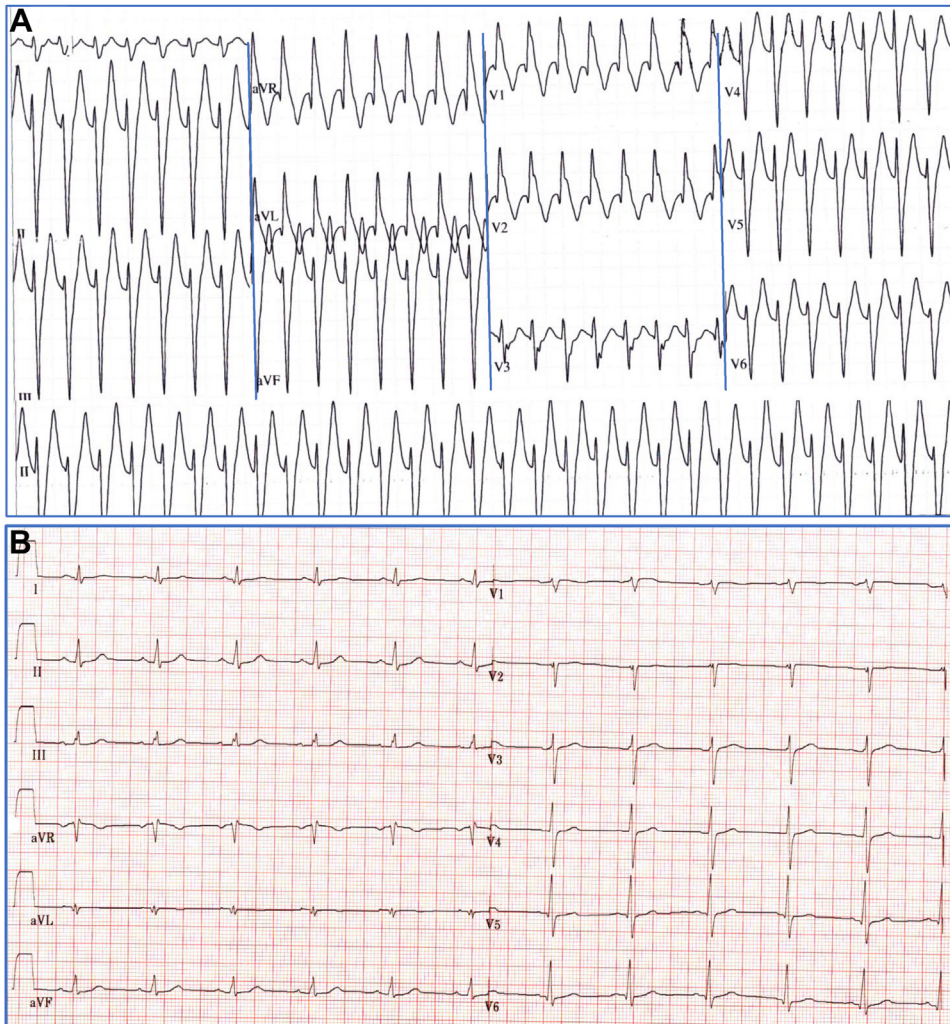


Figure 1 **A:** Sustained ventricular tachycardia (VT), 190 beats/min, detected incidentally prior to a scheduled exercise test. The VT slowed with intravenous amiodarone (not shown). The QRS pattern (right bundle branch morphology with superior axis) and the relatively narrow complexes suggested the diagnosis of verapamil-sensitive fascicular VT.^{2,3} **B:** Intravenous verapamil restored sinus rhythm with normal QRS morphology.

interval (Figure 2A). One hour later, without warning symptoms, the patient had a witnessed cardiac arrest with ventricular fibrillation (VF) requiring DC defibrillation. The culprit arrhythmia was a polymorphic VT triggered by relatively narrow ectopic beats with very short coupling interval (320 ms) (Figure 2B). At the end of the short resuscitation process the patient was fully conscious and hemodynamically stable. A bedside echocardiogram revealed normal left ventricular systolic function and no pericardial fluid. On the other hand, the ECG showed sinus rhythm with right bundle branch block and ectopic ventricular bigeminy with very short coupling interval (Figure 2C). Fearing the possibility of an arrhythmic storm of polymorphic VT,⁴ we started quinidine therapy.^{5,6} Intravenous quinidine gluconate (Quinidine Gluconate Injection; Lilly, Indianapolis, IN) at a rate of 15 mg/min led to immediate (within minutes) suppression of all ventricular ectopic activity; the infusion rate was then reduced by 50% every 15 minutes until a final dose of 2 mg/min was achieved and maintained, for a

total dose of 800 mg intravenous quinidine gluconate over 4 hours. This was followed by oral hydroquinidine (Serecor; Sanofi, Paris, France) at a dose of 300 mg every 6 hours.

The patient remained stable and asymptomatic for 24 hours. In addition to quinidine, he was receiving bisoprolol, ramipril, atorvastatin, aspirin, and colchicine. After 24 hours of quinidine therapy, he suddenly complained of nausea and had a burst of diarrhea. Immediately thereafter, the patient lost consciousness (while still in sinus rhythm) and then developed asystolic cardiac arrest (Figure 3A). He underwent a prolonged resuscitation that included intravenous atropine (total 2 mg) and epinephrine (total 2 mg). Once return of spontaneous circulation was achieved, a high-degree AV block with left bundle branch block QRS complexes was recorded (Figure 3B), prompting urgent insertion of a transvenous temporary ventricular electrode for ventricular pacing. In addition, suspecting excessive sodium channel blockade from quinidine toxicity, we administered intravenous bicarbonate (2 intravenous bolus injections of 8.4 g

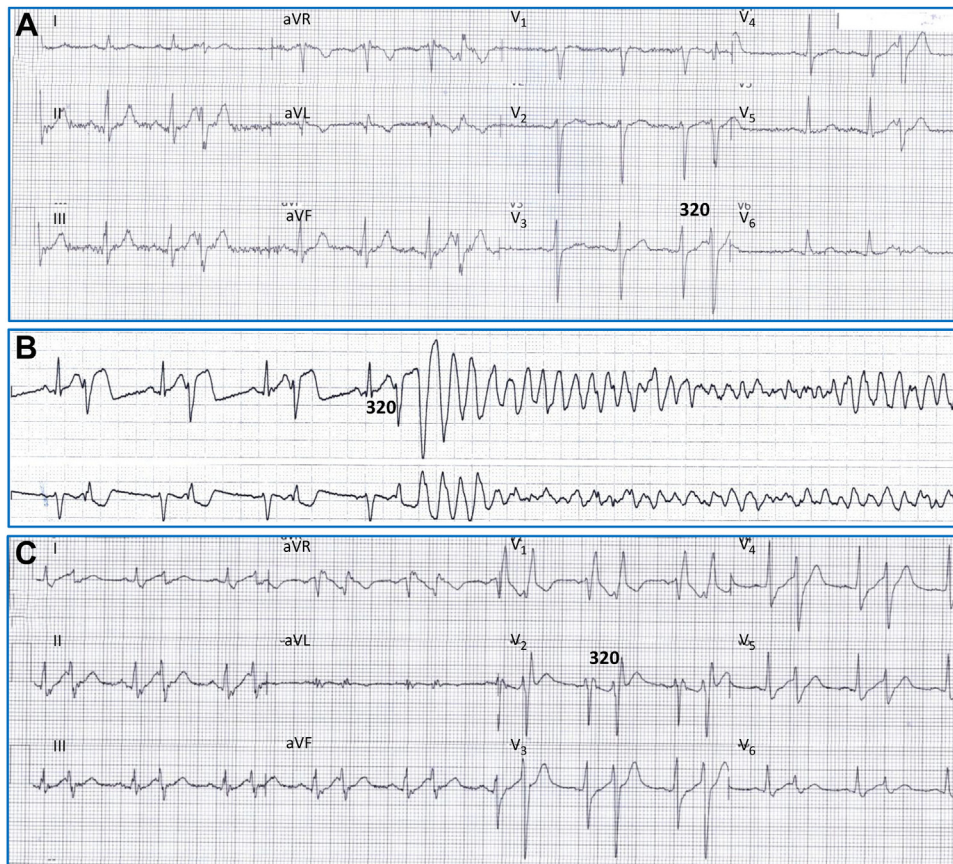

Figure 2 A: Electrocardiogram recorded 2 hours after the ablation procedure in the absence of symptoms. Note the ventricular extrasystoles with right bundle branch block (RBBB)-like morphology, leftward axis, yet fairly narrow QRS complexes (best appreciated at leads V₁-V₂). The extrasystoles have a very short coupling interval (320 ms). These characteristics indicate that the ectopic beats originate from Purkinje fibers located in the area of ablation within the left posterior fascicle. B: One hour later, polymorphic ventricular tachycardia deteriorating to ventricular fibrillation is triggered by a ventricular extrasystole with short coupling interval. C: After defibrillation there is sinus rhythm with RBBB and ventricular bigeminy with coupling interval of 320 ms. Intravenous quinidine was started at this point.

sodium bicarbonate). This led to normalization of the ECG (Figure 3C). Quinidine was discontinued. Cardiac catheterization revealed a chronically occluded right coronary artery (known from a previous catheterization) with otherwise patent coronary arteries.

The patient remained stable for additional 24 hours but then developed, once more, frequent ventricular extrasystoles with ultra-short coupling interval (Supplemental Figure S2). Oral hydroquinidine was reinitiated, this time at a lower dose (oral hydroquinidine 300 mg every 8 hours). A dual-chamber defibrillator was implanted and the patient was discharged on hydroquinidine. One month later, hydroquinidine was discontinued. The patient remains asymptomatic and free of arrhythmias 6 months later. No short-coupled ventricular extrasystoles have been observed in repeated Holter recordings.

Discussion

Our patient presented with a well-tolerated fascicular VT and then remained free of symptoms for 3 weeks, only to develop recurrent cardiac arrest after a successful RF ablation. This sequence of events strongly suggests that both events of in-hospital cardiac arrest were iatrogenic. Specifically, the VF

event probably resulted from proarrhythmic effects of the RF ablation, whereas the bradysystolic arrest was probably caused by quinidine.

Polymorphic VT caused by short-coupled ventricular extrasystoles, in patients with coronary disease without evident myocardial ischemia, usually originates from Purkinje fibers located within areas of recent myocardial injury.⁴ We therefore speculate that the RF lesions made along the peripheral conduction system within the interventricular septum caused injury to some Purkinje fibers, provoking short-coupled ventricular extrasystoles within the relative ventricular refractory period, thus triggering VF. Alternatively, the RF lesions may have led to small areas of myocardial necrosis where Purkinje fibers remained vital. This would be akin to surviving Purkinje fibers within areas of myocardial scar in experimental myocardial infarction.⁷ Once the electrotonic (suppressive) effects of the surrounding myocardium ceased, early phase 2 afterdepolarizations (ubiquitous in Purkinje fibers)⁸ could have propagated with unidirectional block and reentry within the Purkinje-myocardial junctions, causing very fast arrhythmias.^{5,6}

The mechanism of the bradysystolic cardiac arrest is intriguing. In the absence of reaccumulation of pericardial

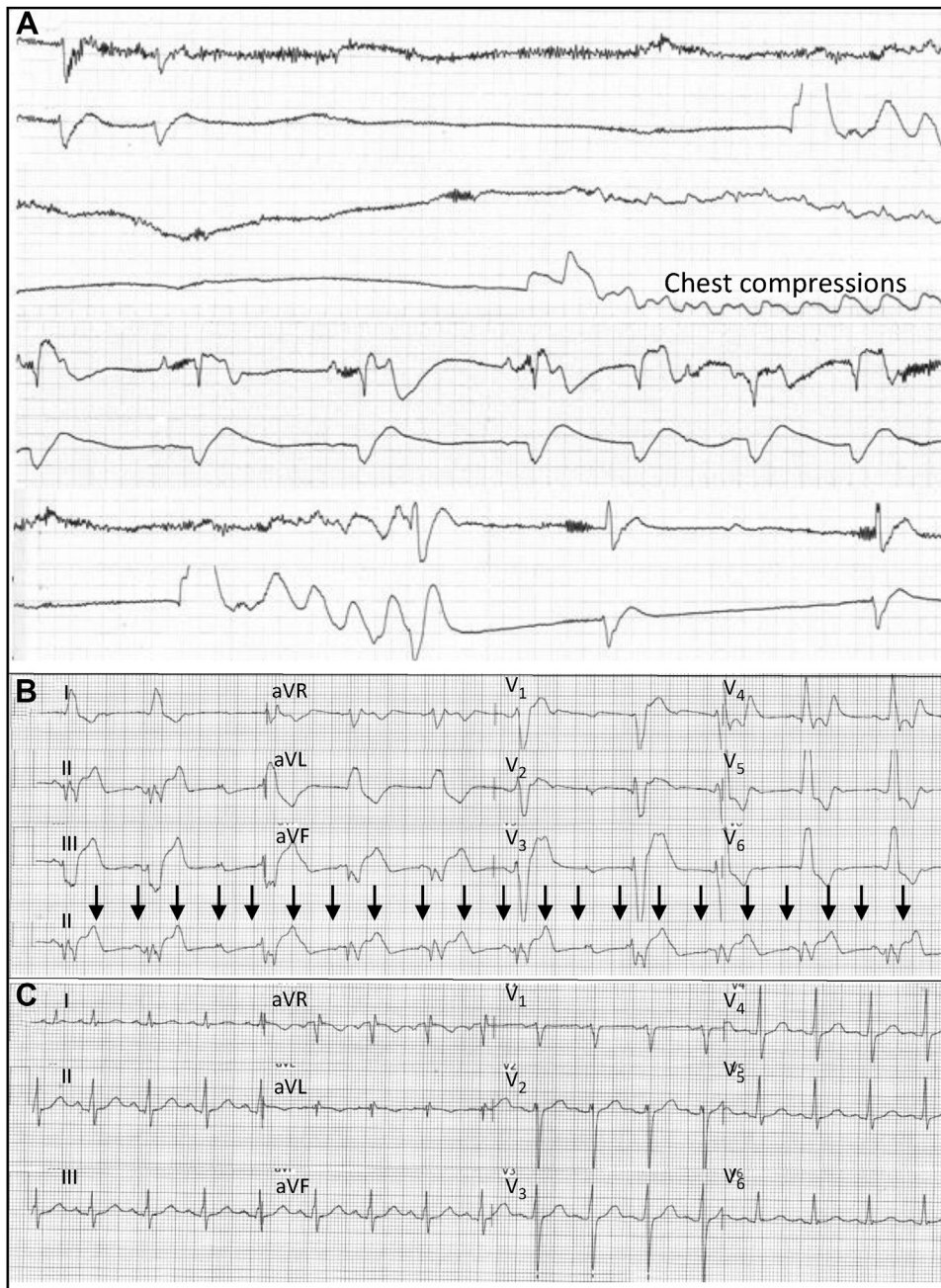


Figure 3 A: Bradyasystolic cardiac arrest that ensued after 24 hours of quinidine therapy. Asystole is followed by a slow escape rhythm with very wide QRS. B: After resuscitation with chest compressions, epinephrine, and atropine, there is sinus rhythm with complete atrioventricular block (arrows show the P waves) with an escape rhythm with left bundle branch block pattern with very wide QRS. C: Sodium bicarbonate, injected intravenously at this point, led to immediate restoration of atrioventricular conduction with narrow QRS.

fluid or new coronary stenosis on repeated angiography, a toxic effect of quinidine is the most likely cause. Furthermore, the immediate reversal of AV block with wide QRS by intravenous injection of sodium^{9,10} (in the form of sodium bicarbonate) argues in favor of quinidine poisoning of the sodium channel as the cause of the bradyasystolic arrest. However, there was no gradual QRS widening noticeable prior to the asystolic event. In fact, the patient was asymptomatic and hemodynamically stable until he developed an otherwise typical vagal syncope that progressed to asystole, requiring prolonged resuscitation. It is tempting to speculate

that the vagal episode produced *accentuated antagonism*, leading to a strong reduction of sympathetic activity. Sympathetic activity increases both sodium and calcium channel current, so the vagal-mediated increase in cGMP would reduce both sodium and calcium current, which in the presence of a high level of quinidine could cause asystole and conduction impairment. To our knowledge, the effects of quinidine on the I_f “funny channel” have not been systematically studied.¹¹ However, hydroxychloroquine (of similar structure to quinidine) does reduce the sinus rate by modulating the hyperpolarization-activated I_f current¹² and

it is therefore possible that quinidine has I_f -blocking properties that could have contributed to the sinus arrest. Finally, once vagal-mediated bradycardia ensued, quinidine could have affected the phase 4 depolarization of Purkinje fibers, preventing the appearance of escape rhythms, thus perpetuating asystole.^{13,14}

VF after ablation of benign arrhythmias is a rare phenomenon. We could find only 1 report, from almost 2 decades ago,¹⁵ describing recurrent polymorphic VT and VF that started 6 hours after ablation of a benign idiopathic VT from the right ventricular outflow. Based on the single-lead recording presented, the polymorphic VT appeared to originate from the zone of ablation and had a coupling interval shorter than 400 ms.¹⁵

It is possible that arrhythmogenic ablation lesions are also under-reported. Until the rarity of this “angry Purkinje” phenomenon is better defined, a close ECG-monitor watch for short-coupled extrasystoles for 24 hours is warranted.

Acknowledgments

We are indebted to Charles Antzelevitch, from the Lankenau Institute for Medical Research, Philadelphia, PA; Christopher L.-H. Huang, from the Physiological Laboratory, University of Cambridge, United Kingdom; and Ming Lei and Derek Terrar, from the Department of Pharmacology, University of Oxford, United Kingdom, for insightful discussions concerning the arrhythmogenic effects of quinidine.

Appendix

Supplementary data

Supplementary data associated with this article can be found in the online version at <https://doi.org/10.1016/j.hrcr.2020.09.010>.

References

1. Viskin S, Antzelevitch C. The cardiologists' worst nightmare: sudden death from "benign" ventricular arrhythmias. *J Am Coll Cardiol* 2005;46:1295–1297.
2. Belhassen B, Rotmensch HH, Laniado S. Response of recurrent sustained ventricular tachycardia to verapamil. *Br Heart J* 1981;46:679–682.
3. Belhassen B, Shapira I, Pelleg A, Copperman I, Kauli N, Laniado S. Idiopathic recurrent sustained ventricular tachycardia responsive to verapamil: an ECG-electrophysiologic entity. *Am Heart J* 1984;108:1034–1037.
4. Komatsu Y, Hocini M, Nogami A, et al. Catheter ablation of refractory ventricular fibrillation storm after myocardial infarction. *Circulation* 2019;139:2315–2325.
5. Viskin S, Chorin E, Viskin D, et al. Quinidine-responsive polymorphic ventricular tachycardia in patients with coronary heart disease. *Circulation* 2019;139:2304–2314.
6. Viskin S, Hochstadt A, Chorin E, et al. Quinidine-responsive out-of-hospital polymorphic ventricular tachycardia in patients with coronary heart disease. *Europace* 2020;22:265–273.
7. Friedman PL, Stewart JR, Fenoglio JJ Jr, Wit AL. Survival of subendocardial Purkinje fibers after extensive myocardial infarction in dogs. *Circ Res* 1973;33:597–611.
8. Haissaguerre M, Vigmond E, Stuyvers B, Hocini M, Bernus O. Ventricular arrhythmias and the His-Purkinje system. *Nat Rev Cardiol* 2016;13:155–166.
9. Wasserman F, Brodsky L, Dick MM, Kathe JH, Rodensky PL. Successful treatment of quinidine and procaine amide intoxication; report of three cases. *N Engl J Med* 1958;259:797–802.
10. Wasserman F, Brodsky L, Kathe JH, Rodensky PL, Dick MM, Denton PS. The effect of molar sodium lactate in quinidine intoxication. *Am J Cardiol* 1959;3:294–299.
11. Lei M, Wu L, Terrar DA, Huang CL. Modernized classification of cardiac antiarrhythmic drugs. *Circulation* 2018;138:1879–1896.
12. Capel RA, Herring N, Kalla M, et al. Hydroxychloroquine reduces heart rate by modulating the hyperpolarization-activated current I_f : Novel electrophysiological insights and therapeutic potential. *Heart Rhythm* 2015;12:2186–2194.
13. Akhtar M. Drugs acting on the fast inward sodium current in the management of tachycardias. In: Surawicz B, Prattap Reddy C, Prystowsky EN, eds. *Tachycardias*. Boston: Martinus Nijhoff Publishing; 1984:471–481.
14. Roden DM. Antiarrhythmic drugs. In: Brunton L, Knollman B, Hilal-Dandan R, eds. *Goodman and Gilman's The Pharmacological Basis of Therapeutics*, 11th ed. New York: McGrawHill; 2006:899–932.
15. Lacroix D, Kacet S, Lekieffre J. Ventricular fibrillation after successful radiofrequency catheter ablation of idiopathic right ventricular tachycardia. *Am Heart J* 1994;128:1044–1045.