



Contents lists available at ScienceDirect

International Journal of Surgery Case Reports

journal homepage: www.casereports.com

Appendix carcinoid associated with the Peutz-Jeghers syndrome

Sabine Hofmann^{a,*}, Thomas F.E. Barth^b, Marko Kornmann^a, Doris Henne-Bruns^a^a Department of General and Visceral Surgery, University of Ulm, Albert-Einstein-Allee 23, 89081 Ulm, Germany^b Institute of Pathology University of Ulm, Albert-Einstein-Allee 23, 89081 Ulm, Germany

ARTICLE INFO

Article history:

Received 7 May 2013

Received in revised form 9 May 2013

Accepted 25 June 2014

Available online 27 October 2014

Keywords:

Peutz-Jeghers syndrome

Appendix carcinoid

Hamartoma

Intestinal polyposis

ABSTRACT

INTRODUCTION: The Peutz-Jeghers syndrome (PJS) is a rare hereditary, autosomal-dominant disorder.It is characterized by a gastrointestinal polyposis and mucocutaneous melanic spots. It has also been reported as a precondition for malignancies with a life-time-hazard for cancer up to 93%, caused by a germline mutation in the *STK11* gene.**PRESENTATION OF CASE:** A 21-year-old man presented with nausea and abdominal pain. He had a known history of PJS since the age of 13 when he was treated for intussusception due to a hamartomatous polyp. Preoperative diagnostics revealed a second intussusception and an extensive intestinal polyposis. Intraoperative findings confirmed the suspected diagnoses and desvagination was performed. Nearly 50 polyps were removed from the small intestine over several longitudinal sections. As the appendix appeared thickened an appendectomy was performed simultaneously. Histology showed hamartomatous polyps and the incidental finding of a pT1 carcinoid of the appendix. The patient recovered well and needed no further treatment for his carcinoid tumor.**DISCUSSION:** The mechanism of carcinogenesis in PJS still remains debatable, although the genetic disorder underlying the syndrome is known. A predisposition for carcinoid tumors also stays questionable. To our knowledge there is no description of an association between carcinoid tumors of the appendix and PJS to date.**CONCLUSION:** Life-expectancy in patients with PJS is reduced. Causes are the development of malignancies and complications from the polyps such as intussusception. Since there is no treatment possible main focus must be aimed at early recognition of malignancies and the prevention of complications.© 2014 Published by Elsevier Ltd. on behalf of Surgical Associates Ltd. This is an open access article under the CC BY-NC-ND license (<http://creativecommons.org/licenses/by-nc-nd/3.0/>).

1. Introduction

The Peutz-Jeghers syndrome (PJS) is a rare hereditary, autosomal-dominant disorder. It is distinguished by a polyposis of the gastrointestinal tract (GIT) combined with typical mucocutaneous pigmentations. Patients present with multiple melanic spots of a size between 1 and 5 mm and various hues of brown or black.

They occur inter alia, around the mouth, in the buccal mucosa and on the fingertips and toes. Freckling develops in the first decade of life, the melanic spots on the skin tend to fade gradually after puberty.¹ These spots were first described by Hutchinson in 1898 who illustrated twin sisters with the same characteristic oral pigmentations.² The association of skin lesions and polyposis was first shown in a case report by Peutz in 1921 while the first review of the literature and discussion of the syndrome's clinical significance was performed by Jeghers in 1949.^{3,4}

The gastrointestinal polyps vary in size and are often pedunculated. They cause most of the complications such as obstruction

of the small bowel, intussusception and bleeding. They are located throughout the GIT except the esophagus.

A Peutz-Jeghers (PJ) polyp is unique in its frond- or treelike appearance. Histology shows a hamartomatous composition, consisting of elongated, branching crypts lined by normal epithelial cells with a core of characteristic interlaced smooth muscle bands, causing a distorted architecture.^{1,5–7} Pseudoinvasion may occur when epithelial elements are located in the gut layers adjoining the polyp.⁵

Genetic analysis revealed a germline mutation in the serine-threonine kinase *STK11*. The affected gene is located on chromosome 19p13.3.⁸ Current theory suggests it is caused by a tumor-suppressor-gene, as loss of the gene leads to a disorder of cell polarity and cellular proliferation.⁹ In the majority of patients with PJS family history is positive, but 10–20% have no other cases of PJS in their family.

Compared to standard population a highly increased lifetime-hazard for malignancies has been reported.¹⁰ Most of the cancers concern the GIT, followed by tumors of the breast, ovaries, cervix, lungs, pancreas, uterus and testes.

To our knowledge only one case of carcinoid-tumor in PJ patients has been described in the literature so far. This 16 year old patient

* Corresponding author. Tel.: +49 731 500 53500; fax: +49 731 500 53503.
E-mail address: sabine@hofmann.net (S. Hofmann).

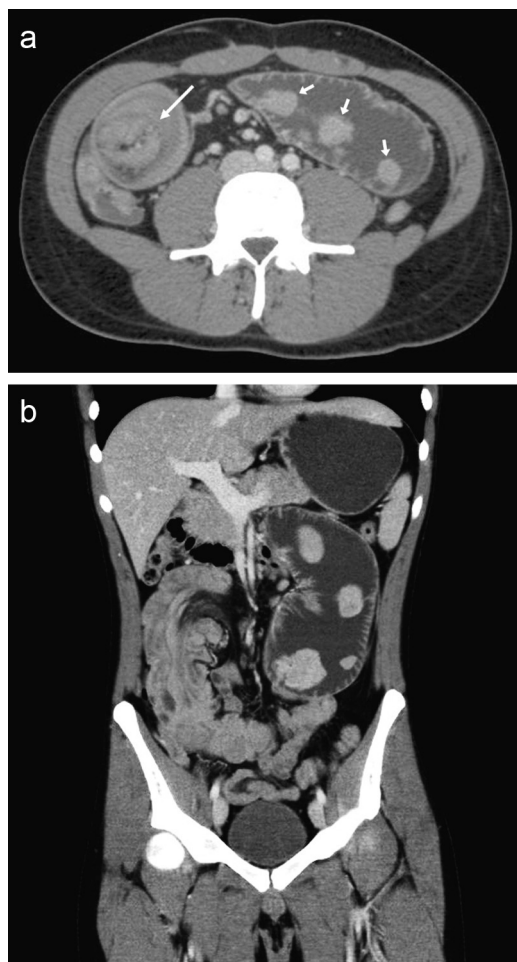


Fig. 1. CT scan of the abdomen showing an ileus due to intussusception in the right lower quadrant (large arrow) and several large polyps in the intestine (small arrows). (a) Coronal slice. (b) Axial slice.

presented with a rectal carcinoid tumor as reported in by Wada et al.¹¹ No case of a coincidental PJS and a carcinoid tumor of the appendix has been mentioned to date.

2. Case report

A 21-year-old man was admitted to hospital with acute onset of abdominal cramps and nausea.

He was suffering from PJS, first diagnosed in 2003 when he had an occurrence of intussusception due to a 3 cm, pedunculated polyp of the small intestine. He underwent surgery with subsequent partial resection of the jejunum containing the polyp. The diagnosis was confirmed by histology showing hamartomatous polyps. Since then he suffered from recurring polyps throughout the GIT, which were regularly removed by endoscopy. He also had a mild iron-deficiency anemia due to recurrent bleeding from the polyps. There was no history of skin alterations, polyposis or GI diseases in his family.

Noticeable on physical examination were perioral lentigines and hyperpigmentations on feet and fingertips. The abdomen showed tenderness with maximum pain on pressure in the upper and middle abdomen. Ultrasonography suspected an ileus due to intussusception and showed several polyps up to 3 cm. The subsequent CT scan reinforced the tentative diagnosis, demonstrating an intussusception of the small intestine in the right lower quadrant (Fig. 1).

An emergency laparotomy was performed and intraoperative findings confirmed the suspected diagnosis (Fig. 2). Therefore

desvagination of the jejunum was accomplished. Therefore the invaginated jejunal segment was pulled out of the distal segment, accomplishing an open desvagination. No intestine had to be resected this time as it was viable and perfusion was unimpaired. The cause of the invagination was, as suspected, a large pedunculated polyp. Over several longitudinal sections about 35 polyps of different sizes were resected from the small intestine. As the appendix appeared thickened a simultaneous appendectomy was performed.

Histologic findings were hamartomatous polyps with a diameter up to 5.1 cm. They possessed the typical PJ-appearance accompanied by a chronic inflammatory response with the beginning hemorrhagic infarction.

The appendix showed, besides a small hamartomatous polyp (Fig. 3a), the incidental finding of a 1 cm long carcinoid tumor (Fig. 3b). The tumor infiltrated the smooth muscle layers, reaching the serosa without serosal penetration. The carcinoid cells were immunohistochemically positive for chromogranin and synaptophysin. An invasion of blood-vessels was excluded by additional CD34 stainings. With the MIB1-antibody a proliferation index well below 1% was demonstrated. According to the TNM staging system this tumor was classified as a well differentiated neuroendocrine tumor (appendix carcinoid): pT1a, L0, V0, Nx, M0, R0, tumorgrading G1 (Fig. 4).

After a week's uneventful hospital stay the patient was discharged from hospital in a good general condition. As the appendix carcinoid was an early stage tumor, no further treatment is required. However, the patient will need regular endoscopy and tumor-aftercare in the outpatient clinic.

3. Discussion

PJS is a known to be precancerous. Life-time-hazard for cancer amounts up to 93%.¹⁰ Mainly these tumors affect the GIT, but there are also less commonly carcinomas of extraintestinal tissues.¹² Tumors other than cancers have been described, like lymphomas and sex-cord-tumors.^{13,14}

Our patient was found to have a carcinoid of the appendix as an incidental finding on laparotomy. To our knowledge there is only one case report showing a carcinoid tumor of the rectum in a PJ patient and none showing appendiceal or other carcinoids.¹¹ As there have been numerous case reports since the 1920s a predisposition for carcinoid tumors stays questionable.

Although the genetic disorder underlying the syndrome is known, the mechanism of carcinogenesis in PJS still remains debatable.^{8,13,14}

Some authors have suggested a hamartoma-adenoma-carcinoma sequence for the GI cancers.^{15–19} Other authors stated that PJ-polyps are non-neoplastic and therefore have no potential for malignancy.²⁰ It has been proposed that the polyp's origin is a mucosal prolapse due to stromal proliferation without tumorigenesis. Moreover, although adenomatous and even malignant foci have been found in the polyps these are rare events.^{13,14}

In addition, the coexistent pigmentations have no malignant potential whatsoever, and non-GI tumors in PJS do not develop in association with hamartomas.¹⁷

One line of argument considers a side by side occurrence of malignant tumors, hamartomas and hyperpigmentations all caused by the known germline mutation in the STK11 gene, that is ubiquitously expressed. A probable explanation was given by Buck et al.⁵ Considering the great number of polyps in the GIT the rate of malignancies arising in the polyps is low. Therefore, as adenocarcinomas can occur in any glandular epithelium, this may eventually occur in the epithelium covering the polyps.

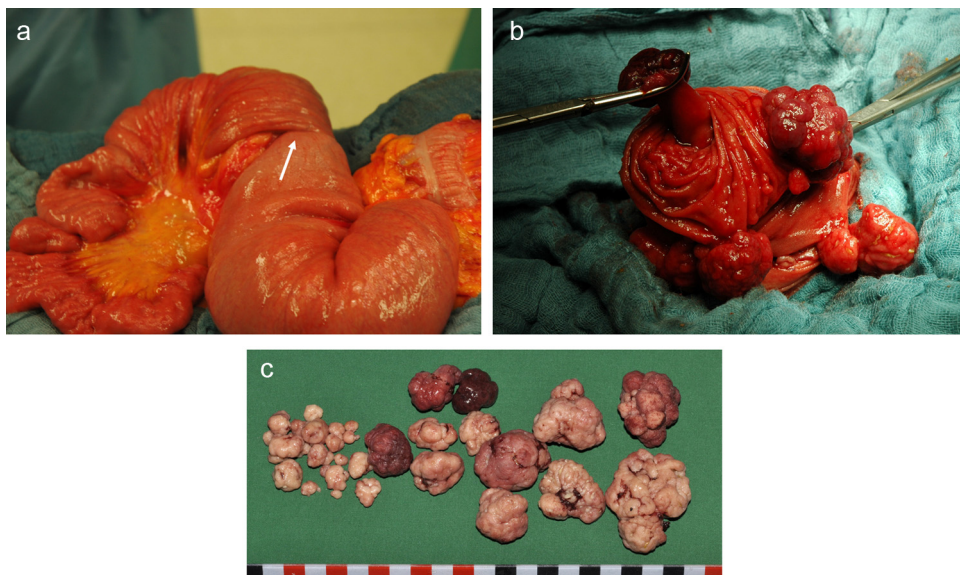


Fig. 2. Intraoperative findings. (a) Intussusception of the ileum (large arrow). (b) Pedunculated polyps in the small intestine. (c) Resected polyps of different sizes.

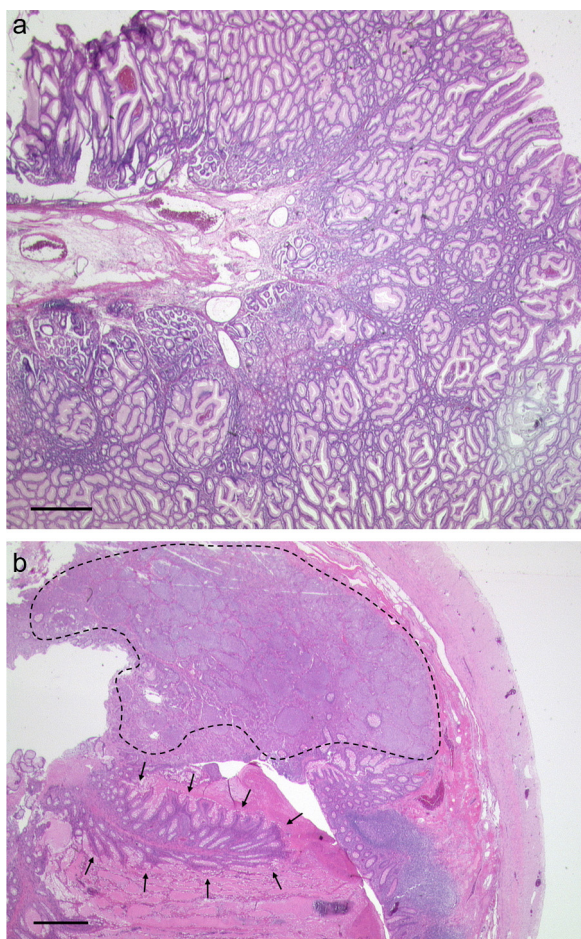


Fig. 3. Histology (hematoxylin-eosin staining; bar = 200 μ m). (a) Section of one of the resected hamartomatous polyps with typical stromal and epithelial branching. The epithelial cells are highly differentiated with no intraepithelial neoplasia. (b) Transverse section of the appendix shows a hamartomatous polyp of the appendix mucosa (arrows) and the co-existing neuroendocrine tumor with deep infiltration of submucosal layer (dashed line).

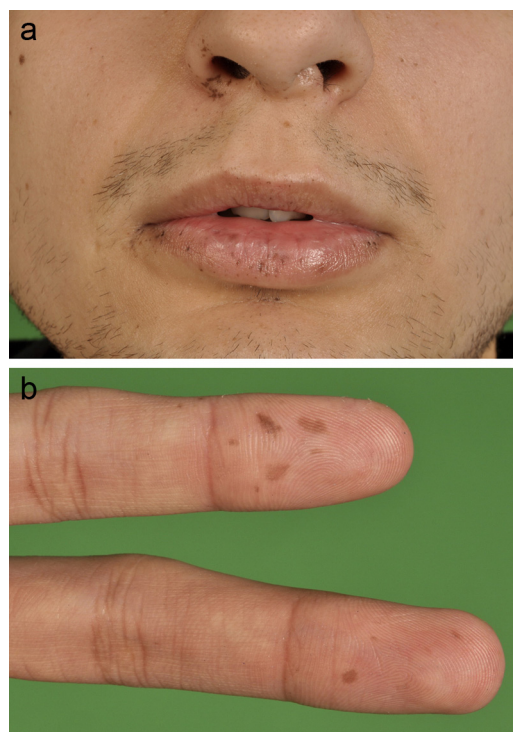


Fig. 4. Hyperpigmentations, located perioral, perinasal and on the fingertips of our patient (selection).

What also remains unclear is the exact role of *STK11* in the carcinogenesis-pathway and in the pathogenesis of polyps.^{13,14} In general it functions as a tumor suppressor gene responsible for cell-polarity, but so far it is unknown what particular steps are regulated by *STK11*. A role as a gatekeeper at the earliest step of the tumors' pathogenesis has been discussed.¹⁷

Another noticeable aspect of this genetic disorder is the age of onset. As known from hereditary precanceroses the average age is lower than in the normal population and is becoming lower with every passing generation. This might be fueled by the loss of *STK11* as a tumor suppressor gene with an accelerated carcinogenesis in these individuals.

4. Conclusion

Recent publications demonstrated that life-expectancy in PJ patients is reduced.^{13,14} Causes are the development of malignancies and complications from the polyps such as intussusception. Since to date there is no treatment the main focus must be aimed at frequent checkups for early recognition of malignancies in these young patients and the prevention of complications. Surveillance is difficult, due to the varieties of possible tumor localisations,^{13,14} but surveillance-protocols may help as suggested by several authors.^{1,6}

Regular endoscopic and on occasion operative procedures are needed for early detection of GI cancers and prevention of polyp-associated complications.

Conflict of interest

The authors declare, that there is no conflict of interest.

Funding

None.

Ethical approval

None.

Author contributions

Sabine Hofmann was involved in data collection and writing. Marko Kornmann contributed greatly towards the case-idea and design. Thomas Barth was involved in writing and pathological works. Doris Henne-Bruns was involved in paper design.

Consent

Written informed consent was obtained from the patient for publication of this case report and accompanying images. A copy of the written consent is available for review by the Editor-in-Chief of this journal on request.

References

- Choi HS, Park YJ, Park J-G. Peutz-Jeghers syndrome: a new understanding. *J Korean Med Sci* 1999;**14**:2–7.
- Hutchinson J. Pigmentation of lips and mouth. *Arch Surg* 1896;**7**:290.
- Peutz JLA. Very remarkable case of familial polyposis of mucous membrane of intestinal tract and nasopharynx accompanied by peculiar pigmentations of skin and mucous membrane. *Ned Maandschr Geneesk* 1921;**10**:134–46.
- Jeghers H, McKusick VA, Katz KH. Generalized intestinal polyposis and melanin spots of the oral mucosa, lips and digits. *N Engl J Med* 1949;**241**:993–1005.
- Buck JL, Harned RK, Lichtenstein JE, Sobin LH. Peutz-Jeghers syndrome. *Radiographics* 1992;**12**:365–78.
- Tomlinson IPM, Houlston RS. Peutz-Jeghers syndrome. *J Med Genet* 1997;**34**:1007–11.
- Georgescu EF, Stanescu L, Simionescu C, Georgescu I, Ionescu R, Florescu G. Peutz-Jeghers syndrome: case report and literature review. *Rom J Morphol Embryol* 2008;**49**(2):241245.
- Beggs AD, Latchford AR, Vasen HFA, Moslein G, Alonso A, Aretz S, et al. Peutz-Jeghers syndrome: a systematic review and recommendations for management. *Gut* 2010;**59**:975–86.
- Kopacova M, Tacheci I, Rejchrt S, Bures J. Peutz-Jeghers syndrome: diagnostic and therapeutic approach. *World J Gastroenterol* 2009;**15**(43):5397–408.
- Giardello FM, Brensinger JD, Tersmette AC, Goodman SN, Petersen GM, Booker SV. Very high risk of cancer in familial Peutz-Jeghers syndrome. *Gastroenterology* 2000;**119**(6):1447–53.
- Wada K, Asoh T, Imamura T, Wada K, Tanaka N, Yamaguchi K, et al. Rectal carcinoid tumor associated with the Peutz-Jeghers syndrome. *J Gastroenterol* 1998;**33**:743–6.
- Hearle N, Schumacher V, Menko FH, Olschwang S, Boardman LA, Gille JJ, et al. Frequency and spectrum of cancers in the Peutz-Jeghers syndrome. *Clin Cancer Res* 2006;**12**(10):3209–15.
- Van Lier MG, Wagner A, Mathus-Vliegen EM, Kuipers EJ, Steyerberg EW, van Leerdam ME. High cancer risk in Peutz-Jeghers syndrome: a systematic review and surveillance recommendations. *Am J Gastroenterol* 2010;**105**(6):1258–64.
- Van Lier MG, Westerman AM, Wagner A, Looman CW, Wilson JH, de Rooij FW, et al. High cancer risk and increased mortality in patients with Peutz-Jeghers syndrome. *Gut* 2011;**60**(2):141–7.
- Hizawa K, Iida M, Matsumoto T, Kohroggi N, Yao T, Fujishima M. Neoplastic transformation arising in Peutz-Jeghers polyposis. *Dis Colon Rectum* 1993;**36**(10):953–7.
- Hizawa K, Iida M, Matsumoto T, Kohroggi N, Kinoshita H, Yao T, et al. Cancer in Peutz-Jeghers syndrome. *Cancer* 1993;**72**(9):2777–81.
- Gruber SB, Entius MM, Petersen GM, Laken SJ, Longo PA, Boyer R, et al. Pathogenesis of adenocarcinoma in Peutz-Jeghers syndrome. *Cancer Res* 1998;**58**(23):5267–70.
- Perzin KH, Bridge MF. Adenomatous and carcinomatous changes in hamartomatous polyps of the small intestine (Peutz-Jeghers syndrome): report of a case and review of the literature. *Cancer* 1982;**49**(5):971–83.
- Bosman FT. The hamartoma-adenoma-carcinoma sequence. *J Pathol* 1999;**188**(1):1–2.
- Jansen M, de Leng WW, Baas AF, Myoshi H, Mathus-Vliegen L, Taketo MM, et al. Mucosal prolapse in the pathogenesis of Peutz-Jeghers polyposis. *Gut* 2006;**55**:1–5.

Open Access

This article is published Open Access at scimedirect.com. It is distributed under the [IJSCR Supplemental terms and conditions](#), which permits unrestricted non commercial use, distribution, and reproduction in any medium, provided the original authors and source are credited.