

# Cardioneural ablation in a patient with spinal cord injury and significant sinus bradycardia



Adi Lador, MD, Miguel Valderrábano, MD, Apoor Patel, MD

*From the Division of Cardiac Electrophysiology, Department of Cardiology, Houston Methodist DeBakey Heart and Vascular Center, Houston Methodist Hospital, Houston, Texas.*

## Introduction

Cervical or high thoracic spinal cord injury (SCI) can cause autonomic dysreflexia with significant bradycardia.<sup>1</sup> The destruction of the descending vasomotor pathways results in the loss of input to the sympathetic neurons and is currently considered the primary factor underlying the lack of sympathetic tone seen after high SCI.<sup>2</sup> Ganglionated plexi (GP) consist of autonomic ganglia on the epicardial surface of the heart. Cardioneural ablation (CNA), ablation of the GP in the atria, has been described as a potential treatment of different arrhythmias that depend on excessive parasympathetic tone, including neurocardiogenic syncope,<sup>3</sup> functional atrioventricular (AV) block,<sup>4</sup> sinus dysfunction,<sup>5</sup> and vagal-related atrial fibrillation.<sup>6</sup> We describe a case of a patient with high SCI with significant bradycardia after his injury. CNA led to a pronounced increase in heart rate, obviating pacemaker implantation.

## Case report

A 73-year-old man with a history of diabetes, hypertension, and anemia presented to the hospital after a traumatic fall. Upon admission, computed tomography showed subluxation of his cervical spine at the C3 and C4 levels. The patient was unable to move any of his extremities. His cervical injury was graded as ASIA (American Spinal Injury Association) grade A, representing the most severe injury. He underwent emergent neurosurgery. Postoperatively he remained quadriplegic and underwent a tracheostomy and percutaneous endoscopic gastrostomy placement. Although he initially required a norepinephrine drip for blood pressure support, he was eventually stable on oral midodrine. His heart rate from postoperative day (POD) 0–4 ranged from 55 to 82 beats per minute

**KEYWORDS** Cardioneural ablation; Ganglionated plexi; Parasympathetic; Sinus bradycardia; Spinal cord injury  
(Heart Rhythm Case Reports 2021;7:398–402)

Conflict of interest: All authors have no conflicts to declare. Funding: Dr Miguel Valderrábano is funded by NIH/NHLBI grant RO1 HL 115003; and the Charles Burnett III and Lois and Carl David endowments. **Address reprint requests and correspondence:** Dr Adi Lador, Division of Cardiac Electrophysiology, Department of Cardiology, Houston Methodist Hospital, 6550 Fannin St, Suite 1901, Houston, TX 77030. E-mail address: [alador@houstonmethodist.org](mailto:alador@houstonmethodist.org).

## KEY TEACHING POINTS

- Cardioneural ablation, ablation of the ganglionated plexi in the atria, is a potential treatment for a variety of disorders associated with high vagal tone, including neurocardiogenic syncope, functional atrioventricular block, sinus dysfunction, and vagal-related atrial fibrillation.
- Cardioneural ablation can be a potential treatment for a severe bradycardia due to spinal cord injury.
- The most pronounced increase in heart rate was gained after ablating the right atrial septum and the aorta–superior vena cava ganglionated plexi.

(bpm). On POD 5 his heart rate dropped to as low as 30 bpm while awake and never went above 48 bpm. He had junctional bradycardia as well as sinus pauses (Figure 1). Atropine and dobutamine infusions were intermittently given to maintain his heart rate. He was not sedated and not on AV nodal agents during the time of his bradycardia.

The electrophysiology service was consulted for further management of his significant bradycardia. The patient had no symptoms or signs of hypoperfusion from his bradycardia, but owing to the high level and severity of spinal injury it was felt to be unlikely that he would have a significant acute and potentially chronic improvement in his heart rate.

Pacemaker implantation was now discussed with the family, but given that his condition was felt to be attributable to high vagal tone, cardioneural ablation was also offered. After a thorough discussion of the risks and unclear outcome of the procedure, the family opted for catheter ablation.

Owing to ongoing bradycardia, he underwent catheter ablation on POD 8 after his neurosurgery. The patient was placed under general anesthesia. Heparin infusion was administered for an activated clotting time of >300 seconds and transseptal puncture was performed. High-frequency stimulation (HFS; 50 ms, 20 mA output, and 2 ms pulse width; StimLab™ system (Micropace; EP Inc, Santa Ana,

CA) was performed in the left and right atrium and would invariably induce nonsustained atrial fibrillation. Vagal responses in atrial fibrillation were identified but difficult to discern consistently owing to the inherent R-R variability. Positive vagal response was defined as an incremental prolongation of the R-R interval by 50%, transient ventricular asystole, or AV block.<sup>7</sup>

Ablation was performed at sites of clear vagal responses as well as at empiric sites of known GP (Figure 2). The order of ablation was the left superior GP (on the anterior superior portion of the left pulmonary veins), the right anterior GP (RAGP; anterior to the right superior pulmonary vein [PV]), the coronary sinus ostium, the septum of the right atrium, and the aorta–superior vena cava (SVC) GP (Ao-SVC), between the medial SVC and the aortic root, superior to the right pulmonary artery. The left and right inferior GP were not targeted, as there was not a parasympathetic response with HFS and in order to avoid unnecessarily ablate on the posterior wall. The most pronounced increase in heart rate occurred during ablation of the right atrial septum and the Ao-SVC GP.

Post procedure, the patient remained in the hospital until POD 13 and had heart rates in the 50s–70s. The patient was placed on a direct anticoagulant for 1 month and

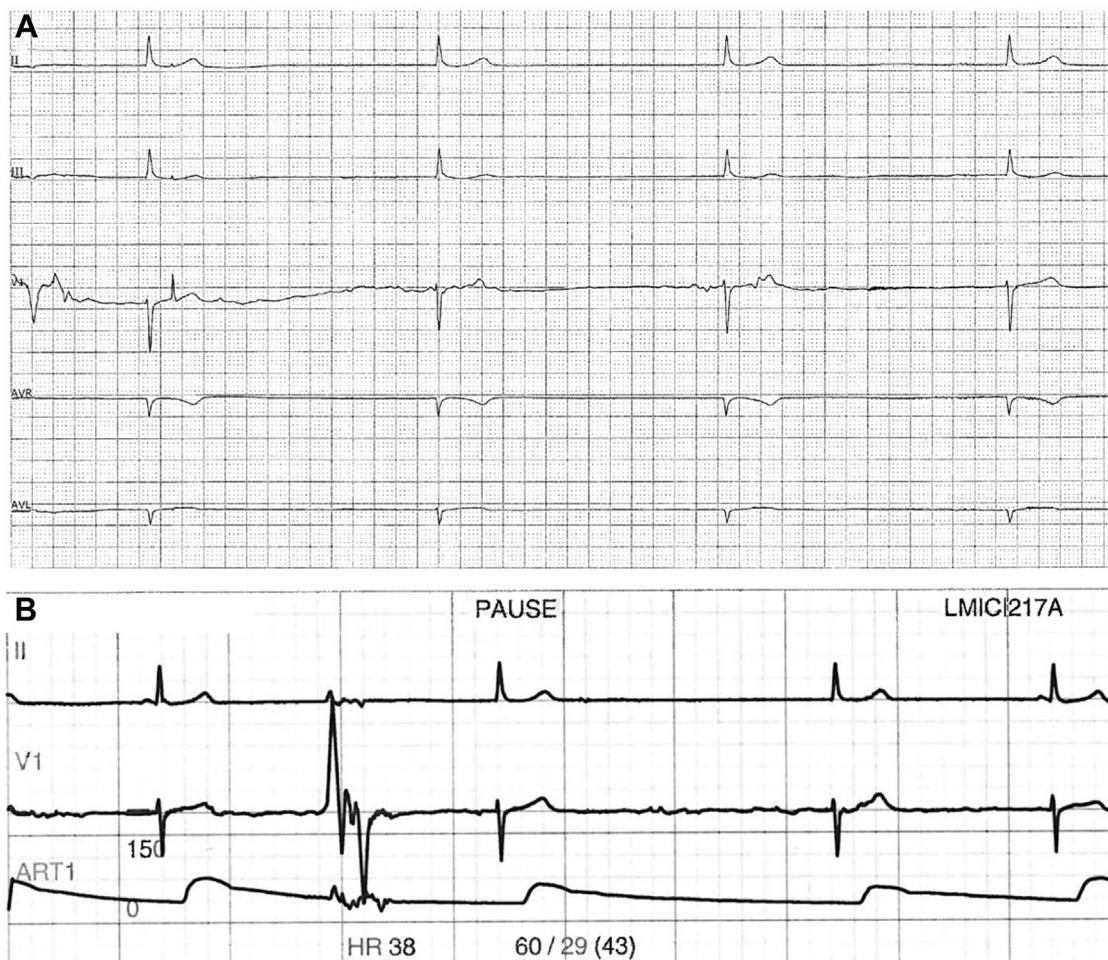
discharged to a rehabilitation facility. He was followed on inpatient telemetry without any bradycardia. Ten months post procedure he wore a 5-day event monitor, which showed that his heart rate variability was below the normal range with a standard deviation of all normal sinus intervals over a 24-hour period (Standard deviation of NN intervals for each 5 minutes segments) of 53.4 ms (Figure 3).

## Discussion

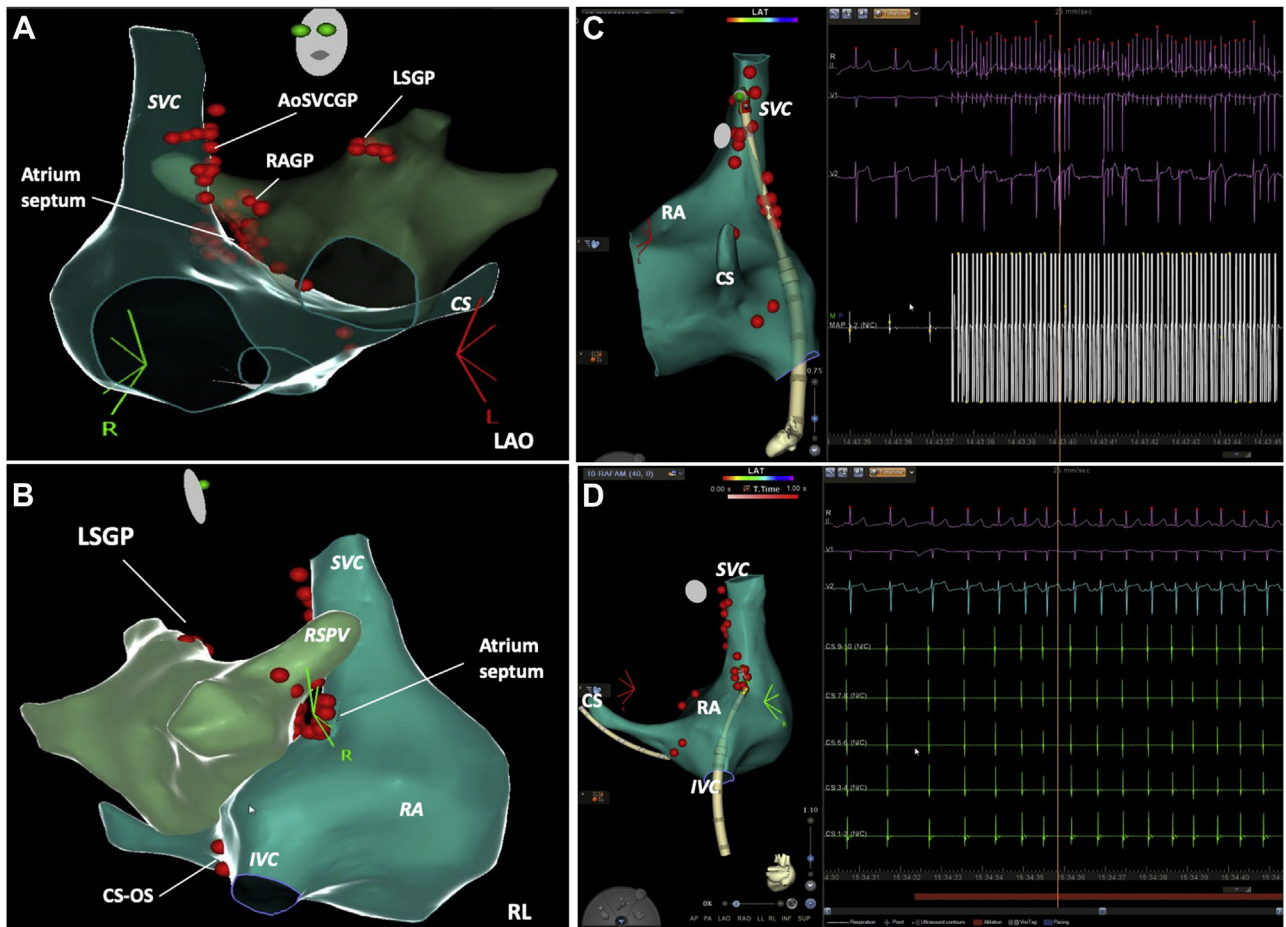
We describe a case of a patient with high SCI resulting in significant bradycardia. CNA was performed with a pronounced increase in heart rate, most pronounced after ablating the right atrial septum and then the Ao-SVC GP.

Individuals with cervical or high thoracic SCI may suffer from life-threatening episodes of autonomic dysreflexia, characterized by extreme hypertension, headache, and bradycardia.<sup>1</sup> The destruction of the descending vasomotor pathways results in the loss of excitatory supraspinal input to the sympathetic preganglionic neurons, and is currently considered the primary factor underlying the lack of sympathetic tone seen after high SCI.<sup>2</sup>

Patients with high injury and ASIA grade A–type injuries demonstrate less improvement in their bradycardia. Early



**Figure 1** Sinus bradycardia and junctional bradycardia prior to the ablation. **A:** Sinus bradycardia with heart rate 27 beats/min. **B:** Junctional bradycardia on telemetry monitoring.



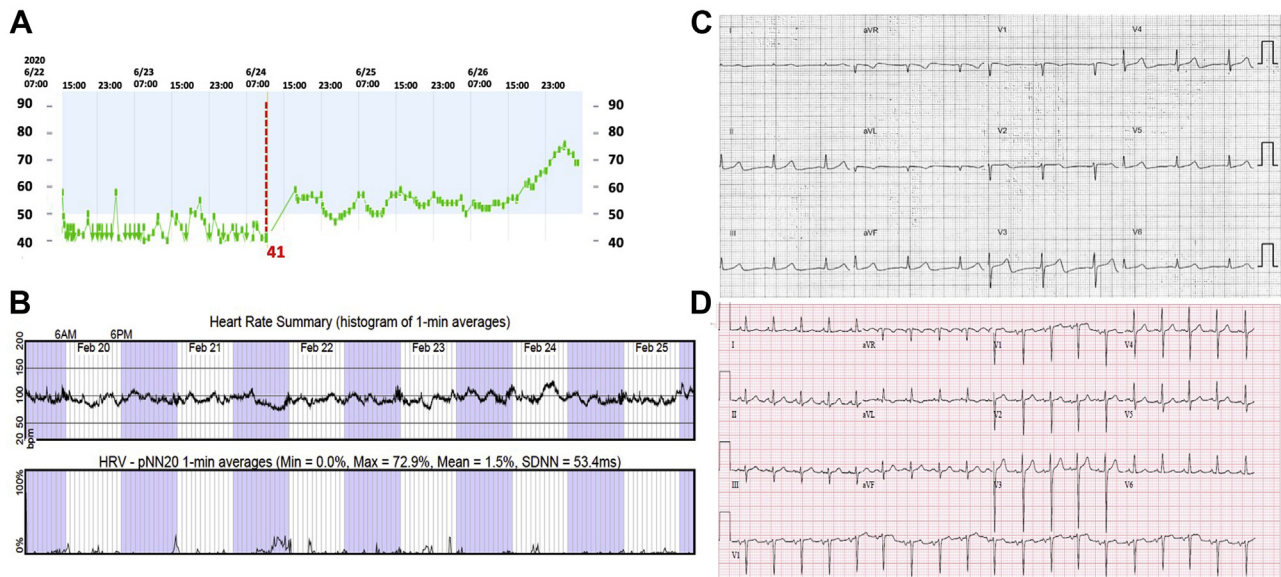
**Figure 2** Electroanatomic maps of both atria displaying the radiofrequency application sites. **A:** Left anterior oblique (LAO) view of right and left atrium showing ablation lesion set. **B:** Posterior view of atria highlighting septal ablation in the right atrium (RA) with proximity to ablation on antrum of right superior pulmonary vein (RSPV). **C:** An example of induction of atrial fibrillation as well as R-R interval prolongation during high-frequency stimulation from the superior vena cava. **D:** An example of pronounced heart rate increase with ablation from the right atrial septum. Ao-SVCGP = aorta–superior vena cava ganglionated plexi; CS = coronary sinus; CS-OS = coronary sinus ostium; IVC = inferior vena cava; LSGP = left superior ganglionated plexi; RAGP = right anterior ganglionated plexi; RL = right lateral; SVC = superior vena cava.

stabilization of the heart rate may facilitate transfer out of the intensive care unit, mobilization, and rehabilitation.<sup>8</sup> Several case series described the use of such medications as aminophylline or theophylline for the prophylaxis of bradycardic events in some patients. Pacemaker therapy should be considered for patients who either fail medical treatment or have severe bradycardia episodes for which medical treatment may not be sufficient.<sup>9</sup> Pacemaker implantation for severe bradycardia in SCI has been reported in 2%–16% of cases. It seems to be more common in patients with injury at high cervical levels (above C5/C6).<sup>8,9</sup> Given the increased propensity for infection in patients after SCI,<sup>9</sup> and the poor prognosis for recovery given his high ASIA grade, we preferred to explore alternatives to pacemaker implantation in our patient.

Sympathetic efferent preganglionic neurons have cell bodies in the spinal cord and project axons onto postganglionic sympathetic neurons, which are organized into the extracardiac–intrathoracic ganglia, including the middle cervical, stellate, paravertebral sympathetic chain (T2–T4), and mediastinal ganglia. Preganglionic efferent neurons of the

parasympathetic system are located within the brain stem and project via the vagus nerve and its branches to postganglionic neurons directly to the heart to form the intrinsic cardiac nervous system. The intrinsic cardiac nervous system itself is organized into GP with efferent and afferent neurons, which relay central signals and form local reflexive circuits to independently regulate regional cardiac responses.<sup>10</sup> The GPs are usually located in epicardial fat pads and form a complex interacting network that regulates heart rate and heart rhythm. This direct innervation of the parasympathetic system onto the epicardial surface of the heart allows modification via catheter ablation.

There is no consensus on the anatomical location and number of GPs.<sup>10–12</sup> Yuan and colleagues<sup>12</sup> defined, in a canine model, 3 main atrial GPs. According to this classification, the sinus node is mainly innervated by the RAGP, whereas innervation of the AV node is provided by the inferior vena cava (IVC)–inferior atrial ganglion (at the junction of the left atrium [LA] and IVC). Apart from these 2 regions, they defined a rich innervation network at the PV–LA junction. Chiou and colleagues<sup>11</sup> found that most efferent vagal



**Figure 3** Change in heart rate post ablation. **A:** Heart rate trend from initial hospitalization. Red dashed line denotes date of ablation with a subsequent increase in heart rate. **B:** Preprocedure electrocardiogram (ECG) showing sinus bradycardia. **C:** Heart rate trend and heart rate variability from heart rate monitor 10 months post procedure, showing a significant increase in heart rate and heart rate variability below the normal range. **D:** ECG 3 months post procedure showing sinus tachycardia.

fibers to the atria travel through the SVC-aorta fat pad, which is located between the medial SVC and the aortic root, superior to the right pulmonary artery, and then project on to the IVC-LA fat pad and the right PV fat pad and both atria.

Various groups in different patient populations investigated the potential therapeutic role of eliminating these structures by endocardial radiofrequency catheter ablation.<sup>11</sup> The technique was attempted first by Pachon and colleagues<sup>3</sup> and termed cardio-neuro ablation. CNA was used for the treatment of neurocardiogenic syncope, functional AV block, sinus dysfunction, and vagal-related atrial fibrillation, especially in young individuals.<sup>3-6,13</sup>

Three different approaches have been used for identification of GPs in atria: HFS, electrogram (EGM) characteristics, and an anatomic approach.<sup>3,14</sup> HFS application causes 2 types of response in atria: (1) a vagal response, which is defined as significant prolongation of the PR or R-R intervals; and (2) a normal response, characterized by the absence of any effect or nonsignificant changes on the PR or R-R intervals. The technique has some limitations, such as inadvertent atrial fibrillation induction and the requirement of general anesthesia.

Operators who target EGMs have identified 2 different patterns of atrial activation using spectral analysis: (1) fibrillar atrial myocardium, which contains extensions of neural fibers between cardiac myocytes and exhibits a highly fragmented, heterogeneous, and right-skewed spectral distribution; and (2) compact atrial myocardium, which works as a single isolated unit, and presents homogeneous and fast conduction with left-skewed frequency distribution. Fibrillar myocardium is targeted via spectral analysis to guide the ablation in combination with empirical anatomical ablation, HFS, or both.<sup>3,5</sup> As spectral analysis involves use of

additional equipment during electrophysiologic study, targeting fractionated EGMs alone has been used in vasovagal CNA to identify GPs.<sup>15</sup> Finally, an empiric anatomic approach has been used as an adjunct to HFS, EGM characteristics, or both, as well as a standalone strategy.

A solely right-sided ablation approach for CNA has been proposed. The RAGP has been reported to mainly control the function of the sinoatrial node. Multiple studies<sup>13,14</sup> performed anatomically guided GP ablation via both atria for the treatment of symptomatic sinus bradycardia and found that RAGP and Ao-SVC GP ablation led to a more significant heart rate increase as compared to left atrial GP ablation. These findings suggest that the RAGP is the final common pathway of sinus node vagal innervation and can be a more valuable CNA target. In our case we also found the most pronounced increase in heart rate after ablating the right atrial septum and the Ao-SVC GP.

Our patient had a high and severe cervical spine injury and had an acute increase in his heart rate post CNA. In 10 months of follow-up he had no episodes of recurrent bradycardia. While we cannot definitively say that his chronic heart rate increase was due to spontaneous recovery, given his ASIA grade I injury (high and severe), his lack of long-term neurologic improvement, and his low heart rate variability, we feel this is unlikely. In deferring a pacemaker, we avoided the long-term complications of device implantation, including the infectious risk associated with immobility.

## Conclusion

We present for the first time CNA in a patient with significant bradycardia as a result of SCI.

While we performed biatrial CNA, the most pronounced increase in heart rate occurred after ablating the right atrial septum and the Ao-SVC GP. Though the long-term effects of CNA in SCI patients are unknown, in patients with high-level and severe SCI that is unlikely to resolve over time, CNA can be considered as an alternative to pacemaker implantation.

## Acknowledgments

We thank Lauren Bjerke (Biosense Webster) for technical assistance with the CARTO images.

## References

- DeVivo MJ, Krause JS, Lammertse DP. Recent trends in mortality and causes of death among persons with spinal cord injury. *Arch Phys Med Rehabil* 1999; 80:1411–1419.
- Furlan JC, Fehlings MG, Shannon P, Norenberg MD, Krassioukov AV. Descending vasomotor pathways in humans: correlation between axonal preservation and cardiovascular dysfunction after spinal cord injury. *J Neurotrauma* 2003;20:1351–1363.
- Pachon JC, Pachon EI, Pachon JC, et al. Cardioneuroablation—new treatment for neurocardiogenic syncope, functional AV block and sinus dysfunction using catheter RF-ablation. *Europace* 2005;7:1–13.
- Pachon MJ, Pachon ME, Lobo TJ, et al. Syncopal high-degree AV block treated with catheter RF ablation without pacemaker implantation. *Pacing Clin Electrophysiol* 2006;29:318–322.
- Aksu T, Golcuk E, Yalin K, Guler TE, Erden I. Simplified cardioneuroablation in the treatment of reflex syncope, functional AV block, and sinus node dysfunction. *Pacing Clin Electrophysiol* 2016;39:42–53.
- Chen PS, Chen LS, Fishbein MC, Lin SF, Nattel S. Role of the autonomic nervous system in atrial fibrillation: pathophysiology and therapy. *Circ Res* 2014; 114:1500–1515.
- Po SS, Nakagawa H, Jackman WM. Localization of left atrial ganglionated plexi in patients with atrial fibrillation. *J Cardiovasc Electrophysiol* 2009; 20:1186–1189.
- Moerman JR, Christie B 3rd, Sykes LN, Vogel RL, Nolan TL, Ashley DW. Early cardiac pacemaker placement for life-threatening bradycardia in traumatic spinal cord injury. *J Trauma* 2011;70:1485–1488.
- Manogue M, Hirsh DS, Lloyd M. Cardiac electrophysiology of patients with spinal cord injury. *Heart Rhythm* 2017;14:920–927.
- Armour JA. Potential clinical relevance of the 'little brain' on the mammalian heart. *Exp Physiol* 2008;93:165–176.
- Chiou CW, Eble JN, Zipes DP. Efferent vagal innervation of the canine atria and sinus and atrioventricular nodes. The third fat pad. *Circulation* 1997; 95:2573–2584.
- Yuan BX, Ardell JL, Hopkins DA, Losier AM, Armour JA. Gross and microscopic anatomy of the canine intrinsic cardiac nervous system. *Anat Rec* 1994; 239:75–87.
- Qin M, Zhang Y, Liu X, Jiang WF, Wu SH, Po S. Atrial ganglionated plexus modification: a novel approach to treat symptomatic sinus bradycardia. *JACC Clin Electrophysiol* 2017;3:950–959.
- Hu F, Zheng L, Liang E, et al. Right anterior ganglionated plexus: the primary target of cardioneuroablation? *Heart Rhythm* 2019;16:1545–1551.
- Aksu T, Guler TE, Bozyel S, Yalin K. Selective vagal innervation principles of ganglionated plexi: step-by-step cardioneuroablation in a patient with vasovagal syncope. *J Interv Card Electrophysiol*. <https://doi.org/10.1007/s10840-020-00757-3>. 2020.05.11.