

Available online at www.sciencedirect.com

ScienceDirect

journal homepage: <http://Elsevier.com/locate/radcr>

Case Report

Extranodal manifestation of Rosai-Dorfman disease in the breast tissue

Qiao Zhou MD^{a,*}, Umer Ansari BS^a, Nandan Keshav BS^a, Fiona Davis MD^b,
Maria Cundiff MD^b

^a Department of Radiology, Eastern Virginia Medical School, 6800 Gresham Dr Norfolk, VA 23510, USA

^b Department of Radiology, Sentara Norfolk General Hospital, Norfolk, VA, USA

ARTICLE INFO

Article history:

Received 14 December 2015

Received in revised form

24 January 2016

Accepted 17 April 2016

Available online 17 May 2016

Keywords:

Rosai Dorfman disease

Mammography

Histiocytes

Breast

ABSTRACT

A 71-year-old asymptomatic female with a history of breast cancer status after right total mastectomy had interval development of several new nodules in the left breast in a 1-year time span. Stereotactic biopsy was performed, which revealed multifocal Rosai Dorfman disease in the left breast. The patient was referred to hematology, and computed tomography of the chest/abdomen/pelvis did not demonstrate any lymphadenopathy elsewhere in the body. This case report discusses incidences of extranodal Rosai Dorfman disease and the differential for breast lesions that can present the same way.

Published by Elsevier Inc. on behalf of under copyright license from the University of Washington. This is an open access article under the CC BY-NC-ND license (<http://creativecommons.org/licenses/by-nc-nd/4.0/>).

Case report

A 71-year-old woman with a history of breast cancer s/p right total mastectomy, hypertension, hypothyroidism, and right knee osteoarthritis presented to the clinic for a regularly scheduled annual screening mammogram. On comparison with previous mammograms (Fig. 1), several new nodules were noted in the left breast (Fig. 2). Diagnostic mammography confirmed the persistence of 2 new nodules within the left breast. Ultrasonography confirmed the presence of an oval parallel $5 \times 3 \times 5$ mm³ mass with slightly irregular margins at the 12:00 position, as well as a $4 \times 4 \times 3$ mm³ hypoechoic nodule near the 2:00

position (Fig. 3). A Breast Imaging Reporting and Data System of 4 was given, and biopsy of these nodules was recommended.

A stereotactic core biopsy of the left breast was chosen over ultrasound guidance because of close proximity of these nodules, and a total of 9 core samples were obtained. The pathology of these nodules was later found to be extranodal Rosai-Dorfman disease (RDD; Figs. 4 and 5). This finding was deemed benign, but further evaluation for additional involvement of nonbreast areas was recommended, and patient follow-up with the hematology service was advised as well. Subsequent computed tomography (CT) of the chest abdomen pelvis did not demonstrate any evidence of

Competing Interests: The authors have declared that no competing interests exist.

* Corresponding author.

E-mail address: chowzhoumd@gmail.com (Q. Zhou).

<http://dx.doi.org/10.1016/j.radcr.2016.04.012>

1930-0433/Published by Elsevier Inc. on behalf of under copyright license from the University of Washington. This is an open access article under the CC BY-NC-ND license (<http://creativecommons.org/licenses/by-nc-nd/4.0/>).

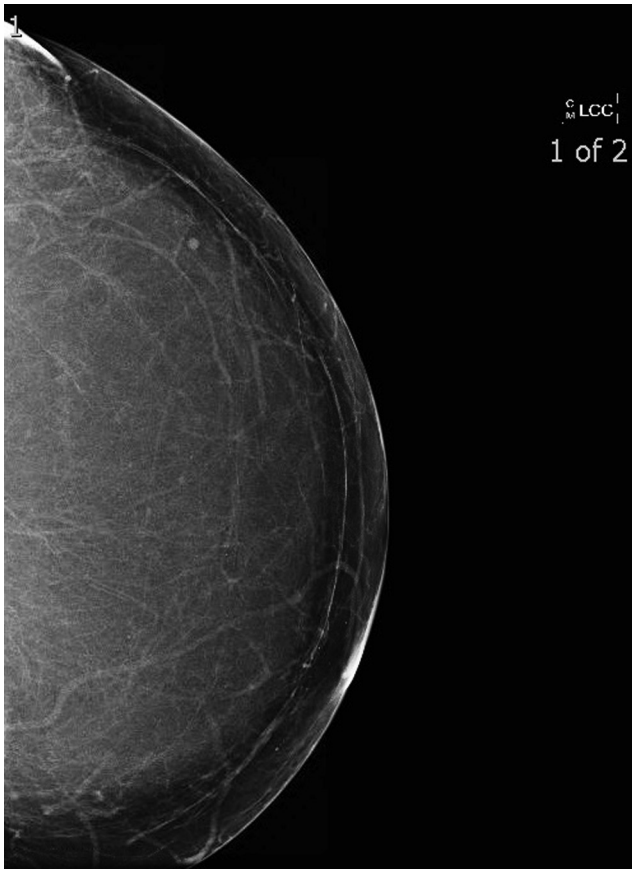

Fig. 1 – 7/3/2014: Mammogram demonstrates no evidence of malignancy.

systemic lymphadenopathy. Because of the patient's history of breast carcinoma and isolated locus of disease, it was ultimately determined by the patient's multidisciplinary team to perform a curative resection of the involved site.

Discussion

Sinus histiocytosis and massive lymphadenopathy also known as RDD is characterized by an uncontrolled proliferation of the non-Langerhans sinus histiocyte [1]. Pathologically, these histiocytes harbor what are presumably engulfed, intact lymphocytes lending the appearance of "cell within a cell" or emperipolesis [2]. Identification of cell surface S-100 and CD68 receptors and the lack of CD1a expression are the cardinal histologic characteristics of this cell type [1]. This rare disease demonstrates predominance in young adults; however, adult cases have also been documented. Most patients present with profound cervical lymphadenopathy in addition to headaches and seizures if the intracranial space is involved. The most commonly reported extranodal sites include the skin, central nervous system, upper respiratory tract, orbit and eyelid, and gastrointestinal tract [3,4]. The exact inciting factor is unknown, but immune system dyscrasias and viral infections, specifically herpesvirus 6, have been implicated [5].

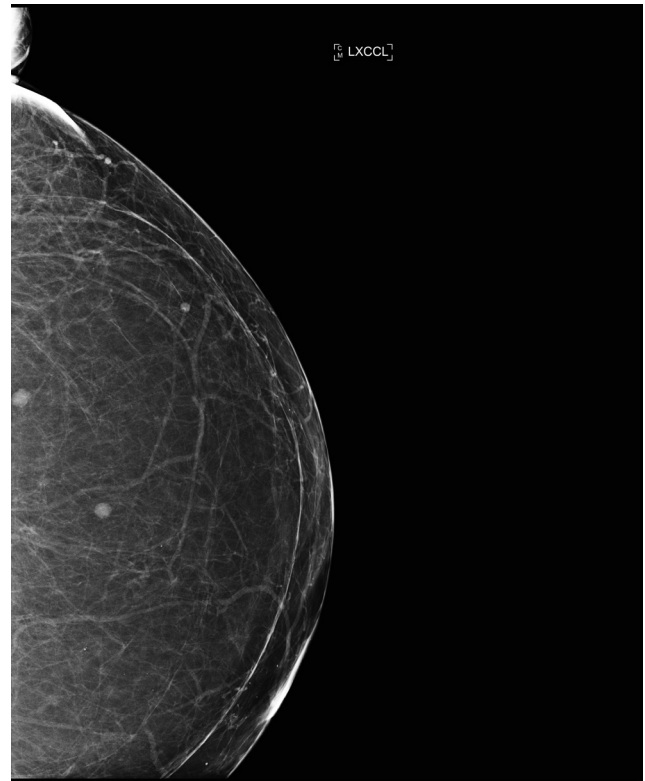


Fig. 2 – Mammogram 7/9/2015: 2 new nodules within the upper left breast, one at the 12:00 position and the other at the 1 to 2:00 position posteriorly.

Infiltration into breast tissue by RDD is a very rare occurrence [6,7]. Moreover, disease isolated solely to the breast is rarer still, as RDD commonly presents with lymphadenopathy and involves multiple organs at the time of diagnosis [8]. Although RDD tends to present most commonly in young males (average age 39 years) involving multiple organs, most of the cases isolated to the breast occur in female patients older than 50 years [9]. This is especially significant because women after 50 years are screened regularly because of increased risk of breast carcinoma, and initial radiographic and clinical presentation of RDD can masquerade as lesions running the gamut of benign cysts and fibroadenomas to carcinoma [10,11]. Differential considerations of mass-like, histiocytic invasion into breast tissue should always include RDD among other entities such as Langerhans' cell histiocytosis, Erdheim-Chester disease, diabetic mastopathy, and granulomatous lobular mastitis [12,13].

In reference to the patient presented in this case, the discovery of 2 new nodular lesions in the left breast in the setting of right breast cancer status after mastectomy were cogent indications to proceed with stereotactic biopsy. RDD can have a high rate of recurrence which could potentially lead to repeated biopsies and excisions in the breast tissue [14]. Notably, incidental discovery of RDD in the breast parenchyma necessitates establishing the full extent of disease elsewhere in the body with full body CT and abdominal ultrasound [15]. Positron emission

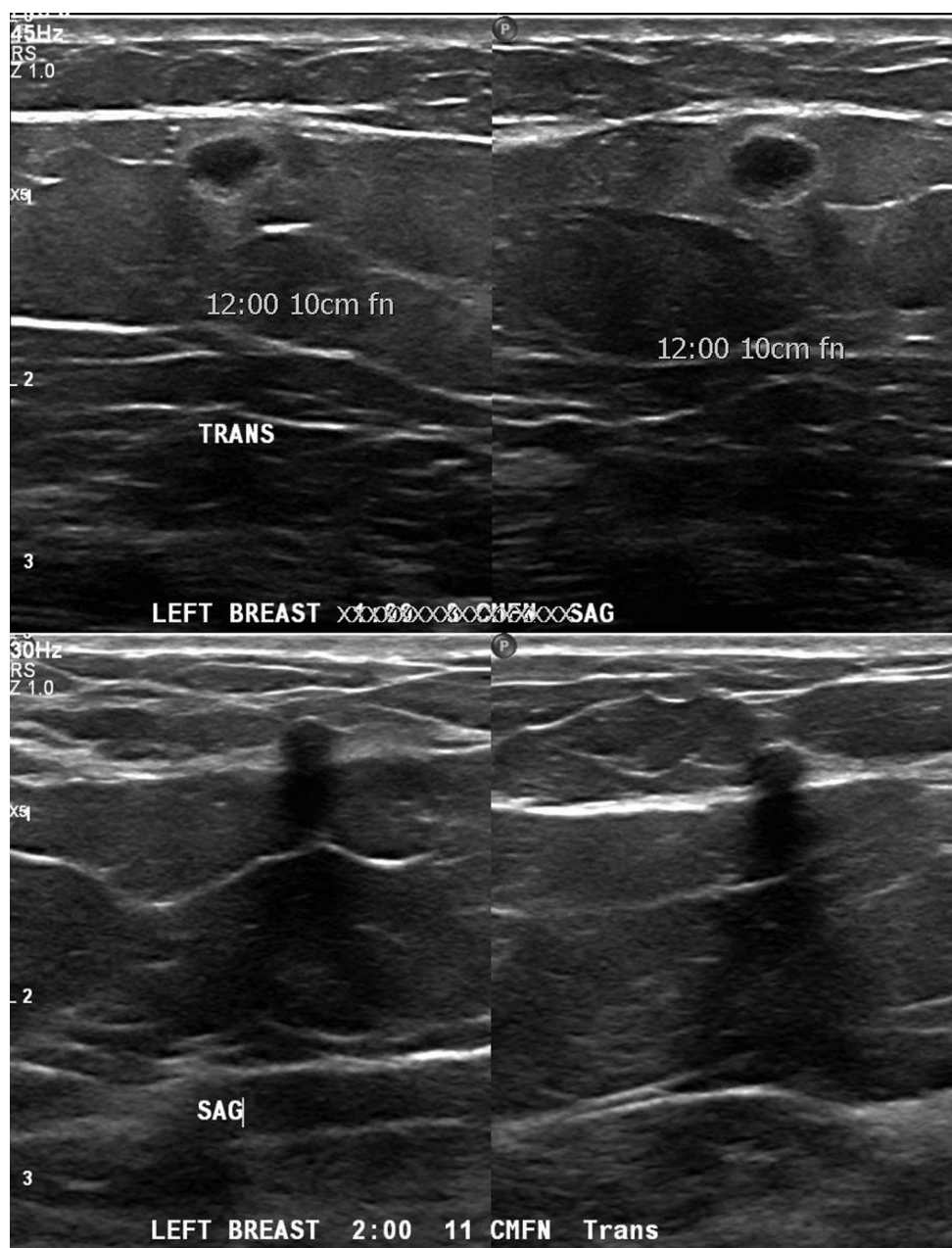


Fig. 3 – At the 12:00 position 10 cm from the nipple, there is an oval parallel $5 \times 3 \times 5 \text{ mm}^3$ mass with slightly irregular margins. At the 2:00 position 4 cm from the nipple, there is a $4 \times 4 \times 3 \text{ mm}^3$ new hypoechoic nodule.

tomography/CT can also be useful for characterization because areas of involvement by RDD can possess flu-deoxyglucose avidity [16].

Parkin et al recently described a patient with isolated RDD of the breast in a 56-year-old healthy patient [11]. Similar to our case, the patient had an intermediate density of the lateral left breast discovered incidentally on routine mammography, with no apparent lymphadenopathy; however, unlike this presented case report, the patient had no history of breast carcinoma. Histologically, their specimen showed emperipolesis and staining for S-100 and CD68. In contrast to

surgical intervention, their patient was followed with regular follow-up and screening. These cases are of note as patients with RDD typically present with fever, leukocytosis, and nonpainful adenopathy—symptoms not seen in either of the cases.

After an indolent, benign course, RDD is not an entity that compels aggressive management, and in most cases, will exhibit spontaneous regression [3]. Recognizing the unique microscopic and histologic presentation of RDD may save both providers and patients from invasive, costly, and unnecessary investigative procedures.

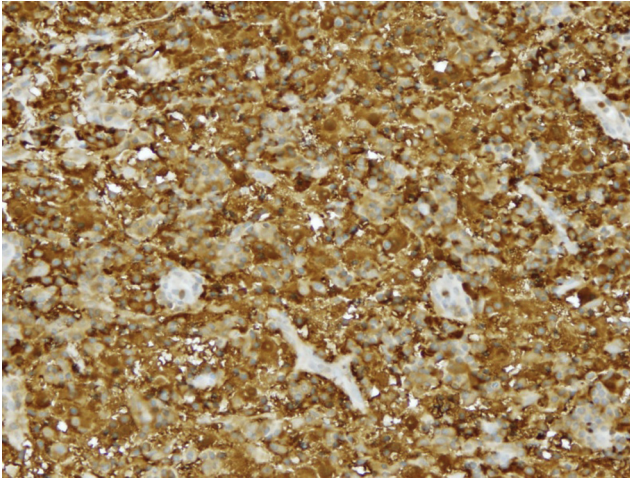


Fig. 4 – Immunoperoxidase stain panel performed on with results: s100 (A1 and C1) strongly positive in histiocytes; CD1a (A1) negative in histiocytes; CD138 (A1) highlights plasma cells; kappa (A1) and lambda (A1) fail to demonstrate evidence of clonality.

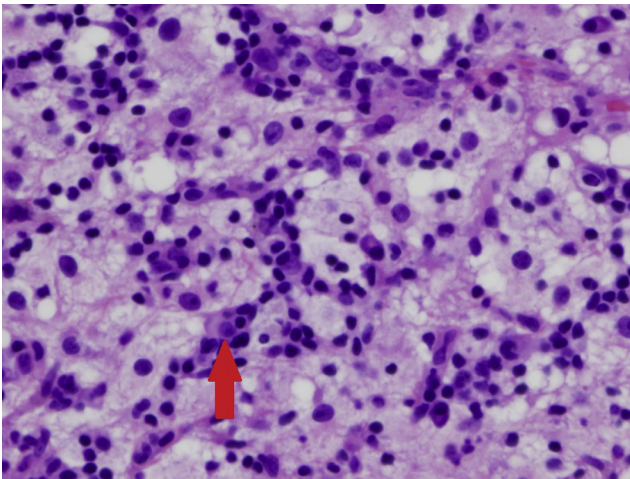


Fig. 5 – Hematoxylin and eosin stain shows well-demarcated infiltrates of prominent histiocytes intermixed with small mature lymphocytes and plasma cells. Histiocytes are large, irregularly shaped with abundant vacuolated cytoplasm. Engulfed lymphocytes as shown by a clear halo of cytoplasm surrounding lymphocytes is a characteristic of emperipolesis (arrow). Plasma cells demonstrate binucleation. Evidence of intact nodal architecture is not identified.

REFERENCES

- [1] Shrestha B, Sekiguchi H, Colby TV, Graziano P, Aubry MC, Smyrk TC. Distinctive pulmonary histopathology with increased IgG4-positive plasma cells in patients with autoimmune pancreatitis: report of 6 and 12 cases with similar histopathology. *Am J Surg Pathol* 2009;33:1450–62.
- [2] Shi Y, Griffin AC, Zhang PJ, Palmer JN, Gupta P. Sinus histiocytosis with massive lymphadenopathy (Rosai–Dorfman disease): a case report and review of 49 cases with fine needle aspiration cytology. *Cytojournal* 2011;8:3.
- [3] Green RF, Dorfman RF, Rosai J. Breast involvement by extranodal Rosai–Dorfman disease: report of seven cases. *Am J Surg Pathol* 1997;21:664–8.
- [4] Zhao M, Li C, Zheng J, Yu J, Sha H, Yan M. Extranodal Rosai–Dorfman disease involving appendix and mesenteric nodes with a protracted course: report of a rare case lacking relationship to IgG4-related disease and review of the literature. *Int J Clin Exp Pathol* 2013;6(11):2569–77.
- [5] McClain KL, Natkunam Y, Swerdlow SH. Atypical cellular disorders. *Hematology (Am Soc Hematol Educ Program)* 2004:283–96.
- [6] Kuo TT, Chen TC, Lee LY, Lu PH. IgG4-positive plasma cells in cutaneous Rosai–Dorfman disease: an additional immunohistochemical feature and possible relationship to IgG4-related sclerosing disease. *J Cutan Pathol* 2009;36:1069–73.
- [7] da Silva BB, Lopes-Costa PV, Pires CG, Pereira-Filho JD, dos Santos AR. Rosai–Dorfman disease of the breast mimicking cancer. *Pathol Res Pract* 2007;203:741–4.
- [8] Kuzmiak CN, Koomen M, Lining R, Pisano E. Rosai–Dorfman disease presenting as a suspicious breast mass. *AJR Am J Roentgenol* 2003;180:1740–2.
- [9] Mac-Moune Lai F, Lam WY, Chin CW, Ng WL. Cutaneous Rosai–Dorfman disease presenting as a suspicious breast mass. *J Cutan Pathol* 1994;21:377–82.
- [10] Pérez-Guillermo M, Sola-Pérez J, Rodríguez-Bermejo M. Malacoplakia and Rosai–Dorfman disease: two entities of histiocytic origin infrequently localized in the female breast. The cytologic aspect in aspirates obtained via fine-needle aspiration cytology. *Diagn Cytopathol* 1993;9:698–704.
- [11] Bendeito S, Pedro L, Cleicilene P, Castanza E. Rosai–Dorfman disease of the breast mimicking cancer. *Pathol Res Pract* 2007;203(10):741–4.
- [12] Cha YJ, Yang WI, Park SH, Koo JS. Rosai–Dorfman Disease in the breast with increased IgG4 expressing plasma cells: a case report. *Korean J Pathol* 2012;46(5):489–93.
- [13] Fong D, Lann MA, Finlayson C, Page DL, Singh M. Diabetic (lymphocytic) mastopathy with exuberant lymphohistiocytic and granulomatous response: a case report with review of literature. *Am J Surg Pathol* 2006;30:1330–6.
- [14] Parkin CK, Keevil C, Howe M, Maxwell A. Rosai–Dorfman disease of the breast. *BJR Case Rep* 2015;1:1.
- [15] Tenny SO, McGinness M, Zhang D, Damjanov I. Rosai–Dorfman disease presenting as a breast mass and enlarged axillary lymph node mimicking malignancy: a case report and review of the literature. *Breast J* 2011;17:516–20.
- [16] Yu JQ, Zhuang H, Xiu Y, Talati E, Alavi A. Demonstration of increased FDG activity in Rosai–Dorfman disease on positron emission tomography. *Clin Nucl Med* 2004 Mar;29(3):209–10.