

# Combining Autologous and Prosthetic Techniques: The Breast Reconstruction Scale Principle

Salvatore Tagliatela Scafati,  
MD, FEBOPRAS\*  
Annachiara Cavaliere, MD\*†  
Bianca Aceto, MD\*  
Francesco Somma, MD\*  
Luigi Cremonese, MD\*

**Background:** The latissimus dorsi (LD) flap remains a good option for immediate or delayed breast reconstruction. The main limitation of this flap is the small volume provided. To improve the reconstructed breast volume, the LD flap is usually combined with a breast implant. Recently, fat grafting to the LD flap was described to maximize flap volume and obtain a totally autologous breast reconstruction. We report our experience with hybrid breast reconstruction using both breast implants and fat-enriched latissimus dorsi (FELD) flaps.

**Methods:** Between 2013 and 2016, 74 patients underwent breast reconstruction with FELD flaps only or FELD flaps combined with a breast implant. The LD flap was harvested as previously described. Donor sites for fat harvesting were chosen according to each patient's natural fat distribution. Fat was harvested, centrifuged, and injected into the LD flap. After fat grafting, breast sizers were employed to determine the final breast volume when the addition of an implant was indicated.

**Results:** Good cosmetic outcomes were achieved in all cases, with a mean follow-up of 2.1 years. No patients had cancer recurrences. Four patients experienced a seroma of the LD donor site, 1 had a breast hematoma, and 1 developed Baker grade III capsular contracture. One year postoperatively, a clinically relevant area of fat necrosis was observed in 1 patient and was surgically treated. Additional fat grafting sessions were required in 3 cases.

**Conclusion:** In selected cases, a FELD flap alone or in combination with a small implant is a valuable technique for breast reconstruction surgery. (*Plast Reconstr Surg Glob Open* 2017;5:e1602; doi: 10.1097/GOX.0000000000001602; Published online 28 December 2017.)

## INTRODUCTION

A wide array of breast reconstruction techniques is currently available to reconstructive surgeons.<sup>1,2</sup> The choice of the most appropriate reconstruction technique depends on the timing of the reconstruction, the surgeons' training, and the clinical setting. Reconstruction should be patient-focused, with the main purpose being to restore local anatomy and achieve, whenever possible, symmetry with the contralateral side.

Autologous reconstruction using abdominally based flaps or inner thigh flaps is now considered the gold standard. Despite the widespread use of microsurgical breast

reconstructions, 2-stage procedures and latissimus dorsi (LD) reconstructions are still very common.<sup>2,3</sup>

Breast reconstruction with prior insertion of a tissue expander is a good option for primary cases receiving post-mastectomy radiotherapy (PMRT). However, in these patients, delayed 2-stage expander/implant reconstructions are associated with poor outcomes. Surgical manipulation of irradiated, expanded tissues can lead to a significantly increased risk of complications such as capsular contracture, implant exposure, high reoperation rates, and poor surgical outcomes.<sup>4,5</sup>

Since it was first reported in 1906 by the Italian surgeon Iginio Tansini,<sup>6,7</sup> the use of the LD flap has been a reliable technique for breast reconstruction.<sup>8-13</sup> The LD flap provides an adequate amount of muscle, allowing for coverage of a small implant when needed, adding well-vascularized extra tissue for the reconstruction of the breast, and reducing the risk of capsular contracture.<sup>2,14,15</sup>

From the \*Unità di Senologia e Chirurgia Plastica Ricostruttiva, Casa di Cura Malzoni – Villa dei Platani (Gruppo Neuromed), Avellino, Italy; and †Scuola di Medicina e Chirurgia, Università degli Studi di Napoli Federico II, Napoli, Italy.

Received for publication September 12, 2017; accepted October 20, 2017.

Copyright © 2017 The Authors. Published by Wolters Kluwer Health, Inc. on behalf of The American Society of Plastic Surgeons. This is an open-access article distributed under the terms of the Creative Commons Attribution-Non Commercial-No Derivatives License 4.0 (CCBY-NC-ND), where it is permissible to download and share the work provided it is properly cited. The work cannot be changed in any way or used commercially without permission from the journal.

DOI: 10.1097/GOX.0000000000001602

**Disclosure:** The authors have no financial interest to declare in relation to the content of this article. The Article Processing Charge was paid for by the authors.

Supplemental digital content is available for this article. Clickable URL citations appear in the text.

Recently, fat grafting of the LD has been described to maximize flap volume and to obtain a completely autologous reconstruction, thereby avoiding the need for a prosthetic device to match the contralateral side.<sup>16-20</sup>

We present a series of 74 consecutive patients who underwent immediate and delayed reconstructions in which both autologous and prosthetic techniques, individually or in combination, were employed. The results demonstrate the efficacy and reliability of the fat-enriched latissimus dorsi (FELD) flap, with and without implants, in giving structural support with adequate volume replacement for the reconstructed breast.

## PATIENTS AND METHODS

Seventy-four consecutive patients who underwent immediate or delayed breast reconstruction between 2013 and 2016 were included in this study. A detailed retrospective analysis was performed using patients' charts, clinical data, and photographs.

Inclusion criteria included patients undergoing immediate reconstruction, failed breast conservative surgeries, and delayed reconstruction in patients with a tissue expander, with or without PMRT.

FELD reconstruction was offered to patients unwilling to undergo free tissue transfer surgery techniques, and to patients who were not candidates for microsurgical reconstruction (inadequate donor site, heavy smokers, known thrombophilic condition, or body mass index greater than 40 kg/m<sup>2</sup>).

Preoperative evaluations<sup>21,22</sup> included analysis of the patient's medical history, physical exams, and preoperative imaging. Patients' medical history recording was focused on cancer features (tumor stage, size, type, and hormone receptor positivity [ER/PR/Her2neu]), oncological surgery plan (lumpectomy vs. mastectomy, immediate vs. delayed), chemotherapy or radiation therapy (PMRT) plan, family history (breast disease and coagulopathy), smoking, and comorbidities (hypertension, diabetes, cardiovascular disease, obesity, and hypercoagulable disorders).

Physical exams evaluated each patient's overall breast size and shape, location and size of lumps in the breast/axilla, position of the inframammary fold and nipple (grade of ptosis), nipple deformity, location of the mastectomy or quadrantectomy scar, chest wall deformity, skin changes, and any asymmetries. Measurements from the sternum to nipple, nipple to fold distances, and base diameter were taken. Also, the donor site for the LD flap and the fat graft was evaluated.

Preoperative imaging included standard mammograms, ultrasounds, magnetic resonance imaging of the breast, and positron emission tomography scans to exclude metastatic disease.

Accurate photographic documentation was obtained for all of our cases.

### Flap Design and Dissection

Each patient was marked preoperatively while in an upright position. The location of the skin paddle was drawn to lie along the natural resting tension lines and natural

crease of the back. The pinch test was used to determine the skin paddle size. When required, skin paddle orientation was marked according to the mastectomy or quadrantectomy scar. Whenever possible and in cases in which a skin sparing mastectomy was indicated, the LD incision lay in the natural bra line. The excised areola was then resurfaced using a circular skin paddle.<sup>19,23</sup> Attention was paid to identify and mark the anterior border of LD muscle, which is an essential anatomical landmark for this flap.

With the patient in lateral decubitus, a beveled incision was used that reached the sub-fascial plane. Dissection was done by staying just above the LD muscle, and proceeding in a cephalo-caudal direction. Once the anterior border was identified and retracted, the inner surface of the LD muscle was detached from the serratus fascia, taking care to clip or coagulate any encountered perforators. In case of a large breast or totally autologous FELD (without implant), the maximum amount of muscle was harvested by extending the dissection caudally, reaching the iliac crest.

The thoracodorsal pedicle was dissected bluntly in the areolar plane between the serratus and the LD plane. To avoid dynamic breast deformities, the thoracodorsal nerve was identified and transected in cases of implant placement.

The LD tendon was divided to maximize the arch of rotation. The flap was then rotated through a subcutaneous tunnel to reach the mastectomy site.

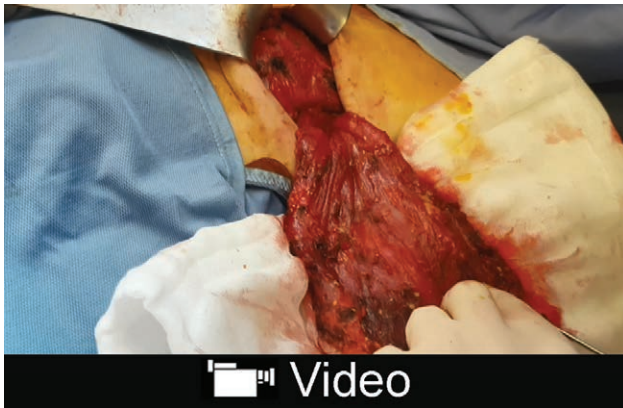After placing two Jackson Pratt drains, closure was performed in layers.

### Fat Grafting

Fat harvest donor sites were chosen according to the distribution of natural fat deposits. Common donor sites included the abdomen, flank, and inner thighs.

The donor sites were injected with a tumescent solution containing 1 mL of adrenaline per 1 L of normal saline. Fat was harvested through 3-mm multihole cannulas (Trimed, LTD., Ankara, Turkey) using 60-cc Luer-lock syringes. Fat was then centrifuged for 3 minutes at 3200 rpm and, once excess liquids were removed, it was transferred to smaller 20-cc Luer-lock syringes.

With the patient lying supine and using a single-hole, 2.4-mm infiltration cannula (Trimed, LTD., Ankara, Turkey), fat was injected into the LD muscle, taking care to avoid the main vascular branches, which are clearly visible on the underface of the muscle tissue, into pectoralis major and serratus muscle when needed (See video, Supplemental Digital Content 1, which displays multilayer and multisite fat grafting of the LD flap: fat is injected into the LD muscle, into pectoralis major and serratus muscle until the recipient site is saturated and according to the volume desired. This video is available in the "Related Videos" section of the Full-Text article on PRSGlobalOpen.com or at <http://links.lww.com/PRSGO/A623>). Fat was injected in small quantities in "far to near" fatty deposits and in a fan-shaped fashion until the recipient site was saturated and according to the volume desired. Fat grafting of the LD flap was performed both into the skin paddle and into the LD muscle. In cases where breast implants were needed, breast sizers were employed to determine definitive breast



**Video Graphic 1.** See video, Supplemental Digital Content 1, which displays multilayer and multisite fat grafting of the LD flap: fat is injected into the LD muscle, into pectoralis major and serratus muscle until the recipient site is saturated and according to the volume desired. This video is available in the “Related Videos” section of the Full-Text article on PRSGlobalOpen.com or at <http://links.lww.com/PRSGO/A623>.

implant volume after the fat grafting procedure. Before implant placement, the breast pocket was rinsed copiously with saline.

The FELD edges were secured to the medial and inferior aspects of the breast pocket by means of 1–4 external Ethilon (Ethicon, Inc., Somerville, NJ) bolster sutures to ensure correct flap inseting, with complete implant coverage (Fig. 1). When the implant was avoided, the FELD was folded on itself using 2-0 Vicryl (Ethicon, Inc., Somerville, NJ) to create the new breast mound to be placed into the new breast pocket (Fig. 2). After positioning a Jackson-Pratt drain, the skin was closed directly in layers.

When required, a de-epithelized FELD skin paddle was buried under the mastectomy flaps.

Additional fat grafting procedures were considered 4–6 months postoperatively to correct any asymmetry.

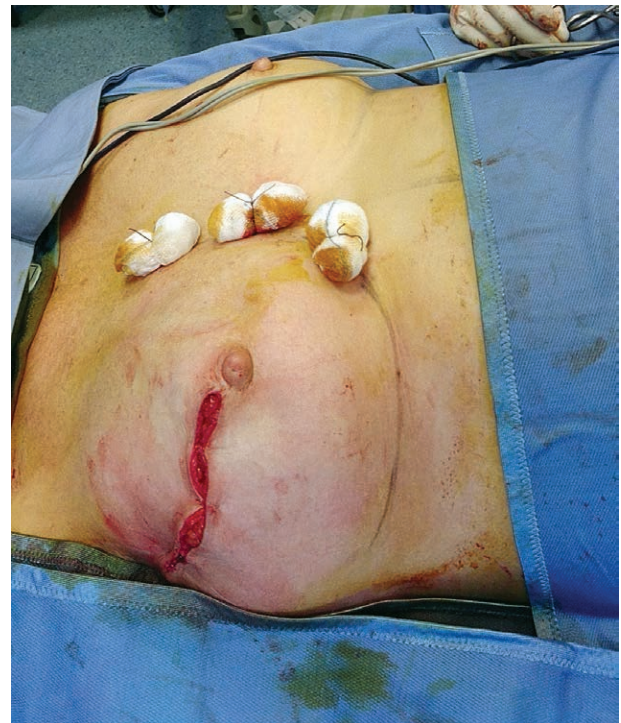## RESULTS

Of the 74 consecutive cases included in this study, 65 had at least 12 months of follow-up. The mean follow-up was 2.1 years. Patients’ mean age was 44.3 years. In 48 patients, immediate reconstruction was performed, whereas the remaining 26 cases received delayed reconstruction. Ten of the 26 delayed reconstructions had received PMRT. A salvage mastectomy was necessary in 5 patients in which breast conservative surgeries had failed because of recurrent disease.

In 58 patients, breast reconstruction was a hybrid, using FELD in combination with an implant, whereas 16 patients received a FELD-only autologous reconstruction (14 immediate and 2 delayed reconstructions). In 4 cases, the reconstruction was bilateral.

Fat graft donor sites were the abdomen, flanks, and inner thighs for all cases. The mean volume of harvested fat was 207.3 cc (range: 130–320 cc), whereas the mean volume of the injected fat was 146.7 cc (range: 100–300 cc).

Postoperative complications in our case series included 4 cases (2 with FELD + implants and 2 with FELD only) of seroma of the LD donor site, which were treated with

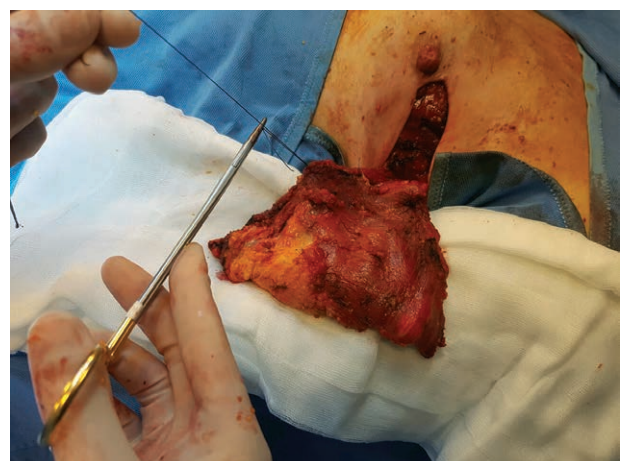

**Fig. 1.** External bolster sutures of the LD flap.

repeated syringe drainage; 1 breast hematoma in a patient with a FELD + implant, which was surgically evacuated; and 1 Baker grade III capsular contracture in a patient who received PMRT. One year postoperatively, 1 patient with FELD-only developed a palpable 3-cm fat necrosis lump that had to be surgically excised. Additional fat grafting sessions were required in 3 cases and were performed 4–6 months after reconstruction (Table 1).

### Case A

Case A was a 42-year-old patient admitted to our unit with a history of recurrent invasive intraductal carcinoma. Ten months before, she had undergone quadrantectomy and radiotherapy elsewhere. Her magnetic resonance im-



**Fig. 2.** The LD flap is folded on itself to create the new breast mound.

**Table 1. Results**

	Immediate Reconstruction	Delayed Reconstruction	PMRT	Additional Fat Graft Sessions	Complications
FELD + implant	34	24	58	1	<ul style="list-style-type: none"> <li>• 1 capsular contracture (grade III)</li> <li>• 2 LD donor site seroma</li> <li>• 1 hematoma</li> </ul>
FELD only	14	2	6	2	<ul style="list-style-type: none"> <li>• 2 LD donor site seroma</li> <li>• 1 fat necrosis</li> </ul>
Total	48	26	64	3	7

aging showed extensive multifocal disease. Under general anesthesia, she underwent skin sparing mastectomy with immediate breast reconstruction using a FELD flap augmented with 100 cc of fat and a 140-cc CPG322 Mentor implant. At her most recent follow-up (2.5 years after breast reconstruction), no recurrence was observed (Fig. 3).

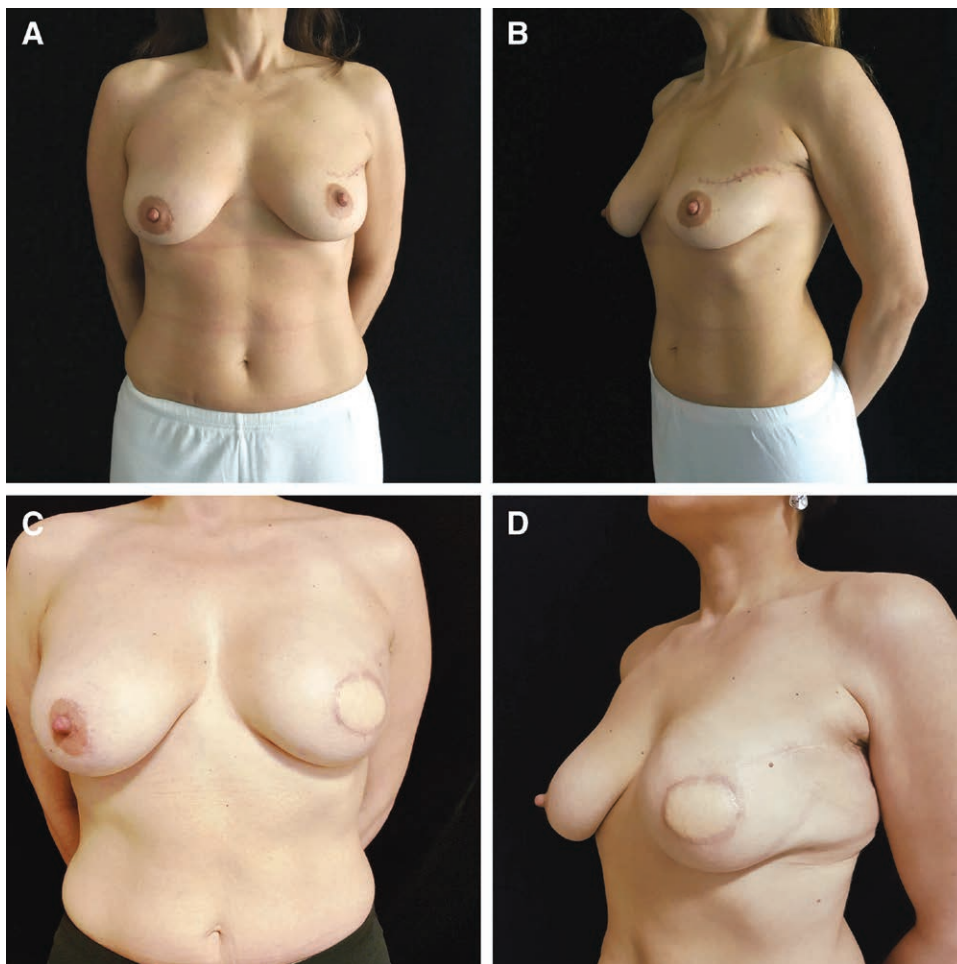
**Case B**

Case B was a 50-year-old patient with a previous expander placement who was admitted for secondary breast reconstruction. Her surgical plan included delayed reconstruction using a FELD flap augmented with 130 cc of fat and a subpectoral 135 CPG 321 Mentor Implant. For the contralateral breast adjustment, a crescent augmenta-

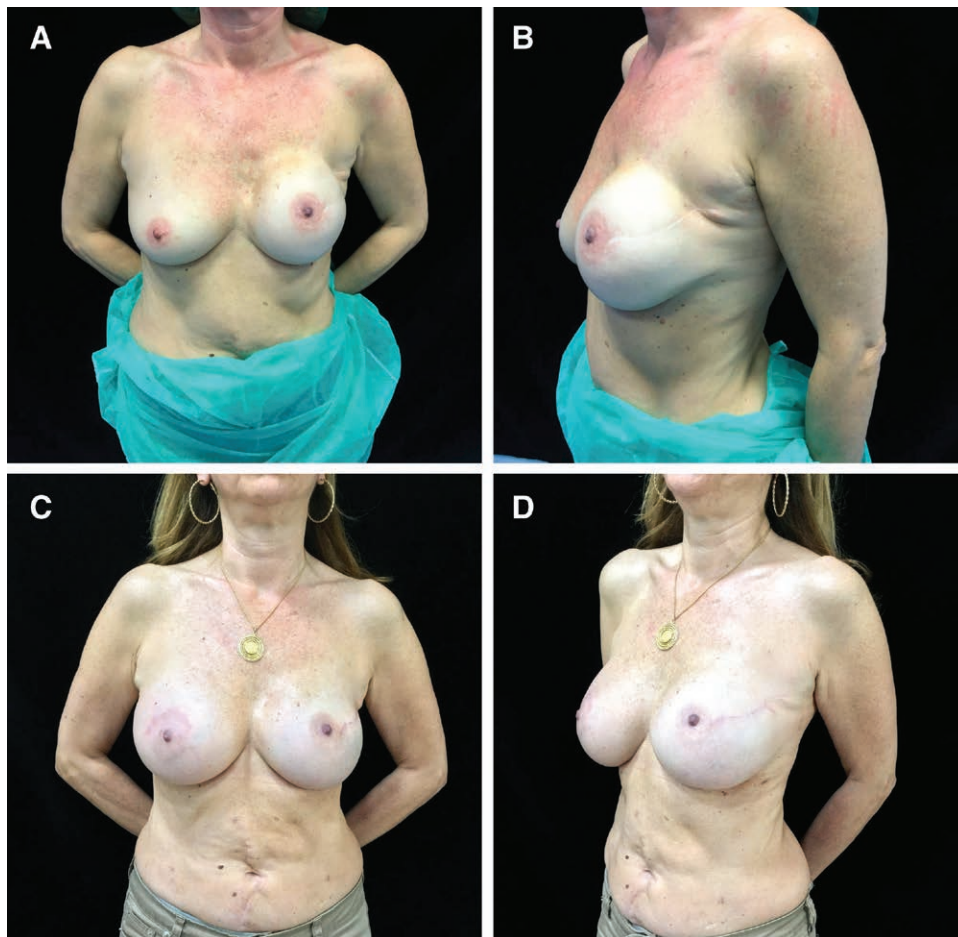
tion mastopexy using a 175-cm<sup>3</sup> CPG 322 Mentor implant was performed. At her most recent follow-up (1 year after breast reconstruction), no recurrence was observed (Fig. 4).

**Case C**

Case C was a 39-year-old patient who was previously diagnosed with invasive lobular carcinoma of the left breast. She presented to our unit 3 years after her primary surgery and after radiotherapy with a second primary triple-negative intraductal carcinoma. Her surgical plan included immediate reconstruction with a FELD flap augmented with 250 cc of fat. At her most recent follow-up (1.8 years after breast reconstruction), no recurrence was observed and



**Fig. 3.** Case A. A, B, Preoperative frontal and oblique views. C, D, Postoperative (2.5 years of follow-up) frontal and oblique views.



**Fig. 4.** Case B. A, B, Preoperative frontal and oblique views. C, D, Postoperative (1 year of follow-up) frontal and oblique views.

she was satisfied with the appearance of her reconstructed breast (Fig. 5).

**Case D**

Case D was a 38-year-old patient presenting with intraductal carcinoma of the left breast. She underwent nipple sparing mastectomy with concomitant axillary dissection with FELD flap reconstruction. Both the LD and pectoralis major muscle were augmented with 230 cc of fat. At her 11-month follow-up, she had satisfying breast contour with no recurrence of the disease (Fig. 6).

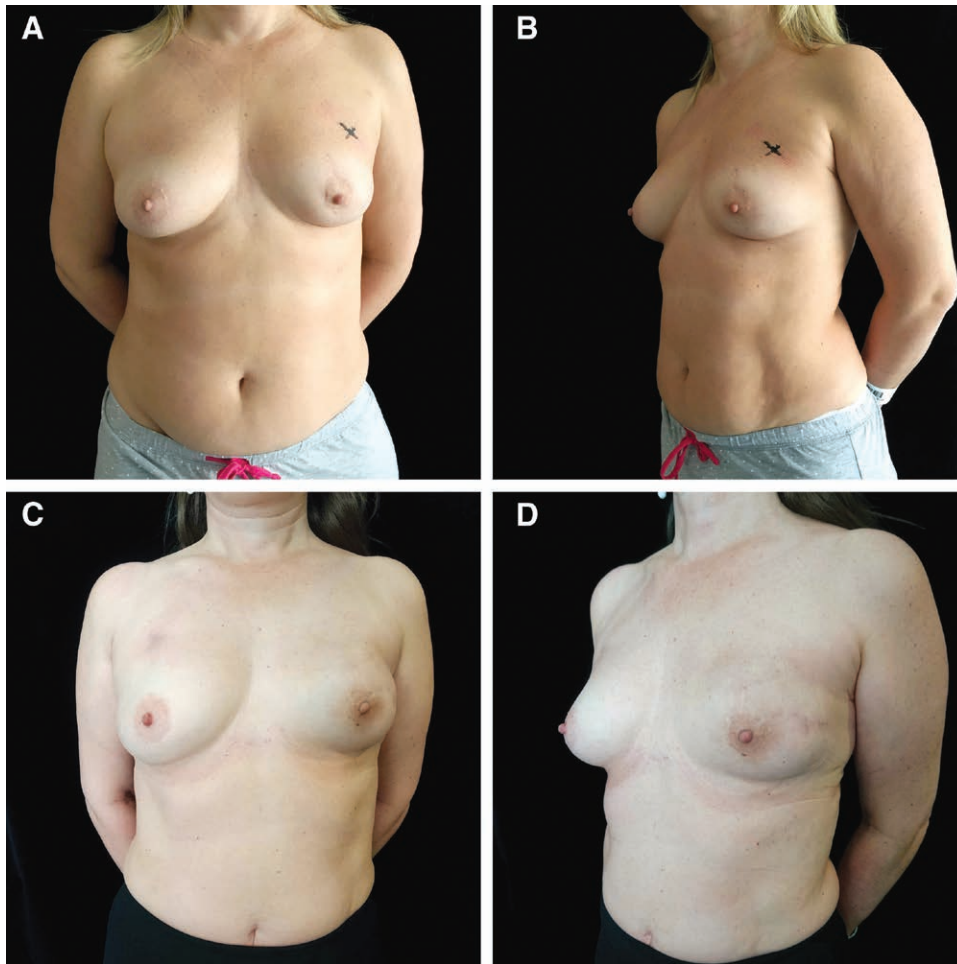
**DISCUSSION**

Breast reconstruction surgery is considered an integral part of breast cancer treatment to restore one or both breasts to their near-normal shape, appearance, symmetry, and size, and to enhance the patient’s quality of life.<sup>3,24</sup> In addition, the high surgical standards presently achieved in breast surgery along with modern mastectomy techniques, with the possibility of preserving the skin envelope, lead plastic surgeons to look for a natural and aesthetically pleasing appearance of the reconstructed breast.<sup>15</sup> Patients’ demands for breast reconstruction, moreover, are constantly increasing.<sup>25</sup>

Each reconstructive surgery should be patient-focused, taking into consideration both the size and shape of the woman’s natural breasts along with localization, cancer type, and prior radiotherapy.

Reconstruction with autologous tissues is the method of choice at our institution, especially in secondary cases who had received PMRT. Previously irradiated tissue can lead to poor results, with increased reoperation rates. These patients benefit from autologous reconstruction that includes microsurgical transfer of nonirradiated and healthy tissue, dramatically improving the appearance and the consistency of the reconstructed breast.<sup>5,22,26</sup>

The abdomen is an ideal source of tissue for breast reconstruction. Among peers, the autologous breast reconstruction techniques with abdominal tissue, the deep inferior epigastric perforator flap, is considered to be the first choice. The deep inferior epigastric perforator flap usually provides an ample amount of soft, viable, and highly moldable tissue for unilateral or bilateral reconstruction, with minimal donor site morbidity compared with the classic TRAM flap.<sup>27,28</sup> On the other hand, donor site paucity can limit the use of abdominally based flaps, especially in thin patients with a small breast size and smaller fatty deposits; in these cases, we prefer the FELD flap.



**Fig. 5.** Case C. A, B, Preoperative frontal and oblique views. C, D, Postoperative (1.8 years of follow-up) frontal and oblique views.

Transverse upper gracilis and profunda artery perforator flaps are reliable reconstructive tools for small-breasted patients in whom there is an absence of suitable abdominal donor sites that limit the use of deep inferior epigastric perforator.<sup>22</sup> In this setting, the need for microsurgery can also be associated with increased operative times and increased risk of flap-related complications, with subsequent partial or total flap loss.

Despite the wide spread use of microsurgical techniques, the LD flap is still one of the most reliable and popular methods used for breast reconstruction in patients who are not good candidates for microsurgical reconstruction techniques.<sup>19</sup>

The LD flap provides well-vascularized autologous tissue for breast reconstruction, is relatively easy to harvest, and is associated with a low rate of complications due to its constant anatomy.<sup>7</sup> The major source of concern and skepticism among peers is related to the effect of LD harvest on shoulder mobility; however, several studies showed no significant loss of range of motion or movement limitations.<sup>29–31</sup>

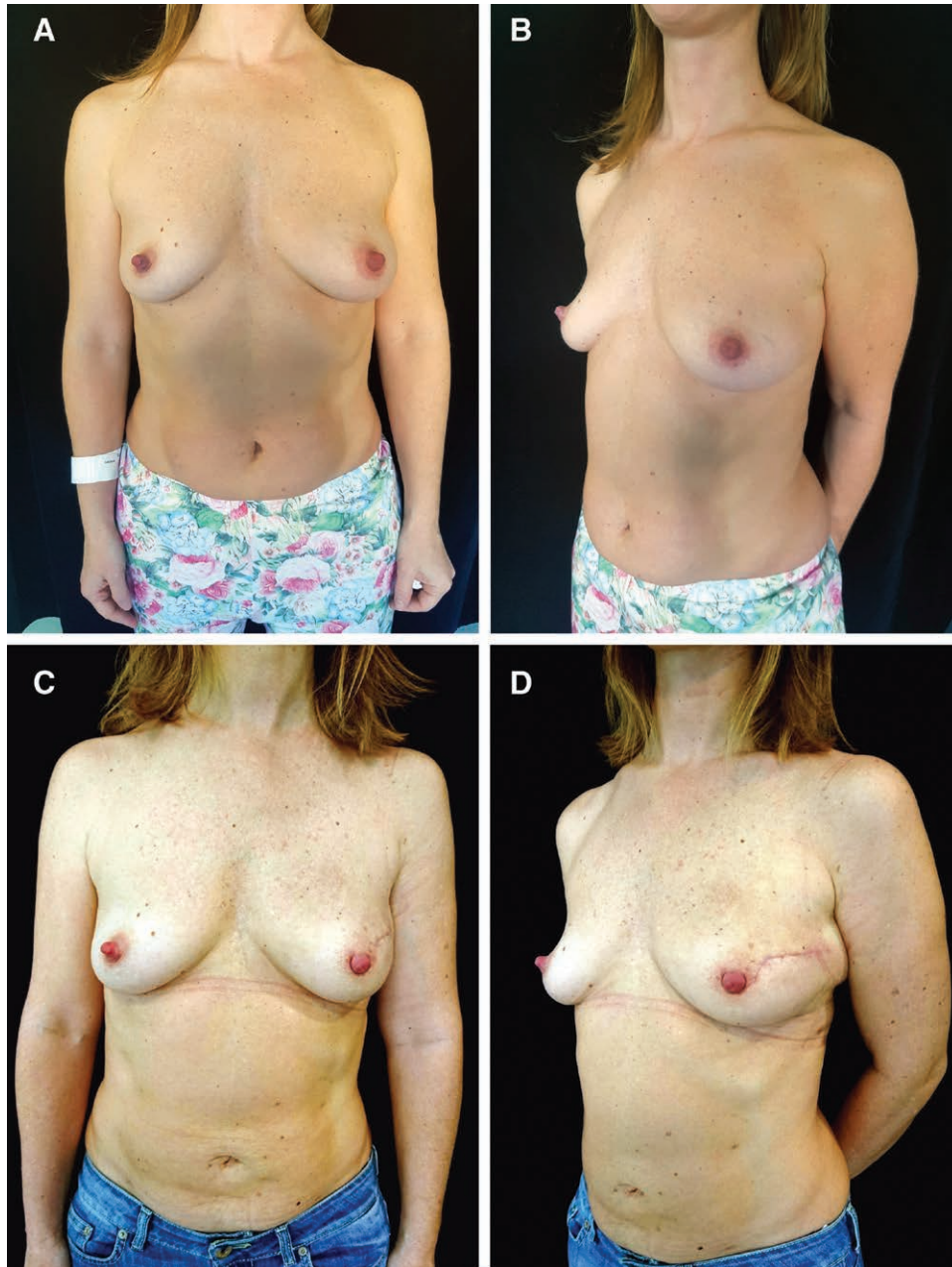
The main limitation of the LD flap is the small volume provided.<sup>19,32</sup> To overcome the lack of adequate volume to reconstruct the breast, the LD flap is usually combined with an implant.<sup>16–20,31,32</sup>

However, despite the protection provided by muscle tissue, implants are still associated with complications such as infection, displacement, rotation capsular contracture with distortion of the reconstructed breast, and eventually, poor aesthetic outcomes.<sup>14,16,33</sup>

The extended LD flap was popularized by Hokin<sup>34</sup> to avoid the use of implants. The extended LD flap usually provides sufficient volume for a totally autologous breast reconstruction due to the surgical technique, which includes harvesting a large skin paddle with the whole muscle, including the lumbar fascia.

Aggressive dissection can inevitably lead to increased donor site morbidity, with a high incidence of postoperative seroma. Lumbar fascia harvesting, moreover, makes surgical closure technically demanding. It can interfere with the normal approximation of the wound edges that are usually accomplished by suturing the superficial fascial layer first, with interrupted absorbable sutures. The lack of the superficial fascia and the extended dissection can cause wound breakdown, with subsequent dehiscence.<sup>35–37</sup> The final donor site scar can result in a huge depressed area in the back.

Fat grafting can be considered one of the most revolutionary procedures in the field of plastic surgery. Autolo-



**Fig. 6.** Case D. A, B, Preoperative frontal and oblique views. C, D, Postoperative (11 months of follow-up) frontal and oblique views.

gous fat is a useful technique in breast reconstruction and is widely employed. Recently, fat-enriched or fat-augmented LD flap series have been reported. The LD muscle is a suitable recipient tissue for fat transfer, with a rich blood supply and a reasonable volume to inject the fat into.<sup>16</sup> This can avoid the use of implants and allow the muscle to increase in volume and projection to reconstruct small-to average-sized breasts.<sup>16-21</sup> Fat grafting also represents a powerful tool for correcting any secondary deformity after breast reconstructive surgery.<sup>38</sup>

However, due to the breast shape, consistency, and size of some patients, autologous reconstruction with FELD flaps alone cannot provide satisfactory results. Placing a

small implant under the FELD flap can improve the aesthetic outcomes of the reconstructed breast. In this hybrid reconstruction, the LD flap provides good initial coverage of the implant, whereas the fat grafting to the LD and pectoralis major muscles provide a new tissue layer, improving the tissues' quality (especially in patients who received PMRT) and adding extra volume. This allows the breast implant size to be reduced, with subsequent decrease in implant-related complications over the long term.<sup>39</sup> Relying on a careful analysis of the literature and on our own experience, we suggest that a hybrid reconstruction with FELD and a small implant is a valuable breast reconstruction technique in selected cases.

Bearing in mind the “replace like with like” fundamentals, we introduce the “Scale Principle” in which the “autologous” should always outweigh the “prosthetic-heterologous” to achieve a natural, long-lasting reconstruction.

**Salvatore Tagliatalata Scafati, MD, FEBOPRAS**

Casa di Cura Malzoni – Villa dei Platani (Gruppo Neuromed)  
Via Carmelo Errico, 2  
83100 Avellino, Italy  
E-mail: salvataglia@gmail.com

## REFERENCES

- Champaneria MC, Wong WW, Hill ME, et al. The evolution of breast reconstruction: a historical perspective. *World J Surg.* 2012;36:730–742.
- Nahabedian MY. Achieving ideal breast aesthetics with autologous reconstruction. *Gland Surg.* 2015;4:134–144.
- Lindegren A, Halle M, Docherty Skogh AC, et al. Postmastectomy breast reconstruction in the irradiated breast: a comparative study of DIEP and latissimus dorsi flap outcome. *Plast Reconstr Surg.* 2012;130:10–18.
- Sacotte R, Fine N, Kim JY, et al. Assessing long-term complications in patients undergoing immediate postmastectomy breast reconstruction and adjuvant radiation. *Pract Radiat Oncol.* 2017;7:e91–e97.
- Spear SL, Shuck J, Hannan L, Albino F, Patel KM. Evaluating long-term outcomes following nipple-sparing mastectomy and reconstruction in the irradiated breast. *Plast Reconstr Surg.* 2014;133.5:605e–614e.
- Maxwell GP. Iginio Tansini and the origin of the latissimus dorsi musculocutaneous flap. *Plast Reconstr Surg.* 1980;65:686–692.
- Ribuffo D, Cigna E, Gerald GL, et al. Iginio Tansini revisited. *Eur Rev Med Pharmacol Sci.* 2015;19:2477–2481.
- Schneider WJ, Hill HL Jr, Brown RG. Latissimus dorsi myocutaneous flap for breast reconstruction. *Br J Plast Surg.* 1977;30:277–281.
- Maxwell GP, McGibbon BM, Hoopes JE. Vascular considerations in the use of a latissimus dorsi myocutaneous flap after a mastectomy with an axillary dissection. *Plast Reconstr Surg.* 1979;64:771–780.
- Olivari N. The latissimus flap. *Br J Plast Surg.* 1976;29:126–128.
- McCraw JB, Papp C, Edwards A, et al. The autogenous latissimus breast reconstruction. *Clin Plast Surg.* 1994;21:279–288.
- Delay E, Gounot N, Bouillot A, et al. Autologous latissimus breast reconstruction: a 3-year clinical experience with 100 patients. *Plast Reconstr Surg.* 1998;102:1461–1478.
- Hammond DC. Latissimus dorsi flap breast reconstruction. *Plast Reconstr Surg.* 2009;124:1055–1063.
- Hodgson EL, Malata CM. Implant-based breast reconstruction following mastectomy. *Breast Dis.* 2002;16:47–63.
- Perdikis G, Koonce S, Collis G, et al. Latissimus dorsi myocutaneous flap for breast reconstruction: bad rap or good flap? *Eplasty.* 2011;11:e39.
- Santanelli F, Laporta R, Sorotos M, Pagnoni M, Falesiedi F, Longo, B. Latissimus dorsi flap for total autologous immediate breast reconstruction without implants. *Plast Reconstr Surg.* 2014;134.6:871e–879e.
- Szychta P, Zadrozny M, Rykala J, et al. Autologous fat transfer to the subcutaneous tissue in the context of breast reconstructive procedures. *Postepy Dermatol Alergol.* 2016;33:323–328.
- Simonacci F, Bertozzi N, Grieco MP, et al. Autologous fat transplantation for breast reconstruction: a literature review. *Ann Med Surg (Lond).* 2016;12:94–100.
- Zhu L, Mohan AT, Vijayasekaran A, et al. Maximizing the volume of latissimus dorsi flap in autologous breast reconstruction with simultaneous multisite fat grafting. *Aesthet Surg J.* 2016;36:169–178.
- Delay E, Guerid S. The role of fat grafting in breast reconstruction. *Clin Plast Surg.* 2015;42:315–23, vii.
- Cheng A, Losken A. Essential elements of the preoperative breast reconstruction evaluation. *Gland Surg.* 2015;4:93–96.
- Voineskos SH, Frank SG, Cordeiro PG. Breast reconstruction following conservative mastectomies: predictors of complications and outcomes. *Gland Surg.* 2015;4:484–496.
- Bailey S, Saint-Cyr M, Zhang K, et al. Breast reconstruction with the latissimus dorsi flap: women’s preference for scar location. *Plast Reconstr Surg.* 2010;126:358–365.
- Rowland JH, Desmond KA, Meyerowitz BE, et al. Role of breast reconstructive surgery in physical and emotional outcomes among breast cancer survivors. *J Natl Cancer Inst.* 2000;92:1422–1429.
- Morrow M, Li Y, Alderman AK, et al. Access to breast reconstruction after mastectomy and patient perspectives on reconstruction decision making. *JAMA Surg.* 2014;149:1015–1021.
- Kronowitz SJ, Robb GL. Radiation therapy and breast reconstruction: a critical review of the literature. *Plast Reconstr Surg.* 2009;124:395–408.
- Blondeel PN. One hundred free DIEP flap breast reconstructions: a personal experience. *Br J Plast Surg.* 1999;52:104–111.
- Healy C, Allen RJ Sr. The evolution of perforator flap breast reconstruction: twenty years after the first DIEP flap. *J Reconstr Microsurg.* 2014;30:121–125.
- Hamdi M, Decorte T, Demuynck M, et al. Shoulder function after harvesting a thoracodorsal artery perforator flap. *Plast Reconstr Surg.* 2008;122:1111–1117; discussion 1118.
- Spear SL, Hess CL. A review of the biomechanical and functional changes in the shoulder following transfer of the latissimus dorsi muscles. *Plast Reconstr Surg.* 2005;115:2070–2073.
- de Oliveira RR, do Nascimento SL, Derchain SF, et al. Immediate breast reconstruction with a Latissimus dorsi flap has no detrimental effects on shoulder motion or postsurgical complications up to 1 year after surgery. *Plast Reconstr Surg.* 2013;131:673e–680e.
- Sinna R, Delay E, Garson S, et al. Breast fat grafting (lipomodelling) after extended latissimus dorsi flap breast reconstruction: a preliminary report of 200 consecutive cases. *J Plast Reconstr Aesthet Surg.* 2010;63:1769–1777.
- Feng J, Pardoe CI, Mota AM, et al. Two-stage latissimus dorsi flap with implant for unilateral breast reconstruction: getting the size right. *Arch Plast Surg.* 2016;43:197–203.
- Hokin JA. Mastectomy reconstruction without a prosthetic implant. *Plast Reconstr Surg.* 1983;72:810–818.
- Chang DW, Youssef A, Cha S, et al. Autologous breast reconstruction with the extended latissimus dorsi flap. *Plast Reconstr Surg.* 2002;110:751–759; discussion 760.
- Germann G, Steinau HU. Breast reconstruction with the extended latissimus dorsi flap. *Plast Reconstr Surg.* 1996;97:519–526.
- Kim H, Wiraatmadja ES, Lim SY, et al. Comparison of morbidity of donor site following pedicled muscle-sparing latissimus dorsi flap versus extended latissimus dorsi flap breast reconstruction. *J Plast Reconstr Aesthet Surg.* 2013;66:640–646.
- Losken A, Pinell XA, Sikoro K, et al. Autologous fat grafting in secondary breast reconstruction. *Ann Plast Surg.* 2011;66:518–522.
- Nahabedian MY. Implant-based breast reconstruction: strategies to achieve optimal outcomes and minimize complications. *J Surg Oncol.* 2016;113:895–905.