

Anterior Segment Optical Coherence Tomography Evaluation of a Dexamethasone Intravitreal Implant in the Crystalline Lens: A Case Report

Joana Santos-Oliveira ¹, Rita Teixeira-Martins ¹, Ana Margarida Ferreira ¹, João Paulo Macedo¹, Cláudia Oliveira-Ferreira ^{1,2}

¹Department of Ophthalmology, Centro Hospitalar Universitário de São João, Porto, Portugal; ²Department of Surgery and Physiology, Faculty of Medicine, University of Porto, Porto, Portugal

Correspondence: Joana Santos-Oliveira, Department of Ophthalmology, Centro Hospitalar Universitário de São João, Alameda Prof. Hernâni Monteiro, Porto, 4200-319, Portugal, Email joana.santos.oliveira@ulssjoao.min-saude.pt

Purpose: Ozurdex[®] is a dexamethasone intravitreal implant approved for the treatment of macular edema secondary to branch or central retinal vein occlusion, non-infectious uveitis affecting the posterior segment of the eye, and diabetic macular edema.

Patients and Methods: We report a case of an accidental injection of the implant into the crystalline lens, successfully managed by surgery afterwards. The case description is supported by Anterior Segment Optical Coherence Tomography (AS-OCT) images.

Results: A 69-year-old male was observed for bilateral diabetic macular edema. He had previously been treated with bevacizumab and aflibercept, with an incomplete anatomical response (<20% reduction in central macular thickness). The patient consented to undergo a bilateral intravitreal dexamethasone injection (dexamethasone intravitreal implant (0.7 mg)). The procedures were uneventful, except for an extensive conjunctival hemorrhage in the right eye. An appointment was scheduled for fifteen days later, however the patient missed it. Four months later, he referred OD vision loss, which occurred a few days after the injection, and the implant was found within the right crystalline lens. An AS-OCT was done to better understand the implant's location and entry point. Due to decreased visual acuity, the patient was scheduled for surgery. A phacoemulsification surgery with a three-piece hydrophobic intraocular lens implantation in the sulcus associated with anterior vitrectomy was done.

Conclusion: The injection of a dexamethasone implant is becoming increasingly common. Nonetheless, it must always be carried out carefully, to avoid complications. If the implant is accidentally injected into the crystalline lens, the AS-OCT can help determine its exact location, which is important for preparing the surgical plan and determining the appropriate timing.

Keywords: crystalline, intravitreal injections, lens, macular edema

Introduction

Ozurdex[®] is a dexamethasone intravitreal implant (0.7 mg) approved for the treatment of macular edema secondary to branch retinal vein occlusion (BRVO) or central retinal vein occlusion (CRVO), non-infectious uveitis involving the posterior segment of the eye and diabetic macular edema. Its injection procedure should be carried out with caution - The long axis of the applicator should be aligned parallel to the limbus and the sclera should be engaged at an oblique angle with the needle bevel facing upward to create a shelved scleral path; the needle tip is inserted and advanced within the sclera for about 1 mm (parallel to the limbus), then re-directed toward the center of the eye and advanced until penetration of the sclera is completed and the vitreous cavity is entered. Finally, the actuator button should be depressed slowly until an audible click is noted.¹

If the procedure steps are not followed correctly, complications can occur such as leakage through the injection site with subsequent chemosis and filtering bleb, retention of part of the implant at the entry site or the unintended placement of the implant into the crystalline lens.²⁻⁵

Materials and Methods

We report a case of an accidental injection of the implant into the crystalline lens successfully managed by surgery. To the best of our knowledge, this is the first published case supported by an anterior segment optical coherence tomography (AS-OCT) examination.

Written informed consent was obtained from the patient for publication of the details of their medical case and the accompanying images.

Results

A 69-year-old Caucasian male was observed in our diabetic retina department with bilateral diabetic macular edema. His medical history included diabetes mellitus (diagnosed ten years earlier), arterial hypertension, dyslipidemia, and benign prostatic hyperplasia. Additionally, his ophthalmologic history included left eye (OS) cataract surgery the previous year. His best-corrected visual acuity (BCVA) was 4/10 in the right eye (OD) and 5/10 in the left eye (OS). On biomicroscopy, he presented a nuclear sclerosis OD and intraocular lens OS. Intraocular pressure was 16 mmHg in both eyes (OU). For macular edema, he had previously been treated with bevacizumab (5 injections; 1.25 mg) and aflibercept (5 injections; 2 mg) with an incomplete anatomical response (<20% reduction in central macular thickness (CMT)). Fluorescein angiography revealed no ischemia in the peripheral retina OU. Optical coherence tomography (OCT) revealed a CMT of 371 μm in the OD and 475 μm in the OS. After discussing the risks and benefits of intravitreal dexamethasone injection (Ozurdex® - dexamethasone intravitreal implant (0.7 mg)), the patient agreed to proceed. The injections were performed in both eyes three days apart under a surgical microscope in the operating room. The injections were administered by an experienced attending, under local anesthesia with topical oxybuprocaine (4 mg/mL) and after disinfection of the periocular skin with 10% povidone-iodine solution and the ocular surface with 5% povidone-iodine. Local anesthesia was supplemented with a subconjunctival injection of 2% lidocaine. The injection site was marked on the inferotemporal sclera, 4.0 mm OD (phakic eye) and 3.5 mm OS (pseudophakic eye) from the limbus. Paracentesis was not required to reduce intraocular pressure. After the injection, topical 5% povidone-iodine was reapplied to the conjunctival cul-de-sac. The procedures were uneventful, except for an extensive conjunctival hemorrhage OD. An appointment was scheduled fifteen days later to assess his intraocular pressure, but the patient missed it.

Four months later, at the rescheduled appointment, the patient referred OD vision loss (from 4/10 to 2/10), which occurred a few days after the injection. On the slit-lamp observation, under pharmacological mydriasis, the implant was found in the right crystalline lens, in the pupillary area (Figure 1a and b). The cataract was more advanced around the implant. The cornea remained transparent, with no inflammation observed in the anterior chamber, and the intraocular pressure was normal. The retinal OCT showed an improvement of macular edema (Figure 2a and b) in the OD, but not in the OS. An AS-OCT (Spectralis Heidelberg Engineering) was performed to better understand the location of the implant, its entry point and the non-integrity of the posterior capsule (Figure 3a–c).

Due to decreased visual acuity (VA), caused by the cataract progression and the implant's position in the visual axis, the patient was scheduled for surgery. One week later, a phacoemulsification surgery with a three-piece hydrophobic intraocular lens (Alcon AcrySof® MA60AC) implantation in the sulcus, associated with anterior vitrectomy was completed (Figure 4). No lens fragments dropped during surgery. Hydro-dissection and hydro-delamination were avoided to prevent exacerbation of the suspected posterior capsular rupture. The repositioning of the implant into the vitreous cavity was unsuccessful, as the implant was friable and subsequently could not be grasped. As a result, the implant was aspirated during surgery.

The patient had an uncomplicated post-operative recovery. One month after the surgery his OD BCVA was 9/10 and the OCT demonstrated the same CMT as before surgery.

Discussion

Nowadays, AS-OCT has become an essential tool for assessing the anterior segment of the eye. Its applications include comprehensive evaluations of the ocular surface and cornea, the anterior chamber, the angle, the sclera, the limbus, the

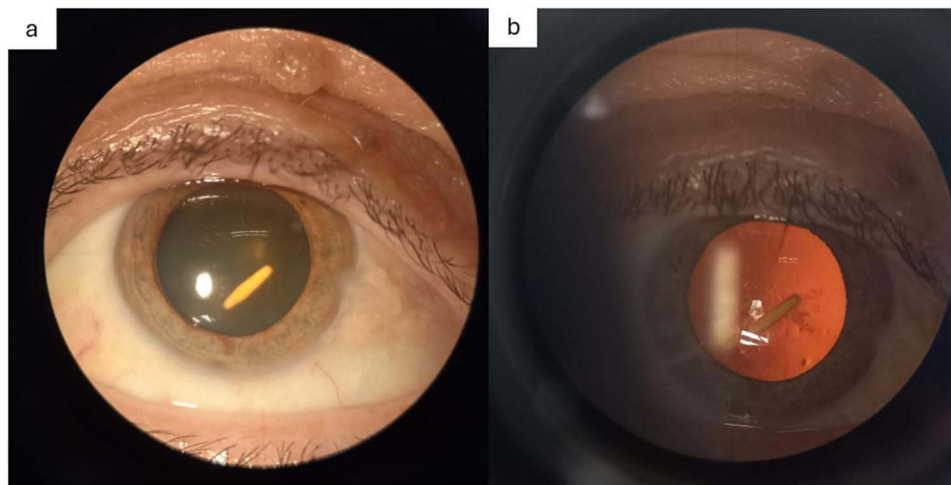


Figure 1 Slit-lamp photograph of the biomicroscopy of the right eye showing intra-lens dexamethasone implant - diffuse illumination (a) and fundus retro-illumination (b).

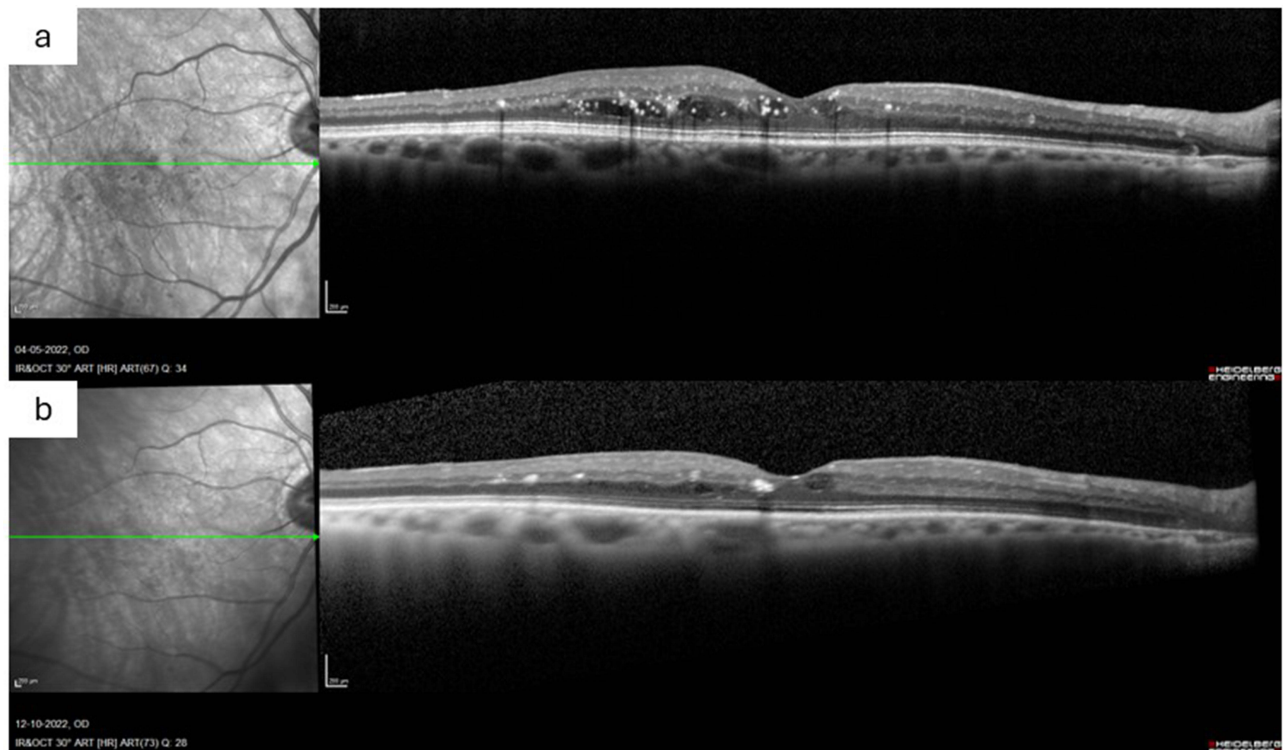


Figure 2 (a) – Right eye macular OCT before the intravitreal implant injection. (b) – Right eye macular OCT four months after the intravitreal implant injection (before surgery).

extraocular muscles and even the vascular supply of the anterior segment. Additionally, the lens is another structure that can be evaluated using this technology. The advantage of AS-OCT lies in its ability to provide rapid, non-invasive, and in vivo imaging of the eye's structures.⁶

In our case, AS-OCT proved to be a valuable resource, providing precise information about the location of the implant within the lens and its entry point, as well as insights into the condition of the posterior capsule. This information helped the surgeon in determining the necessary adjustments for a successful surgery.

The detail provided by AS-OCT images is clearly superior to that of a B-scan.⁷ In our research, we did not find any other documented cases that included AS-OCT images.

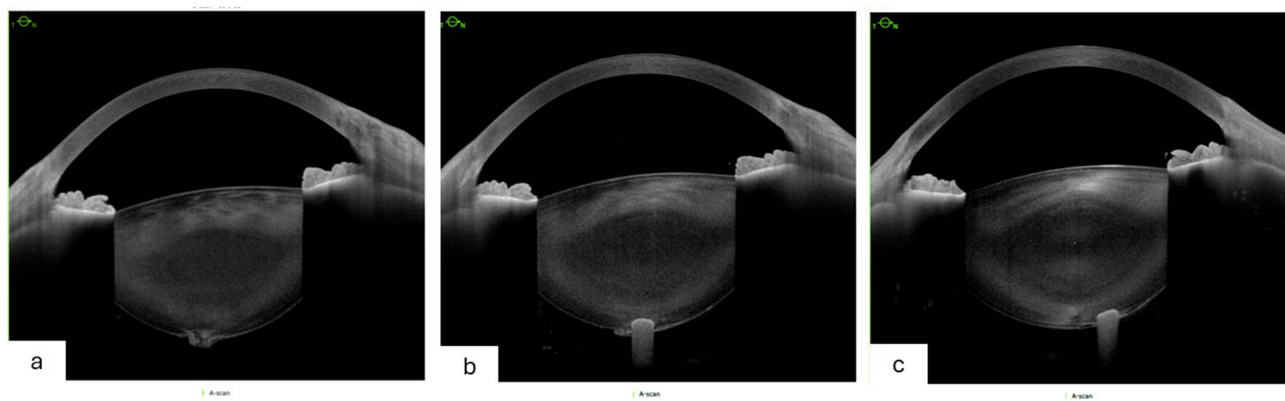


Figure 3 (a–c) – AS-OCT exam reveals the exact location of the implant and the non-integrity of the posterior capsule.

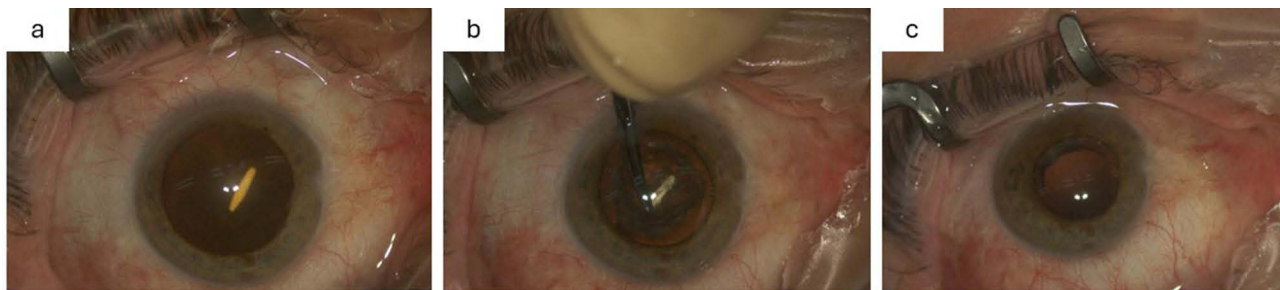


Figure 4 Images from the surgery – (a) - The implant in the crystalline lens; (b) - Unsuccessful attempt to remove the implant *en bloc*; (c) - Posterior capsule rupture.

Ozurdex[®] (Allergan Inc., Irvine, CA, USA) is a disposable injection device containing a rod-shaped implant of dexamethasone (0.7 mg), which is approximately 0.46 mm in diameter and 6 mm in length. The muzzle velocity of the injection has been calculated as 0.8 m/s.^{1,8} This implant is associated with increased intraocular pressure, steroid-induced glaucoma, onset and progression of cataract, and secondary ocular infections. The injection itself has also been linked to risks, such as conjunctival hemorrhage, leakage with consecutive chemosis and filtering bleb, retention of part of the implant at the entry site, retinal detachment, vitreous hemorrhage, implant migration into the anterior chamber, and endophthalmitis.^{1–5} In addition to those, accidental intra-lens injection is a rare complication that has been previously described.^{3,5,9,10} It can be caused by the surgeon's flawed technique and/or poor patient cooperation.

The decision to wait-and-see or to operate early depends on a case-by-case basis. It can happen that the implant is not in the visual axis, the crystalline lens remains stable and macular edema improves, probably because the implant can be partially in contact with the vitreous.^{3,9,10}

In our case, due to the decreasing VA, the patient was scheduled for surgery. Hydro-dissection was not performed, but hydro-delamination could have been carried out gently. However, as it was a soft cataract, neither procedure was performed.

In Regan et al, cataract surgery was done twelve months after the injection and during surgery no capsular defect was noted and no vitreous was encountered. It seems that there was a healing fibrous process of the posterior capsule, which may have made the cataract surgery safer. In fact, this may be another reason to postpone surgery if the patient's clinical condition does not worsen.¹⁰

Baskan et al reported a case of a 70-year-old patient with central retinal vein occlusion who had a dexamethasone implant accidentally injected into the crystalline lens. Its exact position was determined using the OCULUS Pentacam[®] and they decided to perform a phacoemulsification surgery due to the presence of a posterior subcapsular cataract. Curiously, the implant remained with minimal changes fourteen months after the injection, possibly due to posterior capsular fibrosis and its

intra-lens localization. The lack of contact between the implant and the vitreous may result in unsatisfactory therapeutic efficacy.¹¹

Another surgical option could have been a vitrectomy with lensectomy. This option was suggested by Pintor et al, who argued that they were able to preserve the entire implant and place it in the vitreous cavity, with a reduced risk of damage to the endothelium, and the possibility of removing the vitreous body, an important vascular endothelial growth factor deposit.¹² On the contrary, the removal of the vitreous body may reduce the time of action of the anti-VEGF drugs.¹³

Conclusion

The injection of the dexamethasone implant has become increasingly common. Nonetheless, it must always be carried out carefully to avoid complications. If the implant is found in the crystalline lens, the AS-OCT can help determine its exact location, which is important for preparing the surgical plan and determining the appropriate timing.

Abbreviations

AS-OCT, Anterior Segment Optical Coherence Tomography; BRVO, branch retinal vein occlusion; CRVO, central retinal vein occlusion; BCVA, best-corrected visual acuity; OD, right eye; OS, left eye; OU, both eyes; CMT, central macular thickness; OCT, Optical Coherence Tomography; VA, visual acuity.

Statement of Ethics

The study was performed in accordance with the Helsinki Declaration of 1964. This retrospective review of patient data did not require approval by the ethics committee of Centro Hospitalar Universitário de São João to publish. Written informed consent was obtained from the patient for publication of the details of the medical case and the accompanying images.

Disclosure

The authors report no conflicts of interest in this work.

References

1. Ozurdex. Product Information EMA. Available from: https://www.ema.europa.eu/en/documents/product-information/ozurdex-epar-product-information_en.pdf. Accessed July 12, 2024..
2. Celik N, Khoramnia R, Auffarth GU, Sel S, Mayer CS. Complications of dexamethasone implants: risk factors, prevention, and clinical management. *Int J Ophthalmol*. 2020;13(10):1612–1620. doi:10.18240/ijo.2020.10.16
3. Ertan E, Duman R, Duman R, Doğan M. Dexamethasone intravitreal implant in the crystalline lens: a case report. *Arquivos Brasileiros de Oftalmologia*. 2020;83:242–245. doi:10.5935/0004-2749.20200065
4. Sborgia G, Niro A, D’Oria F, et al. Surgical management of complications after dexamethasone implant. *Case Rep Ophthalmol Med*. 2020;2020:1–5.
5. Kurt A, Durukan AH, Küçükcüoğlu M. Accidental intralenticular injection of ozurdex® for branch retinal vein occlusion: intact posterior capsule and resolution of macular edema. *Case Rep Ophthalmol Med*. 2019;2019:1–4.
6. Ang M, Baskaran M, Werkmeister RM, et al. Anterior segment optical coherence tomography. *Prog Retin Eye Res*. 2018;66:132–156. PMID: 29635068. doi:10.1016/j.preteyeres.2018.04.002
7. Roy M, Maiti A, das S, das SS. Inadvertent intralenticular Ozurdex removal. *Oman J Ophthalmol*. 2022;15(1):119–120. doi:10.4103/ojo.ojo_144_21
8. Meyer CH, Klein A, Alten F, et al. Release and velocity of micronized dexamethasone implants with an intravitreal drug delivery system kinematic analysis with a high-speed camera [Internet]. *Retina*. 2012;32(10):2133–2140. doi:10.1097/IAE.0b013e31825699e5
9. Chhabra R, Kopsidas K, Mahmood S. Accidental insertion of dexamethasone implant into the crystalline lens - 12 months follow-up. *Eye*. 2014;28:624–625. doi:10.1038/eye.2014.18
10. Regan KA, Blake CR, Lukowski ZL, Iyer SSR. Intralenticular ozurdex® - One year later. *Case Rep Ophthalmol*. 2017;8(3):590–594. doi:10.1159/000485318
11. Baskan B, Cicek A, Gulhan A, Gundogan M, Goktas S. Ozurdex completely located inside a crystallized lens - results of 14 months. *Am J Ophthalmol Case Rep*. 2016;4:38–40. doi:10.1016/j.ajoc.2016.08.001
12. Siotto Pintor E, Demarinis G, Tatti F, Peiretti E. Management of accidental intravitreal dexamethasone injection into the lens: a case report. *Cureus*. 2023. doi:10.7759/cureus.36216
13. Edington M, Connolly J, Chong NV. Pharmacokinetics of intravitreal anti-VEGF drugs in vitrectomized versus non-vitrectomized eyes. *Expert Opin Drug Metab Toxicol*. 2017;13(12):1217–1224. PMID: 29134820. doi:10.1080/17425255.2017.1404987

International Medical Case Reports Journal**Publish your work in this journal**

The International Medical Case Reports Journal is an international, peer-reviewed open-access journal publishing original case reports from all medical specialties. Previously unpublished medical posters are also accepted relating to any area of clinical or preclinical science. Submissions should not normally exceed 2,000 words or 4 published pages including figures, diagrams and references. The manuscript management system is completely online and includes a very quick and fair peer-review system, which is all easy to use. Visit <http://www.dovepress.com/testimonials.php> to read real quotes from published authors.

Submit your manuscript here: <https://www.dovepress.com/international-medical-case-reports-journal-journal>

Dovepress

Taylor & Francis Group