

Case Series

Renal Transplant Hydroureteronephrosis as a Manifestation of Rejection: An Under-Recognized Entity?

Ratna Acharya^a Rasha Aly^b Kiran Upadhyay^b

^aDivision of General Pediatrics, Department of Pediatrics, University of Florida, Gainesville, FL, USA; ^bDivision of Pediatric Nephrology, Department of Pediatrics, University of Florida, Gainesville, FL, USA

Keywords

Hydroureteronephrosis · Transplant · Rejection

Abstract

Hydroureteronephrosis (HUN) of the renal transplant (RT) can be obstructive or non-obstructive, refluxing or non-refluxing, and can cause allograft dysfunction. HUN of the RT as a manifestation of rejection is uncommon and has not been described in children. We describe two pediatric RT recipients who presented with late-onset HUN, 5 and 10 years after transplantation. Both had new-onset HUN which occurred at the time of rejection; HUN resolved in both patients after treatment of rejection. Renal function stabilized in both patients without the need for stent or nephrostomy tube placement. There was no obstruction or vesicoureteral reflux (VUR). Edema of the uroepithelial cells leading to transient obstruction causing HUN is a most likely explanation. We conclude that treatment of rejection in patients without obstruction or VUR may lead to resolution of HUN without the need for urological interventions.

© 2021 The Author(s)
Published by S. Karger AG, Basel

Introduction

Hydroureteronephrosis (HUN) of renal transplant (RT) can occur secondary to ureteral obstruction or vesicoureteral reflux (VUR) [1, 2]. However, secondary megaureter of various etiologies, neurogenic bladder, loss of ureteral tonicity following denervation, and polyuric states can also present with non-obstructive non-refluxing transplant HUN [3]. Allograft HUN has been correlated with worsening renal function and increased incidence of pyelonephritis and rejection [1]. Mercurioacetyltriglycine-3 (MAG-3) renography is a useful test to differentiate obstructive versus non-obstructive HUN of the allograft. Rejection of RT as a cause of non-obstructive non-refluxing HUN is not a well-known entity. In this report, we describe two RT recipients with predominantly antibody-mediated rejection (ABMR), who presented with such manifestation.

Case Presentation

Case 1

An 11-year-old morbidly obese African American boy received a preemptive deceased donor RT with single renal artery and ureter for end-stage renal disease (ESRD) secondary to posterior urethral valves (PUV) 10 years ago. Non-antireflux ureteroneocystostomy was performed with ureteral stent placement. Graft function was immediate. Initial immunosuppression (IS) regimen consisted of tacrolimus, mycophenolate mofetil (MMF), and prednisone. He was treated for several episodes of transplant pyelonephritis in the first 3 years after RT along with an episode of steroid-sensitive cellular rejection 1 year post-RT. He had PUV ablation and vesicostomy closure a year after the RT. He had native kidneys in situ and the most recent sonogram 8 months ago had not shown allograft HUN. Current IS regimen consisted of sirolimus and MMF. He presented with abrupt rise in serum creatinine of 2.5 mg/dL from a baseline of 1 mg/dL. Urine output was normal. Serum electrolytes including sodium and glucose were normal. Viral surveillance including serum BK virus deoxyribonucleic acid (DNA) polymerase chain reaction (PCR) was negative. Urine culture was negative. Sonogram showed moderate to severe allograft HUN without calculus, normal resistive indices, and absence of significant post-void residual (Fig. 1a, b). Urethral catheter was placed for 7 days with only mild improvement in HUN. Voiding cystourethrography showed no evidence of VUR (Fig. 2). A diuretic nuclear renogram with urinary catheter in situ showed a mildly decreased allograft perfusion, no significant spontaneous drainage of MAG-3 but prompt response to gravity and diuretic with post-diuretic half time of 12 min (Fig. 3a–d). Donor specific antibodies (DSA) were positive (single antigen bead, luminex) for DQ5 (>15,000 mean fluorescent intensity [MFI]), DQ2 (3,000 MFI), and DR53 (4,000 MFI). Due to the HUN, allograft biopsy was not initially performed; however, he was presumptively treated for ABMR with pulse steroid, plasma exchange, intravenous immunoglobulin (IVIG), and rituximab. Post-treatment, a computed tomogram-guided biopsy showed evidence of borderline cellular rejection, a focal mild peritubular capillaritis, negative C4d deposition in the peritubular capillaries (PTC), intact podocyte foot processes, and basement membrane multi-lamination in few PTC. No urological intervention was required. At discharge, serum creatinine was 1.3 mg/dL, urine output was 2–

3 L daily without urethral catheter, and the HUN had improved. Discharge IS consisted of sirolimus, MMF, and prednisone. Mild HUN persisted upon follow-up at 4 weeks, which resolved completely at 8 weeks without the need for urological intervention such as ureteral stent or nephrostomy tube placement. Allograft function was stable with serum creatinine of 1.2 mg/dL.

Case 2

An 8-year-old obese African American boy underwent a preemptive deceased donor RT for ESRD secondary to PUV 5 years ago. Non-antireflux ureteroneocystostomy of a single transplant ureter with ureteral stent placement was done. There was an immediate graft function. IS consisted of tacrolimus, MMF, and steroid. His vesicostomy was closed and PUV was ablated at 19 months of age. There were no episodes of transplant pyelonephritis. Two years post-RT, he was treated for ABMR with pulse steroid, plasmapheresis, IVIG, and rituximab. Baseline allograft sonogram showed no HUN. Four years post-RT, he presented with an asymptomatic rise in serum creatinine from a baseline of 0.8–2.2 mg/dL, with stable serum electrolytes. Viral PCRs were negative. Allograft sonogram showed a new-onset moderate HUN without calculus; post-void residual bladder volume was minimal. Urine output was normal. Urethral catheterization was not required. Voiding cystourethrography and diuretic renogram were not done. DSA were positive for DQ5 (>15,000 MFI), DPA1 (7,000 MFI), DP3 (3,000 MFI), and B7 (4,000 MFI). Allograft biopsy showed mild glomerulitis, peritubular capillaritis, PTC C4d deposition, mild to moderate intimal thickening of the small arteries without vasculitis, interstitial fibrosis (30–40%), and global glomerulosclerosis (30%). He was treated with pulse steroid, IVIG, and four doses of rituximab. Subsequent DSA 3 months later showed very weak DQ5 (3,000 MFI). One year later, serum creatinine has remained stable at 1.2 mg/dL with absence of HUN.

Discussion

The incidence of transplant ureter complications including stenosis ranges from 3 to 10% [4]. Early ureteral obstruction secondary to postoperative edema, torsion or kink, extrinsic compression from hematoma or lymphocele, difficult or faulty ureteral implantation, or tenuous blood supply leading to ischemia of the distal ureter can all lead to allograft HUN. Late ureteral stenosis, usually beyond the first month post-RT, could be related to ischemic fibrosis due to persistently deficient blood supply, decreased ureteral tone due to denervation, vasoconstriction due to calcineurin inhibitors, ureterolithiasis, and infection due to CMV and BK virus [5].

Late rejection occurring in association with non-obstructive non-refluxing transplant HUN has been described only in few studies (Table 1). Faenza et al. [6] observed ureteral stenosis leading to obstructive HUN in 27 out of 869 RT recipients, with acute and chronic rejections as most probable etiologies in 15 patients; six had rejection between 2 and 12 months, six between 1 and 2 years and three after 2 years post-RT. Rigg et al. [7], in their study of 1,016 RT recipients, described several patients with marked ureteral dilatation associated with acute rejection and the resolution of dilatation after treatment with anti-rejection agents.

More patients with ureteral obstruction had two or more episodes of rejection as compared to those without obstruction ($p = 0.03$). These studies did not provide information on whether VUR was present or not. Similarly, Maier et al. [8] described two adult RT recipients with late-onset HUN (14 and 18 years post-RT) secondary to ureteral stenosis; both had rejection episodes 1 and 10 months before and had been successfully treated. Histological examination of the ureter showed thickened ureteral wall due to fibrosis along with inflammatory infiltrates in the lamina propria, epithelium, and muscle layer along with endothelialitis of the vessels; the latter findings were strongly suggestive of rejection. Antegrade pyelography showed pre-vesical ureteral stenosis; both patients were treated with resection of stenosis and ureteral reimplantation.

The most likely explanation of HUN is that, in addition to the renal tubulointerstitial cells, rejection episodes can lead to edema of the uroepithelial cells as well, leading to transient obstruction. This edema along with the narrowing of the blood vessels due to thrombosis, mainly seen in vascular rejection, may also cause ischemic damage to the uroepithelial cells. With severe or repeated episodes of rejections, subsequent fibrotic reactions and loss of ureteral elasticity may occur leading to anatomic stenosis. As seen in the study by Maier et al. [8], the ureteral stenosis may happen despite successful treatment of prior rejection and a recurrent or chronic ureteral rejection can also occur. In our patients, the ureteral histology could not be obtained due to the risk associated with the procedure, especially since the renal function stabilized with treatment of rejection and the HUN resolved completely during follow-up. In addition, the absence of obstruction in the MAG-3 scan indicated that transient ureteral edema/ischemia secondary to rejection most likely was the cause of HUN in these patients. However, a close vigilance with repeat sonograms is necessary for potential recurrence of HUN from chronic or recurrent ureteral rejection leading to ureteral fibrosis and anatomic stenosis as seen in the report by Maier et al. [8].

There appears to be some similarities between the two cases described in this report: both patients were male, African American, and obese; etiology of ESRD was PUV; both were transplanted at very young age; both had late-onset HUN (4 and 10 years post-RT), which occurred at the time of rejection, and did not have prior HUN; had prior rejection episodes (2 and 9 years prior), and both seemed to have predominantly ABMR at the time of presentation with HUN. Given only two patients, we are unable to determine a definite cause and effect relationship among these variables and HUN but there may be an association. Also, due to the unavailability of ureteral histology, HUN secondary to the ureteral edema/ischemia from rejection merely remains a speculation at this time. In addition, whether there is a relationship between specific immunosuppressive therapy and development of this functional obstruction is unclear and needs to be studied further in larger studies.

Conclusion

The improvement in renal function and resolution of HUN with treatment of rejection along with absence of obstruction and VUR suggests that HUN seen at the time of rejection could be secondary to concurrent ureteral rejection leading to edema or ischemia. Knowledge

of such is important in avoidance of unnecessary surgical procedures. Larger studies are necessary to establish a causal relationship between ureteral rejection and HUN.

Statement of Ethics

The family of the patients gave written informed consent for publication of the cases including publication of images. This case study was conducted ethically in accordance with the World Medical Association Declaration of Helsinki.

Conflict of Interest Statement

The authors have no conflicts of interest to declare.

Funding Sources

The authors received no specific funding for this work.

Author Contributions

R. Aly and K. Upadhyay contributed to patient care. R. Acharya, R. Aly, and K. Upadhyay contributed to the writing of the manuscript. K. Upadhyay contributed to the critical revision of the manuscript.

References

- 1 Chu L, Jacobs BL, Schwen Z, Schneck FX. Hydronephrosis in pediatric kidney transplant: clinical relevance to graft outcome. *J Pediatr Urol*. 2013 Apr;9(2):217–22.
- 2 Wu HY, Concepcion W, Grimm PC. When does vesicoureteral reflux in pediatric kidney transplant patients need treatment? *Pediatr Transplant*. 2018 Dec;22(8):e13299.
- 3 Wu CQ, Franco I. Management of vesicoureteral reflux in neurogenic bladder. *Investig Clin Urol*. 2017 Jun;58(Suppl 1): S54–S58.
- 4 Keller H, Nöldge G, Wilms H, Kirste G. Incidence, diagnosis, and treatment of ureteric stenosis in 1298 renal transplant patients. *Transpl Int*. 1994 Jul;7(4):253–7.
- 5 Karam G, Hétet JF, Maillet F, Rigaud J, Hourmant M, Soullou JP, et al. Late ureteral stenosis following renal transplantation: risk factors and impact on patient and graft survival. *Am J Transplant*. 2006 Feb;6(2):352–6.
- 6 Faenza A, Nardo B, Catena F, Scolari MP, d’Arcangelo GL, Buscaroli A, et al. Ureteral stenosis after kidney transplantation. A study on 869 consecutive transplants. *Transpl Int*. 1999;12(5):334–40.
- 7 Rigg KM, Proud G, Taylor RM. Urological complications following renal transplantation. A study of 1016 consecutive transplants from a single centre. *Transpl Int*. 1994;7(2):120–6.
- 8 Maier U, Madersbacher S, Banyai-Falger S, Susani M, Grünberger T. Late ureteral obstruction after kidney transplantation. Fibrotic answer to previous rejection? *Transpl Int*. 1997;10(1):65–8.

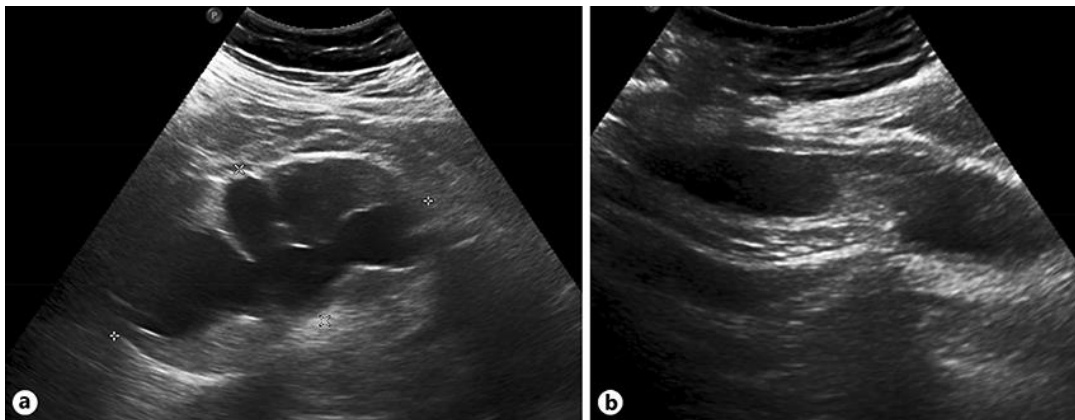


Fig. 1. **a** Renal transplant sonogram showing allograft hydronephrosis. **b** Sonogram of the ureter showing dilated transplant ureter.

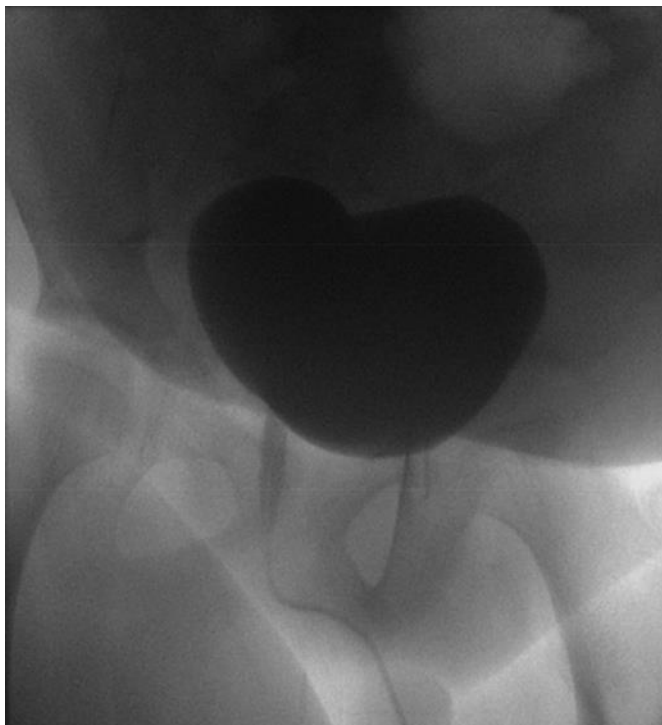


Fig. 2. Voiding cystourethrogram showing no vesicoureteral reflux.

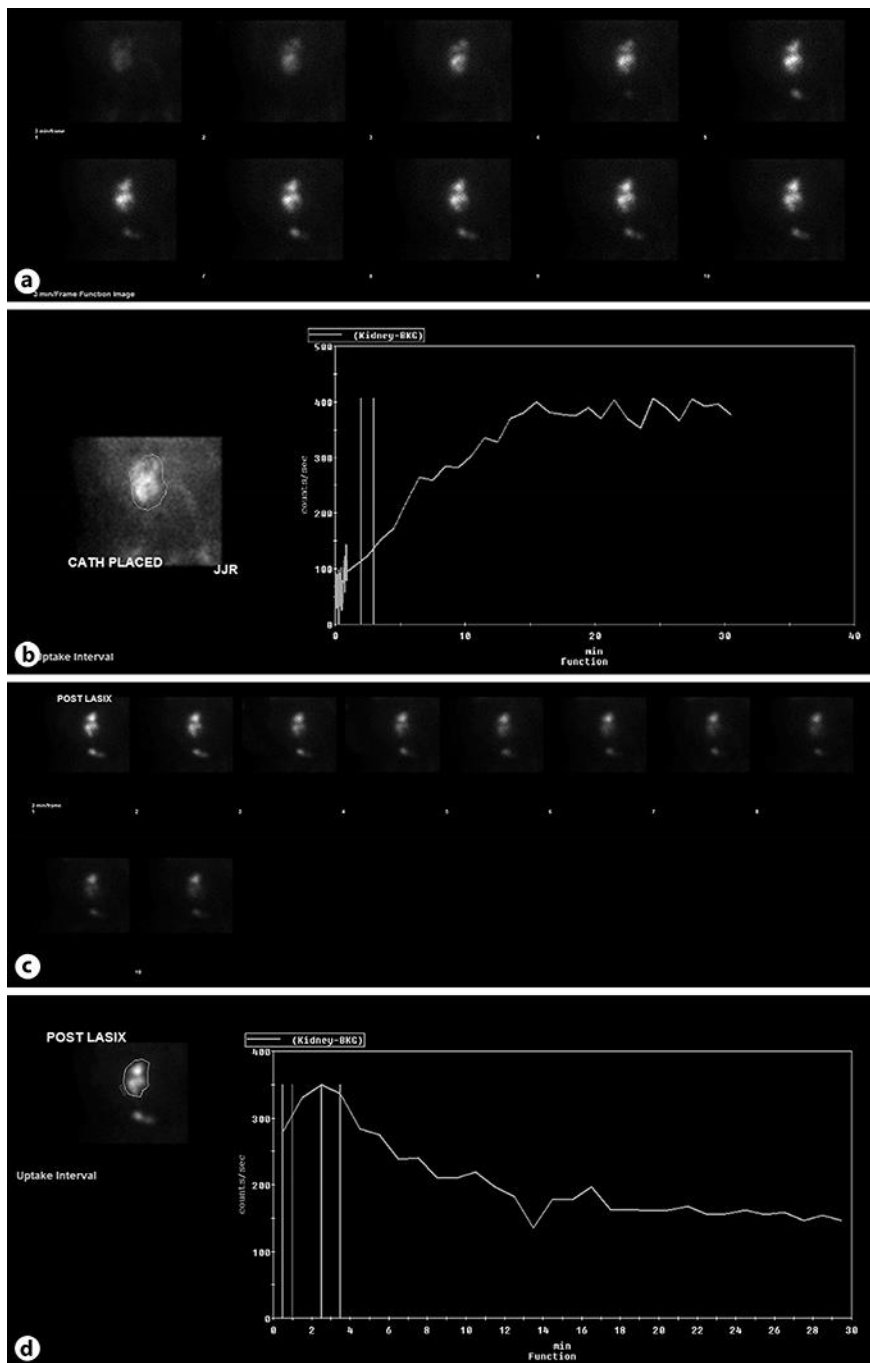


Fig. 3. **a** MAG-3 nuclear renal scan showing the pre-diuretic function images. There is no significant spontaneous drainage of the radiotracer to the bladder. **b** MAG-3 nuclear renal scan showing the pre-diuretic function curve. There is no significant spontaneous drainage of the radiotracer. The *x* axis is labelled as radiotracer activity in counts/s, and the *y* axis is labelled as time in minutes following the infusion of the radiotracer (30 min pre-diuretic renogram). **c** MAG-3 nuclear renal scan showing the post-diuretic function images. There is a prompt response to the diuretic with significant drainage of the radiotracer to the bladder. **d** MAG-3 nuclear renal scan showing the post-diuretic function curve. There is a prompt response to the diuretic with significant drainage of the radiotracer. The *x* axis is labelled as radiotracer activity in counts/s, and the *y* axis is labelled as time in minutes following the administration of the diuretic (30 min post-diuretic imaging).

Table 1. Studies among renal transplant recipients demonstrating presence of hydroureteronephrosis in association with rejection of renal transplant

Study	HUN of renal transplant	Rejection	Treatment
Faenza et al. [6]	27 out of 869 RT recipients; 2 months to 12 years post RT	15 (12 acute rejections, 3 chronic rejections)	Ureteral reimplantation, stent
Rigg et al. [7]	126 episodes of HUN out of 1,016 RT recipients; up to 12 years post RT	38 rejection episodes	Anti-rejection treatment led to HUN resolution in some; some had urologic interventions
Maier et al. [8]	2 RT recipients; 14–18 years post RT	Both had rejection 1 and 10 months prior; histology showed evidence of ureteral rejection	Resection of stenosis and ureteral reimplantation