

CASE REPORT

A novel mutation in the glutaryl-CoA dehydrogenase gene (GCDH) in an Iranian patient affected with Glutaric acidemia type 1

Sima Rayat¹  | Saeid Morovvati²

¹Department of Biology, Science and Research Branch, Islamic Azad University, Tehran, Iran

²Department of Genetics, Islamic Azad University, Tehran Medical Sciences Branch, Tehran, Iran

Correspondence

Saeid Morovvati, Department of Genetics, Faculty of Advanced Sciences and Technology, Tehran Medical Sciences, Islamic Azad University, Tehran, Zargandeh St., 19395/1495, Iran.
Email: morovvati@iautmu.ac.ir

Funding information

None

Abstract

Our findings revealed the mutation c.536T>C (p. Leu179Pro) in GCDH gene although has not been reported so far, but the in-silico analysis and clinical symptoms of the patient indicated that the mutation is pathogenic full stop. Also, it can be diagnosed and prevented in families affected by the disease.

KEYWORDS

GCDH, Glutaric acidemia type 1, mutation, Novel

1 | INTRODUCTION

Glutaric Acidemia type 1 (GA1) is an autosomal recessive disorder, in which a mutation in the *GCDH* gene disrupts the catalytic activity of glutaryl-CoA, leading to buildup of lysine, hydroxylysine, and tryptophan amino acids and their intermediates in blood, urine, and tissues, especially the brain, causing toxic damage. Intermediate products, such as glutaric acid, accumulate in body fluids, and symptoms appear. A couple with a consanguineous marriage had a son with anorexia, insomnia, subdural hygroma, speech and walking impairment, learning disability, excessive sweating, vomiting, and macrocephaly, which finally led to his death at an age of 4 years. Given the clinical signs of GA, genetic tests were performed on his parents. In the father sample in which *GCDH*, *ETFA*, *ETFB*, and *ETFDH* genes were analyzed using the NGS method, a novel mutation, NM_000159.4: c.536T>C;

(p. Leu179Pro), was found in the *GCDH* gene in a heterozygous state. In the mother, this mutation was confirmed in a heterozygous state by the Sanger method. Although the mutation c.536T>C; (p. Leu179Pro) in the *GCDH* gene has not been reported so far, the in-silico analysis and clinical symptoms of the patient indicated that the mutation was pathogenic.

A large group of genetic diseases belong to inherited metabolic diseases (IMDs), the prevalence of which is estimated to be one out of 1,500 people in all kinds of these diseases. One of the most important class of this classification are organic acidurias (OAs), which are caused by defects in intermediary metabolic pathways of carbohydrate, amino acid, and fatty acid oxidation. Continuation of this process leads to the accumulation of organic acids in the tissues and eventually its excretion through the urine.¹ So far, more than 100 different types of organic acids have been found in urine, such as propionic aciduria

This is an open access article under the terms of the Creative Commons Attribution-NonCommercial-NoDerivs License, which permits use and distribution in any medium, provided the original work is properly cited, the use is non-commercial and no modifications or adaptations are made.

© 2021 The Authors. *Clinical Case Reports* published by John Wiley & Sons Ltd.

(PA), methylmalonic aciduria (MMA), branched chain organic aciduria, glutaric acidurias (GAs), and multiple carboxylase deficiencies.^{2,3} Glutaric acidurias are a branch of the OADs group that includes three different types caused by different genetic mutations. Glutaric Acidemia type 1 (GA1, OMIM # 231670) is an autosomal recessive disorder characterized by gliosis, neuronal damage in basal ganglia, and progressive movement disorder that usually begins in the first year of life. However, the main clinical manifestation of GA1 is extrapyramidal movement disorder, caused by acute striatal necrosis. Glutaric acidemia type 1 is a congenital disorder caused by a mutation in the *GCDH* gene (NM_000159.4), which is located on the chromosome 19p13.2 spanning about 7kb and contains 11 exons.⁴ The gene product is a polypeptide of 438 amino acids, of which 44 N-terminal residues are removed after mitochondrial import.² The defect in the glutaryl-CoA dehydrogenase enzyme (NP_000150.1), which is encoded by this gene, results in the lack of the enzyme ability to decompose lysine (Lys), L-hydroxylysine, and L-tryptophan (Trp). Continuation of this process leads to an increase in the concentrations of glutaric acid (GA), 3-hydroxy-glutaric acid (3HG), and glutaryl carnitine (C5DC) in the tissues and body fluids of patients.^{2,5} The incidence is one case per 110,000 live births.⁶ Pathogenic mutations in the human genome mutation database (HGMD; www.hgmd.cf.ac.uk). In this study, we report a consanguineous Iranian family in which a novel variant of the *GCDH* gene causes GA1.

2 | CASE PRESENTATION

A consanguineous couple was referred to the Rasad genetic counseling center (Tehran, Iran) with a familial relationship (Figure 1). In the first pregnancy, they had a son with normal weight and normal head circumference at birth. By 5 months of age, the infant's health condition was satisfactory. The first symptom began at 5 months of age with febrile convulsion, and he was hospitalized. The second time attack began with lethargy at the age of one year, and he was readmitted and treated. He was followed up and other symptoms, such as insomnia, subdural hygroma, speech, walking and learning impairment, macrocephaly, micropenis, excessive sweating, and vomiting, and appeared over time. Moreover, he contracted his arms and legs due to dystonia that involved all the muscles of the body. The occurrence of attacks lasted until the age of 4 years when the child died. Regarding the symptoms of GA1 in the patient, it was impossible to perform the genetic analysis in the dead affected child. Thus, a genetic study of the genes involved in GA1, including *GCDH*, *ETFA*, *ETFB*, and *ETFDH*, was performed on the father's

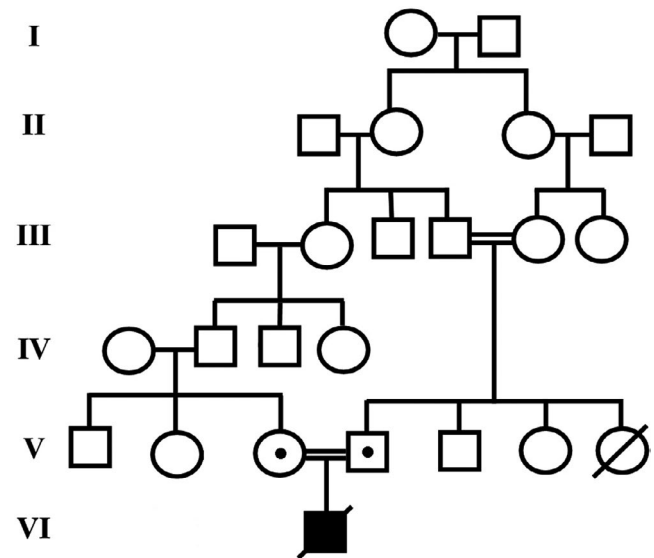


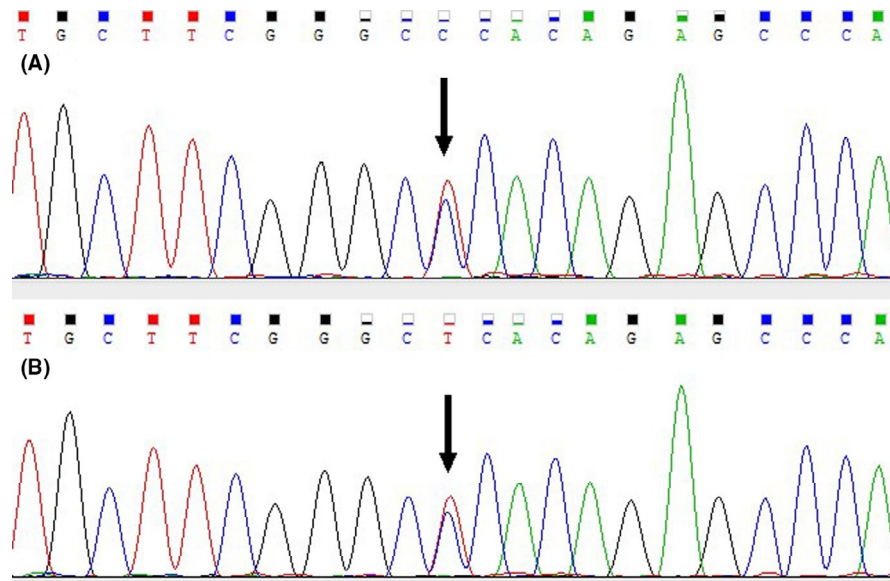
FIGURE 1 Pedigree chart of the family with a child with glutaric acidemia type one

sample using the NGS method, and the mutation c.536T>C (p. Leu179Pro) was found in the heterozygous *GCDH* gene. This new mutation, located at Exon 7, has not been reported until now. Polyphen, SIFT, and the Mutation Taster software showed the pathogenicity of this mutation. According to the variant assessments (including the type of this variant, population frequency, and bioinformatics analysis) and based on the ACMG guideline, this variant can be classified as a likely pathogenic mutation. To confirm the mutation and mother's carrier, the Sanger method was used by primer sequences as follows F: CGC CAC GAG GAT AAT TTT TG and R: ACC GAG CCC ACA CTA CAA AC. Following the PCR and Sanger sequencing, heterozygous state of the mother was confirmed for the same mutation (Figure 2).

3 | DISCUSSION

Glutaric Acidemia type 1 disease has complex heterogeneity in phenotype and genotype. Therefore, the symptoms of the disease and the age of its occurrence are very variable. The age of onset varies from the early neonatal period till adulthood. Symptoms are severe in some children, and in others, it is mild. This may be due to type and site of the mutation in the *GCDH* gene and its effect on the amount and function of the enzyme. Patients with mild disease are often asymptomatic. Conversely, severe GA1 may cause death or disability due to acute encephalopathy, which may be precipitated by febrile illness, immunization, or surgical intervention.⁷ Children with Glutaric Acidemia type 1 appear almost healthy at birth. In fact, unlike other types of the disease, GA1 rarely show specific clinical signs

FIGURE 2 Sequencing chromatograms of heterozygous change T>C in Parents of the affected child with glutaric acidemia type one (A) Mother (B) Father



in the neonatal period, Except for macrocephaly, which is one of the first signs of the disease in 70% of neonates so size of children's heads can be significant for diagnosing the disease.⁸ Other symptoms usually occur between 2 months and 4 years. Patients with glutaric acidemia type 1 have an episode of metabolic decompensation with ketoacidosis, hyperammonemia, and hypoglycemia that called metabolic crises. Some of the symptoms of metabolic crises include diarrhea, irritability, nausea and vomiting, and weakness in the muscles and joints. The metabolic crisis can usually be prevented by carnitine supplementation and diet. Other diseases and infections can lead to metabolic crises. Other symptoms of the disease include brain damage (2–37 months), decreased Growth, excessive sweating, dystonic dyskinetic movement disorder, tremor, seizure, liver enlargement, frequent fever, learning disability and motor delay, rhabdomyolysis with increased creatine kinase, subdural hygroma, subdural hematoma, retinal hemorrhage, and atrophy of the frontal and temporal lobes.^{9–11} In patients with Glutaric Acidemia Type 2 (GAII, OMIM # 231680), mutations in at least 3 genes namely ETFA, ETFB, and ETFDH genes cause three subtypes of GAII namely GAIIA, GAIIB, and GAIIC. Glutaric acidemia type II (GA2) caused by a defect in electron transfer flavoprotein (ETF) or ETF dehydrogenase (ETFDH), resulting in deficiencies in multiple acyl-CoA dehydrogenases, such as short-, medium-, and long-chain acyl-CoA dehydrogenases, as well as isovaleryl-CoA dehydrogenase, glutaryl-CoA dehydrogenase, and sarcosine dehydrogenase.² The Biochemical properties of glutaric aciduria type I (GA I) due to glutaryl-CoA dehydrogenase deficiency is the accumulation of glutaric acid, and to a lesser degree of 3-hydroxy-glutaric and glutaconic acids.¹² ETFA, ETFB and ETFDH genes encode flavoprotein alpha and beta, and the transferrin fluoroprotein

dehydrogenase, which interfere with electron transfer in the mitochondrial respiratory chain. Lack or inappropriate functioning of each of these enzymes leads to inherited disorder in the metabolism of fatty acids, amino acids and choline. Although glutaric acid type 2 can be produced by three different genes, they are not distinctly phenotypic. Generally, Glutaric Acidemia of type 2 is classified into 3 classes in terms of clinical symptoms and their occurrence, depending on the type of mutation in each of these genes. The first group the neonatal form with congenital anomalies. The second group the neonatal form without congenital anomalies. The third category comes with a late start.¹ The child has symptoms like kidney cysts, hypospadias, cardiomyopathies, metabolic acidosis, sweaty feet odor, hypoglycemia without ketosis, and Rocker Bottom feet. The distinction between type 1 and 2 is that in type 2, the deficiency of Acetyl dehydrogenase does not only result in high secretion glutaric acid, but also increases the secretion of lactic acid, malonic acetate, butyric, isobutyric, 2-methylbutyric and Isovalic.¹³ Glutaric aciduria type 3 is Third type of disease. It is an autosomal recessive disorder, and its diagnosis is made after the exclusion of the other types of the disease. It is caused by mutations in the succinylCoA:glutarate-CoA transferase gene, which causes deficiency of succinate-hydroxymethylglutarate CoA transferase, and thus a decreased conversion of free glutaric acid to glutaryl-CoA, without clinical consequences.¹ Several common mutations have been identified so far including A421V in the Amish population in Pennsylvania,¹⁴ IVS 1 + 5G> T in Canadian Indians Oji-Cree,¹⁵ E365K in Irish,¹⁶ R402W in European population,^{16,17} and IVS10-2A> C in China¹⁸ and Taiwan.¹⁹ In 2017, Mosaeilhy et al examined in 18 patients with type 1 glutaric. In 14 of these patients, mutations in the *GCDH* gene were found, most of these

mutations were missense.²⁰ In 2014, Gupta et al studied 17 patients from 15 unrelated Indian families. They showed that exon 8 and 11 are hot spot region of *GCHD* gene in Indian patients.²¹ In 2020, Marina et al presented the biochemical and molecular genetic characteristics of 51 patients diagnosed with GA1 from 49 unrelated families in Russia. They identified a total of 21 variants, 9 of which were novel. The most commonly detected missense variants were c.1204C>T (p. Arg402Trp) and c.1262C>T (p. Ala421Val), which were identified in 56.38% and 11.7% of mutated alleles.²² In 2019, Ahmadi Shadmehri et al investigated clinical and molecular aspects of GA-1 in one Iranian patient and showed one novel pathogenic mutation in the *GCDH* gene: c.1147C > A (p. Arg383Ser). They suggested, it may be prevalent among Iranian populations.²³ In 2019, Zayed et al studied 41 Egyptian patients with GA1. They identified a total of 25 variants, of which the following six novel variants were identified. The most common variant, c.*165A>G, was detected in 42 alleles, and the most commonly detected missense variant, c.1204C>T (p. Arg402Trp), was identified in 29 mutated alleles in 15/41 (34.2%) of patients.²⁴ The results of our study showed that C.536T>C (p. Leu179Pro) mutation in *GCDH* gene has not been reported so far, but examination through in-silico software tools was performed for novel L179P missense mutation. BayesDel_addAF, DANN, DEOGEN2, EIGEN, FATHMM-MKL, LIST-S2, M-CAP, MVP, MutationAssessor, MutationTaster were used for Assessment and predicted pathogenicity for this variant. Versus benign prediction from PrimateAI was evaluated. Finally, the prediction software tools and clinical symptoms of the patient indicate that the mutation is pathogenic.

GA-I is currently believed to be a curable disorder. To treat metabolically, a low-lysine diet is supplemented with a lysine-free, tryptophane-lowered, amino acid admixture, supplementing L-carnitine orally, and an escalated emergency therapy throughout periods of intermedator disorder or surgical interventions. This is a recommendation from a universal protocol community for entire patients up to 6 years.

Normal development of children with GA1 is plausible if they follow a systematic therapeutic pattern appropriately, but the therapy should start from a quite premature age (since the neonatal time prior to appearing symptoms and ahead). In the case of failure in prompt and proper treatment, GA1 will normally induce severe, irretrievable, neurological injury that can lead to the permanent defective control of moving voluntary muscles, thereby rigorously affecting life and shortening life expectancy, in particular, if the injury happens prior to 6 years of age.

The long-run consequence is not yet completely found out, neurological disorders or extracerebral manifestation

(e.g. chronic kidney disease) can appear in adults, and a variety of extraatrial MRI alterations can develop following 6 years of age. Thus, controlling protein by a low-lysine natural protein level and prevention of lysine-laden foods are advised following 6 years of age.

4 | CONCLUSION

The mutation c.536T>C (p. Leu179Pro) in *GCDH* gene although has not been reported so far, but the in-silico analysis and clinical symptoms of the patient indicated that the mutation is pathogenic. So the identification of *GCDH* mutations will allow a better characterization (together with the precise clinical description of the affected subjects) of the disease in the next future, aimed at facilitating more rapid and accurate diagnosis, and thus also early treatment of patients.

ACKNOWLEDGEMENTS

The authors sincerely thank the staff of Rasad Genetic lab and Science & Research Branch of Islamic Azad University. Published with written consent of the patient.

CONFLICTS OF INTEREST

The authors have no conflicts of interest to declare.

AUTHOR CONTRIBUTIONS

SM is responsible for the design of this study, acquisition, analysis, and interpretation of data for the work. SR drafted the work and revised the draft critically for important intellectual content; SM and SR provided approval for publication of the content; SR collected the detailed information; all authors read and approved the final manuscript.

ETHICAL APPROVAL

“All procedures performed in studies involving human participants were in accordance with the ethical standards of the institutional and/or national research committee and with the 1964 Helsinki declaration and its later amendments or comparable ethical standards.” This study was approved by ethics committees of Rasad Pathobiology and Genetic Laboratory.

INFORMED CONSENT

Informed consent was obtained from all individual participants included in the study.

DATA AVAILABILITY STATEMENT

some data regarding the above case are present within this manuscript and authors have access to all data for this case report.

ORCID

Sima Rayat  <https://orcid.org/0000-0002-7685-9917>

REFERENCES

- Saral NY, Aksungar FB, Serteser M. Simplified approach to glutaric acidurias: a mini-review. *J Rare Dis Res Treat*. 2019;4(1):66-70.
- Goodman SI, Binard RJ, Woontner MR, Frerman FE. Glutaric acidemia type II: gene structure and mutations of the electron transfer flavoprotein:ubiquinone oxidoreductase (ETF:QO) gene.
- Goodman SI, Frerman FE. Glutaric acidemia type II (multiple acyl-CoA dehydrogenation deficiency). *J Inher Metab Dis*. 1984;7(suppl 1):33-37.
- Biery BJ, Stein DE, Morton DH, Goodman SI. Gene structure and mutations of glutaryl-coenzyme A dehydrogenase: impaired association of enzyme subunits that is due to an A421V substitution causes glutaric acidemia type I in the Amish. *Am J Hum Genet*. 1996;59(5):1006.
- Kölker S, Koeller DM, Okun JG, Hoffmann GF. Pathomechanisms of neurodegeneration in glutaryl-CoA dehydrogenase deficiency. *Ann Neurol*. 2004;55(1):7-12.
- Lindner M, Kölker S, Schulze A, Christensen E, Greenberg CR, Hoffmann GF. Neonatal screening for glutaryl-CoA dehydrogenase deficiency. *J Inherited Metab Dis*. 2004;27(6):851-859.
- Wang Q, Yang YL. Complex heterogeneity phenotypes and genotypes of glutaric aciduria type 1. *Zhongguo Dang dai er ke za zhi= Chinese Journal of Contemporary Pediatrics*. 2016;18(5):460-465.
- Kim HS, Yu HJ, Lee J, et al. A Korean patient with glutaric aciduria type 1 with a novel mutation in the glutaryl CoA dehydrogenase gene. *Ann Clin Lab Sci*. 2014;44(2):213-216.
- Strauss KA, Puffenberger EG, Robinson DL, Morton DH. Type I glutaric aciduria, part 1: Natural history of 77 patients. *Am J Med Genet*. 2003;121C(1):38-52.
- Bijarnia S, Wiley V, Carpenter K, Christodoulou J, Ellaway CJ, Wilcken B. Glutaric aciduria type I: outcome following detection by newborn screening. *J Inherited Metab Dis*. 2008;31(4):503-507.
- Viau K, Ernst SL, Vanzo RJ, Botto LD, Pasquali M, Longo N. Glutaric acidemia type 1: outcomes before and after expanded newborn screening. *Mol Genet Metab*. 2012;106(4):430-438.
- Hoffmann GF, Zschocke J. Glutaric aciduria type I: from clinical, biochemical and molecular diversity to successful therapy. *J Inherited Metab Dis*. 1999;22(4):381-391.
- Olsen RK, Andresen BS, Christensen E, Bross P, Skovby F, Gregersen N. Clear relationship between ETF/ETFDH genotype and phenotype in patients with multiple acyl-CoA dehydrogenation deficiency. *Hum Mutat*. 2003;22(1):12-23.
- Hedlund GL, Longo N, Pasquali M. Glutaric acidemia type 1. *Am J Med Genet C Semin Med Genet*. 2006;142C(2):86-94.
- Greenberg CR, Reimer D, Singal R, et al. A G-to-T transversion at the +5 position of intron 1 in the glutaryl CoA dehydrogenase gene is associated with the Island Lake variant of glutaric acidemia type I. *Hum Mol Genet*. 1995;4(3):493-495.
- Zschocke J, Quak E, Guldberg P, Hoffmann GF. Mutation analysis in glutaric aciduria type I. *J Med Genet*. 2000;37(3):177-181.
- Christensen E, Ribes A, Merinero B, Zschocke J. Correlation of genotype and phenotype in glutaryl-CoA dehydrogenase deficiency. *J Inherited Metab Dis*. 2004;27(6):861-868.
- Tang NL, Hui J, Law LK, et al. Recurrent and novel mutations of GCDH gene in Chinese glutaric acidemia type I families. *Hum Mutat*. 2000;16(5):446.
- Shu SG, Tsai CR, Chen LH, Chi CS. Type I glutaric aciduria: phenotypes and genotypes in 5 Taiwanese children. *J Formosan Med Assoc*. 2003;102(10):729-732.
- Mosaeilhy A, Mohamed MM, El Abd HS, Gamal R, Zaki OK, Zayed H. Genotype-phenotype correlation in 18 Egyptian patients with glutaric acidemia type I. *Metab Brain Dis*. 2017;32(5):1417-1426.
- Gupta N, Singh PK, Kumar M, et al. Glutaric acidemia type 1-clinico-molecular profile and novel mutations in GCDH gene in Indian patients. *JIMD Rep*. 2014;21:45-55.
- Kurkina MV, Mihaylova SV, Baydakova GV, et al. Molecular and biochemical study of glutaric aciduria type 1 in 49 Russian families: nine novel mutations in the GCDH gene. *Metab Brain Dis*. 2020;35(6):1009-1016.
- Shadmehri AA, Fattahi N, Pourreza MR, et al. Molecular genetic study of glutaric aciduria, type I: Identification of a novel mutation. *J Cell Biochem*. 2019;120(3):3367-3372.
- Zayed H, El Khayat H, Tomoum H, et al. Clinical, biochemical, neuroradiological and molecular characterization of Egyptian patients with glutaric acidemia type 1. *Metab Brain Dis*. 2019;34(4):1231-1241.

How to cite this article: Rayat S, Morovvati S. A novel mutation in the glutaryl-CoA dehydrogenase gene (GCDH) in an Iranian patient affected with Glutaric acidemia type 1. *Clin Case Rep*. 2021;9:e04749. <https://doi.org/10.1002/ccr3.4749>