



Case report

Adjustments of haptics length for tilted intraocular lens after intrascleral fixation

Helena Yuri Kurimori^{a,b}, Makoto Inoue^{a,*}, Akito Hirakata^a^a Kyorin Eye Center, Kyorin University School of Medicine, Tokyo, Japan^b Department of Ophthalmology, Santa Casa de São Paulo Medical School, São Paulo, Brazil

ARTICLE INFO

Keywords:

Intraocular lens

Intrascleral fixation

Optical coherence tomography

Tilt

ABSTRACT

Purpose: To report the findings and surgical techniques on two cases of severe tilting of an intraocular lens (IOL) that had been implanted with intrascleral fixation and the tilting was detected by anterior segment optical coherence tomography (AS-OCT).

Observations: Two patients underwent flanged intrascleral fixation of an IOL with the double needle technique. AS-OCT showed that the tilt of IOL was 25.3° in Case 1 and was 38.1° in Case 2, and a second surgery was planned to reduce the IOL tilt. Both edges of the flanged haptics were externalized and shortened by 2–3 mm. Then, the haptics edges were inserted intrasclerally. The tilt of the IOLs was reduced to 7.7° and 5.7°, and the myopia-shifted refraction was reduced from −2.75 diopters (D) and −4.50 D to −0.13 D and −0.50 D of the approximate planned refraction in the two cases.

Conclusions and importance: An excessive tilt of an intrasclerally fixed IOL can be corrected by shortening the length of the haptics. AS-OCT was useful in not only detecting the tilted IOL but also in monitoring the degree of tilt after adjustment surgery.

1. Introduction

The implantation of an intraocular lens (IOL) in eyes with insufficient or no lens capsular support has been a challenging. One technique consists of suturing a posterior chamber IOL to the sclera and a second method has been to implant the IOL in the anterior chamber.^{1,2} However, there are some concerns on late complications of erosion and breakage of the sutures that can lead to subluxation of suture-fixed IOLs.³

To reduce the complications of sutured scleral fixated IOLs, sutureless intrascleral fixation has been reported to be successful. In this procedure, the haptics of the IOL are inserted into limbus-parallel scleral tunnels.^{4–9} Intrascleral fixation has been reported to result in less tilting of the IOL than sutured scleral fixation.⁹ However, there is a report that a symmetrical scleral fixation technique has the possibility of inducing a tilting of the two haptics.¹⁰

Yamane and associates¹¹ described a double needle technique for intrascleral fixation with 27-gauge needles inserted parallel to the limbus instead of creating a scleral tunnel. Later, they modified the double needle

technique using thin-walled 30-gauge needles.¹² For this, two angled incisions are initially made by 30-gauge, thin-walled needles that were inserted parallel to the limbus. Then the haptics of the IOL were externalized with the needles and cauterized to make a flange of the haptics edge which would then allow a better fixation of the haptics in the sclera. The IOL was fixed with the exact centration and good axial stability.

The purpose of this paper is to present our findings on two cases of severe tilting of an IOL after flanged intrascleral fixation with the double-needle technique. We shall show that the tilting of the IOLs can be detected and followed by anterior segment optical coherence tomography (AS-OCT). Our results showed that the tilting can be reduced by shortening the length of the haptics.

2. Findings

2.1. Case 1

A 52-year-old man noticed a decrease in his vision of one week duration.

* Corresponding author. Kyorin Eye Center, Kyorin University School of Medicine, 6-20-2 Shinkawa, Mitaka-City, Tokyo, 181-8611, Japan.
E-mail address: inoue@eye-center.org (M. Inoue).

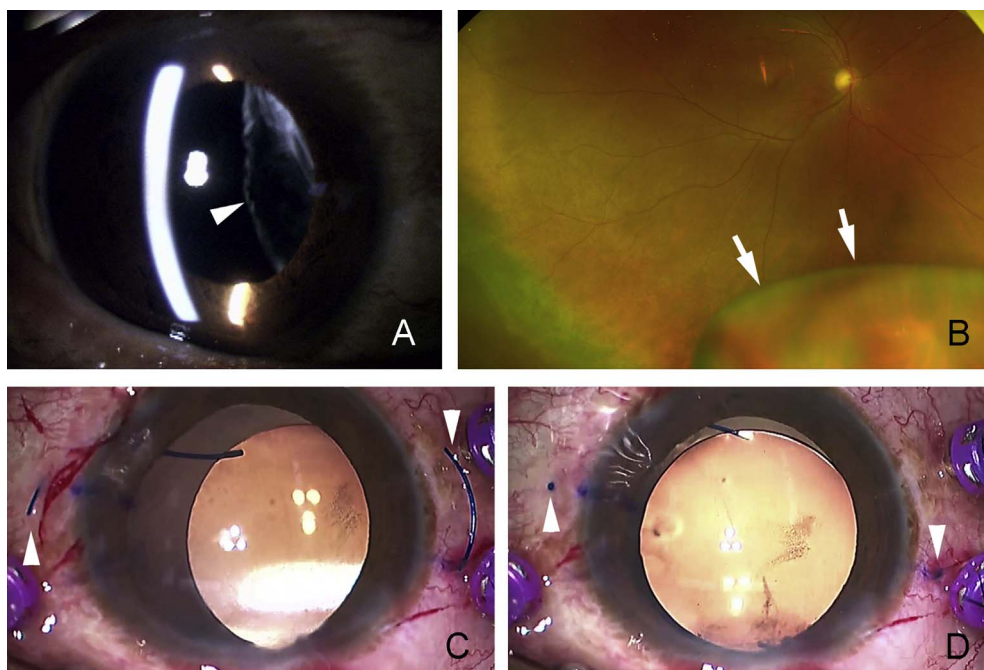


Fig. 1. Preoperative and intraoperative images of Case 1 that had intrascleral fixation of an intraocular lens (IOL). A. Slit-lamp photograph shows aphakia (arrowhead) due to a dislocated crystalline lens. B. Wide-angle image showing dislocated lens (arrows). C. Intraoperative photograph showing the two haptics (arrowheads) of the IOL extracted through the pars plana by the double-needle technique. D. Both edges of the haptics are externalized, and the edges (arrowheads) are inserted into the scleral tunnels.

Table 1
The refractive information of two cases and tilted angle of the intraocular lens.

	Initial visit	After intrascleral fixation	After haptics shortening
Best-corrected visual acuity			
Case 1	20/18	20/18	20/18
Case 2	20/100	20/30	20/18
Spherical equivalent (D)			
Case 1	+11.63	-2.75	-0.13
Case 2	n.c.	-4.50	-0.50
Astigmatism (D (Axis))			
Case 1	-0.75 (15)	-3.00 (170)	-0.75 (15)
Case 2	n.c.	-4.00 (150)	-1.00 (95)
Keratometric astigmatism (D(Axis))			
Case 1	-1.50 (11)	-0.75 (10)	-1.00 (6)
Case 2	-0.62 (129)	-0.56 (111)	-0.75 (78)
IOL tilt (angle (Axis))			
Case 1	NA	25.3 (67)	7.7 (101)
Case 2	NA	38.1 (80)	5.7 (121)

D = diopter, n.c. = non corrigent, NA = not applicable.

Our examination showed that his best-corrected visual acuity (BCVA) was 20/18 in both eyes, and the refractive error was +12.0 diopters (D) combined with a cylinder of -0.75 D at 15° in the right eye and +0.75 D combined with a cylinder of -1.0 D at 165° in the left eye. Slit-lamp biomicroscopy and indirect ophthalmoscopy showed that the crystalline lens was dislocated into the vitreous cavity (Fig. 1). The axial length was 23.91 mm OD and 23.86 mm OS (Table 1). The flattest corneal curvature (K1) was 42.50 D at 11° and the steepest curvature (K2) was 44.00 D at 101°.

Pars plana vitrectomy was performed with 27-gauge instruments with the Constellation® Vision System (Alcon Laboratories, Fort Worth, TX). The dislocated lens was lifted by aspiration of a vitreous cutter and skewered with a light pipe at the iris plane, then removed by a phacoemulsification probe that was inserted through a transconjunctival single-plane sclerocorneal incision. The postoperative refractive power of the IOL was planned to be -0.32 D. Two angled incisions were made parallel and 2 mm posterior to the limbus by 30-gauge thin-walled needles. Both haptics of a 3-piece IOL (NX-70, Santen, Osaka, Japan)

were externalized with the needles and cauterized with a coagulator (Accu-Temp®, Alcon Laboratories, Fort Worth, TX) to create flanges of the edges of the haptics (Fig. 1). The total length of the NX-70 IOL was 13.2 mm between the most lateral haptics. The flanged edges of the haptics were pushed back and fixed into the scleral tunnels for intrascleral fixation. The IOL was implanted in the center of the pupil, and it did not appear to be tilted through the operating microscope when the edges of the haptics were inserted intrasclerally.

The postoperative vision was 20/18 with correction of -1.25 D combined with a cylinder of -3.0 D at 170°. Slit-lamp examination revealed a tilting of the implanted IOL (Fig. 2). The flattest corneal curvature was 43.25 D at 10° and the steepest curvature was 44.00 D at 100°. AS-OCT (CASIA2, Tomey, Tokyo, Japan) detected a tilt of the IOL of 25.3° at axis 67° (Fig. 2). Thus, an adjustment of the tilted IOL was planned for one month later.

After local anesthesia, the conjunctiva and the sclera were incised to access the ends of the haptics, and the flanged haptics edges were extracted out of the sclera with the tip of a sharp blade (Fig. 2). Both edges of the haptics were cut by scissors and shortened by approximately 2 mm with observation of the reduction of tilting of the IOL through the operating microscope. The edges of the haptics were flanged and inserted inside of the sclera tunnel. Slit-lamp examination showed an improvement of IOL tilt. Vision was 20/18 without correction, and the refraction was +0.25 D combined with a cylinder of -0.75 D at axis 15° after 15 days. The IOL tilt was measured to be 7.7° at axis 101° by AS-OCT. By shortening the haptics, the IOL was rotated in a counter-clockwise direction and the axis of the tilted IOL was also rotated in a counter-clockwise direction by 34°.

2.2. Case 2

A 78-year-old woman presented with a dislocated IOL in the right eye (Fig. 3). She had had cataract surgery with the implantation of an IOL 15 years earlier. The BCVA in the right eye was 20/100 (Table 1). Slit-lamp examination revealed a temporal and inferior subluxation of the 3-piece IOL. The axial length was 21.98 mm OD and 22.00 mm OS. The flattest corneal curvature was 44.89 D at 129° and the steepest curvature was 45.51 D at 39° in the right eye.

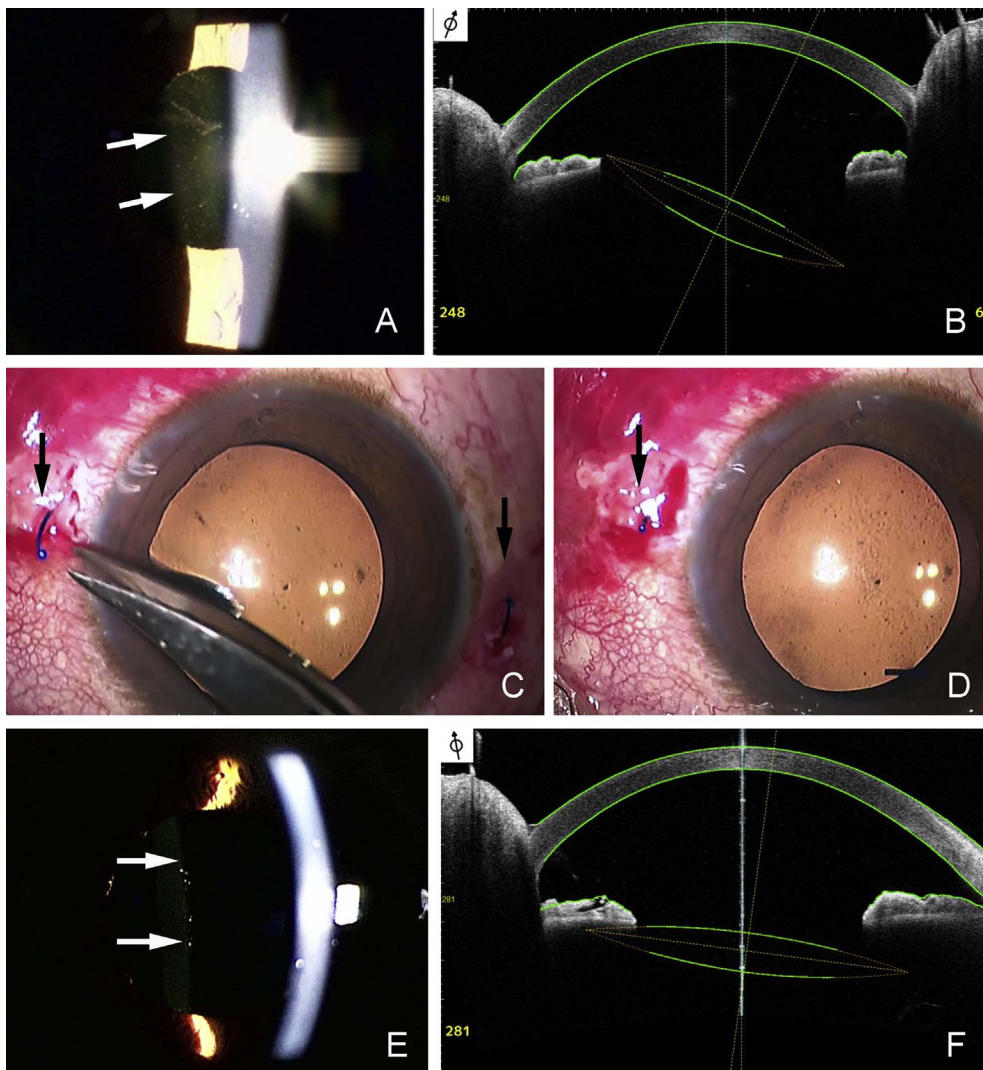


Fig. 2. Preoperative, intraoperative, and postoperative images of Case 1 for adjustment surgery after intrascleral fixation of an intraocular lens (IOL). A. Slit-lamp photograph showing a tilting of an implanted IOL (arrows) with intrascleral fixation. B. Anterior segment optical coherence tomographic (AS-OCT) image showing a tilting of 25.3° at axis 67° of an implanted IOL. C. Intraoperative photograph during the adjustment surgery showing that both sides of the haptics (arrows) edges are pulled out of the sclera. D. The edge of the haptics (arrow) is externalized and shortened by about 2 mm. E. Slit-lamp photograph showing a reduction of the tilting of the IOL (arrows). F. AS-OCT shows a reduction of the tilting of the IOL to 7.7° at 101° axis.

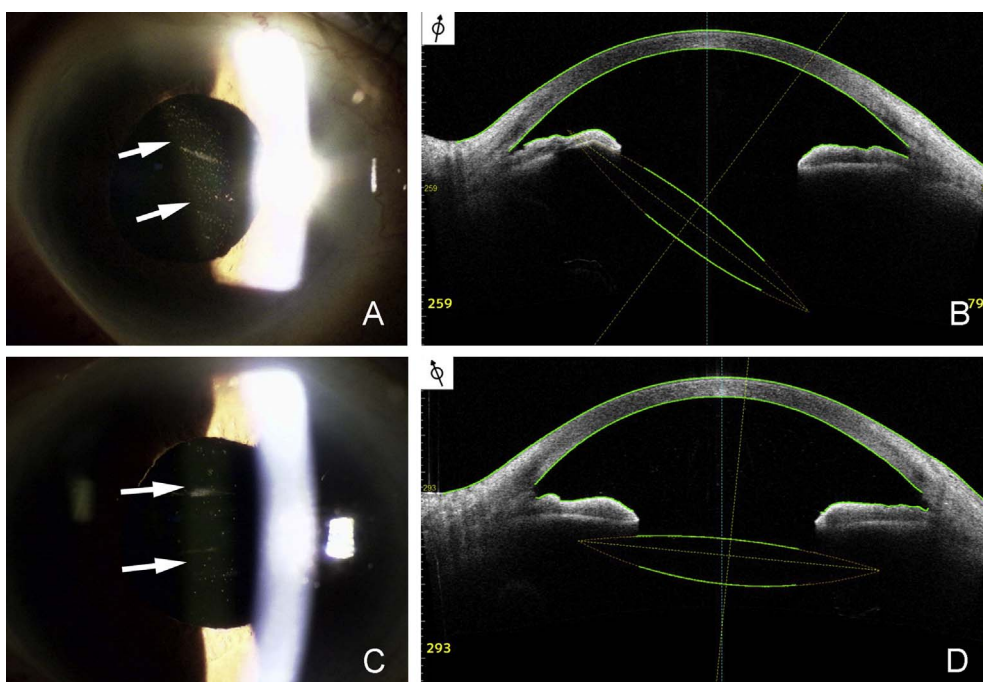


Fig. 3. Postoperative images of Case 2 after intrascleral fixation of an intraocular lens (IOL). A. Slit-lamp photograph showing a tilting of the IOL (arrows) after intrascleral fixation. B. Anterior segment optical coherence tomographic (AS-OCT) image showing a tilt of 38.1° at axis 80° of the implanted IOL. C. Postoperative slit-lamp photograph showing a reduction of the tilting of the IOL (arrows) after the adjustment surgery. D. AS-OCT showing a reduction of the tilting of the IOL to 5.7° at axis 121°.

Pars plana vitrectomy was performed with 27-gauge instruments with Constellation® Vision System, and the subluxated IOL was removed through a corneoscleral incision after the IOL was divided into two pieces in the anterior chamber. A 3-piece IOL (NX-70) was implanted and fixed intrasclerally with the double needle technique in the same way as Case 1. The postoperative refractive power was planned to be -0.89 D in the right eye. The flanged edges of the haptics were pushed back and fixed in the scleral tunnels. Slit-lamp examination revealed that the IOL was implanted intrasclerally but it was tilted (Fig. 3). After 2 months, the BCVA was 20/30 with -2.50 D combined with a cylinder of -4.00 D at axis 150° . The flattest corneal curvature was 44.52 D at 111° and the steepest curvature was 45.08 D at 21° . AS-OCT (CASIA2) detected an IOL tilt of 38.1° at axis 80° . An adjustment of the tilted IOL was planned.

For the adjustment surgery, the flanged haptics edges were extracted out of the sclera. Both edges of the haptics were cut by the scissors approximately 3 mm lengths while observing the reduction of tilt of the IOL through the operating microscope. The edges of the haptics were flanged and inserted into of the sclera. Slit-lamp examination detected an improvement of IOL tilt (Fig. 3). Vision was 20/25 with 0 D combined with a cylinder of -1.0 D at axis 95° after 10 days. The IOL tilt was 5.7° at axis 121° by AS-OCT. The axis of the tilted IOL was rotated in a counter-clockwise direction by 41° . Wavefront analyses (KR-1W, Topcon Medical System Inc., Tokyo, Japan) showed that the aberration of the whole eye after the intrascleral fixation was mainly due to astigmatic aberration in the internal aberration of the tilted IOL, and the astigmatic aberration decreased after adjustment of the haptic length (Fig. 4).

3. Discussion

The results of our study on two cases with excessive tilting of an implanted IOL with intrascleral fixation showed that a shortening of the length of haptics reduced the tilt of the IOL. In addition, the astigmatic

power decreased, and the refraction decreased to the refractive power that had been planned.

Yamane and associates reported that the average tilt of implanted IOLs was $3.4 \pm 2.5^\circ$ in 96 consecutive patients after flanged intrascleral fixation with the double needle technique.¹² They reported that the postoperative complications included iris capture by the IOL in 8 eyes (8%), vitreous hemorrhage in 5 eyes (5%), and cystoid macular edema in 1 eye (1%). There were no severe complications including postoperative retinal detachments, endophthalmitis, or IOL dislocation. They reported a mean angle of tilt of $3.83 \pm 2.69^\circ$ in eyes implanted with the same type of 3-piece IOL (X-70) as our cases. In our two cases that had intrascleral fixation with the double needle technique, the tilt of the IOL was 25.3° in Case 1 and 38.1° in Case 2. We used CASIA2 AS-OCT with a longer wavelength light of 1310 nm which enabled us to scan the posterior surface of IOL as well as the anterior surface, and thus calculate the tilt of the IOL more accurately.

The maximal length between the haptics of the IOL extended for intrascleral fixation was calculated to be 14–15 mm.¹³ The actual length between the haptics for intrascleral fixation depended on the diameter of the ciliary sulcus because the intrascleral portion that the haptics edge was fixed into was located more laterally than the ciliary sulcus.¹³ The extension of the haptics may have induced the tilting of the IOL after the intrascleral fixation. Asymmetric cauterization of the haptics edges may have also induced the tilt and decentration of the IOL. However, the decentration of IOL was not obvious by the slit-lamp examination and AC-OCT.

The haptics of an IOL are designed to attach to the lens capsule or to the ciliary sulcus at the most lateral part of the haptics. However, during intrascleral fixation by the insertion of the haptics edges into a scleral tunnel, the loops of the haptics open and the haptics bend to the opposite side of the loop which may then cause anterior or posterior shift of the haptics and tilt of the IOL. The 3-piece IOL has a forward-tilted haptics and the NX-70 IOL is also forward-tilted by 7° . Flatter angle of insertion of the haptics into the scleral tunnel than the forward-tilted angle may cause the anterior shift of the haptics and IOL tilt. We assume that these changes of the haptics shape may have induced the tilt of IOL after the intrascleral fixation. Symmetrical shortening of the haptics edges to the most lateral part of the extended haptics for intrascleral fixation may reduce the tilt of IOL without losing centration of the IOL.

The refraction of these two cases had a myopic shift from the calculated refractive errors after intrascleral fixation which suggested that tilting of the IOL may have caused a myopic shift by increasing the tilt and astigmatic aberrations. The AS-OCT detected that the haptics would be bent anteriorly and posteriorly, and the optics shifted posteriorly in combination with a tilting of the IOL. Adjustment of the haptics length reduced the aberrations and the shift of the haptics which resulted in not only a decrease in the tilt angle but also a decrease in the posterior shift of the IOL. These changes would reduce the myopic shift of the refractive error to the estimated refraction.

Todorich and associates¹⁴ reported that adjustments of the centration of an IOL could be achieved by manipulating the degree of haptic externalization through the sclerotomies. Our cases clearly showed that a shortening of the haptics can be performed to reduce the tilting of an IOL. However, detecting the tilt of the IOL was difficult to observe through the operating microscope. We tried to use intraoperative OCT to detect the tilting of the IOL intraoperatively, but the transparent IOL was not easily observed by intraoperative OCT. The intraoperative measurements of the refractive power through the operating microscope may resolve these problems. Further studies are needed to improve the effects of intrascleral fixation with additional intraoperative measurements.

4. Conclusions

We describe two cases of severe tilting of an implanted IOL after

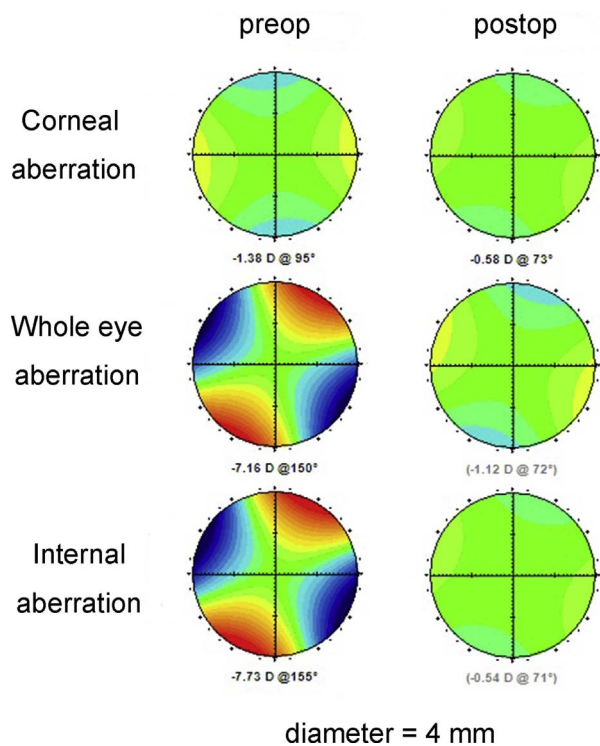


Fig. 4. Preoperative and postoperative wavefront images of Case 2. A. Preoperative wavefront analyses shows astigmatic aberration in the internal and whole eye aberrations. B. Postoperative wavefront analyses detect a decrease of the astigmatic aberration in the internal and whole eye aberrations but the corneal aberration has not changed.

intrasceral fixation with the double-needle technique. The tilting of the IOLs was reduced by shortening the length of the haptics. AS-OCT was useful in detecting the tilted IOL and to monitor the adjustments of the tilted IOL postoperatively.

Patients consent

Consent to publish the case report was not obtained. This report does not contain any personal information that could lead to the identification of the patient.

Funding

No funding or grant support.

Authorship

All authors attest that they meet the current ICMJE criteria for Authorship.

Conflict of interest

The authors have no financial disclosures.

Acknowledgements

None.

Appendix A. Supplementary data

Supplementary data related to this article can be found at <http://dx.doi.org/10.1016/j.ajoc.2018.02.025>.

References

- Hannush SB. Sutured posterior chamber intraocular lenses: indications and procedure. *Curr Opin Ophthalmol*. 2000;11:233–240.
- Wagoner MD, Cox TA, Ariyasu RG, Jacobs DS, Karp CL. American Academy of Ophthalmology. Intraocular lens implantation in the absence of capsular support: a report by the American Academy of Ophthalmology. *Ophthalmology*. 2003;110:840–859.
- Vote BJ, Tranos P, Bunce C, Charteris DG, Da Cruz L. Long-term outcome of combined pars plana vitrectomy and scleral fixated sutured posterior chamber intraocular lens implantation. *Am J Ophthalmol*. 2006;141:308–312.
- Gabor SG, Pavlidis MM. Sutureless intrascleral posterior chamber intraocular lens fixation. *J Cataract Refract Surg*. 2007;33:1851–1854.
- Agarwal A, Kumar DA, Jacob S, et al. Fibrin glue-assisted sutureless posterior chamber intraocular lens implantation in eyes with deficient posterior capsules. *J Cataract Refract Surg*. 2008;34:1433–1438.
- Scharioth GB, Prasad S, Georgalas I, Tataru C, Pavlidis M. Intermediate results of sutureless intrascleral posterior chamber intraocular lens fixation. *J Cataract Refract Surg*. 2010;36:254–259.
- Totan Y, Karadag R. Trocar-assisted sutureless intrascleral posterior chamber foldable intra-ocular lens fixation. *Eye (Lond)*. 2012;26:788–791.
- Akimoto M, Taguchi H, Takahashi T. Using catheter needles to deliver an intraocular lens for intrascleral fixation. *J Cataract Refract Surg*. 2014;40:179–183.
- Ohta T, Toshida H, Murakami A. Simplified and safe method of sutureless intrascleral posterior chamber intraocular lens fixation: Y-fixation technique. *J Cataract Refract Surg*. 2014;40:2–7.
- Teichmann KD, Teichmann IA. The torque and tilt gamble. *J Cataract Refract Surg*. 1997;23:413–418.
- Yamane S, Inoue M, Arakawa A, Kadonosono K. Sutureless 27-gauge needle-guided intrascleral intraocular lens implantation with lamellar scleral dissection. *Ophthalmology*. 2014;121:61–66.
- Yamane S, Sato S, Maruyama-Inoue M, Kadonosono K. Flanged intrascleral intraocular lens fixation with double-needle technique. *Ophthalmology*. 2017;124:1136–1142.
- Matsuki N, Inoue M, Itoh Y, Nagamoto T, Hirakata A. Changes in higher-order aberrations of intraocular lenses with intrascleral fixation. *Br J Ophthalmol*. 2015;99:1732–1738.
- Todorich B, Thanos A, Woodward MA, Wolfe JD. Sutureless intrascleral fixation of secondary intraocular lens using 27-gauge vitrectomy System. *Ophthalmic Surg Lasers Imaging Retina*. 2016;47:376–379.