



NOTE

Surgery

Thoracoscopic pericardiectomy associated with fully implantable catheter via thoracoscopy in the management of mesothelioma in a bitch

Hellen Fialho HARTMANN¹⁾, Marília Teresa DE OLIVEIRA¹⁾, João Pedro Scussel FERANTI¹⁾, Gabriela Pesamosca CORADINI¹⁾, Stephanie Lanzarini ABATI¹⁾, Bibiana Zoppas PIEREZAN¹⁾, Vanessa Zanchi SARTURI¹⁾, Marcella Teixeira LINHARES¹⁾, Álvaro José Chávez SILVA^{1,3)} Francisco Miguel SÁNCHEZ-MARGALLO²⁾, Anne Santos DO AMARAL¹⁾ and Maurício Veloso BRUN^{1)*}

¹⁾Department of Small Animal Clinics, Center of Rural Science, Federal University of Santa Maria (UFSM), Roraima Av., 1000, 97105-900, Camobi, RS, Brazil

²⁾Minimally Invasive Surgery Center Jesús Usón, Carretera N-521, KM 41.8, 10071, Cáceres, Extremadura, Spain

³⁾Department of Animal Welfare, National Autonomous University of Nicaragua (UNAN), Cruz Roja 90 m al norte San Felipe, 21000, León, Nicaragua

ABSTRACT. Mesothelioma is a very aggressive malignant tumor with low survival rates that is often diagnosed belatedly. Pericardial effusion is a common consequence in cases of mesothelioma, with pericardiocentesis and pericardiectomy indicated; therefore thoracocentesis is necessary to drain the contents no longer retained in the pericardium. The present report describes a mesothelioma-carrying dog with a history of cardiac tamponade that underwent thoracoscopic pericardiectomy and, later, thoracoscopic implantation of a fully implantable catheter to function as a thoracic drain. In the consulted literature, there is no use of a fully implantable catheter for this purpose. The authors consider that there was an improvement in the quality of life.

KEY WORDS: canine, thoracic neoplasia, thoracoscopy, vascular portal, videosurgery

J. Vet. Med. Sci.
81(6): 946–948, 2019
doi: 10.1292/jvms.17-0631

Received: 24 November 2017
Accepted: 7 April 2019
Published online in J-STAGE:
17 April 2019

Malignant mesothelioma is a slow-growing solid tumor originating from mesothelial cells [4]. It has large dimensions, irregular growth and complex morphology, resembling other structures in density and composition [1]. It is an aggressive neoplasm with low survival rates since it is often diagnosed at an advanced stage [4] since what usually leads patients to care is signs of cavity effusion rather than the neoplasm itself [3].

A 13-year-old female dog was treated with dyspnea and lethargy on day 1. Thoracic X-ray revealed a large, bulging heart, suggesting pericardial effusion. Upon ultrasound examination, the patient showed a high amount of fluid between heart and pericardium. The patient underwent pericardiocentesis, which resulted in 220 ml of bloody fluid. Analysis of this fluid was inconclusive as to the etiology of effusion. Fifteen days later, he returned to the hospital under the same ailment, being drained 440 ml of bleeding pericardial effusion. The analysis of this content was suggestive of neoplasia. On day 23, the patient returned and was referred to the hospital's video-surgery department, where new pericardiocentesis was performed, resulting in 295 ml drained. To minimize the risks of death due to cardiac tamponade and to provide a definitive diagnosis, a pericardiectomy involving the intercostal and paraxiphoid accesses by thoracoscopy was performed on day 27.

As for thoracoscopic pericardiectomy, followed by pleural biopsies, the patient was maintained in a dorsal decubitus inclined to the right. The first portal was placed through the 8th left intercostal space. Under endoscopic visualization, the paraxiphoid portal was then placed. The third access (intercostal) was performed on the left side seeking for triangulation with the previous ones (Fig. 1A). After the collection of pleural biopsies in areas with macroscopic proliferation similar to neoplasms, partial

*Correspondence to: Brun, M. V.: mauriciovelosobrun@hotmail.com (National Council for Scientific and Technological Development-CNPq-Brazil fellowship (305876/2018-0))

©2019 The Japanese Society of Veterinary Science



This is an open-access article distributed under the terms of the Creative Commons Attribution Non-Commercial No Derivatives (by-nc-nd) License. (CC-BY-NC-ND 4.0: <https://creativecommons.org/licenses/by-nc-nd/4.0/>)

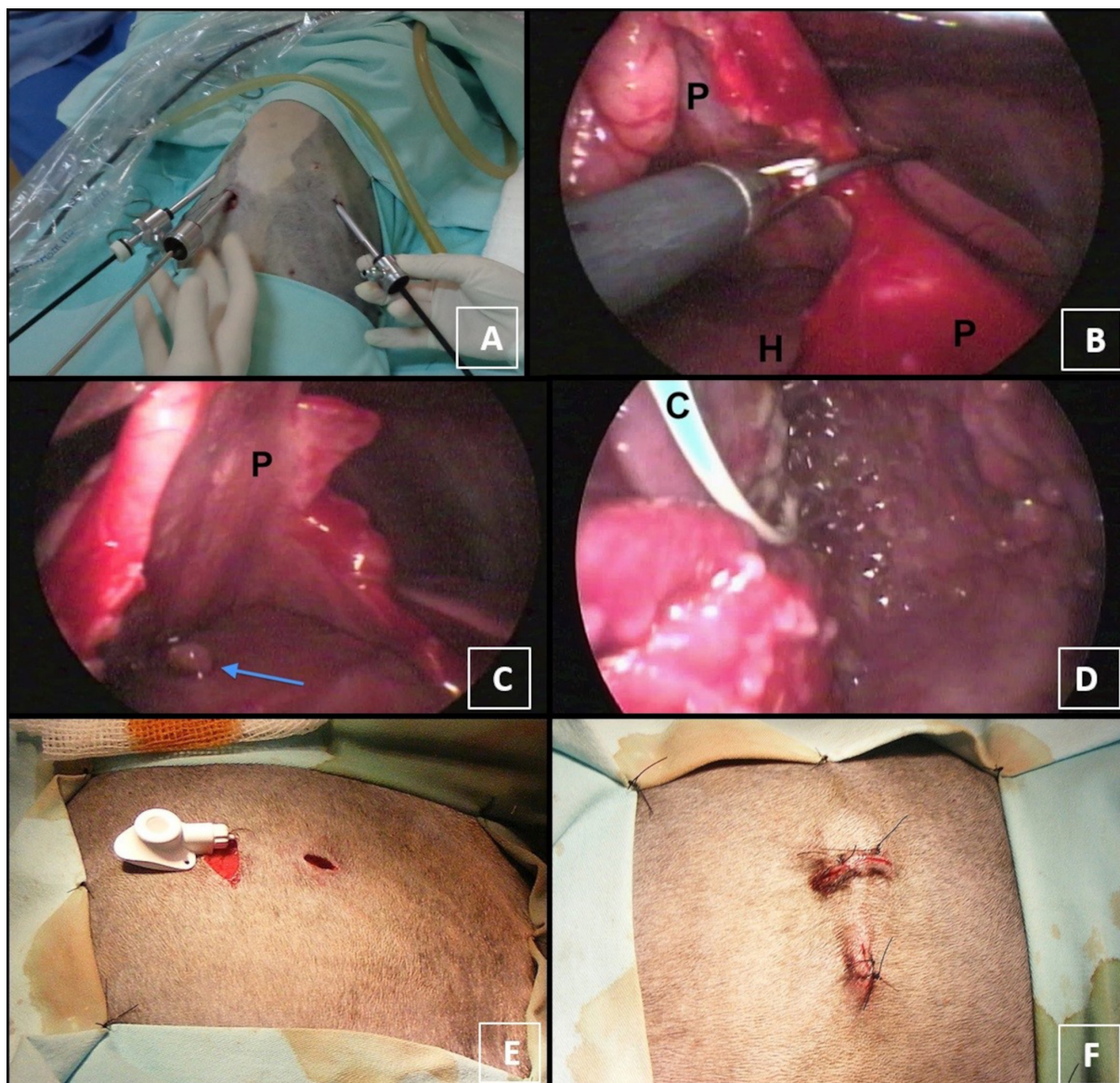


Fig. 1. Management of mesothelioma by partial pericardiectomy and implantation of vascular portal in dog. (A) Positioning of the three portals for thoracoscopic partial pericardiectomy. The endoscope was kept positioned in the paraxiphoid portal. (B) Partial pericardiectomy with Metzenbaum scissors and Kelly forceps without electrosurgery. (C) During the pericardiectomy, the presence of neof ormation was observed next to the pericardium (arrow), which was biopsied. (D) Vascular portal catheter within the thorax with extensive proliferation of mesothelioma and pleural effusion (blisters in the background). (E) Implantation of the catheter below the skin. The portal catheter was positioned in the thorax from the access via intercostal thoracoscopy. (F) Final aspect of the implanted vascular portal. C=catheter; P=pericardium; H=heart.

pericardiectomy with Kelly's forceps and Metzenbaum scissors without electrosurgery was started, removing an extensive pericardial segment, yet without extending the dissection to the vicinity of the phrenic nerve (Fig. 1B). The pericardium together with a neoplasm-compatible epicardial neof ormation were collected (Fig. 1C) and sent for histological evaluation, which confirmed the presence of mesothelioma in both samples as well as for the pleural collections. At the end of this procedure, a 12Fr thoracic drain was positioned through the third portal. This drain was kept closed, and only manipulated during drainages.

Ampicillin (30 mg/kg IV TID), Tramadol (4 mg/kg SC QID) and Dipirone (25 mg/kg SC TID) were administered as postoperative therapy. Thoracic drainage was performed every two hr. The thoracic drainage was removed and the patient was discharged 24 hr postoperatively. The prescription was maintained until 7 days of antibiotic therapy and 4 days of analgesia. On day 37, chemotherapy was started, with Carboplatin 300 mg/m² IV every 21 days, and six sessions were performed. On day 121 the patient presented with dyspnea due to pleural effusion, after this weekly thoracentesis began to be performed.

At day 167, due to repeated thoracentesis, a fully implantable 6 Fr catheter (Celsite Implantofix[®], B. Braun, São Gonçalo Brazil) was chosen as a thoracic drain (Fig. 1D). On this occasion an exploratory thoracoscopy was performed. A significant worsening

in the extent of the neoplasm was evidenced, since the parietal and visceral pleura did not show any healthy portion. The end of the catheter was adjusted to the chest dimensions and positioned through the access for thoracoscopy. A transversal cutaneous incision with broad subcutaneous dissection was performed to fix the reservoir near the skeletal muscle (Fig. 1E). The drainage was continued every seven days approximately, through the subcutaneous portal, with greater comfort for the animal (Fig. 1F), since it excludes the need for puncture of the pleura and thoracic musculature. In addition, it has advantages over conventional drainage, such as: low risk of contamination, prevents the animal from pulling the drain and dispense unnecessary dressing to fix the drain to the body. On day 197, chemotherapy was resumed, this time with the intention of alternating Carboplatin 300 mg/m² and Doxorubicin 30 mg/m² every 14 days. However, two sessions were performed, one with each drug, and then, at the request of the tutors the chemotherapy was suspended. The catheter obstructed 90 days after its implantation, on day 287, and the patient was submitted to a new thoracoscopy and positioning of a second 9 Fr catheter (Celsite Implantofix[®], B. Braun). There was obstruction of the first catheter by neoplastic tissue and extensive proliferation of the neoplasm. The clogged portion of the first catheter was cut and the implant maintained. Both fully implantable catheters had a 12mm- diameter port septum that was positioned in the subcutaneous, through a simple interrupted suture with 3–0 nylon between the orifices of the device itself and the latissimus dorsi muscle. The catheters are made of latex, MRI compatible and Bis (2-ethylhexyl) phthalate (DEHP) and Polyninyl chloride (PVC) free. Pain related to the positioning of the second catheter was not observed.

On day 333, 46 days after the implantation of the second catheter, the animal was brought to emergency room due to flaccid paralysis of the pelvic limbs, exacerbated pain, absence of bilaterally palpable femoral pulse and low temperature in the pelvic extremities, signs compatible with aortic thromboembolism. The patient shown important weight loss. The tutors opted for euthanasia owing to the seriousness of the condition and did not authorize necropsy.

The total survival time was 332 days from the first clinical care. The medical team involved and tutors considered that the patient was benefited by the treatment, gaining time and quality of life against the serious illness presented.

Effusion is the most common pericardial disease in dogs and is commonly idiopathic or due to a neoplastic process and in most cases, pericardiocentesis is initially indicated for the rapid stabilization of the patient [2]. According to these authors, ultrasonography was the method of choice for differentiating neoplastic pericardial effusion from idiopathic; in this work of 11 cases of dogs with heart mass, one was mesothelioma. In the present case, ultrasonography did not detect the neoplasia, which was only suggested in the second pericardiocentesis. According to Machida *et al.* [7] Mesothelioma can be underdiagnosed in dogs because of the difficulty of detecting it in pericardial effusion. Thus, pericardectomy was an excellent management option in the present case and simultaneously allowed the collection of biopsies that defined the diagnosis and directed the treatment. Regardless of the cause of pericardial effusion, pericardiotomy is indicated to facilitate drainage into the pleural cavity, thereby reducing pressure on the heart [2]. In the present case, it was essential to manage the disease, considering the volume and frequency of pericardial effusion as well as the presence of mesothelioma in the pericardium and epicardium, which would certainly cause effusion and present an important risk of death due to cardiac tamponade. Pleural mesothelioma is an aggressive tumor that affects the pleura, and as it is often diagnosed at an advanced stage; it further impoverishes the prognosis with an average survival of 11 months in humans [4]. In a study with dogs, animals without heart mass detected by ultrasonography, the mean post-pericardectomy survival period was 1218 days, while those without pericardectomy survived for an average of 532 days [8]. Yet in a study in dogs with mass at the base of the heart, the mean post-pericardectomy survival time was 730 days, compared to 42 days for those who did not undergo pericardectomy [6]. However, this rate varies according to the type of neoplasia involved. In dogs with right atrial hemangiosarcoma, there was no significant difference in post-pericardectomy survival time [5].

According to the authors' knowledge, there is no record in the literature consulted of the use of a fully implantable catheter for this purpose, nor of the association of implantation of this device with thoracoscopy. Thus, this case demonstrates a new possibility of management of effusive thoracic neoplasms not responsive to clinical treatment in dogs.

REFERENCES

1. Armato, S. G. 3rd., Li, P., Husain, A. N., Straus, C., Khanwalkar, A., Kindler, H. L. and Vigneswaran, W. T. 2015. Radiologic-pathologic correlation of mesothelioma tumor volume. *Lung Cancer* **87**: 278–282. [Medline] [CrossRef]
2. Atencia, S., Doyle, R. S. and Whitley, N. T. 2013. Thoracoscopic pericardial window for management of pericardial effusion in 15 dogs. *J. Small Anim. Pract.* **54**: 564–569. [Medline] [CrossRef]
3. Cloas, J. M., Font, A. and Mascort, J. 1999. Pericardial mesothelioma in a dog: long-term survival after pericardectomy in combination with chemotherapy. *J. Small Anim. Pract.* **40**: 383–386. [Medline] [CrossRef]
4. de Assis, L. V. M., Locatelli, J. and Isoldi, M. C. 2014. The role of key genes and pathways involved in the tumorigenesis of Malignant Mesothelioma. *Biochim. Biophys. Acta* **1845**: 232–247. [Medline]
5. Dunning, D., Monnet, E., Orton, E. C. and Salman, M. D. 1998. Analysis of prognostic indicators for dogs with pericardial effusion: 46 cases (1985-1996). *J. Am. Vet. Med. Assoc.* **212**: 1276–1280. [Medline]
6. Ehrhart, N., Ehrhart, E. J., Willis, J., Sisson, D., Constable, P., Greenfield, C., Manfra-Maretta, S. and Hintermeister, J. 2002. Analysis of factors affecting survival in dogs with aortic body tumors. *Vet. Surg.* **31**: 44–48. [Medline] [CrossRef]
7. Machida, N., Tanaka, R., Takemura, N., Fujii, Y., Ueno, A. and Mitsumori, K. 2004. Development of pericardial mesothelioma in golden retrievers with a long-term history of idiopathic haemorrhagic pericardial effusion. *J. Comp. Pathol.* **131**: 166–175. [Medline] [CrossRef]
8. Stafford Johnson, M., Martin, M., Binns, S. and Day, M. J. 2004. A retrospective study of clinical findings, treatment and outcome in 143 dogs with pericardial effusion. *J. Small Anim. Pract.* **45**: 546–552. [Medline] [CrossRef]