

## Contrast-Enhanced Ultrasound Defines Vascularization Pattern of Hamartomatous Colonic Polyps in Peutz-Jeghers Syndrome

Radu Badea<sup>\*†</sup>, Lidia Ciobanu<sup>\*†</sup>, Emil Boțan<sup>†</sup>, Cristina Pojoga<sup>†</sup>, and Marcel Tanțău<sup>\*†</sup>

<sup>\*</sup>Iuliu Hatieganu University of Medicine and Pharmacy, and <sup>†</sup>Regional Institute of Gastroenterology and Hepatology, 3rd Medical Clinic, Cluj-Napoca, Romania

The hamartomatous polyps in Peutz-Jeghers syndrome may have malignant potential. To differentiate between hamartomatous and adenomas polyps, vascular characterization can be assessed using noninvasive procedures, such as contrast-enhanced ultrasound (CEUS). The neo-angiogenic characteristics of colorectal adenomas and carcinomas are expressed as an anarchic vascular pattern observed on CEUS. Using CEUS in a patient with Peutz-Jeghers syndrome, we describe for the first time the vascularization of a hamartomatous colonic polyp that exhibits a hierarchy branching pattern. (**Gut Liver 2014;8:680-682**)

**Key Words:** Colonic polyps; Peutz-Jeghers syndrome; Ultrasound

### INTRODUCTION

As the malignant potential of polyps in Peutz-Jeghers syndrome is still debated,<sup>1</sup> it is important to differentiate between a typical hamartomatous polyp and an adenoma, using noninvasive methods.

Contrast-enhanced ultrasonography (CEUS) enables the detection of very slow blood flow in vessels measuring as little as 40 microns. This feature is extremely valuable in the characterization of different vascular patterns that could indicate a benign, organized vascularization pattern or a neo-angiogenesis process and could be used on large colonic polyps. CEUS is performed by using high frequency transducers, the intravenous contrast agent SonoVue (Bracco, Milan, Italy) and "Tissue Harmonic Imaging" technique in the presence of a low mechanical index. After bolus injection of 4.8 mL of contrast agent in a peripheral vein, the capillary filling by a contrast-agent is suggested by an enhancement of the colonic wall echogenicity that starts ap-

proximately in 10 to 15 seconds and proceeds up to 30 seconds, when a peak intensity is reached (arterial phase). This phase is followed by the venous phase, in which the contrast agent is distributed to the whole capillary bed and the concentration slowly decreases followed by the excretion of contrast agent through the lungs.<sup>2</sup> This method appreciates the microcirculation in bowel segments in terms of qualitative and quantitative parameters, being able to differentiate benign pathological lesions from neoplasia.<sup>2</sup>

The vascularization pattern of hamartomatous colonic polyps is not well characterized in the literature. As hamartomatous polyps have typical histological features, consisting of a branched, tree-like smooth muscle core covered with normal epithelium it might be supposed that a benign, organized vascular pattern is present.

Using CEUS in a patient with Peutz-Jeghers syndrome we describe for the first time the vascularization of a hamartomatous colonic polyp, which shows hierarchy branching pattern.

### CASE REPORT

A 42-year-old woman diagnosed as Peutz-Jeghers syndrome 19 years ago presented in ultrasound department for left upper abdominal quadrant mild pain. Focusing ultrasound examination on digestive tract on the left upper quadrant abdomen a hypoechoic polypoid mass was identified on colonic wall, protruding into the lumen, measuring 4 cm, with Doppler signal (Fig. 1A). For a better characterization of vascular pattern of this polypoid mass, a CEUS examination was performed. SonoVue contrast agent was used, consisting of stabilized gas microbubbles (1 to 7  $\mu\text{m}$ ) which remain in the circulation and produce a nonlinear harmonic response that can be separated from the tissue signal using contrast harmonic ultrasound. We used

Correspondence to: Lidia Ciobanu

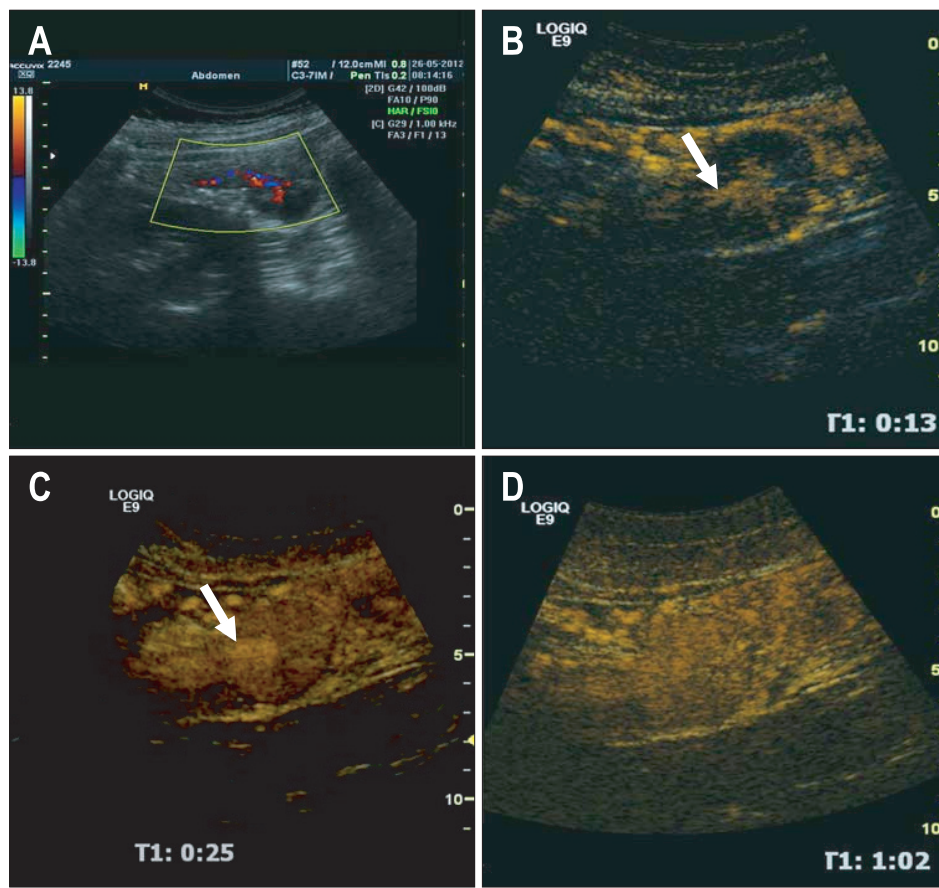
Regional Institute of Gastroenterology and Hepatology, 3rd Medical Clinic, 19-21, Croitorilor Street, Cluj-Napoca 400162, Romania

Tel: +40745042155, Fax: +40264455995, E-mail: ciobanulidia@yahoo.com

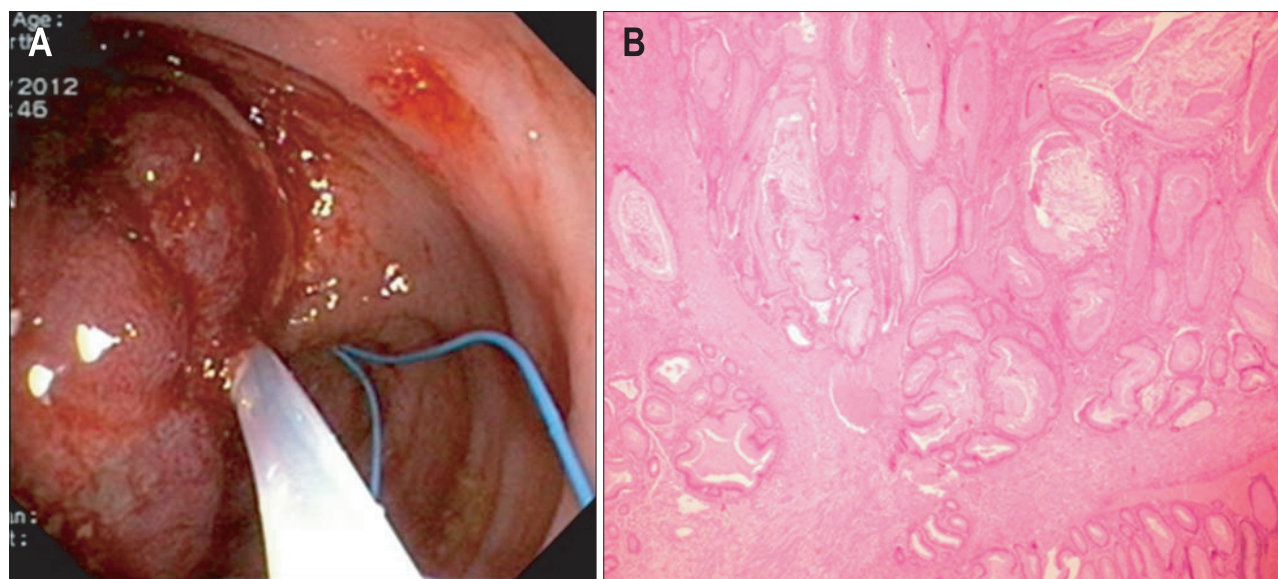
Received on February 8, 2014. Revised on March 30, 2014. Accepted on April 27, 2014.

pISSN 1976-2283 eISSN 2005-1212 <http://dx.doi.org/10.5009/gnl14044>

© This is an Open Access article distributed under the terms of the Creative Commons Attribution Non-Commercial License (<http://creativecommons.org/licenses/by-nc/3.0>) which permits unrestricted non-commercial use, distribution, and reproduction in any medium, provided the original work is properly cited.



**Fig. 1.** Abdominal ultrasound focused on the digestive tract on the left upper abdominal quadrant. (A) B mode and color Doppler showing a hypo echoic polypoid mass on the colonic wall and protruding into the lumen with Doppler signal of the pedicle. (B) Contrast-enhanced ultrasonography (CEUS) arterial phase (13 seconds after contrast injection) of the colonic polypoid mass showing an uptake of contrast media early in the arterial phase and displaying a well-defined arborized pattern (arrow). (C) CEUS arterial phase (at 25 seconds after contrast injection) of the colonic polypoid mass showing the pedicle (arrow) and polyp mass from the surrounding tissue. (D) CEUS late phase (1 minute and 8 seconds after contrast injection) of the polypoid mass revealing no wash-out of contrast agent in the polyp mass.



**Fig. 2.** (A) Endoloop-assisted polypectomy. (B) Histological examination showing hamartomatous features with an arborizing pattern of smooth muscle proliferation (H&E stain,  $\times 40$ ).

a multiband probe with independent transmission and registration frequencies, which optimized the capture of the nonlinear harmonics produced by micro-bubble resonance. Using a low mechanical index the destruction of micro-bubbles was minimal

and the arterial and venous phases were registered continuously. CEUS revealed an uptake of contrast agent early in arterial phased (at 13 seconds after contrast injection), in a well defined arborized pattern (Fig. 1B), allowing a characterization of the

main arterial vessel at 25 seconds after contrast injection (Fig. 1C) without a rapid wash-out in venous phase (Fig. 1D). CEUS depicted both the polyp and the diameter of main arterial vessel: 10 mm, suggesting an increased risk of bleeding after polypectomy. In venous and late phases a slow wash-out was detected. Postprocedural quantitative analysis of tissue perfusion on arterial phase revealed the same perfusion pattern in polyp and surrounded tissue. Endoloop-assisted polypectomy was performed (Fig. 2A) and histological examination revealed hamartomatous features with arborizing pattern of smooth muscle proliferation (Fig. 2B).

## DISCUSSION

The malignant potential of hamartomatous polyps is still debated. Even there are reports about coexisting on the same polyp features of hamartomatous polyp and adenoma, recent molecular data regarding germ line *STK11* mutations argue that hamartomatous polyp carry no inherent risk of malignancy, adenomas being responsible for cancer development in Peutz-Jeghers syndrome.<sup>1</sup>

Assessing the vascularization of tissues with malignant potential is a very dynamic field of research. CEUS is a noninvasive technique that is able to characterize the vascular pattern of different pathological processes and subsequently to differentiate between a benign, organized vascular pattern and an anarchic vascularization found in colorectal adenomas and carcinoma.<sup>3</sup>

Tumor-type specific angiogenesis phenotype found in colorectal adenomatous lesions describes irregular, larger and thicker vessels, in anarchic patterns, different from branching organized vessels found in normal tissue.<sup>3</sup> This neo-angiogenesis model corresponds in CEUS technique with an increased arterial uptake of contrast agent with rapid venous wash out, due to multiple arteriovenous fistulas. Using CEUS, Zhuang *et al.*<sup>4</sup> reported a quantification of tumor vascularity of colorectal adenocarcinomas, using time-intensity curve parameters.

Hamartomatous polyp presented in this case has different vascularity pattern than adenomatous lesions; it shows hierarchy branching pattern, with the same vascular pattern as

surrounded tissue, an argument for nonmalignant potential of hamartomatous polyps. In venous and late phases a slow wash-out also argues for benignity. Another important aspect is the ability of CEUS to depict the diameter of arterial vessel in the polyp pedicle, suggestive for a potential risk of bleeding after polypectomy.

Considering this case, CEUS might be regarded as a complementary method in assessing the vascularization patterns of polyps in Peutz-Jeghers syndrome that is able to differentiate a hamartomatous polyp from an adenoma with malignant potential.

## CONFLICTS OF INTEREST

No potential conflict of interest relevant to this article was reported.

## ACKNOWLEDGEMENTS

This paper was published under the frame of European Social Found, Human Resources Development Operational Programme 2007-2013, project nr. POSTDRU 159/1.5/138776: TRANSCENT.

## REFERENCES

1. Jansen M, de Leng WW, Baas AF, et al. Mucosal prolapse in the pathogenesis of Peutz-Jeghers polyposis. *Gut* 2006;55:1-5.
2. Badea R, Ciobanu L, Gomotirceanu A, Hagiu C, Socaciu M. Contrast ultrasonography: a necessary procedure for a better characterization of digestive tract pathology. *Med Ultrason* 2010;12:73-80.
3. Konerding MA, Fait E, Gaumann A. 3D microvascular architecture of pre-cancerous lesions and invasive carcinomas of the colon. *Br J Cancer* 2001;84:1354-1362.
4. Zhuang H, Yang ZG, Wang ZQ, et al. Features of time-intensity curve parameters of colorectal adenocarcinomas evaluated by double-contrast enhanced ultrasonography: initial observation. *Eur J Radiol* 2012;81:677-682.