

# Current role of endoscopic combined intrarenal surgery in the management of renal stones: A scoping review

Carlotta Nedbal<sup>1,2\*</sup>, Victoria Jahrreiss<sup>2,3</sup>, Clara Cerrato<sup>2</sup>, Daniele Castellani<sup>1</sup>,  
Wissam Khalid Kamal<sup>4</sup>, Zeeshan Hameed<sup>5</sup>, Vineet Gauhar<sup>6</sup>, Patrick Juliebo-Jones<sup>7</sup>,  
Lazaros Tzelves<sup>8</sup>, Panagiotis Kallidonis<sup>9</sup>, Theodoros Tokas<sup>10</sup>, Bhaskar K. Somani<sup>2</sup>

<sup>1</sup>Urology Unit, Azienda Ospedaliero-Universitaria Delle Marche, Università Politecnica Delle Marche, Ancona, Italy,

<sup>2</sup>Department of Urology, University Hospital Southampton NHS Trust, Southampton, UK, <sup>3</sup>Department of Urology, Comprehensive Cancer Center, Medical University of Vienna, Vienna, Austria, <sup>4</sup>Department of Urology, King Fahad Hospital, Jeddah, Saudi Arabia, <sup>5</sup>Department of Urology, Father Muller Medical College, Mangalore, Karnataka, India,

<sup>6</sup>Department of Urology, Ng Teng Fong General Hospital, NUHS, Singapore, <sup>7</sup>Department of Urology, Haukeland University Hospital, Bergen, Norway, Department of Clinical Medicine, University of Bergen, Bergen, Norway, EAU YAU Urolithiasis Group, <sup>8</sup>Department of Urology, Sismanogleio Hospital, National and Kapodistrian University of Athens, Athens,

<sup>9</sup>Department of Urology, University of Patras, Greece, <sup>10</sup>Department of Urology and Andrology, General Hospital Hall I.T., Milser Str. 10, Hall in Tirol, 6060, Austria

\*E-mail: carlottanedbal@gmail.com

## ABSTRACT

**Introduction:** This study aims to review the current role of endoscopic combined intrarenal surgery (ECIRS) in the management of renal stones, with a focus on its efficacy and safety. The secondary outcome was to highlight the tips and tricks to improve the urologist's experience with ECIRS.

**Methods:** A scoping review of the literature, in accordance with the Preferred Reporting Items for Systematic Reviews and Meta-analysis guidelines, was performed, using ECIRS and flexible ureteroscopy and percutaneous nephrolithotomy as the search terms. All original articles were screened and included.


**Results:** Thirty-three studies were included in the analysis. ECIRS showed a good efficacy and safety profile, with an excellent stone-free rate and a low rate of complications, mostly Clavien–Dindo I/II. With ECIRS, a reduction in the need for multiple access tracts was noted and direct visualization of the targeted calyx during the puncture increased the ability to attain transpapillary punctures, thereby reducing the amount of bleeding.

**Conclusion:** ECIRS, as the first-line minimal access intervention, is safe and efficacious, particularly for achieving a stone-free status in patients with large complex stones in a single stage. The ability to gain access under direct vision and the reduction in the number of tracts, in both the supine and the prone positions, makes this procedure an attractive surgical choice.

## INTRODUCTION

The management of complex renal stones has always been a major challenge for the practicing urologist. Different approaches and surgical strategies have been proposed over the time to achieve a one-step

stone-free rate (SFR), thereby avoiding the need for multiple procedures with a consequent increase in the cost and the likelihood of complications.<sup>[1]</sup> Endoscopic combined intrarenal surgery (ECIRS) was first introduced in 2008,<sup>[2]</sup>

Access this article online	
Quick Response Code:	Website: www.indianjurol.com
	DOI: 10.4103/iju.iju_249_23

This is an open access journal, and articles are distributed under the terms of the Creative Commons Attribution-NonCommercial-ShareAlike 4.0 License, which allows others to remix, tweak, and build upon the work non-commercially, as long as appropriate credit is given and the new creations are licensed under the identical terms.

**For reprints contact:** WKHLRPMedknow\_reprints@wolterskluwer.com

**Received:** 29.06.2023, **Revised:** 23.08.2023,

**Accepted:** 19.09.2023, **Published:** 29.09.2023

**Financial support and sponsorship:** Nil.

**Conflicts of interest:** There are no conflicts of interest.

combining an antegrade and a retrograde approach, with the aim to perform the puncture of the collecting system under direct vision and “to pass the ball” during the percutaneous fragmentation, thus speeding up the lithotripsy and achieving higher SFRs.<sup>[3]</sup> Despite the promising features of ECIRS, a clear advantage over the standard percutaneous nephrolithotomy (PCNL), in the terms of single-stage SFR, has still not been demonstrated.<sup>[4]</sup>

Several studies and systematic reviews have compared PCNL with ECIRS, pointing out the benefits and the advantages of this new approach.<sup>[5]</sup> However, the procedure has its own limitations, such as, the need for two experienced surgeons, two camera stack systems, and the availability of two energy sources.<sup>[6]</sup> Despite these shortcomings, there are advantages of ECIRS over the standard or even the mini-invasive PCNL and the increasing interest in this procedure has led to several trials comparing its feasibility and efficacy to PCNL.<sup>[7]</sup> The most interesting characteristics of ECIRS is the possibility to avoid multiple renal accesses and to provide a framework for an individualized approach for each patient.<sup>[8,9]</sup> To this aim, ECIRS has the potential to surpass PCNL in the management of patients with complex and/or multiple renal stones.<sup>[10]</sup>

With this scoping review, we aim to draw a picture of the current role of ECIRS in the management of large and complex renal stones, with an effort to better understand the most important features and highlighting the most used and efficient strategies such as the choice of patients’ position, instruments, and the post-surgical management.

## MATERIALS AND METHODS

### *Literature search and article selection*

A scoping review of the literature was performed by two independent authors (CN, VJ) and the conflicts were resolved by a senior author (BKS). A search on PubMed, Cochrane database and Google Scholar for the eligible studies was performed in accordance to the Preferred Reporting Items for Systematic Reviews and Meta-analysis guidelines.<sup>[11]</sup> The MeSH terms and keywords employed were as follows: “endoscopic combined intrarenal surgery” and “flexible ureteroscopy and percutaneous nephrolithotomy.” Articles were first screened by the title and full-text and a full-text analysis of the eligible articles was then performed for inclusion. Studies in language other than English were excluded during the screening process. Studies included in this review were then subjected to a narrative synthesis for analysis.

### *Study inclusion*

Randomized controlled trials (RCTs), quasi-RCTs, non-randomized comparative studies, and single-arm case series were considered for inclusion. Systematic reviews, meta-analyses, commentaries, editorials only, expert

opinions, case reports, book chapters, reviews, and congress abstracts were excluded. Additional exclusion criteria were the absence of abstract, absence of outcome data, and incomplete technical description of the surgical technique. Preclinical and animal studies were also not considered for inclusion.

### *Patients’ characteristics*

Patients who underwent ECIRS for urolithiasis were included in the study population. There were no limitations regarding the age, sex, body mass index, American Society of Anaesthesiologists score, presence of congenital or acquired abnormalities of the urinary tract, or urinary tract diversion. Studies reporting on staghorn stones, complex stones, and concomitant renal and ureteral stones were included, while those on the application of ECIRS for the treatment of cancer were excluded.

### *Types of interventions*

Only those studies with a clear description about the application of simultaneous combined retrograde ureteroscopy (URS) and percutaneous lithotripsy, namely ECIRS or combined intrarenal surgery, were included. No limitation regarding the patient position (prone, prone modified, supine, supine modified, etc.), the choice of instruments (rigid-flexible URS, access sheet, type of percutaneous access), and the type of energy source were applied.

### *Objectives and outcome measure*

The primary outcome of this review was to assess the efficacy and safety of ECIRS, and the objectives were the SFR and the complication rate (according to Clavien–Dindo grading). Additional outcomes were: the operative time, length of hospital stay, hemoglobin drop, and a qualitative analysis of the reported complications. The secondary objective was to identify the tips and tricks for improving the outcomes of ECIRS regarding the patient’s position during the surgery, and the strategy for percutaneous access.

### *Literature screening*

The literature search identified 509 studies and four hundred and twenty-nine of these were duplicates and were excluded after screening the title and the abstract. Eighty full-texts were screened for inclusion. A total of 47 studies were further excluded and 33 were finally included. Figure 1 shows the flow diagram of the literature search.

## RESULTS

Among the 33 included studies, there were two prospective RCTs,<sup>[12,13]</sup> five prospective non-RCTs,<sup>[14-18]</sup> five prospective single-arm case series,<sup>[2,19-22]</sup> eleven retrospective comparative studies,<sup>[23-33]</sup> and ten retrospective single-arm case series.<sup>[6,34-42]</sup> The level of evidence for each study is summarized in Table 1. With only two prospective RCTs,

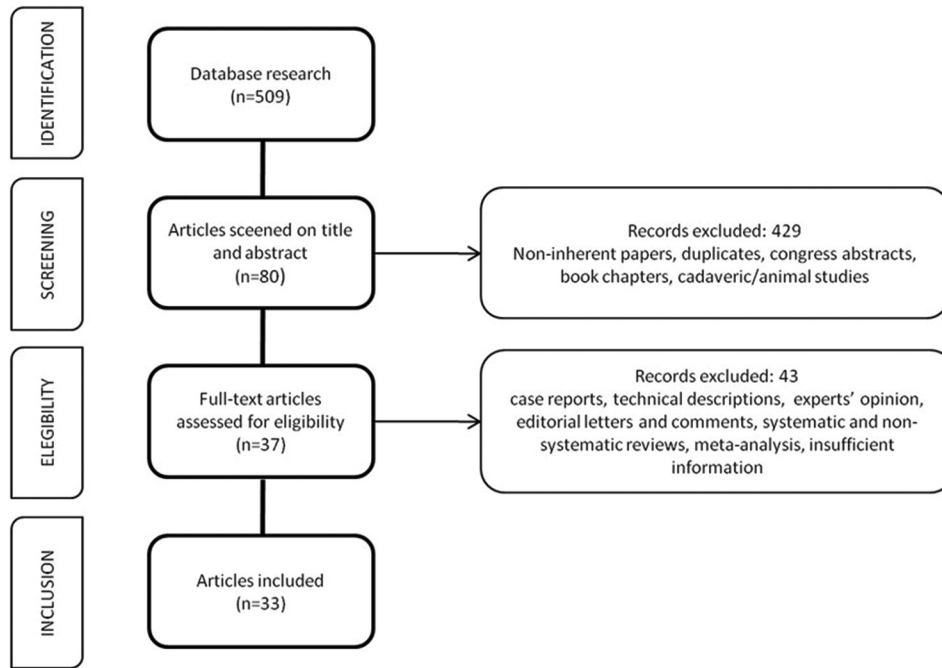


Figure 1: Preferred Reporting Items for Systematic Reviews and Meta-analysis flow diagram

the overall quality of evidence can be graded as “low” and the risk of bias as “serious.”

Twenty-one studies reported the SFR as the primary objective, one studied reported on the safety profile as the primary outcome, six studies focused on the influence of patient’s position during the surgery, and five studies compared the different strategies for renal puncture [Table 1]. Intraoperative variables (patient position, energy sources, instrumentation, strategy for renal puncture, and exit strategy) are summarized in Table 2. Table 3 shows the intra- and postoperative results.

**Efficacy: Stone-free rate**

Stone-free status was defined variably among the included studies, ranging from <4 mm (in eighteen studies) to smaller sized fragment to the complete absence of any residual fragment. A heterogeneity was also found in the choice of imaging for the detection of residual stones: computed tomography (CT) kidney–ureter–bladder (KUB), X-ray, ultrasound (US), or a combination of these modalities were variably used. The followup imaging to assess the postoperative SFR was also planned at a variable time post-operatively. The mean SFR was >80%, ranging from 52% to 98.3%. Smaller stone volume and lower number of involved calyces positively correlated with a higher SFR. In ECIRS, an optimal stone clearance rate could be achieved despite the use of smaller instrumentation such as mini-PCNL and with a single-access tract.

**Safety: Complications**

The reported rate of complications ranged from 5.8% to 70.6%, but most of the complications were classified as

Clavien–Dindo I or II, with occasional reports of grades III or IV complications and none reported a grade V complication. According to the studies that compared ECIRS with PCNL, the former has a superior safety profile with a lower rate of complications. Trials with higher rates of perioperative complications denoted longer operative time and higher stone burden as the risk factors for higher complication rates. In particular, one study<sup>[39]</sup> focused on identifying the risk factors for sepsis and found that the number of involved calyces, stone surface, and previous history of febrile urinary tract infection (UTI) correlated with higher rates of sepsis. On analyzing the procedure-related factors that could influence the risk of complications, only one study that compared the patient’s positions, found that the prone split-leg (PSL) position was associated with an increased risk of postoperative febrile UTI, without an increase in the risk of postoperative sepsis.<sup>[32]</sup> In this study, the authors reported a higher risk of injury to the urinary tract in the PSL cohort, a finding not reported in any of the other studies. The reported amount of blood loss was usually acceptable, with a median drop in the hemoglobin level of <2.5 g/dL, and a reported range of 0.4–2.4 mg/dL.

**Efficiency: Operative time, hospital stay, number of access tracts**

The reported operative time among the included studies was very variable, with a range of 42–140 min, and was probably affected by the different definitions of time calculation (i.e., from anesthesia to checkout time versus from cystoscopy to catheterization) or by the biases due to re-positioning of the patient during some of the procedures. Still, the operative time for ECIRS appears to be shorter as

**Table 1: Characteristics and targets of the studies**

Author	Type of study	Level of evidence	Period of surgery	Number of patients	Target of study	Outcomes
Tabei, 2016	RSACS	4	April 2010–October 2014	370	Complication	Predictors of sepsis
Chen, 2022	RCS	3	January 2018–September 2021	34	Efficacy	ECIRS versus PCNL
Gao, 2019	RCS	3	March 2013–December 2016	140	Efficacy	PCNL versus URS versus ECIRS
Gokce, 2019	PnRCT	2	September 2016–March 2018	137	Efficacy	Antegrade versus retrograde nephroscopy
Goktug, 2023	RCS	3	January 2007–January 2022	177	Efficacy	PCNL versus ECIRS
Hamamoto, 2014	PCS	4	February 2004–January 2013	161	Efficacy	ECIRS versus mini-PCNL versus standard PCNL
Jung, 2018	RSACS	4	August 2017–February 2018	30	Efficacy	Tips and tricks of ECIRS
Jung, 2022	RCS	3	August 2017–January 2019	100	Efficacy	SWL versus ECIRS
Kallidonis, 2022	PCS	4	January 2019–December 2021	33	Efficacy	Nonpapillary puncture
Kuroda, 2015	RCS	3	June 2010–September 2014	329	Efficacy	success versus nonsuccess
Leng, 2017	RCS	3	March 2014–January 2016	87	Efficacy	ECIRS versus PCNL
Manikandan, 2016	RSACS	4	June 2012–March 2016	43	Efficacy	Simultaneous renal and ureteral calculi
Mishra, 2022	PnRCT	2	January 2016–December 2019	60	Efficacy	ECIRS versus PCNL/URS
Ping, 2016	RSACS	4	January 2012–January 2016	26	Efficacy	Post-PCNL residual stone
Schulster, 2019	PCS	4	August 2017–January 2018	110	Efficacy	Prediction of SFR
Scoffone, 2008	PCS	4	April 2014–December 2007	127	Efficacy	ECIRS in GMSV position
Tominaga, 2023	RSACS	4	July 2019–December 2021	61	Efficacy	Vacuum-assisted mini-ECIRS
Usui, 2020	RCS	3	April 2009–May 2016	256	Efficacy	Mini-ECIRS versus ECIRS
Wang, 2022	RSACS	4	September 2017–January 2021	96	Efficacy	Multiple stone
Wen, 2016	PRCT	1	May 2012–Oct 2014	67	Efficacy	Mini-PCNL versus ECIRS
Yamashita, 2017	RSACS	4	February 2008–April 2015	75	Efficacy	Predictors of SFR
Zaho, 2019	PnRCT	2	January 2018–Oct 2019	140	Efficacy	ECIRS versus mini-PCNL
Abouelgheed, 2022	PRCT	1	Oct 2018–August 2021	66	Position	Prone-split-leg versus GMSV
Hamamoto, 2014	RSACS	4	December 2010–January 2013	60	Position	Large renal calculi
Hamamoto, 2015	RSACS	4	December 2010–August 2013	42	Position	Staghorn calculi
Hamamoto, 2021	RCS	3	January 2014–December 2018	218	Position	prone-split-leg versus GMSV
Liu, 2022	RCS	3	January 2018–June 2021	83	Position	PCNL versus ECIRS
Otsuka, 2022	RCS	3	January 2018–December 2022	226	Position	LD versus GMSV
Hamamoto, 2017	PCS	4	April 2014–July 2015	30	Puncture system	Real-time virtual sonography versus US-guided puncture
Inoue, 2016	RSACS	4	January 2013–September 2015	40	Puncture system	Wideband doppler US for puncture
Sugino, 2018	PnRCT	2	July 2013–April 2014	30	Puncture system	US versus URS assisted
Taguchi, 2021	RCS	3	January 2016–April 2020	313	Puncture system	URS assisted versus US
Unno, 2021	PnRCT	2	January 2016–April 2020	221	Puncture system	Double lumen AS versus one-shot dilation

PRCT=Prospective randomized controlled trial, PnRCT=Prospective nonrandomized controlled trial, PCS=Prospective case series, RCS=Retrospective comparative study, RSACS=Retrospective single arm case series, URS=Ureteroscopy, US=Ultrasound, ECIRS=Endoscopic combined intrarenal surgery, PCNL=Percutaneous nephrolithotomy, SWL=Shockwave lithotripsy, SFR=Stone-free rate, GMSV=Galdakao Modified Supine Valdivia, LD: Lateral decubitus, AS=Access sheath

compared to that of PCNL and is not clearly affected by the choice of instruments. The length of hospital stay also varied significantly among the various studies, from shorter than 2 days to longer than 10 days.

Twenty-one studies reported on the feasibility to achieve a complete SFR with a single-access in all the patients. Six studies reported a need of up to two additional access tracts in a few cases, but 78.8%–98.6% of the patients were still managed by a single access tract. In the remaining six studies, the number of percutaneous tracts was not specified. The reduced need of multiple access tracts was more evident in the trials comparing ECIRS with standard or mini-invasive PCNL.

#### **Tips and tricks: Position, puncture system, exit strategy**

Among the studies, the most frequently used patient positions were the PSL and the Galdakao Modified Supine

Valdivia (GMSV) position [Figure 2], but ECIRS was also performed in the lateral decubitus position.<sup>[33]</sup> Of the six studies that compared the patient's position as the main outcome, a gold standard position for ECIRS could not be clearly identified. In fact, both the PSL and the GMSV positions had comparable SFR and complication rates.<sup>[12,32,34,35,40,43]</sup> ECIRS performed in the GMSV position seems to have slightly longer operative time as compared to the PSL and lateral decubitus positions, which could be explained by the larger exposed surface for the renal puncture in the PSL position that allows for a rapid antegrade access. Some of the authors who chose PSL for ECIRS gained the ureteric access in the lithotomy position, and some did not mention whether they changed the patient's position or not. Others, for example, Hamamoto and Goktug, clarified that an ureteric access was obtained in the prone position in all the cases.<sup>[25,32]</sup>

**Table 2: Operative features**

Author	Position	Percutaneous access	Ureteroscope	UAS	URS energy	PCNL energy	Puncture guidance	Nephrostomy
Abouelgreed, 2022	N/A	18Fr Amplatz	7.5F Flex X-2, Karl Storz	10-12Fr	Hoi: YAG	Pneumatic	Fluoroscopic	Yes, 18Fr
Chen, 2022	GMSV	17.5Fr or 22Fr	Flexible	N/A	Holmium laser	Pneumatic	US + fluoroscopic	Not always
Gao, 2015	PSL	18Fr	Flexible	N/A	Holmium laser	Ultrasonic	US + URS	Yes, 16Fr
Gokce, 2019	N/A	24Fr Amplatz	Flex X-2, Karl Storz	9.5-11.5Fr	Laser	Laser or pneumatic	Fluoroscopic	No
Goktug, 2023	GMSV	30Fr Amplatz	7.5F flexible	9.5-11.5Fr	Holmium laser	Pneumatic or ultrasonic	URS + fluoroscopic	Yes, 14Fr
Hamamoto, 2014	PSL	18Fr Karl Storz	Flex X-2, Karl Storz	12-14Fr	Hoi: YAG	Pneumatic	US + fluoroscopic	Yes, 18Fr
Hamamoto, 2014	PSL	18Fr Karl Storz	Flex X-2, Karl Storz	14Fr	Hoi: YAG	Pneumatic	US + fluoroscopic	Yes, 18Fr
Hamamoto, 2015	PSL	18Fr Karl Storz	Flex X-2, Karl Storz	12-14Fr	Hoi: YAG	Pneumatic	US + fluoroscopic	Yes, 18Fr
Hamamoto, 2017	PSL	18Fr Karl Storz	URF-V2; Olympus	12-14Fr	Hoi: YAG	Pneumatic	US + URS/fluoroscopy	Not always
Hamamoto, 2021	PSL or GMSV	17.5-19.5Fr Karl Storz	URF-V2; Olympus; URF-P6; Olympus; Flex X-2; Karl Storz	Variable sizes	Hoi: YAG	Pneumatic	US + fluoroscopic	No
Inoue, 2016	GMSV	18-19.5Fr Karl Storz	Flex X-2, Karl Storz	9.5-11.5Fr	Holmium laser	Pneumatic	US	Yes, 14-16Fr
Jung, 2018	GMSV	18Fr cook medical; 24Fr boston scientific	Flexible	N/A	Holmium laser	Pneumatic	Preoperative nephrostomy	N/A
Jung, 2022	GMSV	18Fr cook medical; 15-16Fr Karl Storz; 24/30Fr boston scientific	Flexible	11-13Fr	N/A	N/A	US + fluoroscopic	N/A
Kallidonis, 2022	PSL	22Fr or 30Fr	Flex-XC, Karl Storz	12-14Fr	Hoi: YAG	Pneumatic	Fluoroscopic	Yes, 20-24r or 16-18Fr
Kuroda, 2015	GMSV	24Fr or 30Fr	Flex X-2, Karl Storz	11-13/13-15Fr	Hoi: YAG	Pneumatic	URS/US + fluoroscopic	N/A
Leng, 2017	Oblique supine	16Fr	URF-P5, Olympus	N/A	Holmium laser	Holmium	US	Yes, 16Fr
Liu, 2022	Modified PSL	20Fr	8-9.5F Wolf ureteroscope	12-14Fr	Holmium laser	Pneumatic or Holmium laser	US + fluoroscopic	Yes, 18Fr
Manikandan, 2016	GMSV	16Fr Karl Storz	N/A	N/A	Pneumatic	Pneumatic	US + fluoroscopic	Not always, 12Fr
Mishra, 2022	GMSV	16Fr Karl Storz	6-7.5F URS, Richard Wolf	N/A	N/A	Laser	US + fluoroscopic	No
Otsuka, 2022	LD or GMSV	26Fr	URF-P5, Olympus	N/A	N/A	Hoi: YAG	US + URS	Not always
Ping, 2016	GMSV	24Fr	Olympus flexible ureteroscope	14Fr	Holmium laser	Pneumatic or ultrasonic	US	Yes, Foley catheter
Schulster, 2019	PSL	18F3 or 30Fr Karl Storz	Flex-XC, Karl Storz	11-13Fr	Hoi: YAG	Pneumatic	URS + fluoroscopic	No
Scoffone, 2008	GMSV	24Fr or 30Fr	N/A	N/A	Laser	Pneumatic ultrasonic	US + fluoroscopy±URS	Yes
Sugino, 2018	PSL	N/A	Flexible	12-14Fr	N/A	N/A	US±URS	Not always
Tabei, 2016	GMSV	24Fr Karl Storz	Flex X-2, Karl Storz	11-13/13-15Fr	Hoi: YAG	Pneumatic	US + fluoroscopic	Not always, 14-22Fr
Taguchi, 2021	PSL or GMSV	16.5-17.5Fr or 21-22Fr Karl Storz	N/A	N/A	Hoi: YAG	Pneumatic	US±URS	Not always
Tominaga, 2023	VFF or PSL	14-16Fr ClearPetra	URF-P7, Olympus	9.5-11.5/10-12Fr	Hoi: YAG	Hoi: YAG	US + fluoroscopic	Yes, 14Fr
Unno, 2021	PSL or GMSV	16.5/19.5 Fr Karl Storz	N/A	N/A	Laser	Pneumatic	US + URS	Not always
Usui, 2020	GMSV	16.5Fr, 24Fr or 30Fr Karl Storz	Flexible	11-13/13-15Fr	Hoi: YAG	Pneumatic	US + fluoroscopic	±14-20Fr
Wang, 2022	Modified PSL	22-24Fr	Flex X-2, Karl Storz	12-14Fr	Hoi: YAG	Pneumatic	US	No
Wen, 2016	GMSV	20Fr Amplatz	URF-V2, Olympus	12-14Fr	Hoi: YAG	Hoi: YAG	US	Yes, 16Fr
Yamashita, 2017	PSL	16.5-19.5Fr	URF-P5/URF-V; Olympus	12-14/14-16Fr	Hoi: YAG	Pneumatic	US + fluoroscopic	Yes, 16Fr
Zaho, 2019	GMSV	16-18Fr	7.5F flexible	12-14Fr	Holmium laser	Holmium laser	US + fluoroscopic	Yes

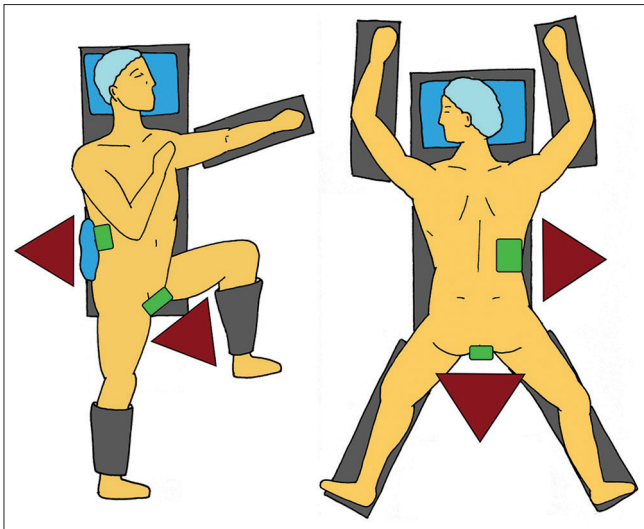
URS = Ureteroscopy, US = Ultrasound, GMSV = Galdakao Modified Supine Valdivia, PCNL = Percutaneous nephrolithotomy, UAS = Ureteral access sheath, PSL = Prone split legs, LD = Lateral decubitus, N/A = Not reported



**Table 3: Intra- and postoperative results**

Author	Mean stone size	SFR (%)	Definition of SF	Imaging for SFR	Mean operation time (min)	Mean hospital stay (days)	Hb drop (g/dL)	Number of tracts	CR (%)	Clavien >II
Abouelgreed, 2022	6.65-6.78 cm <sup>2</sup>	87.87-90.9	<4 mm	KUB CT	118.87	6.7	125 mL (loss)	1	21.2	None
Chen, 2022	21.4 cm <sup>3</sup>	70.6	N/A	KUB X-ray + US	140.12	4.3	1.66	1-5	70.6	One IV
Gao, 2015	26 mm	97.8	<4 mm	KUB CT	63.27	7.4	67.98 mL (loss)	1	28.9	None
Gokce, 2019	29.6 mm	92.7	Absence of residual fragments of any size	KUB CT	80.6	N/A	0.8	1-2	5.8	None
Goktug, 2023	9.00 cm <sup>2</sup>	64.4	<4 mm	KUB X-ray + US	70	2	1.6	1-2	15.5	One IIIB, One IVb
Hamamoto, 2014	39.2 mm	87	<4 mm	KUB X-ray + US	120.5	7.0	1.04	1	10	None
Hamamoto, 2015	45.8 mm	83.3	<4 mm	KUB X-ray	143.2	6.8	1.14	1	21.4	None
Hamamoto, 2017	33.5-30.5 mm	73.3-87.7	<4 mm	KUB CT	102.2-102.9	5	0.93-1.39	1-4	20-33	None
Hamamoto, 2014	39.2 mm	86.7	<4 mm	KUB X-ray + US	120.5	7.0	1.06	1	10	None
Hamamoto, 2021	3.93-5.29 cm <sup>2</sup>	78.8-76.0	<3 mm	KUB X-ray + US	106.5-126.0	N/A	0.8-1.0	1-2	20.0-31.3	One III
Inoue, 2016	45.5 mm	97.5%	<4 mm	KUB X-ray + US	158.4±51	12.8	0.54	1	7.3	None
Jung, 2018	28.86 mm	80	N/A	N/A	89.23±36.14	3.6	N/A	1	N/A	N/A
Jung, 2022	28.7 mm	70.0	<3 mm	KUB X-ray	82.23±35.68	2	1.21	1	N/A	N/A
Kalidonis, 2022	35.0 mm	90.9	Absence of residual fragments of any size	KUB X-ray + US/KUB CT	47 (36-65)	3	1.2	1-3	9.1	None
Kuroda, 2015	4.41-13.08 cm <sup>2</sup>	65.3	<4 mm	KUB CT	125.53-132.44	7.2-9.0	N/A	1-3	15.5	Five V
Leng, 2017	5.171 cm	90.9	<4 mm	KUB CT	87.500	9.7	1.56	1	6.8	None
Liu, 2022	48.7 mm	84.4	<4 mm	KUB X-ray/CT	105.0	10.0	2.4	1	15.5	None
Manikandan, 2016	28.0 mm	97.7	<3 mm	KUB X-ray/CT	132.1	6	1.25	1-3	32.5	Two III
Mishra, 2022	16.8 mm	98.3	N/A	KUB X-ray	42.1	27.7 h	0.07	1	20.1	None
Otsuka, 2022	20.5-21.6 mm <sup>2</sup>	91.6-97.2	<2 mm	KUB X-ray	72-81	5	1.2-1.3	N/A	28-31.9	One III
Ping, 2016	39 mm	96.2	<4 mm	KUB X-ray	78.2	4.7	0.6	N/A	N/A	None
Schulster, 2019	33.3 mm	76	<2 mm	KUB CT	N/A	N/A	N/A	N/A	N/A	N/A
Scoffone, 2008	23.8 mm	81.9	Absence of residual fragments of any size	KUB CT	70	5.1	N/A	1	38.6	Eight III
Sugino, 2018	4.95-5.31 cm <sup>2</sup>	80-93.3	<4 mm	KUB X-ray	92.1-97.6	5.0-7.8	0.88-1.13	N/A	N/A	N/A
Tabei, 2016	7.14-8.83 cm <sup>2</sup>	N/A	N/A	N/A	126.5-123.3	N/A	N/A	1 to multiple	20.7	Eight III
Taguchi, 2021	6.22 cm <sup>3</sup>	65.8-72.6	<3 mm	KUB CT + X-ray	110	5.0	1.3	1-2	35.8	Eight III, Three IV
Tominaga, 2023	8.48 cm <sup>3</sup>	91.8	<4 mm	KUB X-ray/CT	117	11.0	N/A	1 or multiple	65.6	One IV
Uhno, 2021	6.08-6.05 cm <sup>3</sup>	N/A	Absence of residual fragments of any size	KUB CT	105.00-121.00	4-5	0.4-0.5	N/A	N/A	N/A
Usui, 2020	5.56-6.48 cm <sup>2</sup>	61.1-52.0	<4 mm	KUB CT	131.16-132.60	7.3-8.7	1.95-2.03	1	31.2-44.2	One III, Four IV
Wang, 2022	32.5 mm	78.1	<2 mm	KUB CT	82.2	6.5	0.9	1	16.7	None
Wen, 2016	6.89 cm <sup>2</sup>	87.88	<4 mm	KUB X-ray/CT	105.33	9.7	77.21 mL (loss)	1-2	48.5	Two IV
Yamashita, 2017	4.17 cm <sup>2</sup>	69.3	<4 mm	KUB CT	124	9	N/A	N/A	32.0	Three III
Zaho, 2019	6.40 cm <sup>2</sup>	88.06	<4 mm	KUB X-ray/CT	79.77	3	0.4	1	7.5	None

SFR = Stone free rate, CT = Computer tomography, KUB = Kidney-ureter-bladder, US = Ultrasound, Hb = Hemoglobin, CR = Complication rate, N/A = Not reported



**Figure 2:** Galdakao Modified Supine Valdivia on the left and prone-split-leg on the right. The positions of surgeons are represented by red triangles and the endoscopic accesses are shown by green squares

Renal puncture was usually performed under the fluoroscopic and US guidance.<sup>[10,12-14,17-19,21,23,27,28,31,32,35-41]</sup> Some studies reported on the utilization of a ureteroscopic-assisted calyx puncture, which could be very useful, particularly in the absence of hydronephrosis.<sup>[15,30]</sup> When dealing with a very large or a staghorn stone that completely obstructs the target calyx and restricts the immediate direct visualization of the puncture needle, some authors reported an initial retrograde fragmentation of the calculus. Hence, by removing a part of the stone one can “make space” and uncover the calyx, thus allowing for the scope to negotiate into an optimal position.<sup>[25]</sup> URS-guided renal puncture seems to result in lower blood loss and higher accuracy when compared with the standard US-guided puncture.<sup>[15]</sup> Another proposed system for achieving a percutaneous access is the real-time virtual sonography, which showed promising results in the trial by Hamamoto *et al.*<sup>[20]</sup> but was not investigated further, and its validity is not currently confirmed.

Exit strategies were also not standardized among the studies. It appears that the tendency to perform a tubeless procedure or at least reserving the placement of the nephrostomy tube to the complicated procedures, has increased with time and this has been embraced by the most recent studies. When placed, the safety nephrostomy tubes were usually medium sized, ranging from 12Fr to 16Fr in most of the studies. The majority of the authors agree on routinely leaving a ureteral pigtail stent after the surgery.

## DISCUSSION

ECIRS, despite being introduced in 2008, did not gain a significant popularity until the last decade, when it gained a world wide attention, as is witnessed by the increasing number of publications.<sup>[45]</sup> Gaining more and

more popularity, ECIRS has been added to the European Association of Urology Guidelines as a good alternative for the management of complex renal stones as compared to the standard PCNL.<sup>[44]</sup>

In our study, nine trials compared the efficacy of standard or mini-invasive PCNL with that of the ECIRS. Of them, only one study did not report a significant difference between the two procedures,<sup>[23]</sup> while the other eight, and particularly those which recruited a higher number of patients, reported a significant advantage of ECIRS, both in the terms of efficacy (i.e., SFR) and safety (complication rate and postoperative pain). At the same time, when treating complex renal stones such as the staghorn stones, the superiority of ECIRS over URS or extracorporeal shockwave lithotripsy is undeniable, as is also the case with PCNL.<sup>[27]</sup>

The mean stone size reported in each study is presented in Table 3. The authors have measured the stone burden variably, with some reporting the maximum diameter, some the surface, and some the volume of the stones. With only one exception (Mishra 2022, with  $16.8 \pm 4.33$  mm), all the studies reported a mean stone size of  $>2$  cm, despite the different definitions used. We believe that the stone burden can be considered comparable among the studies.

There is a large variation in the definition of stone-free status reported in the various studies. While 18 of 33 studies accepted residual fragments  $<4$  mm as nonsignificant, sometimes adding the absence of infection or any other symptom as a mandatory feature for defining the SFR. Others defined stone-free status with a threshold size for residual fragments as  $<3$  mm or  $<2$  mm, and only 4 studies defined success as the complete absence of any residual fragment at the follow up imaging.<sup>[2,14,16,19]</sup> Moreover, the imaging technique utilized to define the SFR was also very variable among the studies, with plain KUB X-ray, noncontrast-enhanced CT, or US being applied variably to verify the postoperative status, alone or in combination. When specified, the timing of radiological examination varied from day 1 post-ECIRS to 2- or 3-months following the surgery. It is well known that the reported rate of complete clearance is affected by the postoperative management schedules and the definition of SFR.

With these preconditions, it is difficult to satisfactorily state the superiority of ECIRS over PCNL in the terms of efficacy. However, at the same time, it is undeniable that despite the different definitions of SFR used, ECIRS obtained superior results as compared to PCNL,<sup>[13,17,18,21,23,24,28,29]</sup> contrary to the recent meta-analysis that showed a superior SFR in the favor of PCNL.<sup>[4]</sup> One clear advantage of ECIRS is indeed the direct visualization of all the renal cavities and the ureter, which helps the surgeons in achieving a complete clearance of the upper urinary tract and reduces the chances of a missed fragment.<sup>[45]</sup> Gökce *et al.* performed a comparative

study to evaluate whether the retrograde URS detects a higher number of residual fragments as compared to the anterograde view or not.<sup>[14]</sup> In their study, the authors were able to reach a SFR of 92.7% (defined as the absence of any residual stone at the noncontrast-enhanced CT 7–14 days after surgery) through the addition of a URS-driven check of all the renal cavities, before exiting. This final step of ECIRS is therefore recommended to ensure a complete clearance.

PCNL has been shown to have excellent results for the management of large/complex stones, with a general SFR of 57% for the staghorn stones, 66% for the complex stones, 75% with the application of standard technique with multiple accesses and even as high as 78% for the simpler stones.<sup>[46]</sup> Our review found that the reported SFR varied between 52% and 98.3%, with a mean value of 80%. Our results are in line with those reported in a recent systematic review by Cracco and Scoffone,<sup>[47]</sup> where they found a high SFR of 61%–97%, especially in cases with smaller stones and standard accesses, usually through a single percutaneous puncture. Kuroda *et al.* analyzed the possible predictors of SFR in a study of 329 patients and found a negative correlation between the SFR and the stone surface area (total stone surface >400 mm<sup>2</sup>) and the number of involved calyces (more than 1 calyx involved).<sup>[26]</sup>

In the terms of complication rate, the reported results were variable, again being influenced by the way these were described. Ranging from 5.8% to 70% among the studies included in our review, the complication rate was highly influenced by the inclusion of mild asymptomatic haematuria or postoperative pain as a Clavien I complication. What is evident is that the Clavien grade >II complications were uncommon, being reported in only 13 of the 33 studies and completely absent in the others. Hematuria and uncomplicated postoperative fever on the other hand were quite frequent and were independent of the exit strategy applied. Tabei *et al.*, in a retrospective study, analyzed the complication rate in 370 cases of ECIRS and found that the number of involved calyces (>4), stone surface area >500 mm<sup>2</sup> and a history of febrile UTI independently predicted the development of systemic inflammation response syndrome.<sup>[39]</sup>

ECIRS has a low rate of bleeding-related complications, possibly due to the endoscopic assistance during the percutaneous access or the size of the tract used. There are two major advantages of ECIRS in the terms of renal puncture: (1) the direct visualization of the renal collecting system allows for a more accurate puncture and reduces the need of multiple attempts;<sup>[15,30]</sup> (2) the addition of URS to the standard PCNL provides the PCNL surgeon with the ability to use a basket to move the stones from one calyx to another, thus reducing the need of multiple percutaneous tracts.<sup>[4,47]</sup> Both these features help in reducing the intraoperative and postoperative blood loss, which is

mainly related to the renal puncture.<sup>[48]</sup> In our review, the blood loss in patients undergoing ECIRS was minimal, with a median drop in the hemoglobin levels of <2.5 g/dL. A correlation between the blood loss and the size of the percutaneous access tract could not be found in our study, and the blood loss was comparable between the mini- and the standard-percutaneous accesses. At the same time, it is well known that multiple percutaneous tracts can increase the risk of bleeding.<sup>[49]</sup> Moreover, the patient's position did not influence the number of the percutaneous tracts performed. As shown in Table 3, a single-tract ECIRS was performed by many authors for both the procedures, while other used multiple accesses.

It is well known that larger the size of the percutaneous tract higher are the bleeding-related complications. But maintaining a size difference of 4F between the access tract and the nephroscope, the “rule of 4F”, helps with the outflow and maintains a low intrarenal pressure, thus reducing the chances of postoperative fever and sepsis.<sup>[50]</sup> On the same lines, the retrograde access during the ECIRS could facilitate intrarenal decompression through the ureteral access sheath (UAS).<sup>[51]</sup> Although the use of UAS is not mandatory, the majority of the studies included in our review, 24 of the 33 studies, used UAS in all the patients. When placed, the size of the UAS ranged from small size 9.5–11.5F to the larger ones (i.e., 14–16F), according to the surgeon's preference and the patient's characteristics. We believe the UAS is of great value while performing ECIRS, as it can help in maintaining a low intrarenal pressure, provides the possibility to retrieve fragments safely, and also reduces risk of injury to the ureter. Thus, the authors suggest that the UAS might be useful, especially in cases where a miniaturized percutaneous access is used or when a prolonged active role of the retrograde approach is expected.<sup>[47]</sup>

As the secondary outcome of this study, we wanted to evaluate the most common position the patient is placed into for ECIRS. GSMV is the most common position reported in the included studies, followed by the PSL position and lastly by the lateral decubitus position. The GSMV position allows an easy insertion of the ureteroscope and avoids anesthetic complications (i.e., respiratory and pharmacokinetic problems typical of obese patients), and thus is the most commonly used position.<sup>[43]</sup> The PSL position has certain advantages such as it allows for easy renal access, easy image driven puncture and allows for multiple percutaneous accesses.<sup>[52]</sup> A downside of the PSL position is that the percutaneous tract is in an anti-gravity position, and therefore the intra-renal pressure is higher resulting in higher fluid absorption.<sup>[34]</sup> Six studies compared the feasibility, efficacy, and safety of the different positions for ECIRS and found excellent and comparable outcomes, irrespective of the patient's position. The only difference between the two most common positions was the surgical time, which appeared to be longer in the GSMV position



probably due to the time taken in performing the renal puncture.<sup>[32,33]</sup> The choice of patient's position during the surgery should rely on the surgeons preference, if not driven by anesthetic needs or anatomical abnormalities. Besides, there is a difference in the tilt of renal axis according to the various positions chosen for surgery, and the lower pole of the kidney may be displaced medially and ventrally in the oblique position because of the gravity.<sup>[33]</sup> As reported by Hamamoto *et al.*, the PSL might be the position of choice when targeting the lower renal calyces, while the GMSV position makes the access to the middle calyces easier.<sup>[32]</sup>

A lack of standardization in the surgical procedure of ECIRS among the included studies is the main limitation of our review. Also, the variability in reporting SFR and in when and how it was assessed, made it difficult to have a clear image of the efficacy of ECIRS. Moreover, the heterogeneity in reporting of the complications affected the total complication rate reported in each study. We believe, that with the current rising interest in the ECIRS, a consensus would soon be reached and the technique would be standardized. ECIRS is undoubtedly an efficient procedure with a good safety profile and excellent intra- and postoperative outcomes, in particular for the management of complex and/or multiple large stones. With the reduced costs of laser-related endourological procedures and an increase in the role of minimally invasive PCNLs, ECIRS is bound to play a larger role in the future.<sup>[53,54]</sup> With a myriad of options available, the endourological procedure offered to a patient needs to be individualised with the use of patient-reported outcome measures (PROMs) in the coming future.<sup>[55,56]</sup>

The main downside of ECIRS, when compared to the standard PCNL, is the need of two experienced surgeons involved in the same procedure. The increase in the cost of this double procedure could be offset by the advantages in terms of shorter operative times, hospital stay, and complication rates. It also would mean a superior stone clearance in a single stage, possibly avoiding ancillary or second-look procedures.

## CONCLUSION

ECIRS is a feasible and safe procedure that allows for an excellent clearance of complex and large stones and should be considered as the first treatment in patients with large staghorn calculi or multiple stones trapped in different renal calyces. ECIRS has a high single-stage SFR and low rate of major complications.

## REFERENCES

- Geraghty RM, Davis NF, Tzelves L, Lombardo R, Yuan C, Thomas K, *et al.* Best practice in interventional management of urolithiasis: An update from the European Association of Urology guidelines panel for urolithiasis 2022. *Eur Urol Focus* 2023;9:199-208.
- Scoffone CM, Cracco CM, Cossu M, Grande S, Poggio M, Scarpa RM. Endoscopic combined intrarenal surgery in Galdakao-modified supine Valdivia position: A new standard for percutaneous nephrolithotomy? *Eur Urol* 2008;54:1393-403.
- Scoffone C, Hoznek A, Cracco C. *Supine Percutaneous Nephrolithotomy and ECIRS: The New Way of Interpreting PNL*. Paris, France: Springer Science & Business Media; 2014. p. 1-312.
- Gauhar V, Castellani D, Cracco CM, Scoffone CM, Lim EJ, Rubilotta E, *et al.* Is endoscopic combined intrarenal surgery ready for primetime in endourology? Outcomes from a systematic review and meta-analysis. *Cent European J Urol* 2022;75:171-81.
- Abdullatif VA, Sur RL, Abdullatif ZA, Szabo SR, Abbott JE. The safety and efficacy of endoscopic combined intrarenal surgery (ECIRS) versus percutaneous nephrolithotomy (PCNL): A systematic review and meta-analysis. *Adv Urol* 2022;2022:1716554.
- Jung HD, Kim JC, Ahn HK, Kwon JH, Han K, Han WK, *et al.* Real-time simultaneous endoscopic combined intrarenal surgery with intermediate-supine position: Washout mechanism and transport technique. *Investig Clin Urol* 2018;59:348-54.
- Scoffone CM, Cracco CM. Invited review: The tale of ECIRS (endoscopic combined intrarenal surgery) in the Galdakao-modified supine Valdivia position. *Urolithiasis* 2018;46:115-23.
- Hiller SC, Ghani KR. Frontiers of stone management. *Curr Opin Urol* 2020;30:17-23.
- Lim EJ, Osther PJ, Valdivia Uría JG, Ibarluzea JG, Cracco CM, Scoffone CM, *et al.* Personalized stone approach: Can endoscopic combined intrarenal surgery pave the way to tailored management of urolithiasis? *Minerva Urol Nephrol* 2021;73:428-30.
- Liu YH, Jhou HJ, Chou MH, Wu ST, Cha TL, Yu DS, *et al.* Endoscopic combined intrarenal surgery versus percutaneous nephrolithotomy for complex renal stones: A systematic review and meta-analysis. *J Pers Med* 2022;12:532.
- Moher D, Liberati A, Tetzlaff J, Altman DG, PRISMA Group. Preferred reporting items for systematic reviews and meta-analyses: The PRISMA statement. *BMJ* 2009;339:b2535.
- Abouelgreed TA, Abdelaal MA, Amin MM, Elatreisy A, Shalkamy O, Abdrabuh AM, *et al.* Endoscopic combined intrarenal surgery in the prone split-leg position versus Galdakao-modified supine Valdivia position for the management of partial staghorn calculi. *BMC Urol* 2022;22:163.
- Wen J, Xu G, Du C, Wang B. Minimally invasive percutaneous nephrolithotomy versus endoscopic combined intrarenal surgery with flexible ureteroscope for partial staghorn calculi: A randomised controlled trial. *Int J Surg* 2016;28:22-7.
- Gökçe Mİ, Gülpınar O, Ibiş A, Karaburun M, Kubilay E, Süer E. Retrograde versus antegrade flexible nephroscopy for detection of residual fragments following PNL: A prospective study with computerized tomography control. *Int Braz J Urol* 2019;45:581-7.
- Sugino T, Hamamoto S, Unno R, Taguchi K, Okada A, Yasui T. Effectiveness of ureteroscope-assisted renal puncture for endoscopic combined intrarenal surgery. *Int J Urol* 2019;26:424-5.
- Unno R, Taguchi K, Hamamoto S, Hattori T, Kawase K, Okada T, *et al.* A novel approach in creating nephrostomy using a double-lumen access sheath during endoscopic combined intrarenal surgery. *Transl Androl Urol* 2021;10:4181-91.
- Zhao F, Li J, Tang L, Li C. A comparative study of endoscopic combined intrarenal surgery (ECIRS) in the Galdakao-modified supine Valdivia (GMSV) position and minimally invasive percutaneous nephrolithotomy for complex nephrolithiasis: A retrospective single-center study. *Urolithiasis* 2021;49:161-6.
- Mishra DK, Agrawal MS, Shah M, Naganathan K, Hameed Z, Gauhar V. Ambulatory minimally invasive endoscopic combined intrarenal surgery in management of large impacted proximal ureteral calculi: A feasibility study at a tertiary referral center. *J Endourol* 2023;37:251-6.

19. Kallidonis P, Tsaturyan A, Faria-Costa G, Ballesta Martinez B, Peteinaris A, Adamou C, *et al.* Nonpapillary prone endoscopic combined intrarenal surgery: Effectiveness, safety and tips, and tricks. *World J Urol* 2022;40:3067-74.
20. Hamamoto S, Unno R, Taguchi K, Ando R, Hamakawa T, Naiki T, *et al.* A new navigation system of renal puncture for endoscopic combined intrarenal surgery: Real-time virtual sonography-guided renal access. *Urology* 2017;109:44-50.
21. Hamamoto S, Yasui T, Okada A, Taguchi K, Kawai N, Ando R, *et al.* Endoscopic combined intrarenal surgery for large calculi: Simultaneous use of flexible ureteroscopy and mini-percutaneous nephrolithotomy overcomes the disadvantageous of percutaneous nephrolithotomy monotherapy. *J Endourol* 2014;28:28-33.
22. Schulster M, Small AC, Silva MV, Abbott JE, Davalos JG. Endoscopic combined intrarenal surgery can accurately predict high stone clearance rates on postoperative CT. *Urology* 2019;133:46-9.
23. Chen ZH, Lee KH, Tseng WH, Su CC, Hsieh KL, Lim CY, *et al.* Comparison of mini endoscopic combined intrarenal surgery and multitract minimally invasive percutaneous nephrolithotomy specifically for kidney staghorn stones: A single-centre experience. *BMC Urol* 2022;22:93.
24. Gao H, Zhang H, Wang Y, Li K, Du W, Wang X, *et al.* Treatment of complex renal calculi by digital flexible ureterorenoscopy combined with single-tract super-mini percutaneous nephrolithotomy in prone position: A retrospective cohort study. *Med Sci Monit* 2019;25:5878-85.
25. Goktug HN, Ozturk U, Cimen S, Kaymak S, Dogan AE, Imamoglu MA. Comparison of the conventional PNL with ecirs in the treatment of complete staghorn kidney stones. *J Coll Physicians Surg Pak* 2023;33:346-51.
26. Kuroda S, Ito H, Sakamaki K, Tabei T, Kawahara T, Terao H, *et al.* Development and internal validation of a classification system for predicting success rates after endoscopic combined intrarenal surgery in the modified Valdivia position for large renal stones. *Urology* 2015;86:697-702.
27. Jung HD, Moon YJ, Almujalhem AJ, Alqahtani AA, Alkhureeb MA, Lee JY. The first 100 cases of endoscopic combined intrarenal surgery in Korea: Matched cohort analyses versus shock-wave lithotripsy. *Yonsei Med J* 2022;63:440-5.
28. Leng S, Xie D, Zhong Y, Huang M. Combined single-tract of minimally percutaneous nephrolithotomy and flexible ureteroscopy for staghorn calculi in oblique supine lithotomy position. *Surg Innov* 2018;25:22-7.
29. Liu C, Zheng B, Wen J, Mao H, Jiang T, Chen Q, *et al.* One-stage efficacy of single tract minimally invasive ECIRS in the improved prone frog split-leg position for staghorn stones. *BMC Urol* 2022;22:54.
30. Taguchi K, Yamashita S, Hamamoto S, Deguchi R, Kawase K, Okada T, *et al.* Ureteroscopy-assisted puncture for ultrasonography-guided renal access significantly improves overall treatment outcomes in endoscopic combined intrarenal surgery. *Int J Urol* 2021;28:913-9.
31. Usui K, Komeya M, Taguri M, Kataoka K, Asai T, Ogawa T, *et al.* Minimally invasive versus standard endoscopic combined intrarenal surgery for renal stones: A retrospective pilot study analysis. *Int Urol Nephrol* 2020;52:1219-25.
32. Hamamoto S, Okada S, Inoue T, Taguchi K, Kawase K, Okada T, *et al.* Comparison of the safety and efficacy between the prone split-leg and Galdakao-modified supine Valdivia positions during endoscopic combined intrarenal surgery: A multi-institutional analysis. *Int J Urol* 2021;28:1129-35.
33. Otsuka I, Terada N, Iwamoto H, Kobayashi T, Kamoto T. Comparison of safety and efficacy in endoscopic combined intrarenal surgery performed in the lateral decubitus and Galdakao-modified supine Valdivia positions. *Urology* 2023;172:49-54.
34. Hamamoto S, Yasui T, Okada A, Takeuchi M, Taguchi K, Shibamoto Y, *et al.* Developments in the technique of endoscopic combined intrarenal surgery in the prone split-leg position. *Urology* 2014;84:565-70.
35. Hamamoto S, Yasui T, Okada A, Koiwa S, Taguchi K, Itoh Y, *et al.* Efficacy of endoscopic combined intrarenal surgery in the prone split-leg position for staghorn calculi. *J Endourol* 2015;29:19-24.
36. Inoue T, Kinoshita H, Okada S, Hamamoto S, Taguchi M, Murota T, *et al.* Wideband Doppler ultrasound-guided mini-endoscopic combined intrarenal surgery as an effective and safe procedure for management of large renal stones: A preliminary report. *Urology* 2016;95:60-6.
37. Manikandan R, Mittal JK, Dorairajan LN, Mishra AK, Sreerag KS, Verma A. Endoscopic combined intrarenal surgery for simultaneous renal and ureteral stones: A retrospective study. *J Endourol* 2016;30:1056-61.
38. Ping H, Zhang JH, Wang MS, Xing NZ. Endoscopic combined intrarenal surgery for the treatment of postpercutaneous nephrolithotomy residual stones. *Chin Med J (Engl)* 2016;129:2885-7.
39. Tabei T, Ito H, Usui K, Kuroda S, Kawahara T, Terao H, *et al.* Risk factors of systemic inflammation response syndrome after endoscopic combined intrarenal surgery in the modified Valdivia position. *Int J Urol* 2016;23:687-92.
40. Wang D, Sun H, Xie D, Liu Z, Yu D, Ding D. Application of a new position in endoscopic combined intrarenal surgery: Modified prone split-leg position. *BMC Urol* 2022;22:38.
41. Yamashita S, Kohjimoto Y, Iba A, Kikkawa K, Hara I. Stone size is a predictor for residual stone and multiple procedures of endoscopic combined intrarenal surgery. *Scand J Urol* 2017;51:159-64.
42. Tominaga K, Inoue T, Yamamichi F, Fujita M, Fujisawa M. Impact of vacuum-assisted mini-endoscopic combined intrarenal surgery for staghorn stones: Analysis of perioperative factors of postoperative fever and stone-free status. *J Endourol* 2023;37:400-6.
43. Ibarluzea G, Scoffone C, Cracco C, Poggio M, Porpiglia F, Terrone C, *et al.* Supine Valdivia and modified lithotomy position for simultaneous anterograde and retrograde endourological access. *BJU Int* 2007;100:233-6.
44. Skolarikos A, Neisius A, Petřík A, Somani B, Thomas K, Gambaro G. EAU Guidelines on Urolithiasis. EAU Guidelines. Presented at the EAU Annual Congress Amsterdam; 2022. Available from: <https://uroweb.org/guidelines/urolithiasis/chapter/introduction>. [Last accessed on 2023 Jun 12].
45. Cracco CM, Knoll T, Liatsikos EN, Osther PJ, Smith AD, Scarpa RM, *et al.* Rigid-only versus combined rigid and flexible percutaneous nephrolithotomy: A systematic review. *Minerva Urol Nefrol* 2017;69:330-41.
46. de la Rosette J, Assimos D, Desai M, Gutierrez J, Lingeman J, Scarpa R, *et al.* The clinical research office of the endourological society percutaneous nephrolithotomy global study: Indications, complications, and outcomes in 5803 patients. *J Endourol* 2011;25:11-7.
47. Cracco CM, Scoffone CM. Endoscopic combined intrarenal surgery (ECIRS) – Tips and tricks to improve outcomes: A systematic review. *Turk J Urol* 2020;46:S46-57.
48. Ramón de Fata F, Pérez D, Resel-Folkersma L, Galán JA, Serrano A, Servera A, *et al.* Analysis of the factors affecting blood loss in percutaneous nephrolithotomy: A registry of the Spanish Association of Urology in the supine position. *Actas Urol Esp* 2013;37:527-32.
49. Arora AM, Pawar PW, Tamhankar AS, Sawant AS, Mundhe ST, Patil SR. Predictors for severe hemorrhage requiring angioembolization post percutaneous nephrolithotomy: A single-center experience over 3 years. *Urol Ann* 2019;11:180-6.
50. Wilhelm K, Müller PF, Schulze-Ardey J, Späth J, Suarez-Ibarrola R, Miernik A, *et al.* Characterization of flow-caused intrarenal pressure conditions during percutaneous nephrolithotomy *in vitro*. *J Endourol* 2019;33:235-41.
51. Traxer O, Wendt-Nordahl G, Sodha H, Rassweiler J, Meretyk S, Tefekli A, *et al.* Differences in renal stone treatment and outcomes for patients treated either with or without the support of a ureteral access sheath: The clinical research office of the endourological society ureteroscopy global study. *World J Urol* 2015;33:2137-44.

52. Duty B, Waingankar N, Okhunov Z, Ben Levi E, Smith A, Okeke Z. Anatomical variation between the prone, supine, and supine oblique positions on computed tomography: Implications for percutaneous nephrolithotomy access. *Urology* 2012;79:67-71.
53. Somani BK, Robertson A, Kata SG. Decreasing the cost of flexible ureterorenoscopic procedures. *Urology* 2011;78:528-30.
54. Jones P, Elmussareh M, Aboumarzouk OM, Mucksavage P, Somani BK. Role of minimally invasive (micro and ultra-mini) PCNL for adult urinary stone disease in the modern era: Evidence from a systematic review. *Curr Urol Rep* 2018;19:27.
55. Juliebø-Jones P, Keller EX, Haugland JN, Æsøy MS, Beisland C, Somani BK, *et al.* Advances in ureteroscopy: New technologies and current innovations in the era of tailored endourological stone treatment (TEST). *J Clin Urol* 2023;16:190-8.
56. Mehmi A, Jones P, Somani BK. Current status and role of patient-reported outcome measures (PROMs) in endourology. *Urology* 2021;148:26-31.

**How to cite this article:** Nedbal C, Jahrreiss V, Cerrato C, Castellani D, Kamal WK, Hameed Z, *et al.* Current role of endoscopic combined intrarenal surgery in the management of renal stones: A scoping review. *Indian J Urol* 2023;39:274-84.