

Descemet's stripping automated endothelial keratoplasty for congenital hereditary endothelial dystrophy

Hamed M Anwar
AM El Danasoury
AN Hashem

Corneal and Refractive Surgery Unit,
Magrabi Eye Hospital, Jeddah, Saudi
Arabia

Abstract: Congenital hereditary endothelial dystrophy (CHED), presents in infancy or early childhood with bilateral clouding of corneas. This condition has previously been managed surgically with penetrating keratoplasty (PKP). Performing PKP in pediatric patients has its own set of difficulties. More recently, there has been growing interest in treating this condition with Descemet's stripping automated endothelial keratoplasty (DSAEK). The purpose of this study is to report our experience of successfully performing DSAEK in a child with CHED.

Keywords: congenital hereditary endothelial dystrophy, CHED, DSAEK, Descemet's stripping automated endothelial keratoplasty

Introduction

Congenital hereditary endothelial dystrophy (CHED) is a corneal dystrophy characterized by bilateral diffuse clouding of the corneas, causing impaired vision. Depending on the mode of inheritance, it manifests either in infancy or young childhood with a cloudy cornea, light sensitivity, tearing, and sometimes nystagmus.¹

CHED is primarily a disease of the corneal endothelium, but it has traditionally been treated with penetrating keratoplasty.² Targeted corneal endothelium transplantation techniques, such as Descemet's stripping automated endothelial keratoplasty (DSAEK), have become a standard of care for the treatment of corneal endothelial dysfunction in adults,³ but few reports exist describing its use in the pediatric age group.⁴⁻⁷

In this report, the authors describe a case of DSAEK being performed in a child with CHED.

Case report

A 10-year-old boy presented to the Corneal and Refractive Surgery Unit as a referral from a local ophthalmologist due to poor vision and hazy corneas since infancy. There was a positive family history of the condition. The father and both of the child's siblings were affected by the same condition. A diagnosis of CHED was made on the basis of clinical findings and the positive family history.

Visual acuities were counting fingers at 1 m in both eyes. Examination showed uniplanar, jerky, horizontal nystagmus. The corneas of both eyes were diffusely edematous (Figure 1), with central corneal thicknesses of 921 μm and 891 μm in the right and left eyes respectively, measured with ultrasonic pachymetry. Intraocular pressures were 15 mmHg in the right eye and 18 mmHg in the left eye. The horizontal corneal diameters were normal in both eyes. The edematous corneas obscured details

Correspondence: Hamed M Anwar
Corneal and Refractive Surgery Unit,
Magrabi Eye Hospital, PO Box 7344,
Jeddah, Saudi Arabia
Fax +966 2636 6164
Email hamidanwar@hotmail.com

of the fundus on dilated examination. Endothelial cell counts and specular microscopy were not possible due to the corneal edema. Axial lengths of the eyes were slightly shorter than normal, being 22.53 mm and 22.49 mm, as confirmed on A-scan ultrasound biometry.

The patient was scheduled for DSAEK on the right eye, to be performed under general anesthesia. To assist in graft sizing, the eye was measured with a pair of calipers at the beginning of the procedure and was found to be 10.5 mm. The endothelial graft was prepared using a Moria CB microkeratome head (350 μm blade depth) and a Moria ALTK artificial (AC) anterior chamber (Moria Surgical, Doylestown, PA). The thickness of the donor cornea was 673 μm , as measured by ultrasonic pachymetry. After the microkeratome pass, the posterior lamella tissue was punched from the endothelial side using a disposable trephine, 8 mm in diameter. The thickness of the posterior lamella was measured to be 138 μm . The donor tissue was then covered with Optisol solution (Chiron Ophthalmics, Irvine, CA) until use.

With the surgeon sitting temporally, the central corneal epithelium was debrided to improve visualization of the AC (Figure 2A). A 1-mm side port was created at the 6 o'clock position, through which an AC maintainer was inserted and the irrigating fluid turned on. A 2.75-mm temporal clear corneal incision was created, through which Descemet's membrane (DM) scouring was performed at the required diameter using a reverse Sinsky hook (Figure 2B). The AC maintainer was then turned off, and Trypan blue dye was injected into the AC. The AC maintainer was then turned back on to wash the dye out of the AC. A 90° Descemet's stripper was then used to strip DM from the overlying corneal stroma (Figure 2C). Stripping of DM was difficult and detachment did not occur even after numerous attempts.

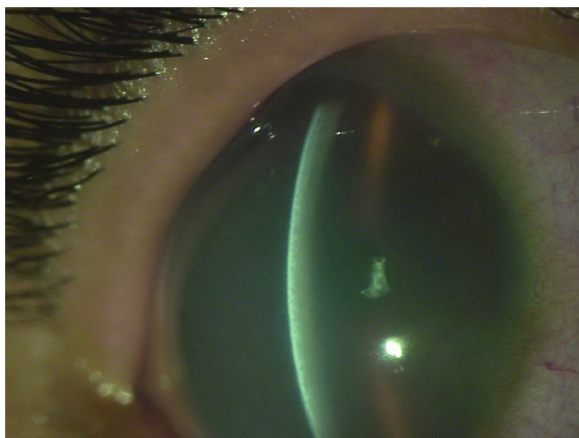


Figure 1 Preoperative appearance of right eye of patient. Best corrected visual acuity counting fingers at 1 m.

DM was therefore left in place. A peripheral iridectomy was performed at the 11 o'clock position using a vitrector (Figure 2D). A 4.5-mm sized nasal clear corneal incision was created to prepare for insertion of the tip of the Busin glide (Moria Surgical).^{8,9}

The donor disk was transferred to the Busin glide with the endothelial surface oriented upwards. The central area of the endothelium was coated with viscoelastic, taking care not to let viscoelastic reach the stromal side of the graft.

With the surgeon sitting superiorly, the loaded glide was inverted and positioned at the entrance of the nasal clear corneal incision. Busin forceps were then passed through the temporal incision across the AC to grasp the donor disk at the glide opening. The donor disk was pulled into the AC (Figure 2E) and allowed to unfold spontaneously under continuous irrigation from the AC maintainer (Figure 2F). An air bubble was injected under the graft and the AC maintainer was turned off (Figure 2G). The wound was then secured with 10/0 nylon monofilament sutures.

The epithelial surface was then gently massaged using a blunt, bent, irrigating cannula centered on the disk (Figure 2H). After centration was achieved, a large air bubble was injected into the AC to keep the disc adherent to the overlying stroma for around 15 minutes (Figure 3). At the conclusion of the procedure, some air was exchanged with balanced salt saline (BSS), reducing the bubble size to approximately 2/3rd of the AC volume.

Postoperatively, the patient was positioned in a face-up position for the first 3 to 4 days. Medication consisted of topical Moxifloxacin HCl 0.5% four times daily (Vigamox, Alcon, Fort Worth, TX) and 1% Prednisolone acetate suspension (Pred Forte®, Allergan, Irvine, CA) administered hourly for the first week. Medications were tapered as appropriate through the postoperative period. Sutures were removed at the slit lamp after 2 months. No examination under anesthesia was required during the postoperative course.

Best spectacle corrected visual acuity (BSCVA) at 3 months was 20/400. At 1 year, the patient had BSCVA of 20/100 with a refraction of +4 – 0.5 \times 180, and was able to play soccer at school with this vision. Vision in the left eye remained at counting fingers. The corneal stroma, although it became clearer, did not become totally transparent, with moderate residual stromal haze being present even at 1 year while the central corneal thickness was 658 μm (Figure 4A – postoperative appearance at 2 weeks; Figure 4B – appearance at 1 month postoperatively; Figure 4C – postoperative appearance at 3 months; Figure 4D – postoperative appearance at 1 year).

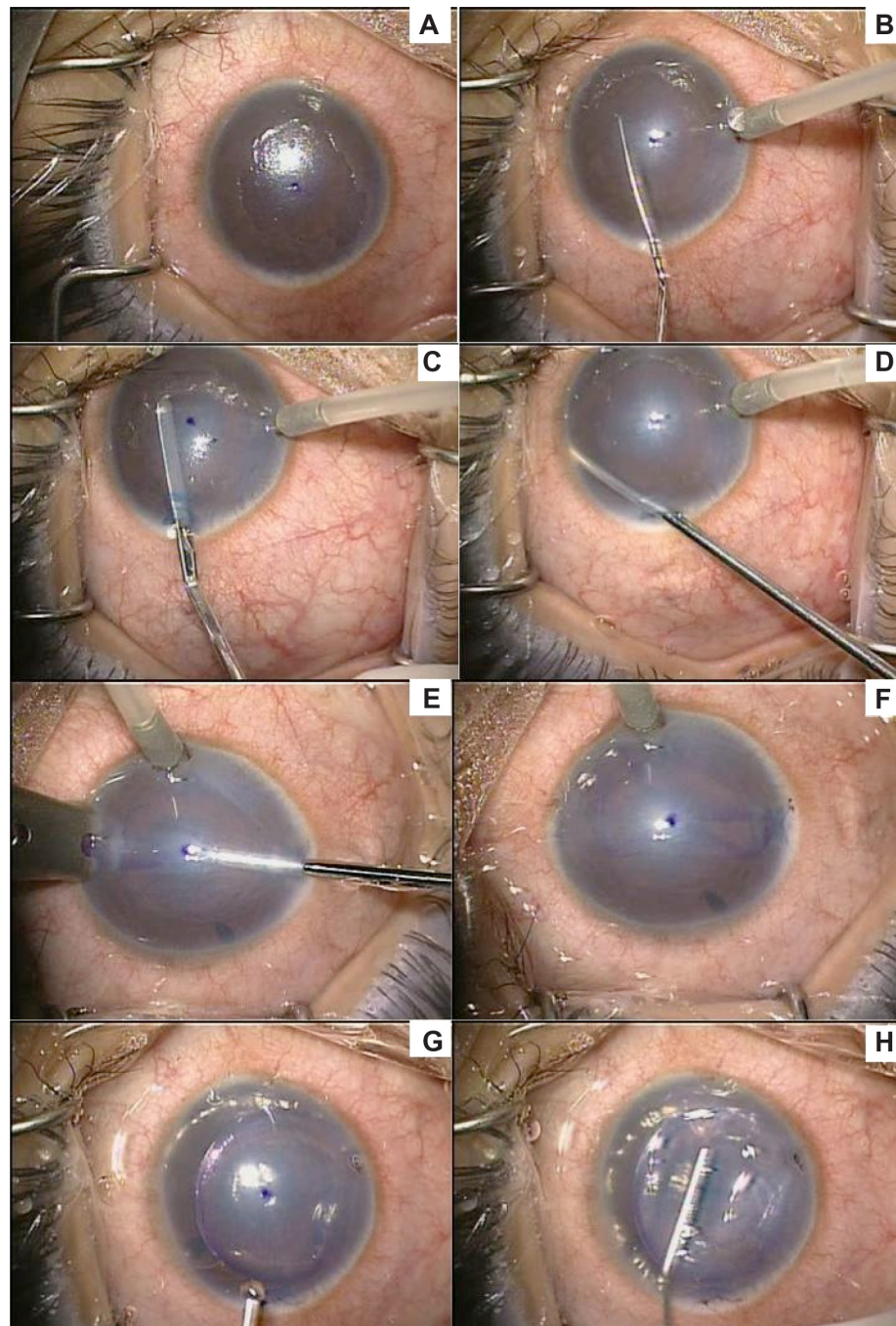


Figure 2 (A) intraoperative view of cornea after debridement of corneal epithelium; (B) scouring of Descemet's membrane using a reverse Sinskey hook; (C) stripping of Descemet's membrane from the overlying corneal stroma with a 90° Descemet's stripper; (D) performing a peripheral iridectomy with a vitrector; (E) pulling the endothelial graft into the anterior chamber; (F) unfolding of the graft in anterior chamber; (G) an air bubble is injected under the graft; (H) centration of the donor disc by massaging the epithelial surface of the cornea with an irrigating cannula.

Discussion

Corneal transplantation in children is a challenging task. Conventional penetrating keratoplasty has a higher risk of graft failure and poorer visual prognosis than that of adult keratoplasty. Children are harder to examine, their eyes have low scleral rigidity, and produce more of a fibrin reaction. During surgery, positive vitreous pressure

may be experienced. There is an increased risk of infection and rejection due to sutures loosening frequently, necessitating their early replacement or removal. PKP wounds are more prone to traumatic rupture in children than in adults.¹⁰

Targeted endothelial keratoplasty now forms an accepted standard of care for corneal endothelial dysfunction in adults.³ The benefits that endothelial transplantation procedures

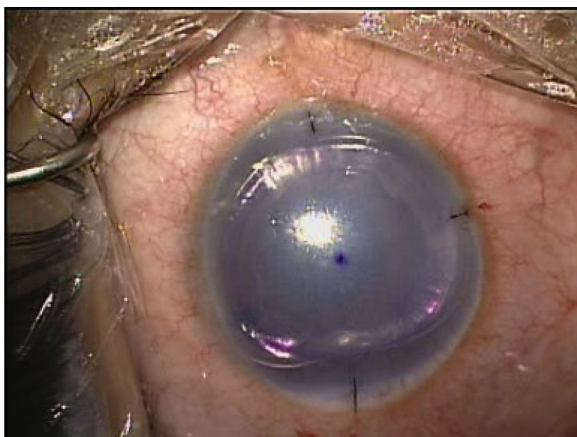


Figure 3 Injection of a large air bubble into the anterior chamber at the conclusion of the procedure.

such as DSAEK have over conventional PKP include faster visual rehabilitation, fewer or no sutures, and a structurally stronger globe. These benefits are especially desirable in the pediatric age group. To date, however, reports of DSAEK being performed in children are few in number, with varying degrees of success, with some being successful and others being converted to PKP.

While performing DSAEK in both cases, we found that the AC view was poor due to the corneal edema.

Debriding the corneal epithelium did little to improve visibility during the procedure. It was not possible to remove Descemet's membrane in this case. Movement inside the eye was made difficult by the shallow AC and phakic state of the eye (Figure 1). Other authors have also reported these findings. Pineda et al, attempted to perform DSAEK on an eye with CHED, but the procedure was converted to a PKP due to difficulty in detaching Descemet's membrane and poor clarity of the cornea.⁴ In contrast, the case the authors performed was successfully completed in spite of an inability to remove DM. Studies have shown, however, that retention of DM in the donor-recipient interface can predispose to graft failure in DSAEK.¹¹

As the photos show, the time taken for the corneal stroma to clear after surgery was prolonged (Figure 4A–D). The corneal stroma retained some anterior haze for up to 1 year after surgery (Figure 5A – appearance of corneal stroma at 3 months; Figure 5B – appearance of corneal stroma at 6 months; Figure 5C – appearance of corneal stroma at 1 year). This haze was mainly located in the AC stroma.

The final BCVA reached by this patient was 20/100. This suboptimal outcome may have been due to the persistent stromal haze or the coexistent amblyopia due to hyperopia. Had surgery been performed in a younger patient, there might have been less corneal haze and more potential for treating

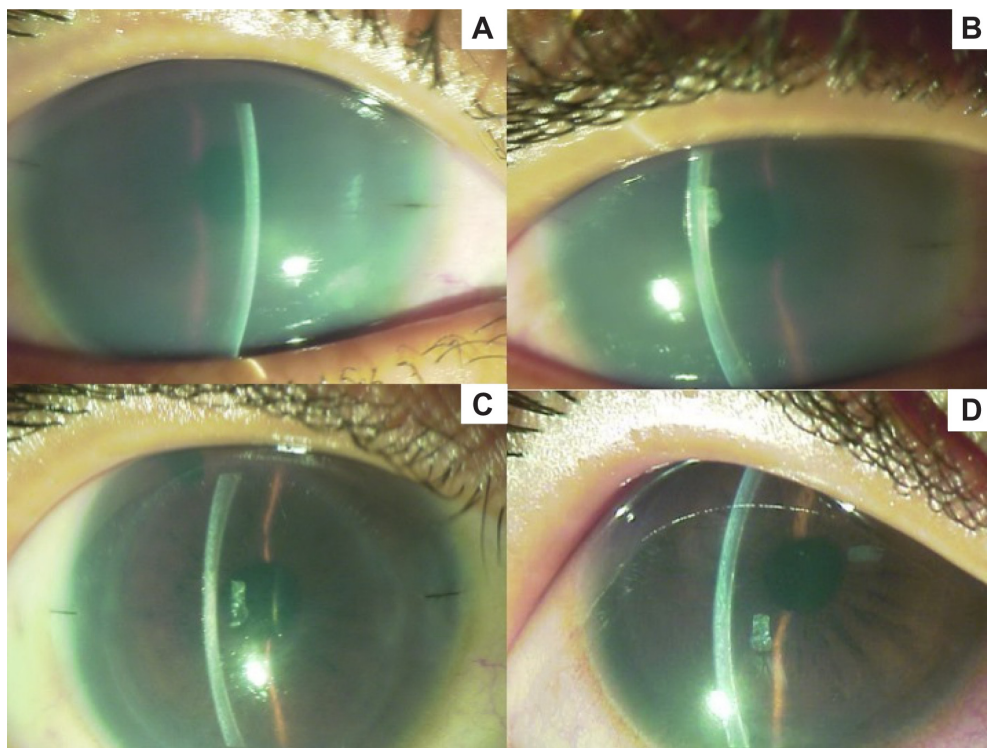


Figure 4 (A) postoperative appearance at 2 weeks; (B) postoperative appearance at 1 month; (C) postoperative appearance at 3 months; (D) postoperative appearance at 1 year.

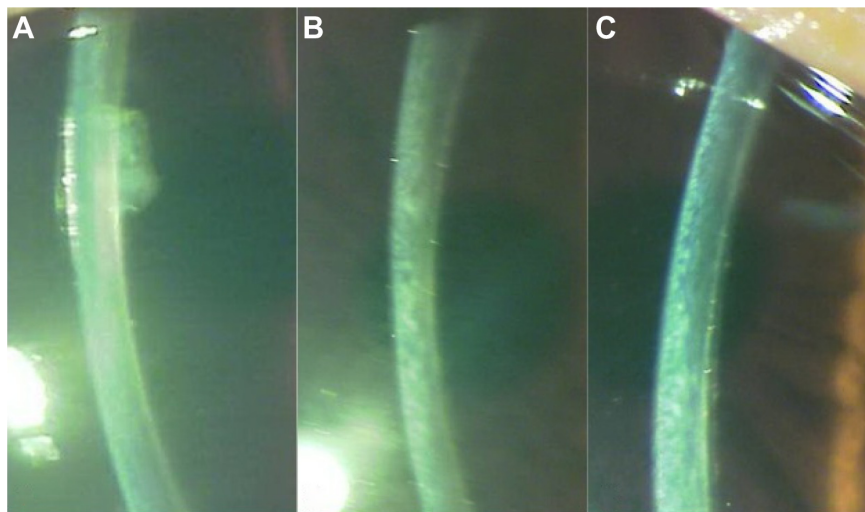


Figure 5 (A) cross sectional appearance of corneal stroma at 3 months; (B) cross sectional appearance of corneal stroma at 6 months; (C) cross sectional appearance of corneal stroma at 1 year.

the amblyopia. Other recent reports describe DSAEK being performed for CHED in babies as young as 6 months¹² and neonates.¹³ These cases could potentially reach better levels of vision as there is sufficient time to treat any associated amblyopia.

No examinations under anesthesia were required in this case, as the child was cooperative enough to have his sutures removed at the slit lamp. This is in contrast to pediatric PKP, where multiple hospital admissions are usually needed during the postoperative course. Moreover, as the final refraction showed in this child, the procedure was refractively neutral, due to the absence of sutures.

In conclusion, DSAEK can be used successfully in the treatment of CHED in children, as an alternative to PKP. DSAEK allows for a more rapid visual rehabilitation of patients and fewer subsequent postoperative hospital admissions for treatment. However, proper timing of the surgery is important to attain a good outcome.

Disclosure

The authors report no conflicts of interest in this work.

References

1. Waring GO III, Rodrigues MM, Laibson PR. Corneal dystrophies. II. Endothelial dystrophies. *Surv Ophthalmol.* 1978;23(3):147–168.

2. Graham MA, Azar NF, Dana MR. Visual rehabilitation in children with congenital hereditary endothelial dystrophy. *Int Ophthalmol Clin.* 2001;41(4):9–18.
3. Price MO, Price FW. Descemet's stripping endothelial keratoplasty. *Curr Opin Ophthalmol.* 2007;18(4):290–294.
4. Pineda R II, Jain V, Shome D, Hunter DC, Natarajan S. Descemet's stripping endothelial keratoplasty: is it an option for congenital hereditary endothelial dystrophy? *Int Ophthalmol.* 2010;30(3):307–310.
5. Jeng BH, Marcotty A, Traboulsi EI. Descemet stripping automated endothelial keratoplasty in a 2-year-old child. *JAAPOS.* 2008;12(3):317–318.
6. Fernandez MM, Buckley EG, Afshari NA. Descemet stripping automated endothelial keratoplasty in a child. *JAAPOS.* 2008;12(3):314–316.
7. Mittal V, Mittal R, Sangwan VS. Successful descemet stripping endothelial keratoplasty in congenital hereditary endothelial dystrophy. *Cornea.* 2011;30(3):354–356.
8. Busin M, Bhatt PR, Scorgia V. A modified technique for descemet membrane stripping automated endothelial keratoplasty to minimize endothelial cell loss. *Arch Ophthalmol.* 2008;126(8):1133–1137.
9. Jhanji V, Greenrod E, Sharma N, Vajpayee R. Modifications in the surgical technique of Descemet stripping automated endothelial keratoplasty. *Br J Ophthalmol.* 2008;92(10):1311, 1368.
10. Vanathi M, Panda A, Vengayil S, Chaudhuri Z, Dada T. Pediatric keratoplasty. *Surv Ophthalmol.* 2009;54(2):245–271.
11. Nikolic L, Jovanovic V, Lackovic V, Todorovic V. Endothelial keratoplasty without Descemet's membrane stripping: histologic and ultrastructural findings. *Ophthalmic Res.* 2010;43(1):56–60.
12. Busin M, Beltz J, Scorgia V. Descemet-stripping automated endothelial keratoplasty for congenital hereditary endothelial dystrophy. *Arch Ophthalmol.* 2011;129(9):1140–1146.
13. Bellucci R, Chierago C, Bellucci C. Endothelial keratoplasty in a newborn baby with CHED. *Cornea.* 2011;30(12):1488–1490.

Clinical Ophthalmology

Publish your work in this journal

Clinical Ophthalmology is an international, peer-reviewed journal covering all subspecialties within ophthalmology. Key topics include: Optometry; Visual science; Pharmacology and drug therapy in eye diseases; Basic Sciences; Primary and Secondary eye care; Patient Safety and Quality of Care Improvements. This journal is indexed on

Submit your manuscript here: <http://www.dovepress.com/clinical-ophthalmology-journal>

Dovepress

PubMed Central and CAS, and is the official journal of The Society of Clinical Ophthalmology (SCO). The manuscript management system is completely online and includes a very quick and fair peer-review system, which is all easy to use. Visit <http://www.dovepress.com/testimonials.php> to read real quotes from published authors.