



Contents lists available at ScienceDirect

International Journal of Surgery Case Reports

journal homepage: www.casereports.com

Co-existence of oral intra-muscular lipoma and lobular capillary hemangioma: A rare case report

Yogesh Kini, Anish Kamat*, Komal Navalkha, Swapna Nayan, Geetanjali Mandlik, Damini Gupta

OMFS, D.Y. Patil University School of Dentistry, Navi Mumbai, Sector 7, Highway Road, Dy Patil Vidyannagar, Nerul East, Navi Mumbai 400706, India

ARTICLE INFO

Article history:

Received 6 November 2020

Received in revised form 9 November 2020

Accepted 9 November 2020

Available online 12 November 2020

Keywords:

Oral intramuscular lipoma
Lobular capillary hemangioma
Pyogenic granuloma
Case report

ABSTRACT

INTRODUCTION: Intramuscular lipoma are benign mesenchymal soft tissue neoplasm of mature adipocytes that arises within the muscle. Oral intramuscular lipoma are more commonly seen on tongue. Lobular capillary hemangioma (LCH) on the other hand are common benign vascular neoplasms which are often confused with pyogenic granuloma.

PRESENTATION OF CASE: In this paper we present a rare case of co-existence of oral intramuscular lipoma with LCH. A 65 year old male complains of swelling on the left chin region from past 4–5 years. On complete intraoral examination another mass was noted on ventral surface of tongue. After performing USG and FNAC of the swelling in the chin region, an excisional biopsy was done and was sent for histopathological examination which showed thin connective tissue septa separating lobules of mature adipocytes.

Histopathological examination of tongue mass revealed a benign tumor composed of blood vessels comprising of small capillary sized vascular channels. After a follow-up of 1 year patient showed no signs of recurrence.

DISCUSSION: According to the literature recurrences are seen in case of intramuscular lipoma due to difficulty in total excision of the lesion. Immunohistochemistry plays a crucial role in distinguishing LCH from pyogenic granuloma. Intraoral LCH should be properly excised after understanding the vascularity of the lesion.

CONCLUSION: In literature, the co-existence of intraoral lipoma with other lesions have been encountered hence for a surgeon a complete examination of oral cavity plays a crucial role to rule out such co-existence.

© 2020 Published by Elsevier Ltd on behalf of IJS Publishing Group Ltd. This is an open access article under the CC BY-NC-ND license (<http://creativecommons.org/licenses/by-nc-nd/4.0/>).

1. Introduction

Lipoma is a benign mesenchymal soft tissue neoplasm of mature adipocytes. It accounts for 50% of all benign soft-tissue tumors [1]. 15%–20% of lipomas are found in head and neck region and only 1–4% cases are seen intraorally which accounts for 0.1%–5% of all the benign tumors of the mouth [2]. Intramuscular lipomas are rare, with an incidence of 1.8%. In literature lipomas are classified based on the location and histological pattern. According to location Lipoma's are either classified as subcutaneous lipoma i.e. (superficial to enclosing fascia in the subcutaneous tissue) and deep seated lipoma i.e. (deep to enclosing fascia).

Intramuscular lipomas are generally deep seated lipoma which originate inside the muscle [3]. Paget in 1853 was the 1st to describe a lipoma infiltrating the trapezius muscle. Later Greenberg et al. classified lipoma as intermuscular and intramuscular [4]. Intra-

muscular lipoma can be histologically divided as infiltrating type, well circumscribed type and mixed type (i.e. with both infiltrating margins and well circumscribed areas) [3–5].

Hemangioma was 1st described by Poncet and Dor as Botryomycose humane in 1897 [6]. Hemangiomas are histologically classified as capillary, cavernous and mixed hemangiomas. It is relatively rare in oral cavity. Incidence of intraoral capillary hemangioma varies from 0.5% to 1.0% of all intraoral neoplasms [7,8]. Histologically capillary hemangioma are very similar to pyogenic granuloma but can be differentiated only on immunohistochemistry. Many studies classify pyogenic granuloma histologically in two types' lobular capillary hemangioma (LCH) and non-lobular capillary hemangioma (non-LCH). This is a rare case of Coexistence of Intramuscular lipoma with LCH who was treated in a tertiary care hospital under the department of Oral and maxillofacial surgery.

2. Presentation of case

A 61 year old male visited the Department of Oral and maxillofacial surgery with a chief complaint of swelling on the left chin region from past 4–5 years. Swelling showed gradual increase in

* Corresponding author.

E-mail addresses: dr.swapnanayan1@gmail.com (S. Nayan), gitsmd20@yahoo.co.in (G. Mandlik), dams.9roxx@gmail.com (D. Gupta).

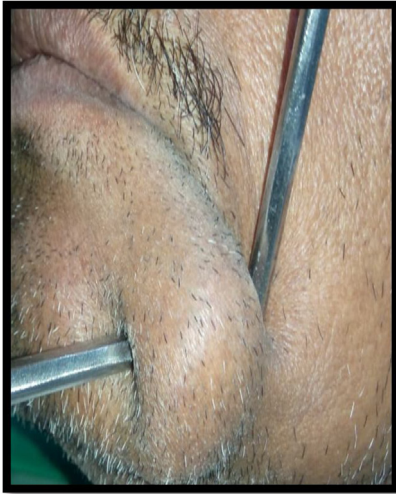

Fig. 1. Extra Oral Photograph Showing Swelling Near Commissure of the Mouth on the Left Side Measuring 5 cm × 3 cm.

size and wasn't associated with pain, paresthesia, or difficulty in mastication. No such mass was observed on any other part of the body. There was no history of any tooth extraction or trauma to that region. Patient had a history of tobacco chewing since 10–15 years, 3–4 times a day. There was no relevant genetic information. No relevant medical history, surgical history, family history, drug history or psychosocial history.

Extra-oral examination revealed a localized swelling on the left side of the face near commissure of the mouth measuring 5 cm × 3 cm, with smooth surface with no color change. On palpation it was soft in consistency, non fluctuant and non tender. No lymphadenopathy was noted (Fig. 1).

Intra-oral examination revealed a swelling on the lower left labial vestibule which was round in shape, yellowish in color and sessile, measuring 3 cm × 2 cm extending from the distal part of the canine till the mesial aspect of 1st molar, with smooth surface and distinct borders. On examination, an incidental finding of a mass on the ventral surface of the tongue was also noticed which was sessile, erythematous in nature measuring 1 cm × 0.5 cm with lobulated surface and irregular borders. On palpation, both the swellings were non-tender, soft in consistency with no blanching on pressure (Fig. 2).

An Orthopantomograph radiograph was done which showed no significant changes related to the area of interest. USG showed fairly well defined echogenic lesion in the intramuscular plane at the site of swelling measuring 2.2 × 0.8 cm in the region of left side of mandible. No evidence of calcification or vascularity were noted. Bony cortices and underlying muscle appeared normal. FNAC was done twice but yielded no material.

A provisional diagnosis of lipoma was made based on its clinical signs and symptoms. The patient was then advised an excisional biopsy under general anesthesia. Patient was kept NBM for 7 h before the surgery. The work has been reported in line with SCARE 2018 criteria [9]. Surgery was performed by the 1st author of this case report.

2.1. Surgical management & follow up

Patient was intubated via nasotracheal route, scrubbed and draped in aseptic manner. 2% lignocaine with 1:80,000 adrenaline was injected around the swelling. An Intraoral longitudinal incision of 4 cm was made over the mucosa covering the swelling in lower left vestibule, blunt dissection was done throughout and

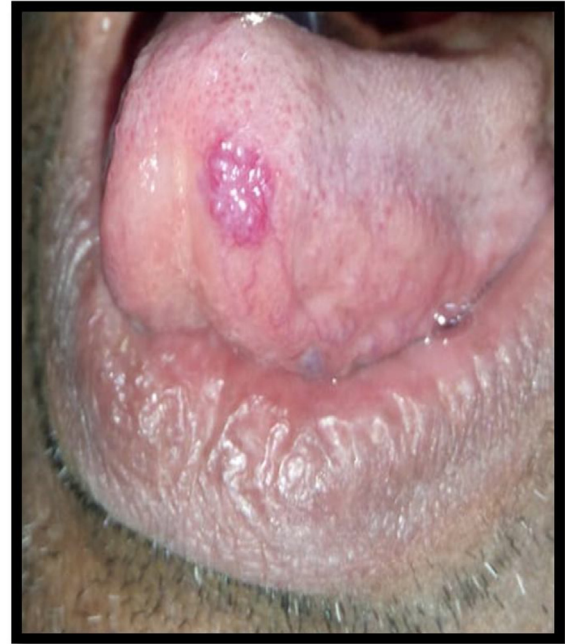


Fig. 2. Intra Oral Photograph Showing Swelling on the Ventral Surface of the Tongue Measuring 1 cm × 0.5 cm.

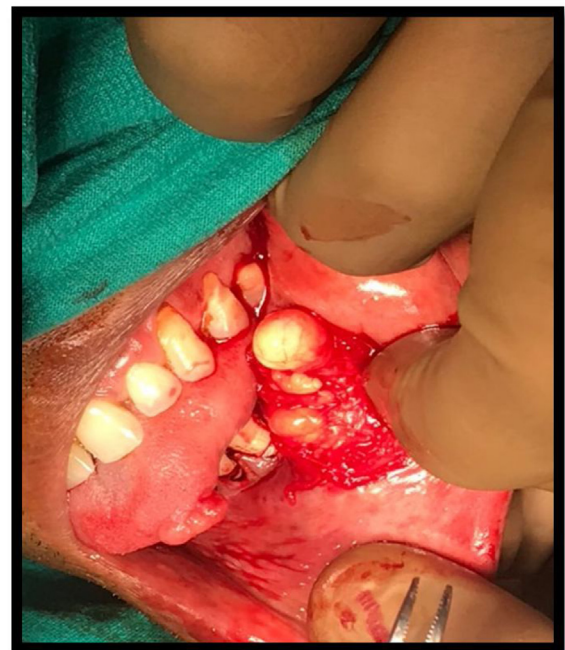

Fig. 3. Intraoperative photo of Excision of Lipoma.

complete lesion was excised. Tongue mass was excised, hemostasis was achieved and closure of mucosa was done using 3-0 Vicryl synthetic absorbable sutures on both the sites. Excised tissue was then stored in 10% formalin and was sent for histopathological examination (Fig. 3). Post-operative pressure dressing was given in the chin region for 3 days. Post-op antibiotic and analgesic were administered i.e. Inj Augmentin 1.2 gm Intravenous BD, Inj Dynapar (in 100cc ns) Intravenous TDS. After a follow-up of 1 year patient showed no signs of recurrence. Clinically the swelling on left chin region subsided after post op day 3. No signs of mental nerve paresthesia.

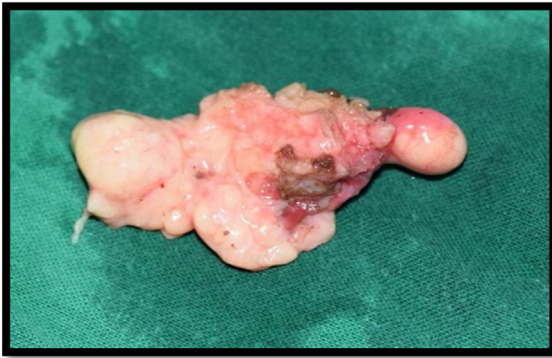

Fig. 4. Excised specimen of lipoma.

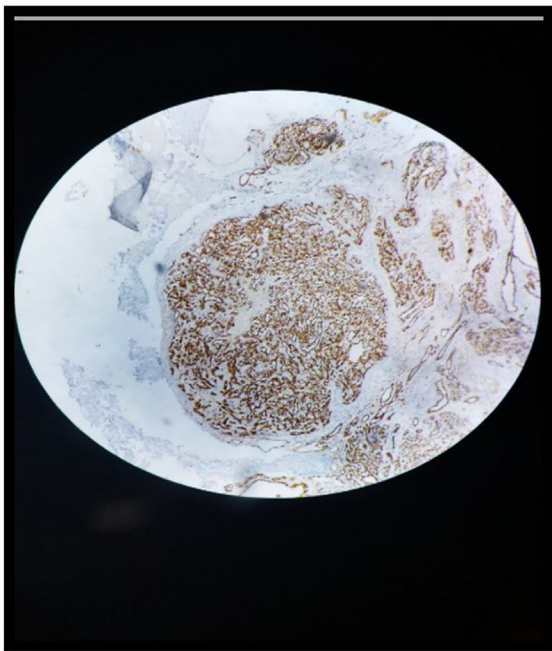


Fig. 5. Photomicrograph of immunohistochemical marker cd31 showing positive reaction.

3. Histopathological examination

Two samples labelled as (A) mass of lower labial vestibule measuring 2 cm × 1.5 cm × 1 cm (Fig. 4) and (B) proliferating lesion at the tip of the tongue measuring 1 cm × 0.5 cm × 0.5 cm were sent for histopathological investigation. Sample A showed features of lipoma that is thin connective tissue septa separating lobules of mature adipocytes while sample B showed a benign tumor composed of blood vessels comprising of small capillary sized vascular channels. There was no evidence of any atypia or malignancy. Immunohistochemistry showed positive reaction for CD31 marker on endothelial cell of blood vessels (Fig. 5).

4. Discussion

Lipoma is a benign soft tissue tumor of mesenchymal origin, most commonly affecting the trunk and proximal part of extremities. Gender predilection also differ depending on type of intra-oral lipoma. Microscopically they are categorized as classic lipoma, fibro-lipoma, angioliipoma, spindle cell lipoma, pleomorphic, myxoid, sialolipoma, and intramuscular lipomas. A higher

female predilection of fibro-lipoma was reported in a study by Juliasse et al. (2010) and Osterne et al. (2019) [10]. All cases of sialolipoma which were observed in a study by Juliasse et al. were female. Intramuscular or infiltrating lipoma is a rare type of lipoma, originating between skeletal muscle bundles and infiltrating through the intramuscular septa. Common site of origin in head and neck region include orbicularis muscle, temporalis muscle. Most common intraoral site was tongue [11,12]. Flechter et al. in his study found 27% of all the infiltrative lipoma in head and neck region whereas 12.5% of all well circumscribed type located in head region [13]. Clinically Intramuscular lipomas are generally slow growing well defined, round to ovoid in shape, sessile, yellow in color due to its thin overlying mucosa [14].

The etiology and pathogenesis of intra-oral lipoma remains unclear, but few theories are put forth which includes “Hypertrophy theory,” which states that obesity and inadvertent growth of adipose tissue may contribute to the formation of these oral lesions, Metaplasia theory suggests formation of lipoma because of aberrant differentiation of in situ mesenchymal cells into lipoblast since fatty tissue can be derived from mutable connective tissue cells almost anywhere in the body.

The differential diagnosis of intraoral lipoma are oral dermoid and epidermoid cysts, oral lymphoepithelial cyst, mucocele, benign mesenchymal neoplasm, benign salivary gland tumor, ranula, lymphoma etc.

CT, MRI and USG can be used to understand the location, extent and nature of swelling. Fine needle aspiration cytology (FNAC) can also be performed in order to confirm the diagnosis, however histopathological diagnosis is the gold standard method for the diagnosis of lipoma. Surgical excision is the treatment of lipoma. After excising it completely, chances of recurrence and malignant transformation are rare in lipomas. Studies suggest recurrence is commonly seen in Intramuscular lipoma (infiltrating lipomas) due to its difficulty in complete excision. Other non-surgical management include lipolysis by injecting agent’s phosphatidyl choline/sodium deoxycholate (PDC/DC) compounds in the subcutaneous fat [15]. Co-existence of Intraoral Lipoma and Lobular capillary hemangioma is extremely rare and only one case of coexistence of lipoma with multiple pyogenic granuloma was reported by Alphy Alphonsa Sebastian et al. in 2017 in a 52 year old female patient [16].

The incidence of intraoral capillary hemangiomas are extremely rare and it varies from 0.5%–1.0% of all intraoral neoplasms especially with female predilection (ratio of 3:1) in second and third decades of life [17,18].

Pyogenic granuloma is often confused with lobular capillary hemangioma. There are two histological types of pyogenic granuloma of the oral cavity: the LCH and non-LCH type. Differential diagnosis for this lesion are Traumatic fibroma, pyogenic granuloma, Epulis granulomatosa etc.

In an analysis of 244 cases of gingival lesions in South Indian population, Shamim et al. found that non-neoplastic lesions accounted for 75.5% of cases with lobulated capillary hemangioma being most frequent lesion, accounting for 52.71% cases [19].

CT Contrast, MRI, USG and Color Doppler can be done in order to confirm the diagnosis. In this case histopathological examination of the excised lesion followed by immunohistochemistry was performed in order to confirm the diagnosis.

Immunohistochemistry play a crucial role in distinguishing pure capillary hemangioma from pyogenic granuloma [20].

In pyogenic granuloma the immunohistochemistry shows absence of CD31, CD34, CD105 and Tie2 of perivascular ovoid mesenchyma. The perivascular mesenchymal spindle cells revealed immunopositivity to SMA [20]. Both pyogenic granuloma and Capillary hemangioma shows presence of CD31 CD34 CD105 on endothelial cell. Immunohistochemical analysis was done in our

case which reveal endothelial cells and ovoid cells are positive to CD34 marker [20].

The treatment of LCH is mainly surgical excision. Surgical excision should be done with utmost care because of high risk of increased intra and postoperative bleeding which should be managed properly if excision is planned. However in this case due to its small size excisional biopsy was planned and bleeding was controlled with absorbable sutures.

Other treatment modalities include steroid therapy, electro-surgery, ND: YAG laser, CO2 laser, cryosurgery, and sclerotherapy.

Patient's main pre-operative concern was the swelling and poor esthetics caused by it. However after excision the swelling was completely eliminated restoring the facial symmetry. Patient was satisfied as there were no extra oral scars since the whole procedure was done via intra-oral approach.

Hence complete examination of oral cavity plays a crucial role to rule out co-existence. Complete excision of intramuscular lipoma and clear histological diagnosis of LCH is important to reduce the chances of recurrence.

Declaration of Competing Interest

The authors report no declarations of interest.

Funding

No source of funding.

Ethical approval

Not applicable.

Consent

Written informed consent was obtained from the patient for publication of this case report and accompanying images. A copy of the written consent is available for review by the editor-in-chief of this journal on request.

Author contribution

1. Dr. Yogesh Kini: The conception and design of the study, analysis and interpretation of data, drafting the article, final approval of the version to be submitted.
2. Dr. Anish Kamat: The conception and design of the study, analysis and interpretation of data, drafting the article, final approval of the version to be submitted.
3. Dr. Komal Navalkha: The conception and design of the study, analysis and interpretation of data, drafting the article, final approval of the version to be submitted.
4. Dr. Swapna Nayan: Analysis and interpretation of data, drafting the article, final approval of the version to be submitted.
5. Dr. Geetanjali Mandlik: Analysis and interpretation of data, drafting the article, final approval of the version to be submitted.
6. Dr. Damini Gupta: Analysis and interpretation of data, drafting the article, final approval of the version to be submitted.

Open Access

This article is published Open Access at [sciencedirect.com](https://www.sciencedirect.com). It is distributed under the [IJSCR Supplemental terms and conditions](#), which permits unrestricted non commercial use, distribution, and reproduction in any medium, provided the original authors and source are credited.

Registration of research studies

Not applicable.

Guarantor

Dr. Yogesh Kini.
Dr. Anish Kamat.

Provenance and peer review

Provenance and peer review not commissioned, externally peer-reviewed.

References

- [1] Francois Loubignac, Christophe Bourtooul, Francoise Chapel, Myxoid liposarcoma: a rare soft-tissue tumor with a misleading benign appearance, *World J. Surg. Oncol.* 7 (2009) 42.
- [2] E.R. Fregnani, F.R. Pires, R. Falzoni, M.A. Lopes, P.A. Vargas, Lipomas of the oral cavity: clinical findings, histological classification and proliferative activity of 46 cases, *Int. J. Oral Maxillofac. Surg.* 32 (2003) 49–53.
- [3] Shane McTighe, Ivan Chernev, Intramuscular lipoma: a review of the literature, *Orthop. Rev. (Pavia)* 6 (October (4)) (2014) 5618.
- [4] S.D. Greenberg, C. Isensee, A. Gonzalez-Angulo, S.A. Wallace, Infiltrating lipomas of the thigh, *Am. J. Clin. Pathol.* 39 (1963) 66–72.
- [5] F. Wurlitzer, C. Bedrossian, A. Ayaia, et al., Problems of diagnosing and treating infiltrating lipomas, *Am. Surg.* 39 (1973) 240–243.
- [6] A. Poncet, L. Dor, Botryomycose humaine, *Rev. Chir. (Paris)* 18 (1897) 996.
- [7] D.C. Dahlin, K.K. Unni, *Bone Tumours: General Aspects and Data on 542 Cases*, vol. 14, Springfield Ill, 1986, pp. 3–17.
- [8] W.Y. Yih, G.S. Ma, R.G. Merrill, D.W. Sperry, Central hemangioma of the jaws, *J. Oral Maxillofac. Surg.* 47 (1989) 1154–1160.
- [9] R.A. Agha, M.R. Borrelli, R. Farwana, K. Koshy, A. Fowler, D.P. Orgill, For the SCARE Group, The SCARE 2018 statement: updating consensus Surgical Case Report (SCARE) guidelines, *Int. J. Surg.* 60 (2018) 132–136.
- [10] L.E. Juliasse, C.F. Nonaka, L.P. Pinto, A.R. de Freitas, M.C. Miguel, Lipomas of the oral cavity: clinical and histopathologic study of 41 cases in Brazilian population, *Eur. Arch. Otorhinolaryngol.* 267 (March (3)) (2010) 459–465, PubMed PMID: 19562364.
- [11] J. Dutton, J. Wright, Intramuscular lipoma of the superior oblique muscle, *Orbit* 25 (2006) 227–233.
- [12] G. Collela, A. Lanza, L. Rossiello, R. Rossiello, Infiltrating lipoma of the tongue, *Oral Oncol. Extra* 40 (2004) 33–35.
- [13] C.D. Fletcher, E. Martin-Bates, Intramuscular and intermuscular lipoma: neglected diagnoses, *Histopathology* 12 (1988) 275–287.
- [14] M.M. Chidzonga, L. Mahomva, C. Marimo, Gigantic tongue lipoma: a case report, *Med. Oral Patol. Oral Cir. Bucal* 11 (2006) 437–439.
- [15] Sonia Nanda, Treatment of lipoma by injection lipolysis, *J. Cutan. Aesthet. Surg.* 4 (May-August (2)) (2011) 135–137.
- [16] Alphy Alphonsa Sebastian, Hasan Subhi, Co-existence of multiple pyogenic granuloma and intra oral lipoma in a 52 year old female patient- a rare entity, *IDJSR* 5 (June (2)) (2017).
- [17] F.J. Schoen, B. Vessels, in: V. Kumar, A.K. Abbas, N. Fausto (Eds.), *Robbins and Cotran: Pathological Basis of Disease*, 7th edition, Saunders, Philadelphia, 2004, pp. 511–554.
- [18] B.W. Neville, D.D. Damm, C.M. Allen, J.E. Bouquet, *Oral & Maxillofacial Pathology*, 2nd edition, Saunders, Philadelphia, 2002, pp. 390–392.
- [19] P.A. Reichert, H.P. Philipsen, *Color Atlas of Oral Medicine Pathology*, Theme, Stuttgart, 2000, p. 163.
- [20] Naoko Kawachi, A comparative histopathological and immunohistochemically study of capillary hemangioma, pyogenic granuloma and cavernous hemangioma in the oral region: with special reference to vascular proliferation factors, *Int. J. Oral-Med. Sci.* 9 (3) (2011) 241–251.