

## Decompression

# Lumbar extraforaminal decompression: A technical note and retrospective study looking at potential complications as an outpatient procedure

Justin W. Miller, MD <sup>a,b,\*</sup>, Rick C. Sasso, MD <sup>a,b</sup>

<sup>a</sup> *Indiana Spine Group, Indianapolis, IN*

<sup>b</sup> *Department of Orthopaedic Surgery, Indiana University School of Medicine, Indianapolis, IN*

### Abstract

**Background:** Lumbar disc herniation and stenosis that results in compression of a nerve root lateral to the foramen is defined as extraforaminal. In recent years the recognition of such pathology has increased with technology and greater awareness. Various approaches and techniques have been developed for extraforaminal decompression in the lumbar region. The purpose of this study was two fold: 1) Determine the safety of treating patients operatively via a paramedian muscle splitting approach on an outpatient basis, and 2) Highlight the technical aspects of the approach to the extraforaminal region.

**Methods:** One hundred consecutive extraforaminal decompressions were performed from 1992 to 2007 by a single surgeon. A retrospective review was performed consisting of chart reviews. Summary statistics and the Pierson Chi-square test were used to analyze the data. The primary outcome measure was the need for hospital admission or readmission following surgical decompression.

**Results:** Seven of 100 patients (7%) were required to remain in the hospital for twenty-three hour observation due to Medicare requirements. Five (5%) of the patients originally scheduled for an outpatient procedure were converted to inpatient status due to postoperative pain. All were released within 2 days (average 1.25 days). Only one (1%) patient was readmitted for urinary retention that resolved without incident. There was no significant difference ( $P = 0.137$ ) in complication rate between our control and those that underwent extraforaminal decompression.

**Conclusions:** Extraforaminal lumbar decompression as an outpatient procedure can be done safely without the need for hospital admission.

© 2011 SAS - The International Society for the Advancement of Spine Surgery. Published by Elsevier Inc. All rights reserved.

*Keywords:* Extraforaminal; Nerve decompression; Wiltse; Lumbar

Extraforaminal lumbar nerve root compression has been a recognized cause of sciatic pain for some time. One of the earliest reports, by Danforth and Wilson<sup>1</sup> in 1925, described extraforaminal stenosis of the fifth lumbar nerve via bone spurring or compression beneath a thickened lumbosacral ligament. Extraforaminal lumbar disc herniations were first described by Lindblom<sup>2</sup> in 1944 via cadaveric dissection, and not until the 1970s were the first clinical descriptions reported, by Abdullah et al.<sup>3</sup> Since these studies, as well as numerous others that have followed, the diagnosis and treatment of extraforaminal nerve compression stenosis have become more prevalent.

Less invasive techniques have been developed to treat stenosis and herniations within the extraforaminal region, including paramedian and lateral approaches. This is in contrast to previously performed midline approaches, laminectomies, and partial or complete facetectomies. These latter approaches are no longer considered standard of care. Although the approaches have become less invasive, they can be more involved than standard midline approaches for intracanal pathology. Dissection can be more challenging, postoperative pain greater, and the risk of bleeding higher.

There have been numerous reports in the literature regarding operative treatment of extraforaminal nerve compression. The purpose of this study was 2-fold: to determine the safety of treating patients operatively via a paramedian muscle-splitting approach on an outpatient basis and to highlight the technical aspects of the approach to the extraforaminal region. As already mentioned, previous approaches to the extraforaminal region are primarily of his-

\* Corresponding author: Justin W. Miller, MD, Department of Orthopaedics, Indiana University School of Medicine, 8402 Harcourt Road, Suite 400, Indianapolis, IN 46260. Tel.: 317-506-5222; Fax: 317-715-4887.

E-mail address: [jwm7\\_9@yahoo.com](mailto:jwm7_9@yahoo.com)

torical interest only. To have a control, we decided to compare the current cohort of patients with those treated for intracanal pathology via a midline approach. A large retrospective study that looked at the safety and effectiveness of microlumbar discectomies (MLDs) via a standard midline approach was previously performed by the senior surgeon (R.C.S.).<sup>4</sup> All patients were treated in the same fashion as the current cohort with the exception of the approach. We believe this to be a reasonable control, because it is common and within the standard of care to treat patients undergoing MLD on an outpatient basis.

**Methods**

One hundred extraforaminal nerve decompressions, treated via a paramedian muscle-splitting approach, were retrospectively studied from 1992 to 2007. All procedures were performed by a single surgeon (R.C.S.). Patient data were systematically collected through chart review and included demographic data, anatomic level, surgical time, blood loss, hospital stay, complications, admissions, and readmissions. Collection of patient follow-up data for the purposes of this study was only carried out during the immediate postoperative period, not past the first postoperative visit. It was believed that any complications related to the surgery should be captured within this time frame.

All patients underwent preoperative magnetic resonance imaging and plain radiography of the lumbar spine. They underwent operative treatment after failure of conservative measures.

*Operative technique*

The patient is placed in the prone position on an Andrews frame in a knee–chest fashion. A posterior midline skin incision is made, and the lumbodorsal fascia is divided 4 cm to the left or right of the midline (Figs. 1 and 2). The interval between the multifidus and longissimus is identified and bluntly developed (Fig. 3). This interval is fairly well defined at the thoracolumbar junction because there is a distinct cleavage plane between the origin of the multifidus musculature and the longissimus at the L1 level. Moving from cephalad to caudad in the lumbar spine, bands of the multifidus spread further lateral from the midline and have insertion sites that span the surface of the sacrum and sacroiliac ligaments (Fig. 2). Some of the most superficial fibers often lack any bony insertion at all and will insert onto the undersurface of the lumbodorsal fascia (Figs. 4 and 5). When one is exposing lower lumbar levels, it is often best to begin cephalad, where the interval is more easily defined, and to move distal. One may need to divide some of the superficial fibers of the multifidus during exposure of more caudal levels to find the correct interval. Once the interval is found, a localizing needle is used to verify the appropriate level. A standard Wiltse paraspinous approach is then performed between the multifidus and longissimus muscles (Fig. 3).<sup>5,6</sup> The posterior primary ramus and terminal branch

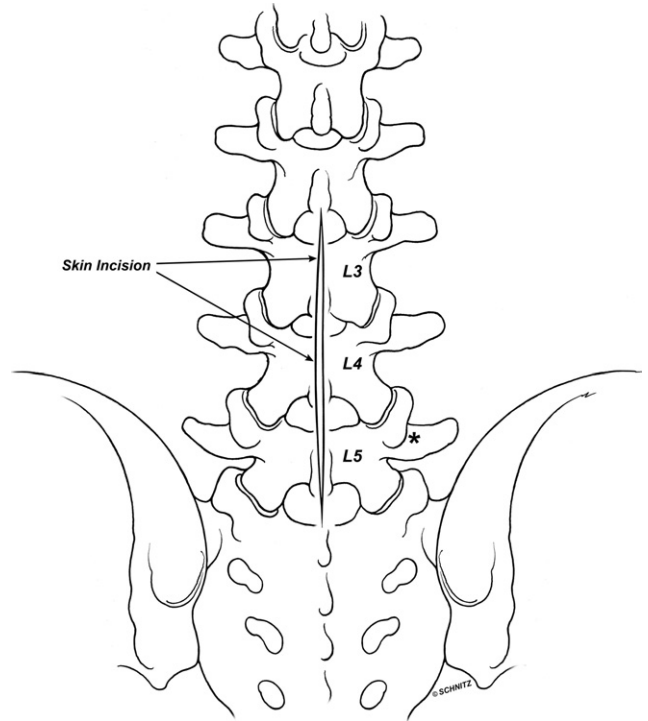


Fig. 1. Surgical skin incision.

of the segmental artery can also help identify the interval that passes between the longissimus and multifidus. Dissection follows the ramus down to the intertransverse mem-

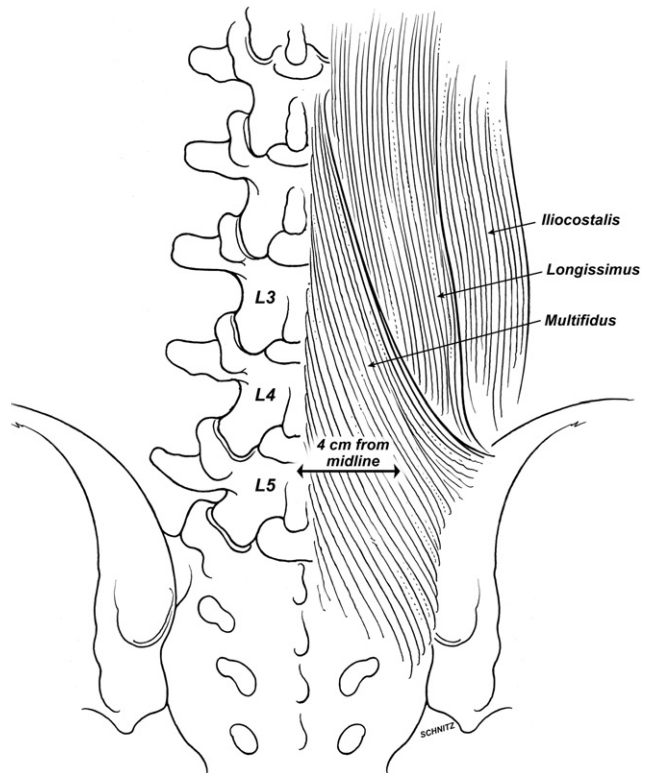


Fig. 2. Distance from midline where lumbodorsal fascia is incised.

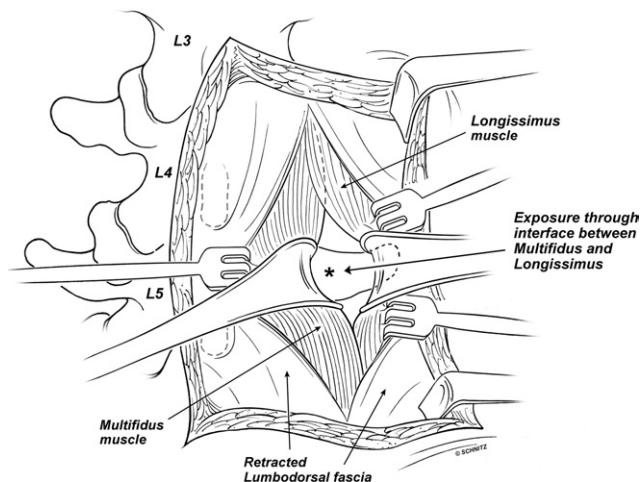


Fig. 3. Wiltse interval.

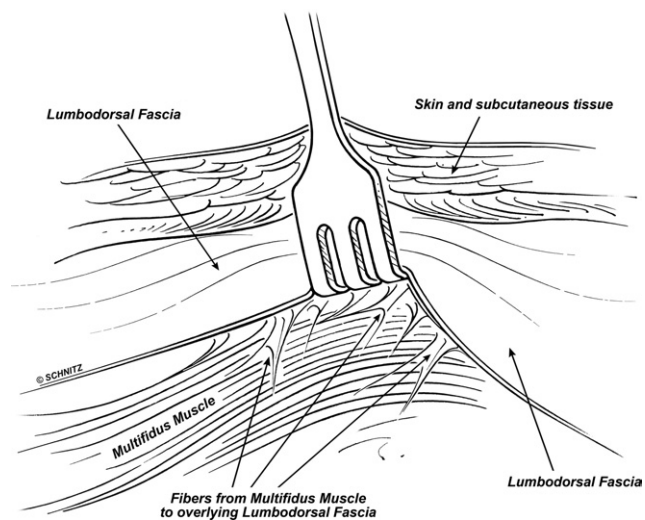


Fig. 5. Multifidus anatomy (superficial fibers).

brane. Deep landmarks include the cephalad facet joint and the pedicle around which the involved nerve exits, the next caudal facet, the interposed pars interarticularis, and the involved transverse processes. The nerve is identified in all cases and decompressed. Meticulous hemostasis is maintained throughout the procedure. The wound is closed in a layered fashion.

*Statistical methods*

Summary statistics (number, mean, standard deviation, and range) were provided for blood loss, surgical time, and hospital admissions/readmissions. The Pearson  $\chi^2$  test was used to compare the complication rate of the current patient cohort with those in the MLD study.

**Results**

A total of 100 extraforaminal nerve decompression procedures were performed in this study. Nerve compression

occurred at all lumbar levels; the distribution is shown in Table 1. The operative times and amount of blood loss are shown in Table 2.

Of the 100 patients, 12 required a hospital stay. Seven were admitted because of Medicare stipulations and the remaining five for pain-related issues. All patients were released within 2 days (mean, 1.25 days) without incident. Complications after the procedure included urinary retention (1%) and prolonged incisional drainage (4%). There were no documented infections, cerebrospinal leaks, or other complications of note. Only 1 patient required readmission, for urinary retention.

By use of the  $\chi^2$  test, the current cohort of patients was compared with those previously studied for MLDs with regard to complication rate. There was no statistical difference ( $P = .137$ ) between the groups of patients.

**Discussion**

The treatment of extraforaminal nerve compression has historically been addressed via a midline approach with varying degrees of facet joint destruction required to adequately decompress the nerve.<sup>7,8</sup> There is some controversy as to whether unilateral facetectomy results in residual back pain and/or instability.<sup>9-11</sup> In addition, the midline approach

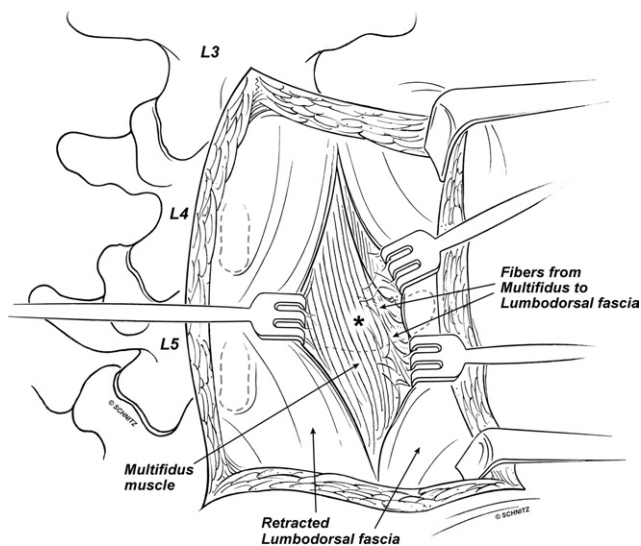


Fig. 4. Multifidus anatomy.

Table 1

Surgical level		
Level (N = 100)	No. of cases	%
L1-2	1	1
L2-3	3	3
L3-4	26	26
L4-5	38	38
L5-S1	31	31
Unknown*	1	1

\* Unable to determine from record.

Table 2  
Operative descriptive statistics

Descriptor	N	Minimum	Maximum	Mean	SD
Estimated blood loss	86	5 mL	100 mL	21.40 mL	15.042 mL
Operative time	68	44 min	197 min	97.76 min	36.467 min

seems to be a more technically challenging route to decompressing the extraforaminal region. Within recent years, various lateral/paramedian approaches have been developed to more directly approach the extraforaminal region.<sup>5,6,12-17</sup> In our study all patients underwent decompression via a traditional Wiltse approach,<sup>7,8</sup> which provides a direct route to the extraforaminal nerve.

Studies in the literature of patients undergoing extraforaminal decompression report anywhere from 0 to 8 hospital admission days after the procedure.<sup>7,8,18-20</sup> The reasons for the increased length of hospital stay include increased muscle dissection, early postoperative pain, inexperience, and increased patient age.<sup>7</sup> If meticulous care is taken during the Wiltse approach, minimal muscle dissection and blood loss need occur. In our study cohort, the mean operative time was 97.76 minutes (range, 44–197 minutes) and mean blood loss was 21.4 mL (range, 5–100 mL).

With strict adherence to anatomic landmarks, natural cleavage planes between muscle groups are developed and the nerve can be decompressed in a direct manner.<sup>6</sup> One must have a firm understanding of the anatomy within the lumbar spine and, specifically, the extraforaminal region to appreciate and locate proper anatomic landmarks. This is true for all levels of the lumbar spine. There are reports suggesting that more caudad levels, specifically L5-S1, are significantly more difficult to treat as a result of anatomic restraints. Some state that it is nearly impossible to address extraforaminal pathology at the L5-S1 region without removal of part of the sacrum, L5 isthmus, hemi-laminectomy, or L5-S1 facet joint. We did not find this to be the case. Within the entire cohort of patients evaluated in this study, 31 had involvement of the L5-S1 region. All cases were approached as previously described. There was no need to remove significant portions of the facet, sacral ala, lamina, or isthmus as some clinicians indicate.

Darden et al.<sup>7</sup> reported 1 postoperative DVT and wound hematoma in 25 patients. Two patients had debilitating, persistent low-back pain. Six continued to have dysesthesias in the preoperative dermatome, although the pain was different from the preoperative radicular pain. All but 2 patients (with disabling back pain only) in this study were doing well at final follow-up. According to Darden et al., the need for hospital stay was thought to result from increased muscle dissection and pain control issues.

Gioia et al.<sup>19</sup> reported 2 wound seromas that required a reoperation in the immediate postoperative period out of a total of 13 patients. There was no explanation as to why this occurred or the potential cause of the seromas. Operative

times and blood loss were similar in these 2 patients compared with the remainder of the study group.

Hassler et al.<sup>21</sup> reported 2 cases of pars interarticularis fracture that was attributed to excessive bone resection during decompression of the nerve root. Despite fracture, there was no evidence of lumbar instability at final follow-up at 30 months.

In our study only 5 patients not previously scheduled for an overnight admission were admitted as a result of postoperative pain (mean, 1.4 days). Seven patients were admitted because of requirements set forth by Medicare. The mean stay for all 12 patients was 1.25 days. Therefore 5% of the total patients in our study cohort were admitted unexpectedly. This is a small percentage of the entire group, and the pain was quickly controlled because the patients were discharged within less than 2 days. As stated previously, pain associated with extraforaminal nerve compression can be more severe than with intracanal compression because of the frequent involvement of the dorsal root ganglion.<sup>7,21-24</sup> This is often the reasoning for hospital admission. Although there may be some merit to this, the majority of patients can be managed medically on an outpatient basis and need not be admitted to the hospital in our experience.

A significant difference in complications was not found ( $P = .137$ ) between the control and the current cohort of patients. There was only 1 readmission to the hospital after the procedure, for urinary retention, which resolved without incident. Although urinary retention is included as a complication in this study, it is something that may develop after any operative procedure and is not unique to spine surgery or extraforaminal nerve decompression. Several patients had prolonged wound drainage that resolved without issue as an outpatient and had no further postoperative complications. All of the complications previously mentioned, except for DVT and urinary retention, can arguably be prevented by medical management and careful surgical technique.

This study was retrospective in nature and therefore has obvious limitations. However, we believe there is sufficient evidence to support the safety of performing extraforaminal nerve root decompression as an outpatient procedure. It is also important to highlight the anatomic variability that can occur during the Wiltse approach. As described in the “Operative technique” section, one should pay careful attention to key landmarks. This is especially true when treating pathology at the most caudal levels in the lumbar spine. The primary surgeon involved in this study is well versed in the anatomy and Wiltse approach and has extensive experience at all levels of the lumbar spine. This most certainly is a factor to consider when looking at the results of this study. For those surgeons who are less experienced, it would be prudent to practice the approach and explore the anatomy in the cadaver laboratory. Our hope is that clarification in this article will help resolve confusion when addressing extraforaminal pathology.

## References

1. Danforth MS, Wilson PD. The anatomy of the lumbosacral region in relation to sciatic pain. *J Bone Joint Surg Am* 1925;7:109–60.
2. Lindblom K. Protrusions of disks and nerve compression in the lumbar region. *Acta Radiol* 1944;25:195–212.
3. Abdullah AF, Ditto EW III, Byrd EB, Williams R. Extreme-lateral lumbar disc herniations. Clinical syndrome and special problems of diagnosis. *J Neurosurg* 1974;41:229–34.
4. Best NM, Sasso RC. Success and safety in outpatient microlumbar discectomy. *J Spin Disord Tech* 2006;19:334–7.
5. Wiltse LL, Bateman JG, Hutchinson RH, Nelson WE. The paraspinous sacrospinalis-splitting approach to the lumbar spine. *J Bone Joint Surg Am* 1968;50:919–26.
6. Wiltse LL, Spencer CW. New uses and refinements of the paraspinous approach to the lumbar spine. *Spine* 1988;13:696–706.
7. Darden BV II, Wade JF, Alexander R, Wood KE, Rhyne AL III, Hicks JR. Far lateral disc herniations treated by microscopic fragment excision. Techniques and results. *Spine* 1995;20:1500–5.
8. Epimenio RO, Giancarlo D, Giuseppe T, Raffaelino R, Luigi F. Extraforaminal lumbar herniation: “far lateral” microinvasive approach retrospective study. *J Spinal Disord Tech* 2003;16:534–8.
9. Epstein NE, Epstein JA, Carras R, Hyman RA. Far lateral lumbar disc herniations and associated structural abnormalities. An evaluation in 60 patients of the comparative value of CT, MRI, and myelo-CT in diagnosis and management. *Spine* 1990;15:534–9.
10. Hazlett JW, Kinnard P. Lumbar apophyseal process excision and spinal instability. *Spine* 1982;7:171–6.
11. Reulen HJ, Pfaundler S, Ebeling U. The lateral microsurgical approach to the “extracanalicular” lumbar disc herniation. I: A technical note. *Acta Neurochir (Wien)* 1987;84:64–7.
12. Vialle R, Wicart P, Drain O, Dubousset J, Court C. The Wiltse paraspinous approach to the lumbar spine revisited: An anatomic study. *Clin Orthop Relat Res* 2006;445:175–80.
13. Watkins MB. Posterolateral bonegrafting for fusion of the lumbar and lumbosacral spine. *J Bone Joint Surg Am* 1959;41:388–96.
14. Wiltse LL. Surgery for intervertebral disk disease of the lumbar spine. *Clin Orthop Relat Res* 1977;22–45.
15. Wiltse LL. The paraspinous sacrospinalis-splitting approach to the lumbar spine. *Clin Orthop Relat Res* 1973;48–57.
16. Wiltse LL, Guyer RD, Spencer CW, Glenn WV, Porter IS. Alar transverse process impingement of the L5 spinal nerve: The far-out syndrome. *Spine* 1984;9:31–41.
17. Wiltse LL, Hutchinson RH. Surgical treatment of spondylolisthesis. *Clin Orthop Relat Res* 1964;35:116–35.
18. Perez-Cruet MJ, Foley KT, Isaacs RE, Rice-Wyllie L, Wellington R, Smith MM, Fessler RG. Microendoscopic lumbar discectomy: A technical note. *Neurosurgery* 2002;51:S2129–36.
19. Gioia G, Mandelli D, Capaccioni B, Randelli F, Tessari L. Surgical treatment of far lateral lumbar disc herniation. Identification of compressed root and discectomy by lateral approach. *Spine* 1999;24:1952–7.
20. Maroon JC, Kopitnik TA, Schulhof LA, Abla A, Wilberger JE. Diagnosis and microsurgical approach to far-lateral disc herniation in the lumbar spine. *J Neurosurg* 1990;72:378–82.
21. Hassler W, Brandner S, Slansky I. Microsurgical management of lateral lumbar disc herniations: Combined lateral and interlaminar approach. *Acta Neurochir (Wien)* 1996;138:907–10; discussion 10–1.
22. Muller A, Reulen HJ. A paramedian tangential approach to lumbosacral extraforaminal disc herniations. *Neurosurgery* 1998;43:854–61; discussion 61–2.
23. O’Hara LJ, Marshall RW. Far lateral lumbar disc herniation. The key to the intertransverse approach. *J Bone Joint Surg Br* 1997;79:943–7.
24. Postacchini F, Cinotti G, Gumina S. Microsurgical excision of lateral lumbar disc herniation through an interlaminar approach. *J Bone Joint Surg Br* 1998;80:201–7.