

Technical Aspects of Lung Transplantation: General Considerations

Samina Park, M.D., Young Tae Kim, M.D., Ph.D.

Department of Thoracic and Cardiovascular Surgery, Seoul National University Hospital, Seoul National University College of Medicine, Seoul, Korea

ARTICLE INFO

Received July 14, 2022

Revised July 19, 2022

Accepted July 21, 2022

Corresponding author

Young Tae Kim

Tel 82-2-2072-3161

Fax 82-2-764-3664

E-mail ytkim@snu.ac.kr

ORCID

<https://orcid.org/0000-0001-9006-4881>

Surgical approaches to lung transplantation in adults vary substantially among surgeons and institutions, but the underlying principles are consistent. This article provides a surgical overview of bilateral sequential lung transplantation.

Keywords: Lung transplantation, Bilateral sequential, Surgical technique

Introduction

Lung transplantation has successfully been established, and about 4,500 lung transplants are now performed annually around the world [1,2]. The surgical approaches to adult lung transplantation are relatively variable among surgeons and institutions, but the principles are not substantially different. This article describes bilateral sequential lung transplantation from a surgical perspective.

Position

The patient is positioned supine with his or her arms elevated or abducted to expose the entire thorax. To prevent brachial plexus neuropathy, it is important that the arms are not abducted excessively. A cushion beneath the middle of the thorax supporting the back facilitates hilum exposure. The bilateral inguinal regions should be prepared for the application of extracorporeal membrane oxygenation (ECMO) assistance. If necessary, catheters are inserted into the femoral veins and arteries to permit prompt ECMO cannulation (Fig. 1).

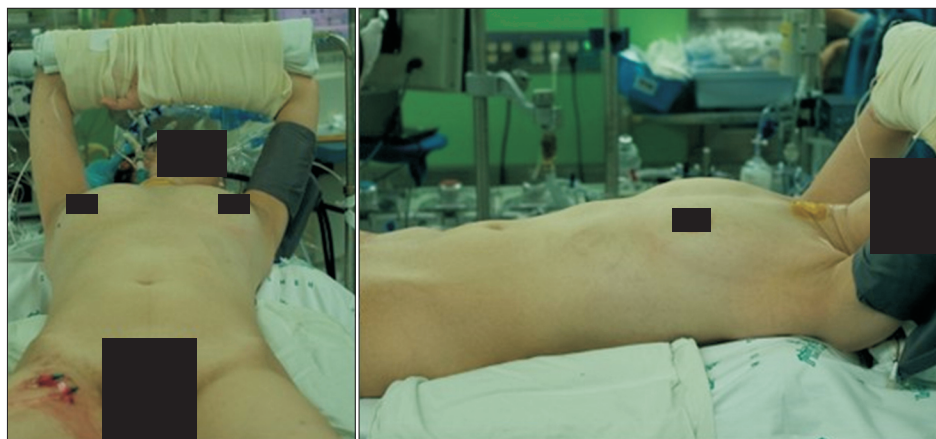


Fig. 1. The patient is positioned supine with his or her arms elevated with a cushion beneath the middle of the thorax. The bilateral inguinal regions are prepared for the application of extracorporeal membrane oxygenation assistance.

Approach

The most common method is the clamshell incision, which allows excellent exposure of the heart, mediastinum, and bilateral pleural cavities. From the anterior axillary line to the sternum, the incision is made along the fourth intercostal space (Fig. 2). For female patients, it is necessary to follow the bilateral inframammary lines and to dissect breast tissue above the pectoralis major muscle. Breast implants can be preserved without problems using this method. Nonetheless, a risk of morbidity is associated with the division of the sternum and bilateral internal mammary arteries. Some centers divide the sternum in a beveled or triangular manner in order to increase the surface area of the divided sternum and thereby reduce the likelihood of sternal malunion [3].

Bilateral anterolateral thoracotomy is advantageous in order to preserve the sternum and minimize morbidity. This strategy is ideal for chronic obstructive pulmonary disease patients with large thoracic cavities and maintained right heart function. The transplantation of a single lung is another good indication for anterolateral thoracotomy. In general, further chondrotomy is required to improve cannulation exposure. Sternotomy is typically favored by cardiac surgeons. It can avoid chest wall complications by sparing the bilateral internal mammary arteries. However, the dissection of pleural adhesions is limited with this method, and it is unsuitable when the hilum is located very deeply.

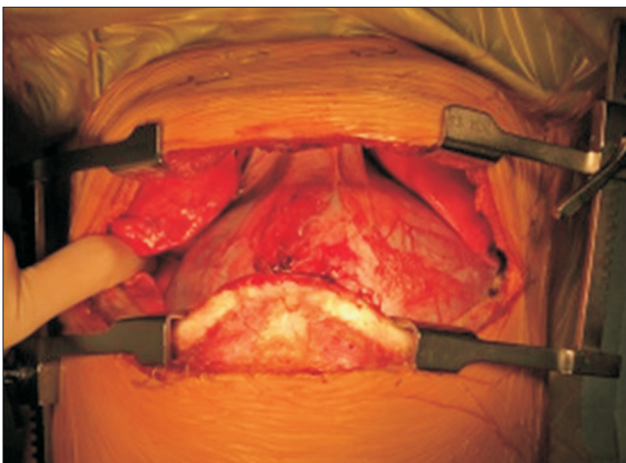


Fig. 2. A clamshell incision provides excellent exposure of the heart, mediastinum, and bilateral pleural cavities.

Pneumonectomy and cardiopulmonary support

Adhesiolysis should be performed as much as possible prior to heparin administration to minimize bleeding. Meticulous hemostasis and protection of the phrenic and vagus nerves are of utmost importance, and they must be safeguarded throughout the surgical procedure. Low-voltage electrocautery or energy devices must be utilized to alleviate the adhesion surrounding these nerves. Isolated calcifications or thick adhesions along the nerves may be left to prevent nerve injury. Tiny systemic collaterals must be ligated in conjunction with the division of the inferior pulmonary ligament.

Frequently, the donor lungs lack an adequate length of the pulmonary artery or left atrial cuff, and it is recommended that sufficient tissue be left from the recipient. The pulmonary artery must be dissected and separated with a surgical stapler beyond the first bifurcation to ensure an adequate stump length and to correct for size mismatch. Before dividing the pulmonary artery, care must be taken to avoid dividing the Swan-Ganz catheter by accident. In a similar fashion, the pulmonary veins should be separated beyond the first branching point of each lobar vein. The lobar bronchus is dissected and divided so that the distal portion of the main bronchus can be trimmed. The maximum amount of peribronchial tissue should be preserved. The bronchial artery and adjacent nodal arteries should be carefully ligated or managed simultaneously. In restrictive lung disease, a small thoracic cavity and an elevated diaphragm can complicate the placement of the donor lung, which is typically on the right side. A thick silk stitch can be placed on the top of the diaphragm and passed through the intercostal space to pull the diaphragm down and make room for the donor lung, thereby facilitating the procedure. In bilateral sequential lung transplantation, the first lung to be transplanted is the one with least perfusion or the one with the most damage in cases without cardiopulmonary support.

Prior to attempting one-lung ventilation, cardiac assistance should be initiated if the patient has severe pulmonary hypertension. Severe hypoxia caused by a unilaterally injured lung is treated by dividing the pulmonary artery, thereby reducing the amount of blood that is shunted. In the event of a major air leak, rapid one-lung ventilation or manual compression of the leaking point can allow the mechanical ventilator to maintain adequate tidal volume.

Cardiopulmonary assistance helps in maintaining stable hemodynamics, particularly in cases of pulmonary hyper-

tension accompanied by right heart dysfunction. It allows controlled reperfusion and minimizes the hyperperfusion of the first implanted lung during the implantation of the second lung, a condition known as first lung syndrome. Additionally, the protected ventilation method can be used for lungs that have already been implanted. Configuration and techniques of cardiopulmonary support vary based on the surgeon's preference; nonetheless, conventional cardiopulmonary bypass or central/peripheral ECMO are frequently used in lung transplants.

ECMO has demonstrated various benefits over cardiopulmonary bypass (CPB): (1) the use of a low dose of heparin, (2) a reduced systemic inflammatory response, (3) a low transfusion rate, and (4) the likelihood of prolonged preoperative or postoperative use of ECMO. Nevertheless, standard CPB should be utilized when hemodynamic instability persists, including hypoxia and hypercarbia in spite of ECMO assistance, and when simultaneous cardiac operations are needed. Since 2018, Seoul National University Hospital has implemented central venoarterial ECMO for lung transplants. Cannulation is typically performed on the ascending aorta and bilateral femoral veins. Under transesophageal echocardiography (TEE) guidance, the bilateral femoral veins are cannulated percutaneously with the Seldinger technique. Central arterial cannulation results in stable oxygen delivery to the heart and brain, which are the primary concerns of peripheral ECMO. During central ECMO, the activated clotting time is maintained between 180 and 200 seconds. If necessary for the protective ventilation strategy, central venoarterial ECMO can be easily changed to peripheral venovenous or venoarterial ECMO at the end of surgery. We believe that our strategies result in no risk of air embolism around the venous cannula, a clear surgical field with only 1 cannula remaining in the thorax, the possibility of prolonged use of peripheral cannulae for preoperative or postoperative ECMO support, no additional incision to the inguinal region, and a brief weaning period.

Hilar preparation

To facilitate dissection following pneumonectomy, the pulmonary vein stumps are pulled using Duval clamps. The pericardium surrounding the pulmonary veins is completely dissected. On the right side, we typically develop an interatrial groove to allow adequate clamp space. Frequently, the left atrial wall is extremely thin, necessitating caution to avoid injury. After the left atrial cuff has been meticulously prepared, stay sutures are placed on the

stumps to facilitate identification of the structure. The pulmonary arterial stumps are then clamped with Duval clamps and pulled to dissect the pulmonary artery. To ensure a sufficient length for vascular clamp, we extend the pulmonary artery dissection to the intrapericardial level (Fig. 3). Stay sutures are again placed on the pulmonary arterial stumps. The bronchial stumps are pulled by using Duval clamps, and the peribronchial tissues are dissected. Concerning bronchial ischemia, as many peribronchial lymph nodes as possible should be preserved. We spend sufficient time performing meticulous hemostasis around the mediastinal lymph nodes and collateral vessels because it is very difficult to see the posterior mediastinum once the anastomosis has been completed. To prevent soiling of the pleural cavity, we cut the bronchus just proximal to the upper lobar bronchus before placing the donor lung in the pleural cavity.

Donor lung preparation

Each orifice of the pulmonary vessels is evaluated, as is the length of the stumps. If necessary, anatomical variations or injured areas should now be investigated and repaired. Insufficiency of the left atrial cuff is a frequent occurrence. When the recipient's left atrial cuff is sufficiently large, we can simply suture them with native tissue. When the left atrial limb is too short or when the pulmonary veins are incorrectly divided without a common cuff, pericardial reconstruction should be considered [4]. When a

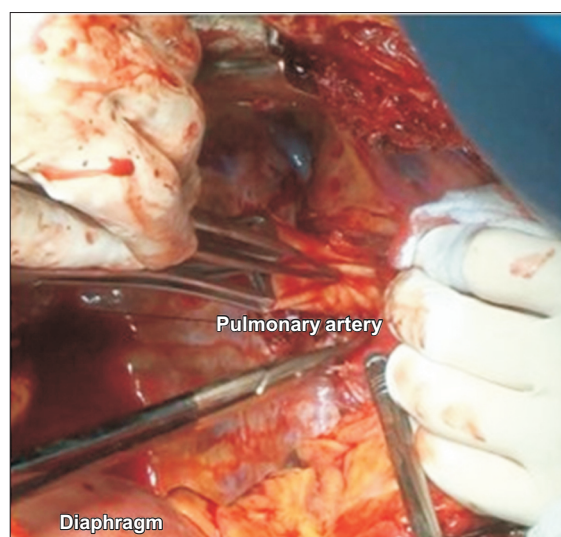


Fig. 3. The pulmonary artery is clamped and pulled with Duval clamps.

tracheal bronchus is discovered on the donor lung, cranioplasty of the recipient trachea or bronchoplasty of the donor bronchus may be performed [5,6]. Nevertheless, segmentectomy of the corresponding region may be performed without increasing morbidity [7]. Prior to deflating the donor lung, the size of the donor lung is evaluated, and lung volume reduction procedures are considered if the lung is oversized. Typically, wedge resection is adequate to reduce the lung volume or to resect emphysematous areas. Due to the high risk of bronchopleural fistula in the donor lung, however, peribronchial tissue must be preserved when lobectomy is required.

Implantation

The order of anastomosis in our center is as follows: bronchus, pulmonary artery, and left atrial cuff. We anastomose the bronchus using a single running 4-0 polydioxanone suture. Generally, we prefer end-to-end anastomosis, but a telescoping technique is used with the depth of 1 cartilage ring for cases of severe size mismatch (Fig. 4). After finishing bronchial anastomosis, routine bronchoscopy and air leak tests are performed. The best anastomotic technique for the bronchus remains a matter of debate [8-10]. Revascularization of the donor bronchus typically takes 2-4 weeks. As deoxygenated blood is immediately perfused following transplantation, it is reasonable to aim for a short donor bronchus to reduce bronchial ischemia. After transplantation, airway complications are the most common complication [11]. Typical manifestations include

sloughing of the anastomosis, exophytic granulation, anastomotic dehiscence, bronchial stenosis, vanishing airway syndrome, and tracheobronchomalacia. In early experience, additional coverage around the anastomosis with omental fat or pericardial fat was attempted to reduce airway complications [9]. In addition, it was suggested that direct bronchial arterial revascularization could reduce early bronchial ischemia and potentially reduce bronchiolitis obliterans syndrome [12-14]. Due to its technical complexity and additional operative time, direct bronchial arterial revascularization has only been adopted by a small number of centers.

We anastomose the pulmonary artery using a single Prolene 6-0 running suture (Fig. 5). The suture is knotted after the pulmonary artery is filled with heparin solution. A brief declamping of the proximal pulmonary artery while the distal pulmonary artery is clamped enables the identification of significant anastomotic disruption. To compensate for size mismatch during anastomosis, direct replication, tack sutures, stapling, and auto-pericardial patching can be used [15]. If the size discrepancy is large, the anastomosis can be made just distal to the first branch rather than the main pulmonary artery of the recipient. In adults, stenosis is rarely a problem in the pulmonary artery anastomosis. In contrast, long stumps of donor and recipient can cause the pulmonary artery to kink around the anastomosis. If significant stenosis is discovered postoperatively, stenting or ballooning can be performed on the stenotic segment. Due to the reduction of the afterload, the native pulmonary arteries become normalized following lung transplant. Rarely, giant pulmonary artery aneurysms in

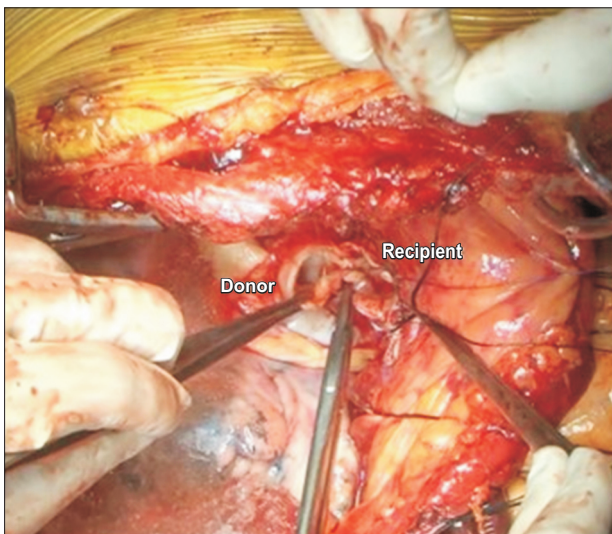


Fig. 4. Bronchial anastomosis using a single running 4-0 polydioxanone suture.

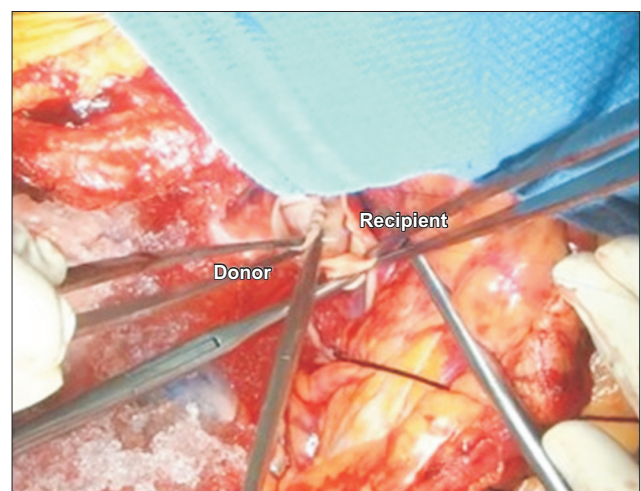


Fig. 5. Arterial anastomosis using a single running 6-0 Prolene suture.

cases of idiopathic pulmonary hypertension may necessitate total pulmonary trunk replacement [16].

We anastomose the left atrial cuff using a single Prolene 5-0 running suture. After establishing a common atrial cuff, an everting mattress suture is applied to the posterior wall to reduce the risk of thrombus formation along the suture line, while a simple running suture is applied on the anterior wall (Fig. 6). For de-airing, the suture is knotted after the pulmonary artery is partially declamped, and blood containing air is slowly expelled for at least 2 to 3 minutes under moderate ventilation. One of the most devastating complications is venous congestion, which is caused by stenosis of the left atrial cuff. Consequently, the pulse-string effect should be avoided when tying the knot. In some instances, Intraoperative TEE may be used, but routinely examining flow acceleration around the anastomosis is not recommended.

Reperfusion strategy

Controlled reperfusion with protective ventilation is a cornerstone of intraoperative management for preventing ischemia-reperfusion injury and, ultimately, primary graft dysfunction. Endothelial cells in donor lungs have stiff cell membranes, and rapid reperfusion induces significant stress to the lung [17]. In the absence of cardiopulmonary support, gradual reperfusion of blood flow by slowly releasing the pulmonary artery clamp for at least 10 minutes is recommended [18]. When intraoperative ECMO is ap-

plied, low perfusion pressure and low blood flow can be easily maintained. At the same time, while the contralateral lung is being transplanted, ECMO should not be run at full flow after the first lung has been implanted to prevent warm ischemia to the newly implanted lung [17]. A protective ventilation strategy consisting of a low tidal volume, adequate positive end-expiratory pressure, and low fraction of inspired oxygen is applied to the new lung to prevent atelectasis and improve oxygenation. In addition, some pharmaceuticals, such as steroids or mannitol, are administered at the time of reperfusion to reduce ischemia-reperfusion injury [19,20].

Closure and lung volume reduction procedure

The chest wall, internal mammary vessels, inferior pulmonary ligament, pericardium, and cannulation site receive special attention during hemostasis. We place 1 right-angled tube and 1 straight tube in each pleural cavity, as well as 1 right-angled tube in the pericardial cavity. A small recipient receiving oversized donor lungs may experience hemodynamic instability, atelectasis, and recurrent respiratory infection. In this situation, lung volume reduction procedures can additionally be performed. Wedge resection of the right middle lobe and lingula can be easily performed without complications. In cases of severe pulmonary edema, coagulopathy, or oversized donor lung grafts, chest closure may be delayed [21]. The divided sternum is closed with Kirschner wire or heavy Vicryl sutures.

Conclusion

Lung transplantation is a well-established and widely accepted treatment for end-stage lung disease. With advances in surgical techniques and perioperative management, postoperative morbidity and mortality have decreased substantially. Nonetheless, lung transplantation necessitates precise surgical techniques based on an understanding of the physiology. Standardization of each step is the key to achieving safe and successful surgical outcomes in lung transplantation.

ORCID

Samina Park: <https://orcid.org/0000-0001-9625-2672>

Young Tae Kim: <https://orcid.org/0000-0001-9006-4881>

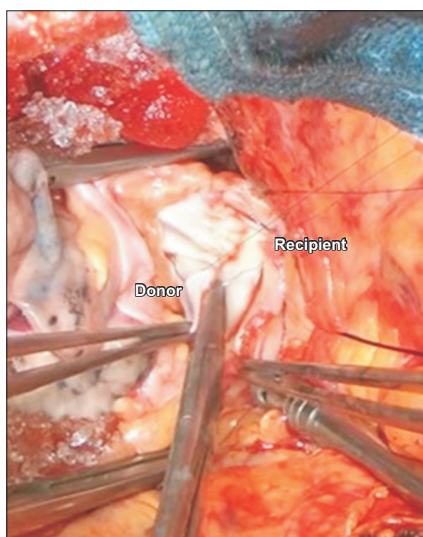


Fig. 6. Atrial anastomosis using a single running 5-0 Prolene suture.

Author contributions

Conceptualization: YTK. Data curation: SP, YTK. Formal analysis: SP, YTK. Methodology: SP, YTK. Project administration: YTK. Visualization: SP, YTK. Writing—original draft: SP. Writing—review & editing: YTK.

Conflict of interest

No potential conflict of interest relevant to this article was reported.

Funding

This research did not receive any specific grant from funding agencies in the public, commercial, or not-for-profit sectors.

References

1. Khush KK, Cherikh WS, Chambers DC, et al. *The International Thoracic Organ Transplant Registry of the International Society for Heart and Lung Transplantation: thirty-sixth adult heart transplantation report - 2019; focus theme: donor and recipient size match*. J Heart Lung Transplant 2019;38:1056-66.
2. Rossano JW, Singh TP, Cherikh WS, et al. *The International Thoracic Organ Transplant Registry of the International Society for Heart and Lung Transplantation: twenty-second pediatric heart transplantation report - 2019; focus theme: donor and recipient size match*. J Heart Lung Transplant 2019;38:1028-41.
3. Boasquevisque CH, Yildirim E, Waddel TK, Keshavjee S. *Surgical techniques: lung transplant and lung volume reduction*. Proc Am Thorac Soc 2009;6:66-78.
4. Oto T, Rabinov M, Negri J, et al. *Techniques of reconstruction for inadequate donor left atrial cuff in lung transplantation*. Ann Thorac Surg 2006;81:1199-204.
5. Miyahara S, Hamaji M, Aoyama A, et al. *Backtable bronchoplasty for donor tracheal bronchus in lung transplantation*. Gen Thorac Cardiovasc Surg 2020;68:1536-8.
6. Sekine Y, Fischer S, de Perrot M, Pierre AF, Keshavjee S. *Bilateral lung transplantation using a donor with a tracheal right upper lobe bronchus*. Ann Thorac Surg 2002;73:308-10.
7. Mendogni P, Tosi D, Rosso L, et al. *Lung transplant from donor with tracheal bronchus: case report and literature review*. Transplant Proc 2019;51:239-41.
8. Schweiger T, Nenekidis I, Stadler JE, et al. *Single running suture technique is associated with low rate of bronchial complications after lung transplantation*. J Thorac Cardiovasc Surg 2020;160:1099-108.
9. Date H, Trulock EP, Arcidi JM, Sundaresan S, Cooper JD, Patterson GA. *Improved airway healing after lung transplantation: an analysis of 348 bronchial anastomoses*. J Thorac Cardiovasc Surg 1995;110:1424-33.
10. Weder W, Inci I, Korom S, et al. *Airway complications after lung transplantation: risk factors, prevention and outcome*. Eur J Cardiothorac Surg 2009;35:293-8.
11. Machuzak M, Santacruz JF, Gildea T, Murthy SC. *Airway complications after lung transplantation*. Thorac Surg Clin 2015;25:55-75.
12. Pettersson G, Arendrup H, Mortensen SA, et al. *Early experience of double-lung transplantation with bronchial artery revascularization using mammary artery*. Eur J Cardiothorac Surg 1994;8:520-4.
13. Daly RC, Tadjkarimi S, Khaghani A, Banner NR, Yacoub MH. *Successful double-lung transplantation with direct bronchial artery revascularization*. Ann Thorac Surg 1993;56:885-92.
14. Nicolls MR, Zamora MR. *Bronchial blood supply after lung transplantation without bronchial artery revascularization*. Curr Opin Organ Transplant 2010;15:563-7.
15. Yokoyama Y, Chen-Yoshikawa TF, Nakajima D, Ohsumi A, Date H. *Various techniques for anastomosis of pulmonary arteries with size mismatch during lung transplantation*. JTCVS Tech 2021;9:192-4.
16. Schwarz S, Benazzo A, Prosch H, et al. *Lung transplantation for pulmonary hypertension with giant pulmonary artery aneurysm*. J Thorac Cardiovasc Surg 2020;159:2543-50.
17. Van Raemdonck D, Hartwig MG, Hertz MI, et al. *Report of the ISHLT Working Group on primary lung graft dysfunction part IV: prevention and treatment: a 2016 consensus group statement of the International Society for Heart and Lung Transplantation*. J Heart Lung Transplant 2017;36:1121-36.
18. Bhabra MS, Hopkinson DN, Shaw TE, Hooper TL. *Critical importance of the first 10 minutes of lung graft reperfusion after hypothermic storage*. Ann Thorac Surg 1996;61:1631-5.
19. Gray AL, Mulvihill MS, Hartwig MG. *Lung transplantation at Duke*. J Thorac Dis 2016;8:E185-96.
20. Hayanga JW, D'Cunha J. *The surgical technique of bilateral sequential lung transplantation*. J Thorac Dis 2014;6:1063-9.
21. Shigemura N, Orhan Y, Bhama JK, et al. *Delayed chest closure after lung transplantation: techniques, outcomes, and strategies*. J Heart Lung Transplant 2014;33:741-8.