

# Closed Incisional Negative Pressure Therapy Significantly Reduces Early Wound Dehiscence after Reduction Mammoplasty

Owen N. Johnson III, MD,  
FACS\*†‡  
Cara L. Reitz, MD\*  
Khang Thai, MD\*†

**Background:** Closed incisional negative pressure therapy (ciNPT) has been shown to improve surgical outcomes. Functional reduction mammoplasty has a wound dehiscence rate of 25% and higher in most series, requiring extra care and delayed secondary healing. We aimed to determine if shifting from standard care dressings to ciNPT reduced early dehiscence after breast reduction.

**Methods:** This multisurgeon retrospective study compared consecutive patients undergoing primary breast reduction dressed with ciNPT to similar patients with standard dressing materials. Perioperative management was otherwise unchanged. Early dehiscence was defined as incisional disruption requiring wound care within the first 30 postoperative days. Statistical analyses were performed using t-test and Fisher exact test.

**Results:** We analyzed 79 patients with 158 breasts (114 standard and 44 ciNPT). Both groups were similar. Mean ages were 35 and 34 years; body mass index, 28.5 and 27.4 kg/m<sup>2</sup>; and reduction volumes, 565 and 610 g, respectively. None were active smokers, and 9.5% were former smokers. Wise pattern skin incisions were used in all, and parenchymal resections mostly utilized superomedial pedicles. Median ciNPT treatment was 6 days. Early dehiscence was significantly lower with ciNPT, occurring in only 1 of 44 (2%) breasts, compared to 16 of 114 in the standard group (14%),  $P = 0.003$ , a relative risk reduction of 84%. Two control patients required debridement, whereas none of the ciNPT patients did.

**Conclusion:** Application of ciNPT markedly decreased early dehiscence requiring wound care, compared to using standard dressings, in otherwise similarly risk-stratified breast reduction patients. (*Plast Reconstr Surg Glob Open* 2021;9:e3496; doi: 10.1097/GOX.0000000000003496; Published online 22 March 2021.)

## INTRODUCTION

Closed incisional negative pressure therapy (ciNPT) was introduced in 2006 as an adjunct to certain orthopedic surgery procedures as a method to provide a clean, dry wound environment in the immediate postoperative period.<sup>1</sup> Continuous negative pressure on top of a closed

incision alleviates tension across the wound,<sup>2</sup> removes weeping fluid, and acts as a barrier to the external environment. Mounting evidence in the orthopedic,<sup>3-6</sup> cardiothoracic,<sup>7-9</sup> colorectal,<sup>10,11</sup> abdominal wall,<sup>12-14</sup> vascular,<sup>15,16</sup> and plastic<sup>17-19</sup> surgery literature in the past 5 years has suggested that ciNPT can improve surgical outcomes. In breast surgery, Kim et al<sup>17</sup> showed that use of ciNPT reduced wound-related complications and mastectomy flap necrosis in women undergoing immediate expander-based reconstruction.

Reduction mammoplasty for symptomatic breast hypertrophy remains a common operation performed by the US plastic surgeons.<sup>20</sup> Patients seek relief from problems associated with breasts that are too large, but usually desire a pleasing shape with as much preserved sensation and function as possible. Numerous gland resection

From the \*Department of Surgery, William Beaumont Army Medical Center, El Paso, Tex.; †Department of Surgery, Uniformed Services University of the Health Sciences, F. Edward Hébert School of Medicine, Bethesda, Md.; and ‡Department of Surgery, Texas Tech University Health Sciences Center El Paso, Paul L. Foster School of Medicine, El Paso, Tex.

Received for publication November 17, 2020; accepted January 8, 2021.

Copyright © 2021 The Authors. Published by Wolters Kluwer Health, Inc. on behalf of The American Society of Plastic Surgeons. This is an open-access article distributed under the terms of the [Creative Commons Attribution-Non Commercial-No Derivatives License 4.0 \(CCBY-NC-ND\)](https://creativecommons.org/licenses/by-nc-nd/4.0/), where it is permissible to download and share the work provided it is properly cited. The work cannot be changed in any way or used commercially without permission from the journal.

DOI: 10.1097/GOX.0000000000003496

**Disclosure:** The authors have no financial interest to declare in relation to the content of this article. The views expressed in this article are those of the authors and do not reflect official policy of William Beaumont Army Medical Center, the Department of the Army, the Department of Defense, or the US Government.

methods of over the years have been designed to reduce breast size and weight while leaving the tissue with adequate blood supply. Skin incision patterns are tailored to the individual patient, but the most common techniques (Wise pattern, vertical, and inverted-T) continue to largely rely on the skin's tightening and brassiere-like support of the parenchyma.

Regardless of the technique, overall complications after reduction remain high and approach 50%.<sup>21</sup> The underlying breast tissue pressures the overlying skin envelope, which is reduced, tightened, and sutured under tension. Wound dehiscence, most common at points of intersecting incisions where tension is high and flap perfusion is tenuous, remains frustrating.

Properly selected patients undergoing this elective, clean case have an approximate 25% wound dehiscence rate overall,<sup>22</sup> and these rates can be as high as 100% in obese patients undergoing large volume reductions.<sup>23</sup> Dehiscence can require daily wound care, additional office visits, and unfavorable scarring from secondary healing. Associated costs can be higher and patient satisfaction can be lower. Lower pole contraction or poor scarring can lead to disappointing long-term aesthetic results.

Given that ciNPT improves wound-related complications in other types of surgery, and that breast reduction is a common plastic surgery with a high rate of dehiscence, our objective was to see if we could improve early outcomes by altering the type of dressing we used in our practice. We aimed to determine if shifting from standard dressings to ciNPT could reduce clinically meaningful surgical wound dehiscence in the early healing period after breast reduction.

## METHODS

This was a single-institution study involving patients treated by certified plastic and reconstructive surgeons at a military academic medical center. The study was conducted in compliance with the Declaration of Helsinki ethical principles. Over a 10-month period ending August 2018, all consecutive patients who underwent primary reconstructive reduction mammoplasty were dressed with ciNPT instead of standard dressings. All other preoperative, intraoperative, and postoperative care were unaltered. Our institution provided the foam-based ciNPT (PREVENA Therapy; KCI, now part of 3M Company, San Antonio, Tex.).

All patients met criteria for reconstructive breast reduction for functional benefit. Patients were screened appropriately for breast neoplasms, medical and psychological fitness for surgery, and realistic expectations. Those selected for surgery had typical signs and symptoms of macromastia and most had failed a trial of weight loss and/or physical therapy.

Our contraindications to surgery included: morbid obesity that might benefit from bariatric surgery first, recent significant weight instability, pregnancy, active breastfeeding, active cigarette smoking or other tobacco or nicotine use, unrealistic expectations, and medical comorbidities such as poorly controlled diabetes or immunosuppression. Good candidates who were former

smokers were offered surgery if they understood risks of complications, attested to cessation of all products for at least 6 weeks, and demonstrated a negative preoperative urine cotinine test.

This study did not include any patients undergoing secondary revision from a previous reduction, breast amputation with free nipple graft, liposuction-based reduction, cosmetic mastopexy, or breast cancer reconstruction. No patients had a history of breast irradiation.

The surgeons saw each patient at least twice preoperatively. Each patient was thoroughly counseled on the planned use of ciNPT as a dressing and provided consent. Similar clinical pathways were used in all patients, consistent with our practice in the preceding years. We performed surgery in a hospital setting, typically with general anesthesia, preoperative intravenous acetaminophen, intraoperative injection of bupivacaine liposome injectable suspension (Exparel, Pacira Pharmaceuticals, Parsippany, N.J.), and narcotic-minimizing postoperative pain regimens. We used Wise pattern skin incisions for every patient in this study and superomedial dermoglandular pedicles in most. Resected breast tissue specimens were weighed and sent for routine pathologic examination.

Standard dressings were various combinations of sterile gauze, petrolatum gauze, non-adhesive barriers, transparent film dressing (Tegaderm Transparent Film Dressing; 3M Company, St. Paul, Minn.), and/or adhesive skin closures (Steri-Strip Reinforced Adhesive Skin Closures; 3M Company). This depended on surgeon preference and patient history of adverse reaction to certain adhesives or tapes. Patients wore specialized postoperative breast support garments fitted to size.

Closed incision NPT consisted of a peel-and-stick 7-day foam dressing with integrated tubing that delivered -125 mm Hg negative pressure to the closed Wise pattern incisions and allowed for wound fluid removal. The surgeon ensured a good seal and no error indications on the device before leaving the operating room.

Patients were discharged the morning after an overnight stay with: surgical drains, incentive spirometers, supportive garments, and the ciNPT devices. They were instructed to call for any device malfunction or troubleshooting, and taught how to care for drains and record output. Patients were seen in the office within 1 week of surgery—for practical reasons, usually on postoperative day 6—for removal of drains and ciNPT dressings by nursing staff.

After ciNPT removal, the incisional wounds were checked and redressed with petrolatum gauze for a week. At 2 weeks, incision care was transitioned to silicone-based scar gel (Biocorneum Advanced Scar Treatment; Sientra, Inc., Santa Barbara, Calif.) until postoperative week 4. We instructed patients on scar massage, direct sunlight avoidance, gradual return to lifting and activities, and slow return to normal supportive garments. Postoperative photographs were taken at 6 weeks, 6 months, and 1 year after surgery.

Data on these patients were de-identified, retrospectively reviewed, and compared to consecutive patients who had undergone the same operations by the same

surgeons in a preceding 20-month period but with standard dressings (historical controls). We examined patient demographics and surgical factors like age, body mass index, smoking history, weight of breast tissue removed (in grams), pedicle used, ciNPT treatment duration, and drain use. We reviewed all clinic charts primarily to identify patients with clinically meaningful wound dehiscence, defined as disruption of the surgical wound and/or the need for any type of wound care. This was apparent by surgeons' notes, photograph documentation, and often a higher-than-usual number of postoperative visits (for wound care and checks).

We also secondarily noted other adverse outcomes such as readmission, need for debridement, infection, seroma, and hematoma. If there were any minor wound findings that did not represent actual disruption of the incision and did not require wound care, like small areas of superficial epidermolysis or contact dermatitis, these are not considered as clinically meaningful dehiscence.

Given the sample sizes, statistical analyses were performed using contingency tables and the Fisher exact test for categorical variables. Continuous variables were compared using t-test and represented as means with SD. Any  $P < 0.05$  was defined as significant.

## RESULTS

### Patients and Techniques

During the study period, 79 patients with 158 breast incisions were included in our study. Fifty-seven patients with 114 incisions received postoperative care with standard dressings, and 22 patients with 44 incisions received ciNPT. The 2 patient populations were statistically similar in every category of interest (Table 1). All patients were women, with a mean age of  $35.1 \pm 12.0$  years in the standard dressing group and  $34.2 \pm 11.1$  years in the ciNPT group ( $P = 0.65$ ). Mean body mass index values were  $28.5 \pm 3.5 \text{ kg/m}^2$  in the standard dressing group and  $27.4 \pm 3.4 \text{ kg/m}^2$  in the ciNPT group ( $P = 0.07$ ). Some overweight or obese patients were included, with BMIs ranging from 20.6 to 36.2 and 20.5 to 32.3  $\text{kg/m}^2$ , respectively. None of the patients were active smokers. There were slightly more "former smokers" in the ciNPT group (14%) than in the standard dressing group (8%), but this was not significant ( $p = 0.36$ ).

Resected breast tissue weighed a mean of 565 g in the standard group and 610 g in the ciNPT group. The largest

resection weights were 2020 and 1250 g, respectively. Use of the superomedial pedicle was our technique of choice in both groups (75% and 85%,  $P = 0.19$ ). We uniformly used surgical drains for average length of  $8 \pm 3$  days in both groups ( $P = 0.83$ ). Surgery trainees were also involved in most cases (83% versus 77%,  $P = 0.50$ ). The average ciNPT treatment period was 5.7 days and the median was 6 days.

### Outcomes

Clinically meaningful dehiscence requiring wound care was significantly higher in the standard dressing group than in the ciNPT group: 14.0% versus 2.2%,  $P = 0.003$  (Fig. 1).

Ten (8.8%) of 114 breasts in the standard dressing group had minor wound findings that were self-limiting and did not require specific care (Table 2). Dehiscence was observed in 16 (14.0%) breasts. This was typically treated with twice-daily saline wet-to-dry wound dressing care and occasionally included use of topical collagenase (Collagenase Santyl Ointment; Smith & Nephew, Inc., Watford, England, UK). Two patients required sharp postoperative debridement. Five breasts exhibited partial nipple-areolar complex (NAC) necrosis, 5 had superficial surgical site infection, 2 had seroma, and 1 had hematoma. Two patients presented to the emergency department, and 2 required readmission to the hospital for breast imaging and intravenous antibiotic treatment of cellulitis. None experienced deep infection or total NAC loss. All were eventually healed by secondary intention. One patient returned to the operating room within 1 year for revision surgery. One case of incidental malignancy, focal ductal carcinoma in situ, was found on pathology examination and subsequently treated.

In contrast, dehiscence only occurred in 1 (2.2%) breast out of 44 in the ciNPT group. This was significantly lower than that in the standard dressing group ( $P = 0.003$ ). Seven breasts (15.9%) had minor findings, including superficial epidermolysis of less than 3 mm ( $n = 2$ ), self-limiting blisters ( $n = 2$ ), and contact dermatitis ( $n = 3$ ), which were not considered dehiscence. This was not statistically different than the standard dressing group ( $P = 0.25$ ).

Two patients dressed with ciNPT presented to the emergency department, but did not require readmission to the hospital, early reoperation, or debridement. Two breasts developed partial NAC necrosis, 1 had superficial

**Table 1. Patient and Technique Characteristics**

Demographics	Standard Dressing, n = 114	ciNPT, n = 44	P
Patient age (y), mean $\pm$ SD	35.1 $\pm$ 12.0	34.2 $\pm$ 11.0	0.652*
Body mass index ( $\text{kg/m}^2$ ), mean $\pm$ SD	28.5 $\pm$ 3.5	27.4 $\pm$ 3.4	0.065*
Body mass index ( $\text{kg/m}^2$ ), range	20.6–36.2	20.5–32.3	
Active smokers/tobacco users, n	0 (0%)	0 (0%)	
Former smokers/tobacco users, n	9 (7.9%)	6 (13.6%)	0.363†
Tissue resection weight (g), mean	565	610	0.466*
Max tissue resection weight (g)	2020	1250	
Superomedial pedicle used (%)	75%	85%	0.194†
Average drain length (d), mean $\pm$ SD	8.2 $\pm$ 3.1	8.3 $\pm$ 2.9	0.826*
Surgical resident involvement, n (%)	94 (82.5%)	34 (77%)	0.499†

\*Fisher exact test.

†T-test.

**DISCUSSION**

Symptomatic macromastia is a common complaint among both the general and military patient populations.<sup>20</sup> There is some referral bias in our practice, as active duty US service members, retirees, and family members tend to be relatively healthy and compliant with therapy. Under these circumstances, our historical dehiscence rate of 14% using standard dressings was somewhat lower than published averages, but in our opinion still frustratingly high despite employing careful technique and best practices.<sup>21-23</sup> The fact that the dehiscence rate dropped significantly to 2% during the study period has stirred great enthusiasm in our practice for ciNPT.

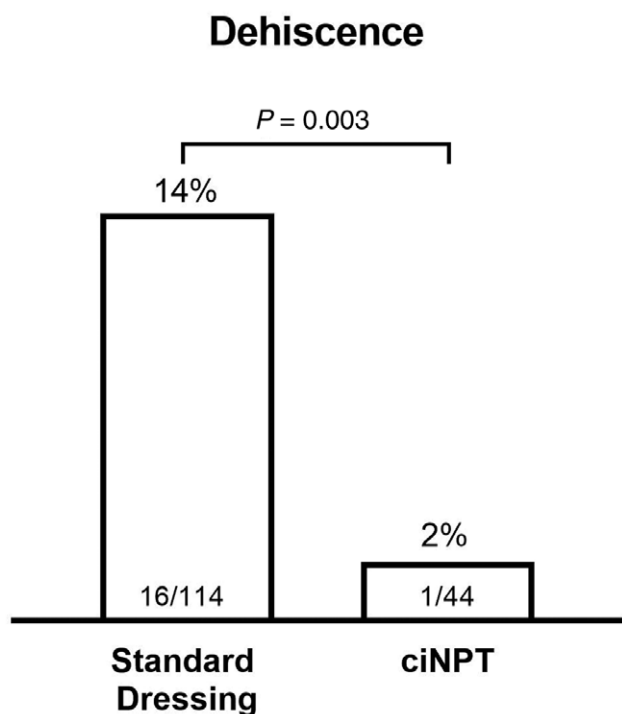
Patients in the traditional dressing group who experienced wound complications had delayed healing, sometimes up to several weeks. Most were inconvenienced by frequent returns to the office. Two patients required hospital readmission, and 2 needed sharp debridement of the necrotic tissue.

Meanwhile, we noted that none of the patients in the ciNPT group needed debridement. Two patients presented to the emergency room for minor device-related malfunctions after-hours, but these were resolved quickly without readmission. There were no device failures. The 1 breast dehiscence in 1 ciNPT patient was minor and easily resolved with a short course of standard dressing care.

Though there seemed to be fewer infections and overall complications in the ciNPT group, we did not observe these to be statistically significant, possibly a type 2 error related to our study being underpowered.

The use of historical controls allowed us to control other variables as much as possible, isolating the use of ciNPT as the only different intervention. Two independent surgeons at the same institution saw a consistent patient population, used consistent patient selection criteria, and employed the same perioperative management strategies throughout the time periods being compared. Wound-related complications after breast reduction were reduced by 84% with 1 intervention, everything else being similar.

We believe the mechanisms for the improved wound complication outcomes we observe are multifactorial. First, ciNPT dressings are applied in an operating room under sterile conditions, where they protect the suture



**Fig. 1.** Use of ciNPT significantly reduced early postoperative wound dehiscence in otherwise similar breast reduction patients.

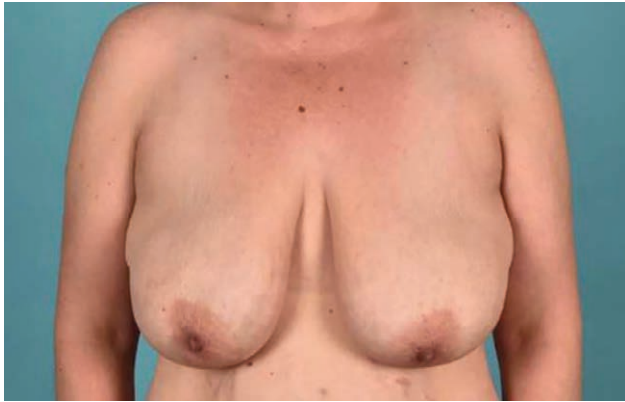surgical site infection, and 2 experienced seromas. There were no deep infections, hematomas, or total NAC losses. Two patients were placed on antibiotics by an emergency department provider, but were not found to have infection when evaluated in our clinic.

Overall complications were slightly lower in the ciNPT group at 29.5% (13 of 44), compared to the standard group at 38.6% (44 of 114), but this was not found to be significant ( $P = 0.30$ ). All ciNPT patients were satisfied with their early care and outcomes. One ciNPT patient with Fitzpatrick type 5 skin sought revision a year later for hypertrophic scarring but remained satisfied with the reduction results. Two representative examples of patients in the ciNPT group were a 33-year old patient with approximately 400g of tissue resected per side (Figs. 2-6) and a 32-year old patient with about 700g removed per side (Figs. 7-11); both followed up at 6 weeks without complication.

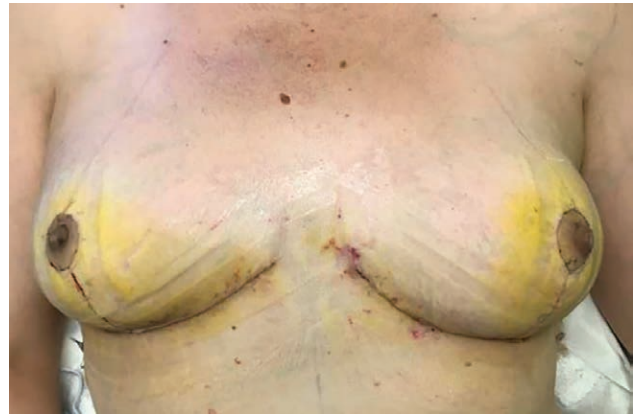**Table 2. Incidence and Comparisons of Postoperative Complications after Breast Reduction Using either Standard Dressings or ciNPT on Closed Wise Pattern Skin Incisions**

Outcomes	Standard Dressing, n = 114	ciNPT, n = 44	P
Dehiscence requiring wound care	16 (14.0%)	1 (2.2%)	0.003
Minor wound finding, no care needed	10 (8.8%)	7 (15.9%)	0.251
Postoperative debridement	2 (1.8%)	0 (0%)	1.000
Partial necrosis of NAC	5 (4.4%)	2 (4.5%)	1.000
Total loss of NAC	0 (0%)	0 (0%)	1.000
Superficial surgical site infection	5 (4.4%)	1 (2.3%)	1.000
Deep surgical site infection	0 (0%)	0 (0%)	1.000
Seroma	2 (1.8%)	2 (4.5%)	0.310
Hematoma	1 (0.9%)	0 (0%)	1.000
Visits to emergency department	2/57 patients (3.5%)	2/22 patients (0.9%)	0.309
Readmission	1/57 patients (1.8%)	0/22 patients (0%)	1.000
Any complication	44 (38.6%)	15 (34.1%)	0.714

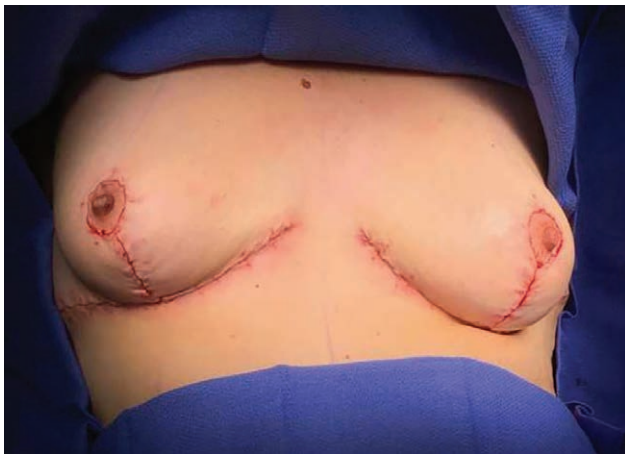All statistics performed using the Fisher exact test.



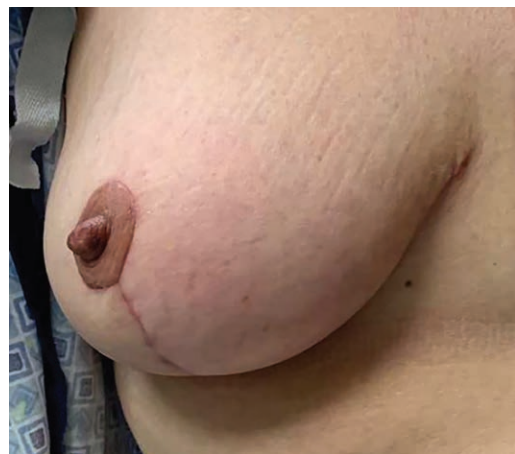**Fig. 2.** Preoperative image of 33-year-old patient seeking functional primary reduction mammoplasty.



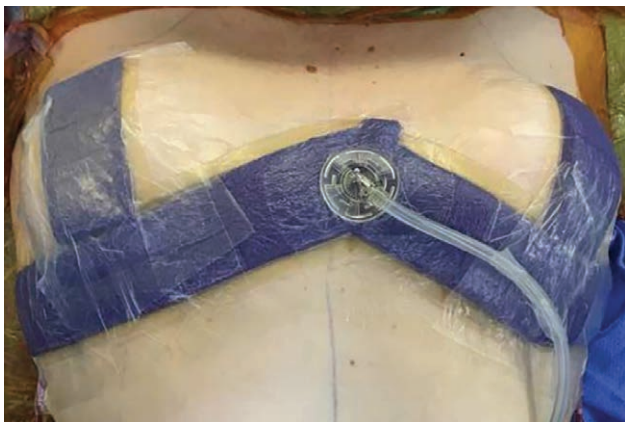**Fig. 5.** Appearance on postoperative day 6, immediately after removal of ciNPT and drains in the office.



**Fig. 3.** On-table result after skin closure of Wise pattern incisions. Superomedial pedicles were used. Resection specimens weighed about 400 g per side.



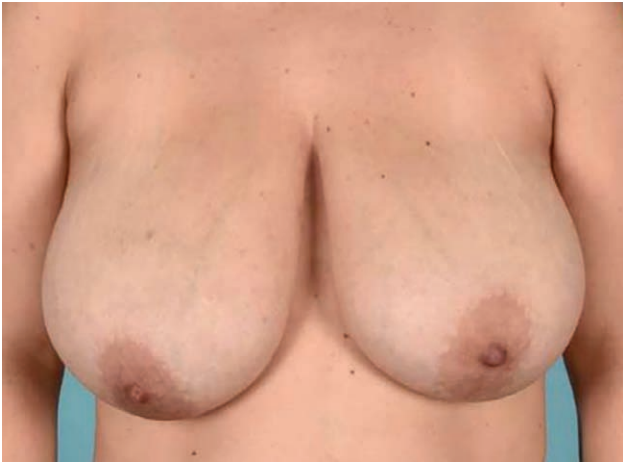**Fig. 6.** Close-up appearance of right breast 6 weeks after surgery. The incisions have healed and the patient did not experience wound dehiscence or other complication.



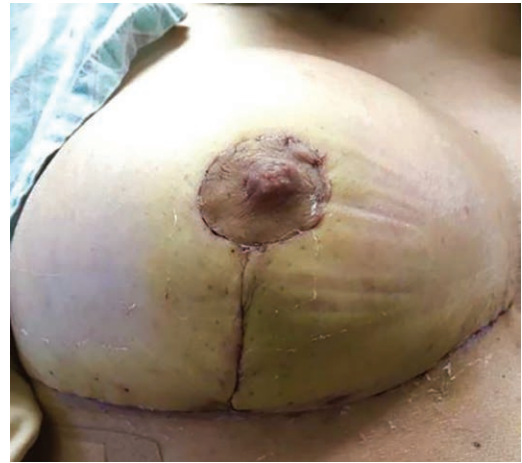
**Fig. 4.** Application of ciNPT, covering closed Wise pattern skin incisions. One device sufficiently covered all incisions. Note that good seal and activation of  $-125$  mm Hg of pressure results in flattening of foam. Barrier material isolates ciNPT from surgical drains, which exit through stab incisions laterally and inferiorly.

line for up to 7 days postoperatively. The dressing acts as a mechanical barrier that maintains a clean and protected wound healing environment for a longer duration than standard dressing, eliminating need for dressing changes at regular intervals, and fewer opportunities for contamination or disruption after the patient is sent home to recover. A long-established in vitro study demonstrated that bacteria are capable of passing through many layers of dry gauze.<sup>24</sup> Previous authors have pointed out that ciNPT foam dressing is also impregnated with 0.019% ionic silver,<sup>25</sup> which may help impede bacterial proliferation in the dressing.

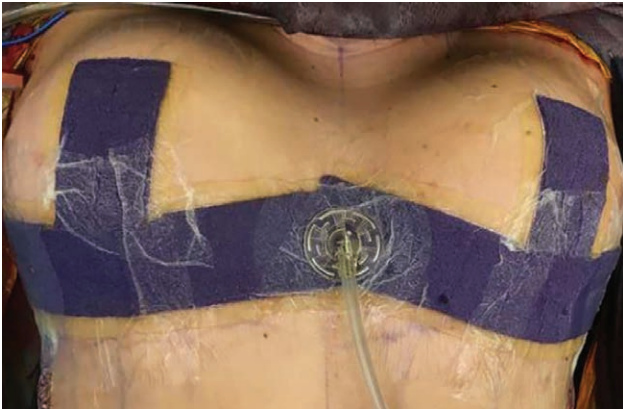
Second, negative pressure exerts appositional force across closed incisions, decreases distraction tension across the surgical wound, and increases the force necessary to separate the wound by 50%.<sup>2</sup> It removes exudate that might otherwise disrupt the wound or serve as nidus for infection. Studies in other surgical disciplines have observed reduced rates of infection and dehiscence.<sup>13,26</sup>



**Fig. 7.** Preoperative image of 32-year-old patient seeking functional primary reduction mammoplasty.



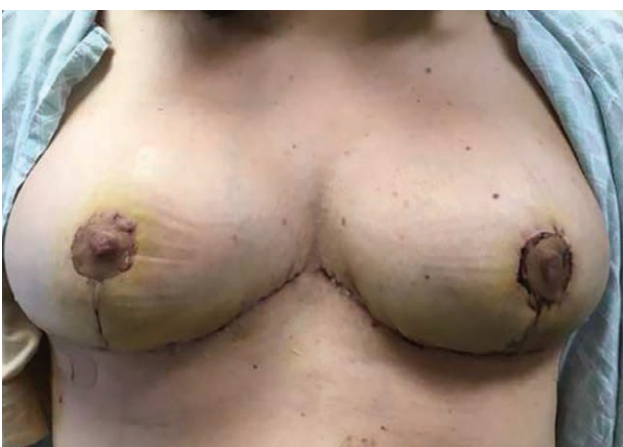**Fig. 10.** Close-up image of right breast incisions immediately after removal of ciNPT and drains, on postoperative day 6. There is no NAC necrosis or dehiscence.



**Fig. 8.** On-table appearance after skin closure of Wise pattern incisions and application of ciNPT. In this case, bilateral inferior pedicles were used and resection specimens weighed about 700g per side.



**Fig. 11.** Close-up appearance of right breast 6 weeks after surgery. The incisions have healed, and the patient did not experience wound dehiscence or other complication.



**Fig. 9.** Appearance on postoperative day 6, immediately after removal of ciNPT and drains in the office.

Third, ciNPT has been observed clinically to reduce wound edema and underlying seroma<sup>27</sup> through an undefined mechanism. In most cases, there is very little or no fluid observed in the collection chambers, so the device is not physically removing large amounts of the edema fluid. We speculate that negative pressure opens lymphatic channels and encourages lymphatic circulation in a beneficial way, but this remains unclear. We did not observe a difference in our seroma rates in this study. Our use and duration of drains were mostly a practical matter, determined by the ability to schedule a follow-up appointment with the patient. We did not specifically examine daily output volumes to determine whether they could have been removed faster with the use of ciNPT.

Since terminating our collection of data, we have changed our practice to use ciNPT for all breast reductions, as well as other high-risk but clean breast incisions. Encouragingly, other authors have recently been reporting benefits such as lower rates of hematoma, seroma,

infection, dehiscence, local wound complications, and even improved “appearance” in a variety of breast and other aesthetic surgery applications.<sup>19</sup> In fact, an international group using a ciNPT device with different designs and technologies, also used in reduction mammoplasty, recently published similar albeit with less impressive results.<sup>28</sup> Using 1 device per patient on 1 breast, with standard dressings on the other (internal controls), they reported a decrease in wound dehiscence from 26% to 16%, an absolute risk reduction of 10% and relative reduction of 38% ( $P < 0.001$ ).

As with any new treatment strategy, added costs must be weighed against potential benefits. In a cosmetic setting, these costs would likely be passed on to the patient. Insurance payors may not reimburse entirely. A thorough analysis of the direct and indirect costs of wound care, delayed return to work, extra clinic visits, emergency department visits, surgical revision rates, and claims filed from dissatisfied patients could characterize cost effectiveness.

There are several future questions we are eager to ask, given our results. In this study, we chose to place ciNPT dressings over the incisions, particularly focused on covering the triple-points. For future investigation, we are interested in whether alternative application techniques of ciNPT may prove to be beneficial. If negative pressure improves lymphatic circulation, would application of a larger dressing over the entire breast area be of additional benefit? With a larger sample size, could we demonstrate lower rates of seroma or hematoma? Could we reduce the dwell time of surgical drains? Though none of our patients experienced total NAC necrosis, it would also be interesting to study whether ciNPT significantly reduced this on a large scale by improving perfusion and/or reducing incisional tension.

Only 1 patient in the ciNPT group developed an infection, compared to 5 in the standard dressing group. We are interested to see if ciNPT could significantly and effectively reduce the rates of infection or antibiotic use. Anecdotally, we found our ciNPT patients were satisfied with the devices at home, but a more detailed patient questionnaire study might be valuable to assess acceptance on a large scale. Patients were certainly happy to heal without early wound difficulties. It remains unclear whether ciNPT translates into improved other late outcomes or long-term scarring.

## CONCLUSIONS

In this single-institution, multisurgeon retrospective review, the shift from traditional standard dressings to the application of ciNPT placed over Wise pattern skin incisions significantly decreased clinically meaningful early wound dehiscence in otherwise similar risk-stratified breast reduction patients. The overall dehiscence rate in the standard dressing group was 14%, consistent with the low end of ranges previously published by other authors examining reduction mammoplasty. By using ciNPT dressings, with otherwise consistent surgical technique and perioperative management,

our dehiscence rate dropped to 2%, an absolute risk reduction of 12%, and a relative risk reduction of 84%.

Owen N. Johnson III, MD, FACS  
3824 Cedar Springs Rd STE #801-14364  
Dallas, TX 75219  
E-mail: owenjohnson3@hotmail.com

## ACKNOWLEDGMENT

The authors would like to thank Irma Enriquez and Connie Humphress-Tullius for taking excellent care of each of the patients in this study.

## REFERENCES

- Gomoll AH, Lin A, Harris MB. Incisional vacuum-assisted closure therapy. *J Orthop Trauma*. 2006;20:705–709.
- Wilkes RP, Kilpad DV, Zhao Y, et al. Closed incision management with negative pressure wound therapy (CIM): biomechanics. *Surg Innov*. 2012;19:67–75.
- Stannard JP, Volgas DA, McGwin G III, et al. Incisional negative pressure wound therapy after high-risk lower extremity fractures. *J Orthop Trauma*. 2012;26:37–42.
- Reddix RN Jr, Leng XI, Woodall J, et al. The effect of incisional negative pressure therapy on wound complications after acetabular fracture surgery. *J Surg Orthop Adv*. 2010;19:91–97.
- Brem MH, Bail HJ, Biber R. Value of incisional negative pressure wound therapy in orthopaedic surgery. *Int Wound J*. 2014;(11 suppl 1):3–5.
- Karlakki S, Brem M, Giannini S, et al. Negative pressure wound therapy for management of the surgical incision in orthopaedic surgery: a review of evidence and mechanisms for an emerging indication. *Bone Joint Res*. 2013;2:276–284.
- Colli A, Camara ML. First experience with a new negative pressure incision management system on surgical incisions after cardiac surgery in high risk patients. *J Cardiothorac Surg*. 2011;6:160.
- Dohmen PM, Markou T, Ingemansson R, et al. Use of incisional negative pressure wound therapy on closed median sternal incisions after cardiothoracic surgery: clinical evidence and consensus recommendations. *Med Sci Monit*. 2014;20:1814–1825.
- Atkins BZ, Wooten MK, Kistler J, et al. Does negative pressure wound therapy have a role in preventing poststernotomy wound complications? *Surg Innov*. 2009;16:140–146.
- Chadi SA, Kidane B, Britto K, et al. Incisional negative pressure wound therapy decreases the frequency of postoperative perineal surgical site infections: a cohort study. *Dis Colon Rectum*. 2014;57:999–1006.
- Leiboff AR. Vertically drained closed incision NPWT. A novel method for managing surgical incisions: a case series. *J Wound Care*. 2014;23:623–629.
- Maclin M, Guerra O. Superficial and deep control with use of negative pressure wound therapy for complex closures over incision line after combined fleur-de-lis panniculectomy and ventral hernia repair. *Negative Pressure Wound Therapy*. 2014;1:86–91.
- Condé-Green A, Chung TL, Holton LH III, et al. Incisional negative-pressure wound therapy versus conventional dressings following abdominal wall reconstruction: a comparative study. *Ann Plast Surg*. 2013;71:394–397.
- Vargo D. Negative pressure wound therapy in the prevention of wound infection in high risk abdominal wound closures. *Am J Surg*. 2012;204:1021–1023; discussion 1023.
- Matatov T, Reddy KN, Doucet LD, et al. Experience with a new negative pressure incision management system in prevention of groin wound infection in vascular surgery patients. *J Vasc Surg*. 2013;57:791–795.

16. Haghshenasskashani A, Varcoe RL. A new negative pressure dressing (Prevena) to prevent wound complications following lower limb distal arterial bypass. *Br J Diabetes Vasc Dis.* 2011;11:21–24.
17. Kim DY, Park SJ, Bang SI, et al. Does the use of incisional Negative-Pressure wound therapy prevent mastectomy flap necrosis in immediate expander-based breast reconstruction? *Plast Reconstr Surg.* 2016;138:558–566.
18. Schlosser KA, Otero J, Lincourt A, et al. Management of surgical incisions using incisional negative-pressure therapy. *Plast Reconstr Surg.* 2019;143:15S–20S.
19. Singh D, Lobach V, Holton T. Use of closed-incision negative-pressure therapy in aesthetic surgery. *Plast Reconstr Surg.* 2019;143:11S–14S.
20. American Society of Plastic Surgeons. *2018 National Plastic Surgery Statistics report.* 2019.
21. Cunningham BL, Gear AJ, Kerrigan CL, et al. Analysis of breast reduction complications derived from the BRAVO study. *Plast Reconstr Surg.* 2005;115:1597–1604.
22. Henry SL, Crawford JL, Puckett CL. Risk factors and complications in reduction mammoplasty: novel associations and preoperative assessment. *Plast Reconstr Surg.* 2009;124:1040–1046.
23. Chopra K, Tadisina KK, Conde-Green A, et al. The expanded inframammary fold triangle: improved results in large volume breast reductions. *Indian J Plast Surg.* 2014;47:65–69.
24. Owens N. Use of pressure dressings in treatment of burns and other wounds. *S Clin North Am.* 1943;23:1354–1366.
25. Lo Torto F, Monfrecola A, Kaciulyte J, et al. Preliminary result with incisional negative pressure wound therapy and pectoralis major muscle flap for median sternotomy wound infection in a high-risk patient population. *Int Wound J.* 2017;14:1335–1339.
26. Willy C, Agarwal A, Andersen CA, et al. Closed incision negative pressure therapy: international multidisciplinary consensus recommendations. *Int Wound J.* 2017;14:385–398.
27. Kilpadi DV, Cunningham MR. Evaluation of closed incision management with negative pressure wound therapy (CIM): hematoma/seroma and involvement of the lymphatic system. *Wound Repair Regen.* 2011;19:588–596.
28. Galiano RD, Hudson D, Shin J, et al. Incisional negative pressure wound therapy for prevention of wound healing complications following reduction mammoplasty. *Plast Reconstr Surg Glob Open.* 2018;6:e1560.