

Acromioclavicular Joint Injuries in Professional Ice Hockey Players

Epidemiologic and MRI Findings and Association With Return to Play

Lawrence M. White,^{*†‡} MD, Jonathan Ehmann,^{†‡} MD, Robert R. Bleakney,^{†‡} MD, Anthony M. Griffin,[§] PhD, and John Theodoropoulos,^{§||} MD

Investigation performed at Mount Sinai Hospital, Sinai Health System, University of Toronto, Toronto, Ontario, Canada

Background: Acromioclavicular joint (ACJ) injuries are common in ice hockey players and are traditionally evaluated with conventional radiography, which has recognized limitations in the accurate characterization of the spectrum of soft tissue injuries and severity/grade of injury sustained.

Purpose: To evaluate the epidemiologic, clinical, and magnetic resonance imaging (MRI) findings in professional ice hockey players who have sustained acute ACJ injuries.

Study Design: Case series; Level of evidence, 4.

Methods: A retrospective review was performed of professional National Hockey League (NHL) players referred for MRI evaluation of acute ACJ injuries. All MRI scans were assessed for status of the ACJ, ligamentous stabilizers, and surrounding musculature. MRI-based overall grade of ACJ injury (modified Rockwood grade 1-6) was assigned to each case. Data regarding mechanism of injury, player handedness, clinical features, and return to play were evaluated.

Results: Overall, 24 MRI examinations of acute ACJ injuries (23 patients; mean age, 24 years) were reviewed. We found that 50% of injuries were sustained during the first period of play, and in 75% of cases, injuries involved the same side as player shooting handedness. Analysis of MRI scans revealed 29% (7/24) grade 1 ACJ injuries, 46% (11/24) grade 2 injuries, 21% (5/24) grade 3 injuries, and 4% (1/24) grade 5 injuries. Trapezius muscle strains were seen in 79% and deltoid muscle strain in 50% of cases. Nonoperative management was used for 23 injuries; 1 patient (grade 5 injury) underwent acute reconstructive surgery. All players successfully returned to professional NHL competition. Excluding cases with additional injuries or surgery ($n = 3$) or convalescence extending into the offseason ($n = 3$), we found that the mean return to play was 21.4 days (7.2 games missed). No statistically significant difference was observed in return to play between nonoperatively treated grade 3 injuries (mean, 28.3 days) and grade 1 or 2 injuries (mean, 20.1 days). However, grade 3 injuries were associated with a greater number of NHL scheduled games missed (mean, 12.7) compared with lower grade injuries (mean, 6.1) ($P = .027$).

Conclusion: The spectrum of pathology and grading of acute ACJ injuries sustained in professional ice hockey can be accurately assessed with MRI; the majority of injuries observed in this study were low grade (grades 1 and 2). Although grade 3 injuries were associated with a greater number of games missed, similar return-to-play results were observed between nonoperatively treated grade 3 and grade 1 or 2 ACJ injuries.

Keywords: acromioclavicular joint; ice hockey; acute injury; MRI

Acromioclavicular joint (ACJ) injuries are common among elite ice hockey players and account for a substantial amount of time away from sport.^{9,11,13,15,17,19} Traditionally, ACJ injuries have been evaluated with conventional

radiographs.^{8,23} Despite trends to use nonoperative methods to treat ACJ injuries without anteroposterior displacement patterns, conventional radiographic assessment alone may be limited in providing accurate and reliable characterization of soft tissue injuries and the severity and grade of injury sustained.^{16,24,27}

Magnetic resonance imaging (MRI) has been shown to be accurate in the assessment of soft tissue and osseous

The Orthopaedic Journal of Sports Medicine, 8(11), 2325967120964474
DOI: 10.1177/2325967120964474
© The Author(s) 2020

This open-access article is published and distributed under the Creative Commons Attribution - NonCommercial - No Derivatives License (<https://creativecommons.org/licenses/by-nc-nd/4.0/>), which permits the noncommercial use, distribution, and reproduction of the article in any medium, provided the original author and source are credited. You may not alter, transform, or build upon this article without the permission of the Author(s). For article reuse guidelines, please visit SAGE's website at <http://www.sagepub.com/journals-permissions>.

pathology in the setting of acute ACJ injuries.^{1-3,16,20,26} The purpose of this study was to retrospectively review the spectrum of epidemiologic, clinical, and MRI findings in a consecutive series of National Hockey League (NHL) players referred for MRI examination after clinically suspected acute ACJ injuries as well as to correlate the MRI findings with time lines for return to play.

METHODS

Patient Selection

Institutional research ethics board approval with waived consent was obtained for this retrospective study. A list of all MRI shoulder examinations performed at our institution, referred by a single NHL team orthopaedic surgeon (J.T.) for assessment of acute ACJ injuries in professional ice hockey players between May 2006 and May 2019, was compiled and cross-referenced between a player-injury database and our institutional radiology information system.

Study patient inclusion criteria were NHL professional ice hockey players who had sustained clinically suspected ACJ injuries and underwent MRI examination of the shoulder performed acutely (0-20 days) after injury. Exclusion criteria included player history of prior ACJ surgery and history of grade 3 or higher ACJ injury.

Magnetic Resonance Imaging

All MRI examinations were performed using a standardized institutional protocol for shoulder imaging on a 1.5-T (Aera; Siemens AG) or 3.0-T superconducting (Skyra; Siemens AG) system using dedicated multichannel shoulder array coils (Siemens AG); patients were imaged in the standard supine position. In all cases, imaging included coronal oblique fast spin-echo (FSE) intermediate-weighted and FSE fat-suppressed T2-weighted acquisitions, sagittal oblique FSE fat-suppressed T2-weighted imaging, and axial FSE intermediate-weighted acquisitions. Imaging slice thickness was 3 mm, with no interslice gap. In all examinations, the entirety of the ACJ and its surrounding stabilizing soft tissues were included within the imaging field of view.

MRI Review

All MRI studies were retrospectively reviewed in consensus by 2 fellowship-trained musculoskeletal radiologists (L.M.W. and R.R.B.) with 25 and 18 years of experience,

respectively, and a musculoskeletal imaging fellow (J.E.) with 1 year of dedicated training. The readers were blinded to patient characteristics, clinical assessment results, and return-to-play data. All MRI scans were reviewed and quantitative measurements performed using a dedicated picture archiving and communication system image review workstation (Coral; University Health Network). Each MRI scan was assessed for possible injury and anatomic location of injuries involving the superior and inferior acromioclavicular (AC) ligaments of the ACJ capsule, coracoclavicular (CC) ligaments, and trapezius and deltoid muscles, using all imaging planes and sequences available.

The superior and inferior AC ligaments of the ACJ capsule were individually assessed as normal (intact, uniform, thin, low-signal ligament), partially torn (thickened, increased intrasubstance T2-weighted signal, incomplete ligament disruption), or completely torn (complete ligament disruption with fluid signal continuity between ACJ and juxta-articular soft tissues). In cases of superior or inferior AC ligament tears, an assessment was made to define the location of tearing as involving the acromial attachment, midsubstance, or clavicular attachment of the respective AC ligament. Superior or inferior displacement of the clavicle across the ACJ was measured on coronal oblique images as the distance between a line tangent to the inferior cortex of the anterior acromion and a second line parallel to the first placed tangent to the inferior cortical margin of the lateral clavicle, at the level of the ACJ. The ACJ width was measured as the shortest medial-lateral distance between the subarticular cortex of the acromion and clavicle at the ACJ on coronal oblique images. Anterior or posterior displacement of the clavicle across the ACJ was defined and measured based upon the anterior or posterior distance between lines drawn tangent to the anterior cortex of the acromion and anterior cortex of the clavicle at the level of the ACJ on axial imaging.

Trapezoid and conoid components of the CC ligamentous complex were individually graded as normal, partially torn, or completely torn on coronal and sagittal acquisitions. Normal CC ligaments were defined as illustrating uniform low-signal-intensity ligamentous fibers running in continuity from the inferior cortex of the clavicle to their respective insertions to the superior cortex of the coracoid process of the scapula. Partial CC ligament tearing was characterized by increased intraligamentous T2-weighted signal, with thickening or partial disruption of ligamentous fibers, and complete CC ligament tearing by complete disruption of ligament fiber continuity between the clavicle and coracoid. When present, conoid and trapezoid ligament tears were

*Address correspondence to Lawrence M. White, MD, Mount Sinai Hospital, 600 University Avenue, Room 562-A, Toronto, ON, Canada, M5G 1X5 (email: lawrence.white@uhn.ca).

[†]Department of Medical Imaging, University of Toronto, Toronto, Ontario, Canada.

[‡]Joint Department of Medical Imaging, Mount Sinai Hospital, Toronto, Ontario, Canada.

[§]Department of Orthopedic Surgery, Mount Sinai Hospital, Toronto, Ontario, Canada.

^{||}Orthopedic Sports Medicine, University of Toronto, Toronto, Ontario, Canada.

Final revision submitted May 26, 2020; accepted June 12, 2020.

The authors declared that there are no conflicts of interest in the authorship and publication of this contribution. AOSSM checks author disclosures against the Open Payments Database (OPD). AOSSM has not conducted an independent investigation on the OPD and disclaims any liability or responsibility relating thereto.

Ethical approval for this study was obtained from Mount Sinai Hospital (study No. 18-0323-C).

additionally anatomically defined as involving their clavicular ligamentous attachment, coracoid insertion, or mid-substance of the ligament. The CC distance was measured on coronal oblique imaging as the shortest superior-inferior distance between a line drawn tangent to the inferior cortex of the lateral clavicle at the CC ligament insertions and a second line parallel to the first placed tangent to the superior cortical margin of the coracoid process of the scapula.

Muscular active stabilizers of the lateral clavicle and acromion, composed of the trapezius insertions to the lateral clavicle and lateral scapular spine as well as deltoid muscular origins from the anterolateral clavicle and acromion, were each assessed for presence or absence of injury. When present, muscle injuries were graded from 1 to 3: grade 1 injuries were characterized by increased T2-weighted edema and hemorrhage extending along muscle fibers and fascicles with a classic feathery appearance, grade 2 injuries were characterized by partial disruption of muscle fibers with possible associated perifascial edema or intramuscular hematoma formation, and grade 3 injuries were characterized as complete disruption or avulsion of muscular osseous attachments with local hematoma formation.^{7,10}

All MRI scans were additionally evaluated for associated osseous fracture, manifested by a linear osseous fracture cleft and cortical disruption, or bone contusion characterized by marrow edema-like signal noted on T2-weighted fat-suppressed imaging within the clavicle, acromion, scapular spine, or coracoid process.

The Rockwood classification of ACJ injury²⁵ was adapted to integrate MRI findings and used to assign an overall grade of ACJ injury in each case.²⁰ Grade 1 injuries were defined on the basis of tearing (partial or complete) of the ACJ ligaments with no evidence of CC ligamentous injury, grade 2 injuries were defined in the setting of tearing (partial or complete) of ACJ ligaments with partial tearing of the CC ligaments, and grade 3 injuries were defined based on tearing of the ACJ ligaments and complete tearing of the CC ligaments. Injuries of grades 4 through 6 were classified based on the presence of clavicular displacement in the setting of tearing of both the AC capsular ligaments and CC ligaments, with grade 4 injuries illustrating posterior displacement of the clavicle relative to the acromion, grade 5 injuries defined by marked superior displacement of the clavicle with the CC interval widened by >100% based on MRI anatomic landmarks and distance measured between torn margins of the CC ligament, and grade 6 injuries defined by anterior and caudal displacement of the lateral clavicle inferior to the acromion or coracoid process of the scapula.

Clinical Data

Clinical data pertaining to each ACJ player injury were collected from clinical team medical records. Data collected in each study case included mechanism of injury, period of play during which the injury was sustained, time interval between injury and MRI examination, player characteristics, position played (eg, center, left or right wing,

defense, or goalie), side of injury, and hockey shooting handedness (side of hand held lower on the ice hockey stick during play). Patient-injury data additionally included documented findings at clinical physical examination, injury treatment (nonoperative or operative), games missed, and time interval (days) between injury and date of medical clearance for full return to play. We documented cases in which injury rehabilitation and return-to-play convalescence extended into the NHL off-season and players who underwent surgical intervention during convalescence for injury other than ACJ.

Statistical analysis was performed using SPSS Statistics for Windows software, Version 19.0 (IBM). Binomial (2-tailed) analysis was used to assess the association between side of ACJ injury and player hockey-shooting handedness. Chi-square analysis was used to compare observed versus expected distribution of injury by player position as well as by periods of game play. Moreover, chi-square analysis was used to assess the association between presence or absence of muscle injury with increasing grade of ACJ injury. One-way analysis of variance was used to assess for differences between ACJ injury grades and measures of return to play (calendar days missed, games missed). Differences were considered statistically significant at $P < .05$. Not all possible data analyses were performed due to the small sample sizes involved.

RESULTS

After the study-inclusion criteria were applied, the study group consisted of 24 shoulder MRI examinations performed on 23 players. In the 1 patient who had 2 injuries and separate MRI examinations, MRI was performed to assess distinct acute injuries of the left and right ACJs that occurred 8 months apart. The mean player age at time of ACJ injury was 24 years (range, 19-32 years).

Regarding mechanism of ACJ injury, 13 injuries were the result of direct impact of the shoulder with the boards or playing surface ice, 8 injuries occurred as a result of receiving a body check, and 2 injuries were sustained while delivering a body check; for 1 injury, the mechanism was not specified in the clinical notes. Of the 24 ACJ injuries reviewed, most were sustained during the first period of game play ($P = .016$): 12 injuries (50%) were sustained during the first period, 5 injuries (21%) during the second period, and 2 injuries (8%) during the third period. Furthermore, 2 of the ACJ injuries were sustained during game play without specification of period, and 3 ACJ injuries occurred during full-contact practice.

The incidence and distribution of ACJ injuries by player position included 11 defense, 5 center, 2 left-winger, and 6 right-winger. A total of 14 of the 24 injuries (58%) were left-side injuries, and 10 (42%) were right-side injuries. In 18 cases (75%), ACJ injuries involved the same side as player shooting handedness, and in 6 cases (25%) ACJ injury involved the contralateral side relative to player shooting handedness (differences statistically significant, $P = .023$).

TABLE 1
MRI Findings and Return to Play for NHL Players With Acute ACJ Injury^a

	Rockwood Grade					
	Grade 1 (n = 7)	Grade 2 (n = 11)	Grade 3 (n = 5)	Grade 4 (n = 0)	Grade 5 (n = 1)	Grade 6 (n = 0)
Acromioclavicular ligaments						
Superior						
Tears (partial; complete), n	7 (5; 2)	11 (1; 10)	5 (1; 4)	—	1 (complete)	—
Tear location, n	5 Clav, 2 Acrom	10 Clav, 1 Acrom	3 Clav, 2 Acrom	—	1 Clav	—
Inferior						
Tears (partial; complete), n	7 (5; 2)	11 (3; 8)	5 (all complete)	—	1 (complete)	—
Tear location, n	7 Clav	8 Clav, 3 Acrom	5 Clav	—	1 Clav	—
ACJ width, mm, mean (range)	2.3 (2-4)	3.0 (1-5)	5 (2-10)	—	8 (—)	—
Clavicular offset, mm, mean (range)	1.7 (0-6)	2.1 (0-5)	8.4 (3-13)	—	16 (—)	—
Coracoclavicular ligaments						
Trapezoid						
Tears (partial; complete), n	0	11 (9; 2)	5 (all complete)	—	1 (complete)	—
Tear location, n	—	4 Clav, 7 Mid	5 Mid	—	1 Mid	—
Conoid						
Tears (partial; complete), n	0	6 (all partial)	5 (all complete)	—	1 (complete)	—
Tear location, n	—	2 Clav, 3 Mid, 1 Cor	5 Mid	—	1 Mid	—
Coracoclavicular distance, mm, mean (range)	8.1 (5-11)	9.9 (6-12)	13.8 (8-18)	—	28 (—)	—
Muscle injury, no. of cases (grade)						
Trapezius						
	3 (grade 1)	11 (4 cases grade 1; 7 cases grade 2)	4 (grade 1)	—	1 (grade 1)	—
Deltoid						
	3 (grade 1)	4 (2 cases grade 1; 2 cases grade 2)	4 (grade 1)	—	1 (grade 1)	—
Days missed, mean (range)	26.1 (7-54)	44.4 (9-285)	53.0 (26-100)	—	118 (—)	—
Games missed, mean (range)	4.7 (0-14)	10.2 (0-40)	8.0 (0-16)	—	49 (—)	—

^aACJ, acromioclavicular joint; Acrom, acromial attachment; Clav, clavicular attachment; Cor, coracoid attachment; Mid, midportion. Dashes indicate not applicable.

Findings upon clinical examination performed acutely after injury included pain and tenderness to palpation over the ACJ in all 24 cases. Results of specific physical testing maneuvers included positive cross-body/horizontal adduction test in 17 of 18 cases and a positive O'Brien (active compression) test in 9 of 10 cases in which such assessment was documented in clinical notes.

MRI findings from the study cohort are summarized in Table 1. The mean duration of time between ACJ injury and MRI was 4 days (range, 0-19 days). MRI examination revealed grade 1 injuries (Figure 1) in 7 cases (29%), grade 2 injuries (Figure 2) in 11 cases (46%), and grade 3 injuries (Figure 3) in 5 cases (21%). One case (4%) demonstrated features of a grade 5 ACJ injury, whereas no cases showed findings of grade 4 or grade 6 injury.

MRI findings of superior and inferior AC ligament injury were seen in all cases (24/24). Tearing of the superior AC ligament was seen from its clavicular insertion in 19 cases (79%) and acromial insertion in 5 cases. Tearing of the inferior AC ligament was seen at its clavicular insertion in 21 (88%) cases and acromial insertion in 3 cases (Figure 4A).

Among cases with CC ligament injury (n = 17), tearing of the trapezoid ligament was seen at its clavicular insertion in 4 cases (24%) and "midaspect" of the ligament in 13 cases (76%). Tearing of the conoid ligament (n = 12) was seen at

its clavicular insertion in 2 cases (17%), midaspect of the ligament in 9 cases (75%), and coracoid attachment in 1 case (8%) case (Figure 4B).

Across the study cohort, 19 cases (79%) showed MRI features of trapezius muscle injury (12 cases of grade 1 injury; 7 cases of grade 2 injury) involving the trapezius insertion to the lateral clavicle (18/19) and lateral scapular spine (9/19). MRI findings of deltoid muscle injury were seen in 12 cases (50%) (10 cases of grade 1 injury; 2 cases of grade 2 injury) involving the deltoid origin from the anterolateral clavicle (11/12) and acromion (2/12). Only 3 cases (12%), all of which were grade 1 ACJ injuries, showed no evidence of a muscle tear. A statistically significant association was observed between presence of a muscle tear and increasing grade of ACJ injury ($P = .04$).

No fracture was detected in any case. In 8 cases (33%), bone marrow edema-like signal consistent with bone contusion was observed involving the lateral acromion (4/8), posterior scapular spine (1/8), and lateral clavicle (3/8). In total, 4 of these contusion injuries were seen in cases with grade 1 ACJ injury, and the other 4 instances of bone contusion were associated with grade 2 ACJ injuries.

All grade 1, grade 2, and grade 3 ACJ injuries (n = 23) were treated with nonoperative management, including pain control and immediate postinjury support with a

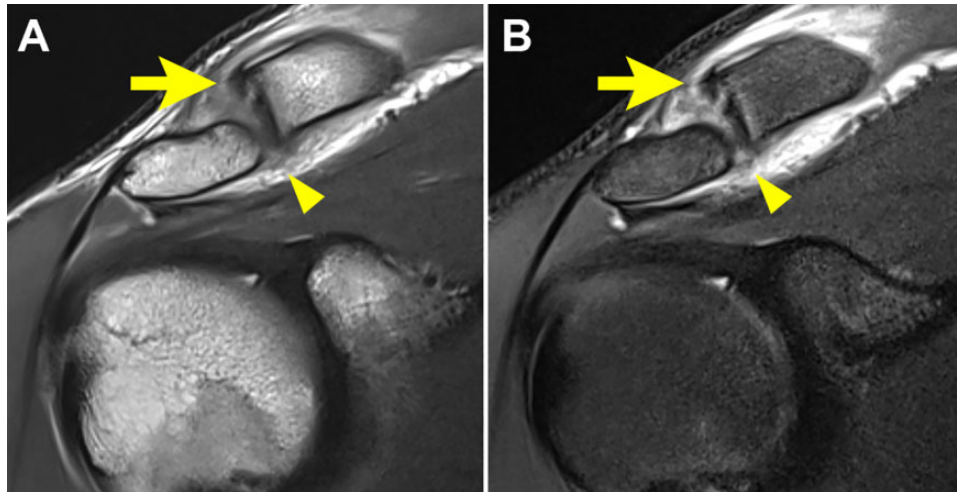


Figure 1. Grade 1 acromioclavicular injury. Coronal (A) intermediate and (B) T2-weighted fat-suppressed magnetic resonance imaging scans show complete disruption of the superior (arrows) and inferior (arrowheads) acromioclavicular ligaments.

shoulder sling, followed by early mobilization and progressive resistance exercises followed by strength and physical reconditioning. We noted that 2 cases (1 case of grade 1 ACJ injury, and 1 case of grade 2 ACJ injury) sustained glenohumeral dislocations at the time of ACJ injury requiring subsequent delayed labrocapsular reparative surgery. The single case with grade 5 ACJ injury was managed operatively with anatomic CC reconstruction surgery performed 4 days after injury.

All patients were evaluated by a team medical orthopaedic surgical consultant (J.T.) for medical approval and clearance before return to full-contact play. The date of return to play was determined based on the date of documented team physician sign-off for approval to play in official NHL game conditions. Criteria for return-to-play approval included objective measures of manual strength with a handheld dynamometer and Y-balance testing compared with preinjury baseline testing, functional assessments of push-up and resisted push-pull testing, and ability during practice to receive contact, battle with stick, and shoot confidently. Manual strength measures were made relative to baseline (preseason) measures of the same extremity, with goals of 90% return to baseline before clearance to return to play. All players successfully returned to professional NHL competition after ACJ injury. The overall median time interval between injury and return to play was 26.5 calendar days (range, 7-285 days), with players missing a median of 8 games (range, 0-49 games) from the NHL season schedule. Excluding 2 patients who underwent surgery (glenohumeral stabilization during ACJ rehabilitation period), the surgically treated grade 5 injury, and 3 additional cases in which injury convalescence extended into the NHL off-season, the mean duration of time between injury and return to regular game play was 21.4 calendar days (range, 7-32 days), with players missing an average of 7.2 games (range, 0-16 games) from the official NHL season schedule. No statistically significant difference was seen in the mean duration of time between injury and return to

play between players with nonoperatively treated grade 3 injuries (mean, 28.3 days; range, 26-32 days) and those with grade 1 or 2 injuries (mean, 20.1 days; range, 7-31 days). However, players with grade 3 injuries missed a significantly greater number of games from the NHL schedule (mean, 12.7 games; range, 11-16 games) compared with players with lower grade injuries (mean, 6.1 games; range, 0-14 games) ($P = .027$).

DISCUSSION

ACJ injury is the most common upper extremity injury and the ACJ is the most commonly injured joint, after the knee, in elite male ice hockey players.^{13,17,19} ACJ injuries are usually classified clinically and radiographically by the Rockwood classification system, which entails 6 types of injuries. Accepted treatment of grade 1 and grade 2 ACJ injuries is nonoperative management, whereas higher grade injuries (grades 4-6) are treated with surgical repair or reconstruction.^{1,3,4,16,18,20,26,28} The physical nature of professional ice hockey play requires heightened awareness and consideration regarding surgical intervention and risks related to osseous stress risers and fractures after return to contact play in the postsurgical setting. Treatment and management of grade 3 ACJ injuries are somewhat controversial; however, recent studies have demonstrated good outcomes for nonoperative treatment of grade 3 ACJ separations,[†] and our current practice is an initial trial of nonsurgical management of grade 3 injuries in professional ice hockey players. In our study cohort, all players who had grade 3 injuries returned to play relatively quickly, at a mean of 28.3 days after initial injury, and none required future surgical intervention.

Although widely relied upon and used in the management of ACJ injuries, the Rockwood radiographic

[†]References 1, 3, 4, 13, 16, 18, 20, 26, 28.

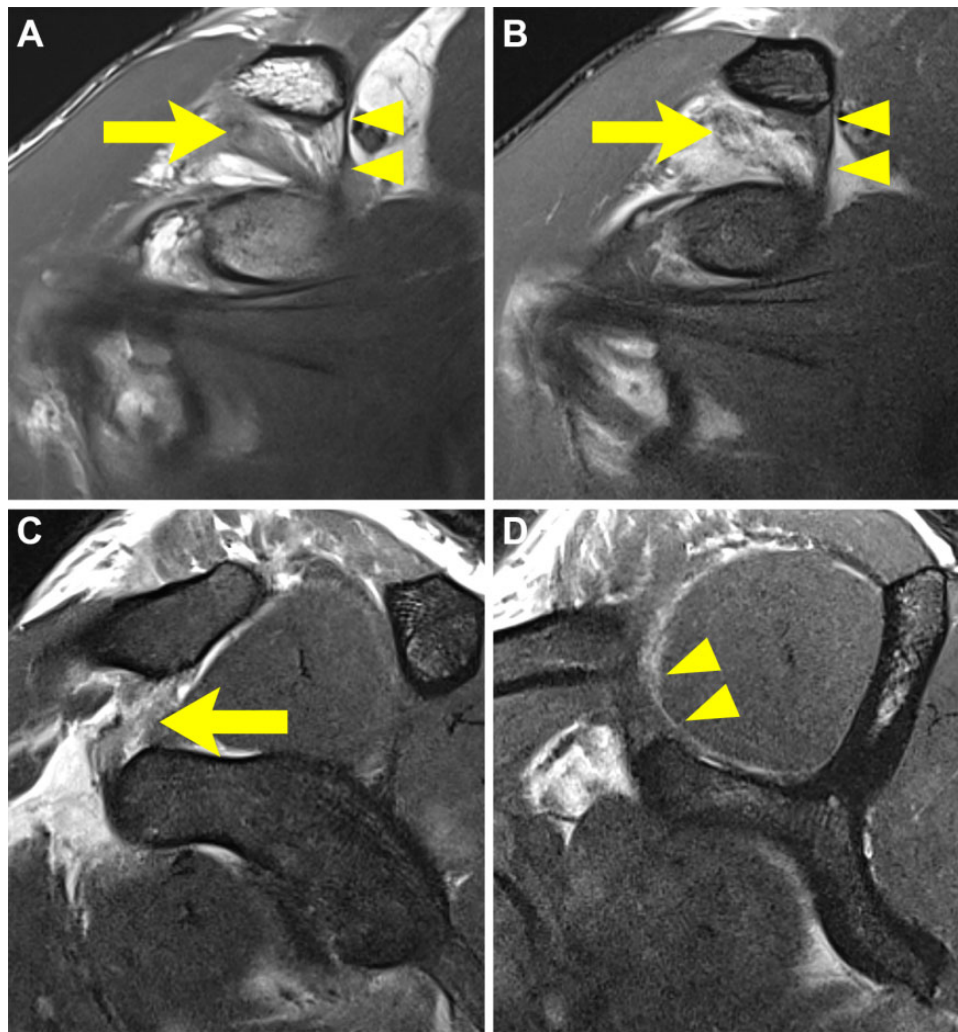


Figure 2. Grade 2 acromioclavicular injury: partial injury of coracoclavicular ligaments. (A) Coronal intermediate, (B) coronal T2-weighted fat suppressed, and (C, D) sagittal T2-weighted magnetic resonance imaging scans show acute tearing and disruption of the trapezoid ligament (arrows) and intact conoid ligament (arrowheads).

classification has limitations in accurately defining specific soft tissue ligamentous injuries sustained and can only indirectly evaluate status of the AC and CC ligamentous complexes through inference based on position of the clavicle relative to the acromion and coracoid process. Grade 3 injuries can be difficult to reliably distinguish from grade 2 ACJ injuries with conventional radiography.^{5,6,20} Furthermore, horizontal (anteroposterior) instability as seen in grade 4 and grade 6 injuries may be difficult to evaluate by traditional radiographic examination alone.^{12,23,24} Unlike conventional radiography, MRI after acute injury enables direct analysis of the soft tissue AC capsular and CC ligaments that stabilize the articulation as well as cross-sectional multiplanar evaluation of osseous alignment after clinically suspected ACJ injury. MRI performed with the patient in a supine position may influence the position of the scapula relative to the clavicle in the setting of ACJ instability and reduces the amount of gravity-assisted displacement traditionally assessed on upright

conventional radiography as indirect indicators of ACJ injuries (joint width, CC interval); supine positioning may also preclude direct comparison of such measurements between radiographs and MRI scans. Many orthopaedic surgeons consider MRI to be the standard diagnostic test in assessment of ACJ injuries; in one prior study, 51% of fellowship-trained subspecialist sports or shoulder orthopaedic surgeons indicated that they routinely obtain an MRI in assessment of ACJ injury.²⁷ Further, in the NHL player population, MRI examination has become standard practice in the assessment and management of clinically suspected acute ACJ injuries of sufficient severity that a player's performance may be impaired. MRI provides for accurate assessment of soft tissue ligamentous injuries as well as osseous alignment in orthogonal imaging planes, which may be particularly valuable in the assessment of horizontal instabilities (eg, grade 4 injuries), where radiographic examination may have limitations. MRI additionally provides for detailed evaluation of concomitant injuries

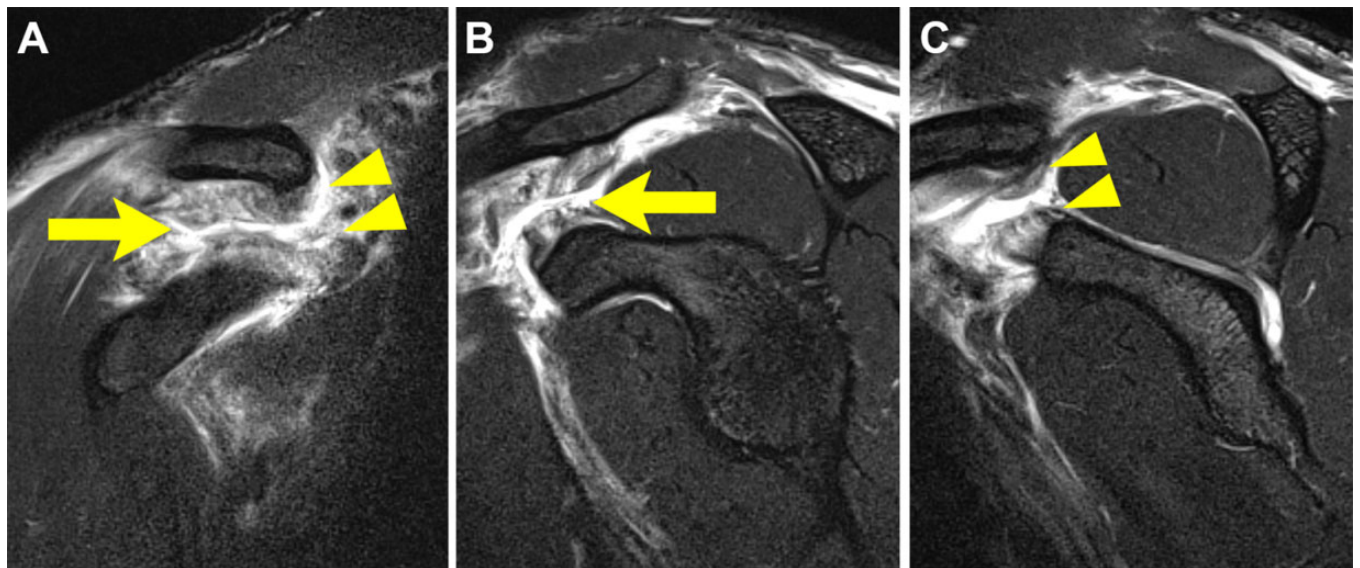


Figure 3. Grade 3 acromioclavicular injury: complete tearing of coracoclavicular ligaments. (A) Coronal T2-weighted fat suppressed and (B, C) sagittal T2-weighted magnetic resonance imaging scans show acute tearing and disruption of the trapezoid (arrows) and conoid (arrowheads) ligaments.

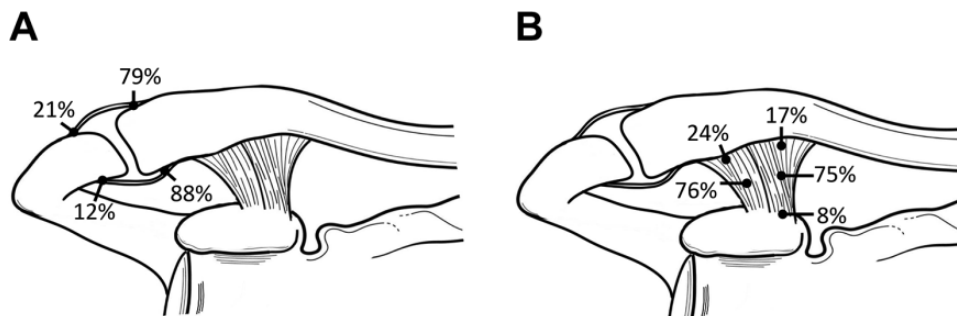


Figure 4. Distribution of ligamentous tearing. Diagrams of the acromioclavicular and coracoclavicular ligaments indicating anatomic location of injury involving (A) the acromial or clavicular insertions of the superior and inferior acromioclavicular ligaments and (B) the clavicular insertion, midportion or coracoid origin of the trapezoid, and conoid ligaments.

including glenohumeral joint injury, muscle strains, and bone bruising or edema, which may influence convalescence and rehabilitation planning. Finally, MRI serves as an important standardized means of accurately classifying ACJ injuries, without uncertainties often associated with radiographs, which ultimately may be required in future studies to objectively assess and compare treatment interventions and clinical outcomes in patients with ACJ injury.

The most common mechanism of ACJ injury in our study group was direct impact of a player's shoulder with the boards or playing surface. This is consistent with findings of prior studies,¹⁷ which noted that impact compression of the player's shoulder against hard, fixed surfaces, including the boards and ice playing surface, was the most common cause of upper extremity and ice hockey ACJ sprains.

Our study cohort demonstrated a significant predominance of ACJ injuries sustained during the first period of

game play. McKay et al,¹⁵ in a study of ice hockey injuries over 6 NHL seasons, similarly observed that a majority of ice hockey injuries overall occurred during the first period of play. In contrast, other epidemiologic reviews of collegiate or junior-level ice hockey injuries have shown an equivalent distribution of injuries across all periods of play⁹ or increased incidence during the third period of game play.²² The exact explanation for the observed predominance of NHL player ACJ injuries during the first period of play is unclear. However, it is possible that players are less fatigued during the first period and that resultant increased player speed and physicality of play during the first period of NHL games predispose players to an increased incidence of contact- or impact-associated injuries.¹⁵ Differences observed may also relate to player skill, size, speed, and physicality of play unique to NHL level-elite professional hockey competition compared with junior-level and collegiate athletics.

An additional feature reviewed in our player cohort was sidedness of ACJ injury. We observed a statistically significant predominance of ACJ injury (75%) ipsilateral to the side of player shooting-hand dominance. To our knowledge, no prior study has analyzed this characteristic of ACJ injuries in professional ice hockey. Ice hockey shooting handedness is defined by the hand positioned lower on the ice hockey stick during shooting and game play. This observation raises the possibility that the lower shoulder position of the player side ipsilateral to the player shooting-hand exposes the ACJ to more frequent or more forceful impact or, alternatively, places the ACJ in a more biomechanically vulnerable position during impact compressive stress.

MRI features of ACJ injuries observed in our study cohort are reflective of progressively increased severity of soft tissue ligamentous injury, from partial to complete disruption of the superior AC ligament, inferior AC ligament, and trapezoid ligament and finally complete conoid ligamentous disruption associated with higher grade ACJ injuries.^{1,2,3,16,20,23,26} All cases in our cohort group illustrated injury of the superior AC ligament. Similar to findings of a prior surgical prospective study investigating morphologic patterns of AC ligament tears in patients with high-grade ACJ injuries,¹⁴ we observed a majority of superior (79%) and inferior AC ligament tears (88%) anatomically involving their clavicular insertions. This morphologic pattern of AC ligamentous injury, particularly involvement of the anterosuperior AC ligament and implications for anteroposterior stability of the joint, may be an important consideration in precise preoperative planning in the setting of high-grade ACJ injuries where AC ligament disruption and incarceration may prevent anatomic ACJ reduction and necessitate open versus arthroscopic ACJ surgical reduction and reconstruction.¹⁴ Similarly, the pattern of CC ligament tearing observed in higher grade ACJ injuries in our series entailed midsubstance disruptions, with associated surgical implications regarding ligament graft reconstruction versus primary suture repair.

Muscular and myofascial soft tissue injuries involving the trapezius insertion and deltoid muscular insertions to the anterolateral clavicle and acromion have been described as clinical and imaging features associated with higher grade ACJ injuries.^{1,2,3,5,20,26} We observed trapezius and deltoid muscle tears on MRI in 79% and 50% of our cases, respectively. The majority of muscle tears observed were low grade by MRI classification (29% grade 1 and 46% grade 2 muscle injuries), and an association was observed between the presence of a muscle tear and increasing grade of ACJ injury. Despite the association of muscle tearing with increasing grade of injury, we could not demonstrate a statistically significant relationship between presence of muscle injury and longer time to return to play in our study.

Accurate estimates of return to play are highly important to professional athletes and their organizations. Limited data are available regarding return to play after ACJ injury in professional ice hockey players. A study of collegiate athletes noted an overall mean of 18.4 days lost per ACJ injury,²¹ although statistical significance was limited due to the small numbers of high-grade injury; the mean

duration of time lost was 63.7 days for high-grade injury and 10.4 days for low-grade ACJ sprains. Another epidemiologic study of injuries in collegiate ice hockey showed a mean of 5 practices missed and just under 2.5 games missed⁹ due to ACJ injuries. In a clinical review of musculoskeletal ice hockey injuries, LaPrade et al¹³ reported that recovery time usually ranged from 2 to 4 weeks for grade 1 and grade 2 ACJ injuries, 6 to 8 weeks for grade 3 injuries, and 4 to 6 months for grade 4 to 6 injuries and associated surgical intervention. In our study, when we excluded from analysis those cases with medical clearance for return to play extending into the off-season as well as the players who underwent surgery, we noted no statistically significant difference in mean duration of time between injury and return to play between players with grade 3 injuries (mean, 28.3 days; range, 26-32 days) and those with grade 1 or 2 injuries (mean, 20.1 days; range, 7-31 days). However, players with grade 3 injuries missed a significantly greater number of games from the NHL schedule compared with players with lower grade injuries (mean, 12.7 vs 6.1 games, respectively; $P = .027$).

Limitations of our investigation include the retrospective nature of the study design as well as selection bias introduced by requisite MRI referral of clinically suspected cases of ACJ injury for study inclusion. We did not have access to conventional radiographic examinations of our cases because radiographs were obtained at the time of injury locally at various arena sites. As a result, we did not assess possible differences in radiographic and MRI features or classification of ACJ injuries. Additionally, we did not assess possible interobserver variation in MRI assessment of injuries. An important limitation of our study is the relatively small number of cases reviewed from a single orthopaedic surgical consultant practice. Small numbers of grade 3 or higher ACJ injuries limited statistical analyses and precluded further characterization of indices of return to play across players with high-grade injuries. Our current nonoperative treatment for acute ACJ injuries may include therapeutic injections during convalescence and rehabilitation. However, we were not able to control or assess for the influence of possible therapeutic injections, including platelet-rich plasma, on return to play, because retrospective data related to injections by club medical staff, other physicians, or therapists were incomplete. Despite inherent limitations, our study represents the largest cohort with systematic MRI evaluation of acute ACJ injuries in active NHL ice hockey players.

CONCLUSION

Professional ice hockey is a high-speed contact sport with unique injury patterns, including a high relative incidence of ACJ injury. MRI provides an accurate and reproducible means of directly assessing the status of ligamentous and muscular stabilizers of the articulation acutely after injury, enabling precise classification of the extent and pattern of ACJ injury sustained. MRI, along with clinical features of injury, provides a basis to estimate return-to-play time frames in NHL players sustaining low-grade versus higher grade ACJ injuries. All players in our cohort successfully

returned to professional NHL competition after ACJ injury, and our results support the opinion that grade 1, 2, and 3 injuries can be successfully managed nonoperatively in professional ice hockey athletes.

REFERENCES

1. Alyas F, Curtis M, Speed C, Saifuddin A, Connell D. MR imaging appearances of acromioclavicular joint dislocation. *Radiographics*. 2008;28:463.
2. Antonio GE, Cho JH, Chung CB, Trudell DJ, Resnick D. MR imaging appearance and classification of acromioclavicular joint injury. *AJR Am J Roentgenol*. 2003;180:1103-1110.
3. Barnes CJ, Higgins LD, Major NM, Basamania CJ. Magnetic resonance imaging of the coracoclavicular ligaments: its role in defining pathoanatomy at the acromioclavicular joint. *J Surg Orthop Adv*. 2004;13(2):69-75.
4. Beitzel K, Mazzocca AD, Bak K, et al. ISAKOS upper extremity committee consensus statement on the need for diversification of the Rockwood classification for acromioclavicular joint injuries. *Arthroscopy*. 2014;30:271-278.
5. Bifield MF, Lapegue F, Gandois HC, Bayol MA, Bonneville N, Sans N. Ultrasound of the coracoclavicular ligaments in the acute phase of an acromioclavicular disjunction: comparison of radiographic ultrasound and MRI findings. *Eur Radiol*. 2017;27:483-490.
6. Bossart PJ, Joyce SM, Manaster BJ, Packer SM. Lack of efficacy of "weighted" radiographs in diagnosing acute acromioclavicular separation. *Ann Emerg Med*. 1988;17(1):20-24.
7. Ekstrand J, Healy JC, Waldén M, Lee JC, English B, Häggglund M. Hamstring muscle injuries in professional football: the correlation of MRI findings with return to play. *Br J Sports Med*. 2012;46(2):112-117.
8. Expert Panel on Musculoskeletal Imaging; Amini B, Beckmann NM, Beaman FD, et al. ACR appropriateness criteria shoulder pain—traumatic. *J Am Coll Radiol*. 2018;15(5) (suppl):S171-S188.
9. Flik K, Lyman S, Marx RG. American collegiate men's ice hockey: an analysis of injuries. *Am J Sports Med*. 2005;33(2):183-189.
10. Guermazi A, Roemer FW, Robinson P, Tol JL, Regatte RR, Crema MD. Imaging of muscle injuries in sports medicine: sports imaging series. *Radiology*. 2017;282:646-663.
11. Hibberd EE, Kerr ZY, Roos KG, Djoko A, Dompier TP. Epidemiology of acromioclavicular joint sprains in 25 National Collegiate Athletic Association sports: 2009-2010 to 2014-2015 academic years. *Am J Sports Med*. 2016;44(10):2667-2674.
12. Kraeutler MJ, Williams GR Jr, Cohen SB, et al. Inter- and intraobserver reliability of the radiographic diagnosis and treatment of acromioclavicular joint separations. *Orthopedics*. 2012;35:e1483-e1487.
13. LaPrade RF, Surowiec RK, Sochanska AN, et al. Epidemiology, identification, treatment and return to play of musculoskeletal-based ice hockey injuries. *Br J Sports Med*. 2014;48(1):4-10.
14. Maier D, Jaeger M, Reising K, Feucht MJ, Südkamp NP, Izadpanah K. Injury patterns of the acromioclavicular ligament complex in acute acromioclavicular joint dislocations: a cross-sectional, fundamental study. *BMC Musculoskelet Disord*. 2016;17(1):385-395.
15. McKay CD, Tufts RJ, Shaffer B, Meeuwisse WH. The epidemiology of professional ice hockey injuries: a prospective report of six NHL seasons. *Br J Sports Med*. 2014;48:57-62.
16. Melenevsky Y, Yablon CM, Ramappa A, Hochman MG. Clavicle and acromioclavicular joint injuries: a review of imaging, treatment, and complications. *Skeletal Radiol*. 2011;40(7):831-842.
17. Melvin PR, Souza S, Mead RN, Smith C, Mulcahey MK. Epidemiology of upper extremity injuries in NCAA men's and women's ice hockey. *Am J Sports Med*. 2018;46(10):2521-2529.
18. Molsa J, Kujala U, Myllynen P, et al. Injuries to the upper extremity in ice hockey: analysis of a series of 760 injuries. *Am J Sports Med*. 2003;31:751-757.
19. Mosenthal W, Kim M, Holzshu R, Hanypsiak B, Athviraham A. Common ice hockey injuries and treatment: a current concepts review. *Curr Sports Med Rep*. 2017;16(5):357-362.
20. Nemeč U, Oberleitner G, Nemeč SF, et al. MRI versus radiography of acromioclavicular joint dislocation. *AJR Am J Roentgenol*. 2011;197(4):968-973.
21. Pallis M, Cameron KL, Svoboda SJ, Owens BD. Epidemiology of acromioclavicular joint injury in young athletes. *Am J Sports Med*. 2012;40(9):2072-2077.
22. Pinto M, Kuhn JE, Greenfield MLVH, Hawkins RJ. Prospective analysis of ice hockey injuries at the junior A level over the course of one season. *Clin J Sport Med*. 1999;9:70-74.
23. Pogorzelski J, Beitzel K, Ranuccio F, et al. The acutely injured acromioclavicular joint—which imaging modalities should be used for accurate diagnosis? A systematic review. *BMC Musculoskelet Disord*. 2017;18(1):515-526.
24. Ringenberg JD, Foughty Z, Hall AD, Aldridge JM III, Wilson JB, Kurmsky MA. Interobserver and intraobserver reliability of radiographic classification of acromioclavicular joint dislocations. *J Shoulder Elbow Surg*. 2018;27(3):538-544.
25. Rockwood CA, Williams GR, Young D. Disorders of the acromioclavicular joint. In: Rockwood CA, Matsen FA, eds. *The Shoulder*. 3rd ed. WB Saunders; 1998:483-553.
26. Schaefer FK, Schaefer PJ, Brossmann J, Hilgert RE, Heller M, Jahnke T. Experimental and clinical evaluation of acromioclavicular joint structures with new scan orientations in MRI. *Eur Radiol*. 2006;16(7):1488-1493.
27. Shaw KA, Synovec J, Eichinger J, Tucker CJ, Grassbaugh JA, Parada SA. Stress radiographs for evaluating acromioclavicular joint separations in an active-duty patient population: what have we learned? *J Orthop*. 2018;15:159-163.
28. Willimon SC, Gaskill TR, Millett PJ. Acromioclavicular joint injuries: anatomy, diagnosis, and treatment. *Phys Sportsmed*. 2011;39:116-122.