

Received: 2012.03.26
Accepted: 2012.05.10
Published: 2012.10.15

Primary anorectal melanoma: A case report with extended follow-up

Aymen Lagha, Mouna Ayadi, Sarra Krimi, Nesrine Chraiet, Bassem Allani, Hela Rifi, Henda Raies, Amel Mezlini

Department of Medical Oncology, Salah Azaiez Institute, Bab Saadoun, Tunis, Tunisia

Summary

- Background:** Anorectal melanoma is a rare and aggressive disease. The mainstay of treatment is usually surgical with curative or palliative intent, since radio- and chemotherapy do not really improve the outcome. The poor prognosis is attributable to delay in diagnosis and its inherent biologic aggressiveness.
- Case Report:** We present a case of anorectal melanoma in a 68-year-old man who underwent solely abdomino-perineal amputation and was doing well 30 months after surgery, without any evidence of recurrent disease.
- Conclusions:** Treatment of anorectal melanoma should be by the least morbid means possible. Surgical procedure that can achieve a complete local excision and respect the functional aspects and quality of life of the patient remains the best therapeutic approach. No systemic regimen for metastatic anorectal melanoma is considered standard of care.
- key words:** malignant melanoma • anorectal neoplasm • immunohistochemistry • surgical treatment

Full-text PDF: <http://www.amjcaserep.com/fulltxt.php?ICID=883506>

Word count: 1513
Tables: –
Figures: 2
References: 20

Author's address: Aymen Lagha, Medical Oncology, Salah Azaiez Institute, 1006 Bab Saadoun Tunis, Tunisia,
e-mail: aymen.lagha@hotmail.com

BACKGROUND

Primary anorectal melanoma (ARM) is a rare and aggressive disease, accounting for less than 1% of all melanomas and 4% of all anorectal malignancies other than carcinoma [1]. The first case of the disease was reported by Moore in 1857 and so far approximately 500 cases have been reported in the literature. These tumors are often misdiagnosed due to their wide macroscopic and histological variability. In addition, due to the low incidence of these tumors and the difficulty in collecting a consistent number of cases in a homogeneous and rational way, clear guidelines for the therapy of anal melanomas are not completely established. In fact, response of ARM to radiotherapy and chemotherapy continues to be poor, and the optimum surgical treatment is still controversial. The prognosis is poor, with all surgical approaches achieving a 5-year survival rate of less than 20% [2]. We report on a patient with ARM who underwent surgical treatment and had extended follow-up, with the objective of analyzing the clinical presentation, histopathologic features, staging system, treatment, and long-term outcome.

CASE REPORT

A 68-year-old man presented with a 3-month history of rectal bleeding and weight loss. Digital rectal examination revealed a 1.5 cm nodular mass 2 cm from the anal verge. There was no clinical involvement of inguinal nodes. A rectosigmoidoscopy showed a 2 cm- polypoid, ulcerated, pigmented tumor in the lower third of the rectum (Figure 1). Biopsy specimens proved to be melanoma. Metastatic disease was ruled out. The patient underwent an abdominoperineal resection (APR). Histopathologic examination of the specimen showed neoplastic cells with melanin in the cytoplasm. Staining for S-100, Melan A and HMB-45 (Figure 2) were positive. The patient did not receive any further treatment. After 30 months of regular follow-up, he is well, without any evidence of local recurrence or distant metastases.

DISCUSSION

Anorectal malignant melanoma is a neuroectodermal neoplasm originating from the melanoblastic cells of the mucosal surface. It is defined as a "primary anorectal melanoma" (ARM) when it occurs around the dentate line [3]. It is a rare disorder, accounting for only 4% of all anorectal malignancies other than adenocarcinoma [1]. Approximately 1% of melanomas arise in the anorectal region, which represents the third most common site for primary mucosal melanomas, after the skin and eye [4]. ARM shows a clear female predominance, typically affecting women in the sixth or seventh decade [3,5]. However, a rising incidence of ARM, especially in males younger than the age of 45 years, and in possible association with HIV infection, has been reported in the literature [5]. Unlike other forms, particularly cutaneous melanoma, ARM does not have a precursor lesion, and there is no association with exposure to ultraviolet light [6].

Typical presentation of ARM is rectal bleeding or a palpable mass with pain; however, some patients may complain of pruritus, tenesmus, symptoms of prolapse, a change in bowel habit, or diarrhea [7]. Digital examination provides information concerning size, fixation and ulceration of the tumor, and proctosigmoidoscopy may be suggestive

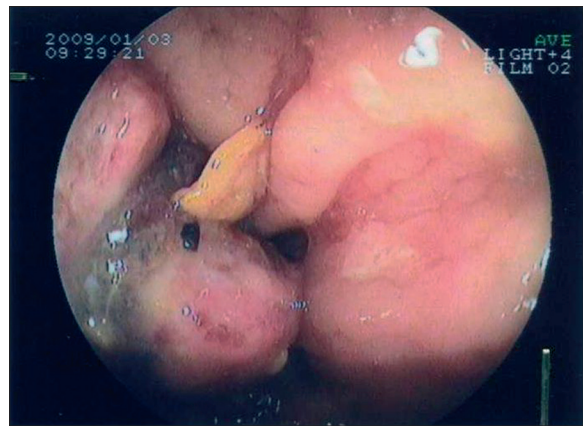


Figure 1. Rectosigmoidoscopy showing polypoid and pigmented tumor.

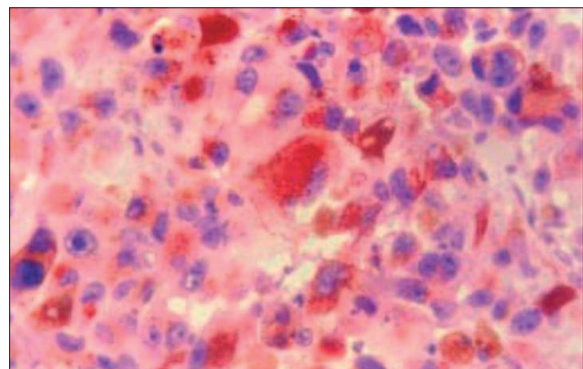


Figure 2. Immunohistochemical staining demonstrating strong staining with HMB-45.

of anorectal melanoma when pigmentation is obvious. Macroscopically, the tumors are polypoidal, so they are often misdiagnosed as a thrombosed hemorrhoid or rectal polyp [8]. ARM is also pigmented in the majority of cases; however, in 16–53% of cases the lesion appears to be amelanotic [9]. A biopsy should be performed on any doubtful lesion. Histologically, anorectal melanomas exhibit considerable variability in cell size and shape, both from tumor-to-tumor and within a given tumor [10]. They can mimic other malignancies such as malignant lymphoma, small round cell sarcoma, spindle cell sarcoma, gastrointestinal stromal tumor, spindle cell carcinoma or even epidermoid carcinoma [10,11].

In the event of difficulty in establishing the diagnosis, particularly in amelanotic cases with unusual morphologic features, immunohistochemical stains (IHC) may be a useful tool [11]. Anti-S-100 protein is the most common screening immunohistochemical stain used in the diagnosis of malignant melanoma, and is highly sensitive for melanocytic differentiation [11]. However, given the lack of specificity, it is used primarily as a screening tool. HMB-45 and antibodies to MelanA (also known as MART-1) are the 2 most common "melanocyte-specific" stains used in the diagnosis of malignant melanoma [11]. These stains are highly specific for melanocytic neoplasms, but also may be seen in other tumors with melanocytic differentiation (eg, angiomyolipomas, lymphangioleiomyomatosis, clear cell myomelanocytic

tumors) [11]. Although these stains are highly specific for melanocytes, sensitivity is decreased compared with S-100 protein. Antityrosinase antibodies also are considered highly specific and sensitive for melanocytic neoplasms with sufficient maturation [11]. Usually, melanomas are negative for pancytokeratin, but up to 10% of melanomas show expression of a keratin or epithelial marker [12], sometimes leading to misdiagnosis as a poorly differentiated carcinoma. In conclusion, to ensure a correct diagnosis, especially in small biopsies of amelanotic undifferentiated tumors, we should perform IHC staining using S-100 protein as a screening tool, and HMB-45, MelanA, and tyrosinase as a panel, because they show higher specificity but lower sensitivity [11].

Treatment of ARM is based essentially on the spread of the disease. Many staging systems have been referenced in the literature, especially the staging system for gastrointestinal mucosal melanomas, in which stage I disease is a clinically localized disease, stage II is a disease with regional lymph node metastases, and stage III represents distant metastasis [2]. Breslow's thickness, which is the distance from the surface of the epithelium to the point of deepest penetration of the tumor, has also been used as a staging tool [13]. More recently, a new staging system has been established by the American Joint Cancer Committee, based primarily on the Breslow thickness [3]. It divides melanomas into 4 localized groups, 1 regional disease, and 1 spread disease.

The cornerstone of treatment for localized ARM is surgery, but controversy still exists over which procedure should be performed – abdominoperineal resection (APR) or wide local excision (WLE). The main arguments in favor of APR are its ability to control lymphatic spread (predominantly to mesenteric lymph nodes) and creation of a larger excision with larger negative margins, leading to better local control [14]. On the other hand, the main arguments against APR are its associated morbidity and mortality, and a high incidence of inguinal lymph node metastasis (not resected with this approach). Additionally, there is no evidence of a survival benefit of APR compared with WLE, based on disease-free survival curves [3,14,15]. As a result, it is recommended that local therapy for the primary tumor should be a sphincter-sparing local excision with normal margins when technically feasible [14,15]. Hence, APR should be reserved for lesions that cannot be removed by local excision (local bulky disease), or for salvage surgery in selected cases of isolated local recurrence [14,15]. Also, prophylactic bilateral inguinal lymphadenectomy in patients without clinically evident lymph nodes is not recommended due to the significant complications [14]. Concerning metastatic ARM, operations are most likely to be palliative surgery, and APR is widely performed, but it can be avoided when WLE is technically feasible [15]. In severely ill patients unable to tolerate any surgical procedures, intramural injections of natural interferon beta and systemic administration of dacarbazine has been used with good results [16].

Nevertheless, no systemic therapy regimen for metastatic anal melanoma is considered standard of care [16]. The role of chemotherapy and immunotherapy in the treatment of melanoma remains controversial. This kind of treatment is based on drugs developed for advanced cutaneous melanoma, although given their clinical, biologic, and molecular differences, mucosal and cutaneous melanomas may be

distinct disease entities [16]. Several regimens have been recommended, including interferon- and cytotoxic chemotherapeutic agents as cisplatin or dacarbazine, but none has shown a survival benefit in patients with melanomas [14,17]. Some authors have noted an improvement in prognosis after adjuvant chemotherapy or immunotherapy [14,15,18], whereas others recommend it only in the palliative setting. The role of radiation therapy for treatment of melanoma is also controversial. In fact, melanomas are known to be relatively radiation-insensitive tumors [19], but some promising results of local excision combined with preoperative or adjuvant radiotherapy have been reported in the literature [17,19]. Definitive assessment of the efficacy of adjuvant treatment based on chemotherapy or radiotherapy requires further prospective study.

Prognosis of ARM is still very poor, regardless of surgical approach used. In fact, even in patients with local or locoregional disease for whom resection is potentially curative, 5-year survival is only 5% to 20% [2,17]. This result is extremely low when compared with the 53.9% 5-year survival for anal carcinomas [20], or the 80% 5-year survival for cutaneous melanomas [11].

CONCLUSIONS

ARM is a rare disorder, but it remains a highly lethal disease. IHC can assist in promptly establishing an accurate diagnosis of these difficult cases, although even with a correct diagnosis, the prognosis is still poor. Treatment should be the by the least morbid means possible. Surgical procedures that can achieve a complete local excision and respect the functional aspects and quality of life of the patient remains the best therapeutic approach – a wide local excision when technically feasible and a combined APR for large or obstructing tumors. No systemic regimen for metastatic ARM is considered standard of care.

REFERENCES:

1. Goldman S, Glimelius B, Pahlman L: Anorectal malignant melanoma in Sweden: Report of 49 patients. *Dis Colon Rectum*, 1990; 33: 874–47
2. Ross M, Pezzi C, Pezzi T et al: Patterns of failure in anorectal melanoma: a guide to surgical therapy. *Arch Surg*, 1990; 125: 313–16
3. Yap LB, Neary P: A comparison of wide local excision with abdominoperineal resection in anorectal melanoma. *Melanoma Res*, 2004; 14(2): 147–50
4. Garnick M, Lokich JJ: Primary malignant melanoma of the rectum: rationale for conservative surgical management. *J Surg Oncol*, 1978; 10(6): 529–31
5. Cagır B, Whiteford MH, Topham A: Changing epidemiology of anorectal melanoma. *Dis Colon Rectum*, 1999; 42: 1203–8
6. Edwards RH, Ward MR, Wu H: Absence of BRAF mutations in UV-protected mucosal melanomas. *J Med Genet*, 2004; 41: 270–72
7. Slingluff C, Vollmer R, Seigler H: Anorectal melanoma: clinical characteristics and results of surgical management in twenty-four patients. *Surgery*, 1990; 107: 1–9
8. Ceccopieri B, Marcomin AR, Vitagliano F, Fragapane P: Primary anorectal malignant melanoma: report of two cases. *Tumori*, 2000; 86: 356–58
9. Sielezneff I, Boutboul R, Thomas P et al: Primary anorectal malignant melanomas. 2 cases. *Presse Med*, 1993; 22: 1999–2001
10. Somran J, Kannnurn S, Porncharoenpong S, Iertkajornsinsin O: Anorectal Malignant Melanoma: Report of Two Cases from Buddhachinnaraj Hospital. *J Med Assoc Thai*, 2005; 88(8): 1128–33
11. Chute DJ, Cousar JB, Mills SE: Anorectal Malignant Melanoma Morphologic and Immunohistochemical Features. *Am J Clin Pathol*, 2006; 126: 93–100

12. Miettinen M, Franssila K: Immunohistochemical spectrum of malignant melanoma: the common presence of keratins. *Lab Invest*, 1989; 61: 623-28
13. Breslow A: Thickness, cross sectional areas and depth of invasion in the prognosis of cutaneous melanoma. *Ann Surg*, 1970; 172: 902-8
14. Pessaux P, Pocard M, Elias D et al: Surgical management of primary anorectal melanoma. *Br J Surg*, 2004; 91: 1183-87
15. Fukui R, Hata F, Yasoshima T et al: Malignant Melanoma of the Anorectum: Report of Four Cases. *Surg Today*, 2002; 32: 555-58
16. Christos NS, Basileios GS, Evangelos PM: Diffuse anorectal melanoma; review of the current diagnostic and treatment aspects based on a case report. *World J Surg Oncol*, 2009; 7: 64
17. Kelli MB, Todd MT, David AR et al: Surgical Therapy for Anorectal Melanoma. *J Am Coll Surg*, 2003; 196(2): 206-11
18. Ulmer A, Metzger S, Fierlbeck C: Successful palliation of stenosing anorectal melanoma by intratumoral injections with natural interferon-beta. *Melanoma Res*, 2002; 12: 395-98
19. Bujko K, Nowacki MP, Liszka-Dalecki P: Radiation therapy for anorectal melanoma. A report of three cases. *Acta Oncol*, 1998; 37: 497-99
20. Myerson RJ, Karnell LH, Menck HR: The National Cancer Data Base report on carcinoma of the anus. *Cancer*, 1997; 80: 805-15