

Received: 2017.09.26
Accepted: 2017.10.24
Published: 2017.11.20

What Kind of Incision Should Be Made to Reduce the Risk of Incisional Hernia in Kidney Transplantation?

Authors' Contribution:
Study Design A
Data Collection B
Statistical Analysis C
Data Interpretation D
Manuscript Preparation E
Literature Search F
Funds Collection G

AEF **Ihsan Yıldız**
BC **Yavuz Savas Koca**

Department of General Surgery, School of Medicine, Suleyman Demirel University, Çünür, Turkey

Corresponding Author:
Source of support:

This article was accepted as a poster presentation in Tx-2016 Congress (The 11th Congress of the Turkish Transplant Centers Coordination Association (TTCCA 2016) October (12–15) 2016 in Konya, Turkey) with poster number of (P 80)1037
Ihsan Yıldız, e-mail: drihsanyildiz@gmail.com
Departmental sources

Background: The incidence of incisional hernia following renal transplantation is 1.1% to 3.8%. The risk factors are immunosuppressive medications, impaired tissue quality, neuromuscular trauma due to the operation, and denervation. The incidence has been decreasing based on the shift from hockey-stick incision method to inguinal oblique incision method. The aim of this study was to minimize the development of incisional hernias due to renal transplantation.

Material/Methods: Twenty-four patients who underwent renal transplantation in 2015–2017 were retrospectively examined. All transplantations were performed with oblique incisions of 10–15 cm in the right or left inguinal region using polydioxanone (No. 2) loop sutures and continuous technique.

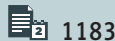
Results: The mean age of study patients was 43 years (range 24–67 years). The mean body mass index (BMI) was 29 kg/m² (range 25–38 kg/m²). Of these patients, one had diabetes mellitus, two had chronic pulmonary disease, six were obese, one had poliomyelitis sequelae, and seven had hypoalbuminemia. None of the patients had ascites; five patients had a history of surgery for peritoneal dialysis. At the end of the one-year follow-up period, none of the patients had developed an incisional hernia.

Conclusions: We conclude that using the smallest possible semilunar line incision in the inguinal region would aid in preventing post-transplantation incisional hernias.

MeSH Keywords: **Hernia • Herniorrhaphy • Kidney Transplantation**

Abbreviations: **BMI** – body mass index; **M** – Male; **F** – Female

Full-text PDF: <https://www.annalsoftransplantation.com/abstract/index/idArt/907305>



1183



2



3



11



Background

The incidence of incisional hernia after abdominal surgery is 2% to 13%. Patient risk factors identified are obesity, systemic diseases including chronic pulmonary diseases, diabetes, and connective tissue disorders, ascites, repetitive laparotomies, pregnancy, and wound infections. In addition to individual patient risk factors, surgical technique, suture material, and the surgeon's experience are also risk factors [1,2]. The incidence of incisional hernia following renal transplantation is reported to be 1.1% to 3.8%. Other factors responsible include immunosuppressive treatment, impaired tissue quality due to renal disease, neuromuscular trauma owing to operation, and denervation [3,4].

The type of incision is an important factor for prevention of this non-rare complication. The rate of incisional hernias has decreased recently, due to increasing application of inguinal oblique incisions as a substitute for traditional hockey-stick incisions. While primary repair and repair with mesh may be performed, no standard approach has been defined for surgical treatment of post-transplantation incisional hernias [5,6]. This study aimed to minimize the incisional hernias following kidney transplantations using the inguinal oblique incision approach.

Material and Methods

A total of 24 patients (13 males and 11 females) with a mean age of 43 years (range 29–67 years) who underwent renal transplantation (13 cadaveric donors and 11 live donors) at Suleyman Demirel University Organ Transplantation Center between July 2015 and July 2017 were retrospectively examined (Table 1). The ethics committee of Suleyman Demirel University approved this study.

All transplantations were performed with oblique incision of the right or left lower quadrant (just above the groin region) a 10–15 cm incision was made using continuous technique instead of the standard hockey-stick incision. The layers of anterior abdominal wall were passed, and the iliac fossa was reached through the junction of the external oblique muscle and rectus sheath (linea semilunaris), avoiding cutting the muscles (Figure 1).

The peritoneum was dissected and turned to the medial. The spermatic cord in males and the round ligament in females were suspended and eliminated. The vasculature and neurologic structures were protected as far as possible. The fatty cellular structures in the iliac fossa were dissected, the vascular structures were prepared for anastomosis, and the transplantation was performed. Following control of bleeding and drainage, the external oblique muscle was attached to the rectus

junction with polydioxanone loop (No. 2) suture via continuous technique. The Camper and Scarpa fasciae were sutured with 3/0 polyglactin and the skin was closed with 3/0 polypropylene (Figures 2, 3). All patients received standard immunosuppression therapy with polyclonal anti-thymocyte globulin (ATG) in the induction, and triple immunosuppression therapy including steroid, tacrolimus, and mycophenolate mofetil. In addition to physical examination, ultrasonography was used in the diagnosis of incisional hernias.

Results

A total of 24 patients (13 males, age 24 to 67 years, 11 females age 29 to 56) were involved in the study, which included 11 cadaver donors and 13 live donors, and 22 left kidneys and 2 right kidneys. The mean duration of hemodialysis and peritoneal dialysis were 10.3 and 3.3 years, respectively (Table 1).

The post-transplantation follow-up time was 7.58 months (range 3–15 months). The mean body mass index (BMI) was 29 kg/m² (range 25–38 kg/m²). Six patients had diabetes mellitus, two patients had chronic pulmonary disease, six patients had BMI >30 kg/m², one patient had poliomyelitis sequelae, and seven patients had hypoalbuminemia (<2.5 g/dL). None of the patients had ascites. Two patients had a history of undergoing laparotomy for ileus due to peritoneal dialysis operation.

No cases of rejection or death occurred in the follow-up period. Also, no surgical complications, such as operation site infections, bleeding, seroma, and dehiscence, were observed. The mean serum creatinine levels were 1.65 mg/dL for the first month and 1.68 mg/dL for the third month and at the last creatinine measurement (Table 2). In the mean follow-up period of one-year, incisional hernia was not observed in any patients.

Discussion

Incisional hernias following abdominal surgery are of a particular concern for surgeons. Incisional hernias do not become apparent until post-operative early months (mean occurrence 48 days) due to the predominance of immunologic complications. Hernias often emerge as a secondary problem identified by discomfort of the patient [7]. While there are several techniques for surgical repair, a standardized approach has not been established [5–10].

In addition to hockey-stick incisions, inguinal oblique incisions have recently become a preferred approach [3]. We performed the kidney transplantations in this study using right or left inguinal oblique incisions to avoid damage to the neuromuscular structures. We did not observe incisional hernias in any of our

Table 1. Distributions of age, sex, duration of hemodialysis and peritoneal dialysis.

Sex	Age	Hemodialysis	Periton dialysis
F	56	No	No
M	42	No	No
F	48	3 years	No
M	58	12 years	2 years
M	42	5 months	No
F	29	3 years	2 years
F	53	7 years	No
F	35	No	No
M	57	5 months	No
F	30	No	6 years
M	48	1 month	No
M	42	13 years	No
M	43	5	No
M	46	7	2 years
F	59	5	No
M	24	No	No
M	34	6	No
M	54	No	No
M	60	12	No
F	30	7	No
F	40	8	No
F	46	11	No
F	60	8	No
M	67	12	No

M – Male; F – Female.

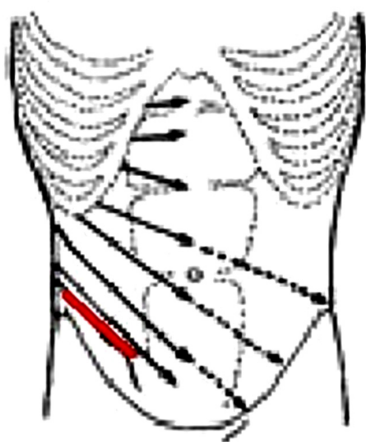


Figure 1. Intercostal nerve and the incision (right or left lower quadrant, just above the groin region: in red) are shown.

patients in the follow-up period of three to 15 months (mean follow-up of 7.58 months).

The systemic effects of immunosuppressive drugs, recent onset diabetes, tendency to gain weight, and hypoproteinemia can affect tissue perfusion and quality negatively [4,11]. In this current study, we prescribed patients a standard regimen of corticosteroids, mycophenolate mofetil, and calcineurin inhibitors. Patients also received standard immunosuppression therapy with polyclonal anti-thymocyte globulin (ATG) in the induction and between three and five days.

Chang et al. [10] and Ooms et al. [11] investigated (2011–2016) the effect of diabetes, chronic pulmonary disease, obesity (BMI >30 kg/m²), time of warm and cold ischemia, hypoalbuminemia (<2.5 g/dL), history of previous abdominal surgery, smoking, and infection on post-transplant incisional hernia. They concluded that obesity, particularly BMI >30 kg/m², was the most

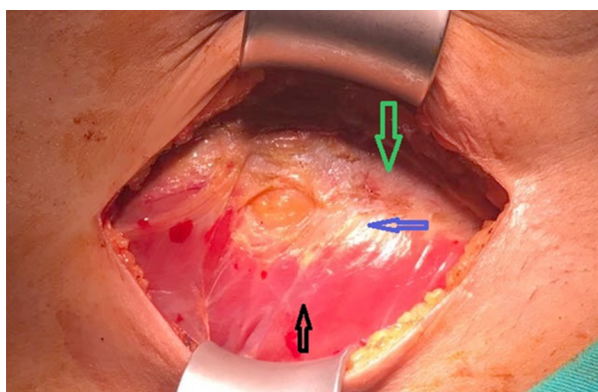


Figure 2. Blue arrow shows the incision line (linea semilunaris), black arrow shows the external oblique muscle, and green arrow shows the rectus sheath.

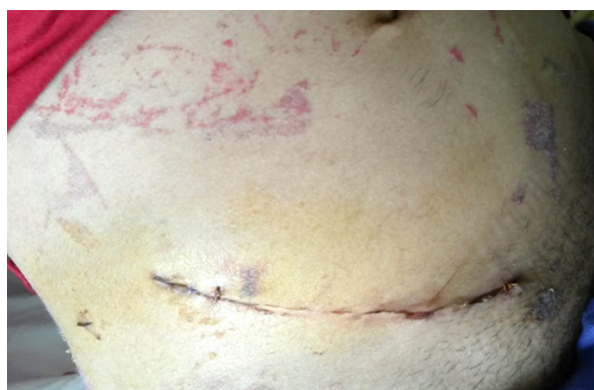

Figure 3. Incision line scar.

Table 2. After kidney transplantation, 1. week, 1. month, 3. month and last creatine levels.

Sex	1. Week Creatinine mg/dL	1. Month Creatinine mg/dL	3. Month Creatinin mg/dL	Last Creatinin mg/dL
F	4.79	4.68	2.98	2.76
F	1.38	1.50	1.32	1.32
M	5.5	1.38	1.20	1.20
M	1.28	0.79	0.85	0.85
M	3.3	1.48	1.46	1.46
F	1.47	0.99	1.04	0.9
M	5.46	2.77	2.46	2.05
M	5.3	1.55	1.87	1.48
F	5.79	1.47	1.34	1.19
F	0.81	0.97	0.96	0.89
F	1.49	1.08	1.03	1.03
M	4.49	1.17	1.15	1.23
M	1.7	1.3	1.2	1.12
M	1.8	1.5	1.2	1.24
F	2.6	1.1	1	0.9
M	3.4	2.1	1.5	1.23
M	5.3	3.2	1.6	1.4
M	3.2	1.5	1.4	1.3
M	3.2	1.2	1.1	1.2
F	2.3	1.4	1.2	1.3
F	3.1	2.1	1.5	1.24
F	2.7	1.5	1.4	1.3
F	1.5	1.3	1.1	0.94
M	3.1	2.3	1.4	1.34

M – Male; F – Female.

important risk factor [10,11]. In another study by Durinka et al. (2016), researchers investigated additional predictive risk factors for hernia development and remarked that delayed graft function might be a predictive risk factor [4].

Of our patients, six had diabetes, one had chronic pulmonary disease, three had obesity (BMI >30 kg/m²), one had poliomyelitis sequelae, and three had hypoalbuminemia (<2.5 g/dL). Two cases had undergone laparotomy for ileus due to peritoneal dialysis. No occurrence of incisional hernia and no surgical complications, such as operation site infections, bleeding, seroma, and dehiscence, were observed in our patients. Also, as seen in Table 2, none of the patients developed delayed graft function.

The surgical technique, and the site and size of the incision are among risk factors of incisional hernia. Experience of the surgeon is also a consideration for complications [11]. We performed the kidney transplantation with right or left inguinal oblique incisions of 10–15 cm to avoid damage to any neuromuscular structures and to minimize the risk of complications (Figures 1, 2).

References:

1. Smith CT, Katz MG, Foley et al: Incidence and risk factors of incisional hernia formation following abdominal organ transplantation. *Surg Endosc*, 2015; 29: 398–404
2. Kieszek R, Wszola M, Domagała P et al: Current trends in the treatment of incisional hernia in patients after kidney transplantation. *Pol Merkuriusz Lekarski*, 2010; 29: 50–53
3. Nanni G, Tondolo V, Citterio F et al: Comparison of oblique versus hockey-sticksurgical incision for kidney transplantation. *Transplant Proc*, 2005; 37: 2479–81
4. Durinka JB, Parsikia A, Karipineni F et al: Association between delayed graft function and incisional hernia after renal transplant. *Exp Clin Transplant*, 2017; 15(1): 27–33
5. Petro CC, Orenstein SB, Criss CN et al: Transversus abdominis muscle release for repair of complex incisional hernias in kidney transplant recipients. *Am J Surg*, 2015; 210: 334–39
6. L Santangelo M, Carlomagno N, Spiezia S et al: Use of biological prostheses in transplant patients with incisional hernias. Preliminary experience. *Ann Ital Chir*, 2013; 84: 471–75
7. Varga M, Matia I, Kucera M et al: Polypropylene mesh repair of incisional hernia after kidney transplantation: Single-center experience and review of the literature. *Ann Transplant*, 2011; 16: 121–25
8. Mahdavi R, Mehrabi M: Incisional hernia after renal transplantation and its repair with propylene mesh. *Urol J*, 2004; 1: 259–62
9. Birolini C, Mazzucchi E, Utiyama EM et al: Prosthetic repair of incisional hernia in kidney transplant patients. A technique with onlay polypropylene mesh. *Hernia*, 2001; 5: 31–35
10. Chang EI, Galvez MG, Padilla BE et al: Ten-year retrospective analysis of incisional herniorrhaphy following renal transplantation. *Arch Surg*, 2011; 146: 21–25
11. Ooms LS, Verhelst J, Jeekel J et al: Incidence, risk factors, and treatment of incisional hernia after kidney transplantation: An analysis of 1,564 consecutive patients. *Surgery*, 2016; 159: 1407–11

Conclusions

Preventing hernias following renal transplantations is an important responsibility of surgeons. A favorable approach is to use of the smallest possible semilunar line incision in the inguinal region.

Conflicts of interest

None.