



Dolichoectasia of vertebrobasilar artery presenting as facial pain: a case report

Prasanna Vadhanan^{1,2}

¹Department of Anaesthesiology, Vinayaka Missions Medical College and Hospitals, Vinayaka Missions Research Foundation, Karaikal, India

²Pain Clinic, Mayiladuthurai, India

Dolichoectasia of the intracranial arteries is a rare condition characterized by elongated and tortuous arteries due to progressive destruction of the vessel walls. Although most patients present with cerebrovascular accidents, our patient presented with intractable facial pain along the distribution of the trigeminal nerve. Clinical examination revealed involvement of the 5th, 7th, and 8th cranial nerves, and subsequent MRI showed dolichoectasia of the left basilar artery. The patient experienced symptomatic relief after a trial of carbamazepine along with botulinum toxin injections.

Keywords: Botulinum Toxin; Facial pain; Hemifacial spasm; Vertebrobasilar insufficiency.



This is an Open Access article distributed under the terms of the Creative Commons Attribution Non-Commercial License (<http://creativecommons.org/licenses/by-nc/4.0/>) which permits unrestricted non-commercial use, distribution, and reproduction in any medium, provided the original work is properly cited.



INTRODUCTION

Intracranial dolichoectasia is a rare condition characterized by tortuous and elongated arteries and is associated with significant morbidity and mortality [1]. Patients usually present with cerebral infarction or hemorrhage. Other less frequent presentations are due to compression of the cranial nerves, brainstem stem, and 3rd ventricle. Trigeminal nerve compression can cause trigeminal neuropathy. We present the case of an elderly patient referred to a pain clinic for intractable facial pain and subsequently managed using botulinum toxin injections, the use of which has not been previously reported for this condition.

CASE REPORT

A 72-year-old man was referred to the pain clinic for intractable facial pain that had persisted for 6 months. The pain was located in the left infrazygomatic and maxillary regions. Initially, the pain was dull, aching, and intermittent, later progressing to a continuous, lancinating type with episodic exacerbations. The patient underwent two dental extractions for the same complaint. The pain intensity was 7 on the numerical rating scale (NRS). The pain was usually constant, unabating, and occasionally exacerbated (NRS score: 9) by chewing and hearing loud sounds. The pain was disturbing his sleep and he was on oral tramadol 50 mg twice daily which made him feel “slightly” better. He also had hearing difficulties on the affected side and occasional involuntary muscle spasms

Received: April 7, 2023 • Revised: May 4, 2023 • Accepted: July 2, 2023

Corresponding Author: Prasanna Vadhanan, M.D, Dip. Pain Management, Professor, Department of Anaesthesiology, Vinayaka Missions University, Vinayaka Mission's Research Foundation, Vinayaka Missions Medical College, Karaikal, Karaikal, 609609, INDIA
Phone: +91 9486489690 E-mail: vadhanan.prasanna@gmail.com

Copyright© 2023 Journal of Dental Anesthesia and Pain Medicine

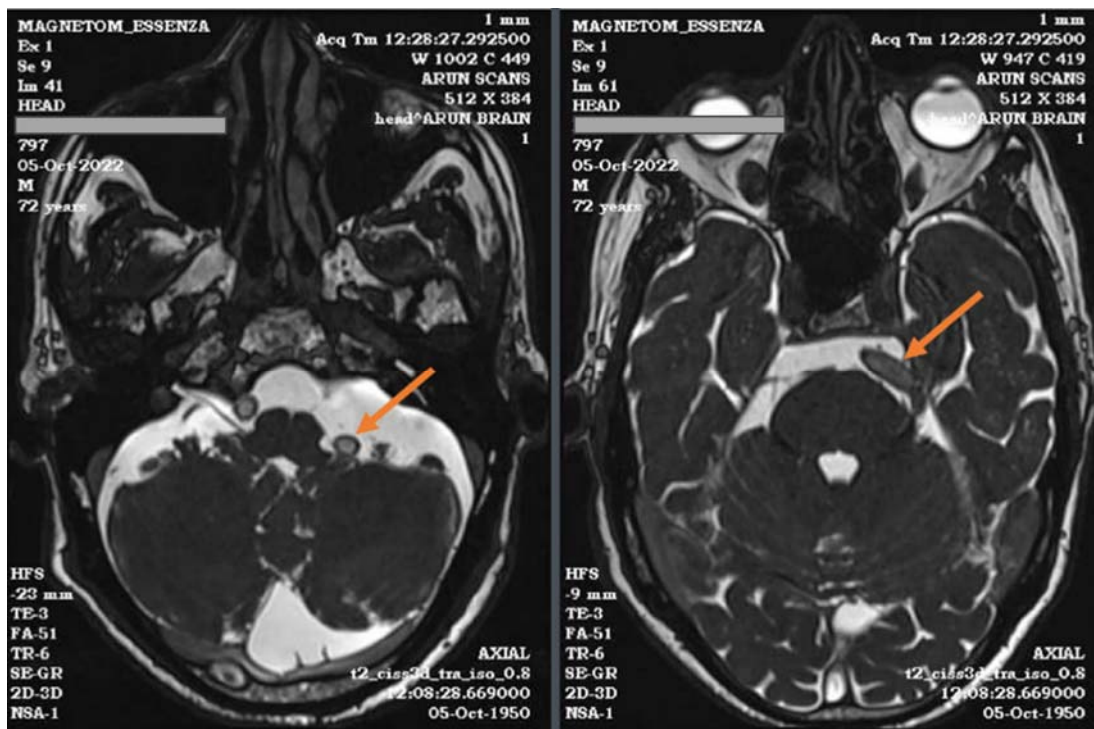


Fig. 1. MRI showing Vertebrobasilar Dolichoectasia. Red arrows point elongated left vertebral artery. MRI, magnetic resonance imaging.

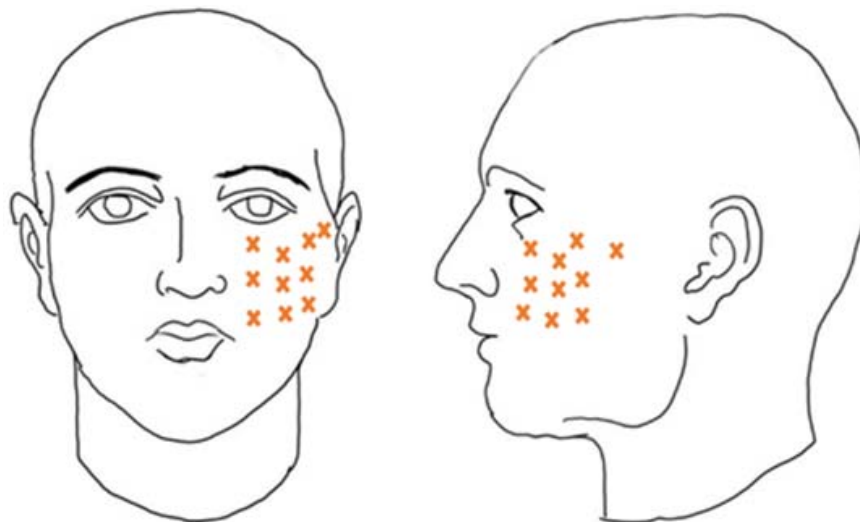


Fig. 2. Botulinum toxin injection sites

of the left facial muscles. He was a patient with known hypertension undergoing irregular treatment. Upon examination, his blood pressure was 170/100 mmHg. The patient had sensorineural deafness on the affected side and occasional facial tics. Mild hyperalgesia was observed along the infrazygomatic area of the affected side. Oral examination was unremarkable, except for the

dental extractions.

A magnetic resonance imaging (MRI) scan was requested that showed vertebrobasilar dolichoectasia, indenting the left anterolateral pons, and compressing and displacing the left trigeminal nerve. The MRI sequences used were FLAIR axial, T1W sagittal, FLAIR coronal, and T2 CISS axial; 5-mm cuts were made (Fig. 1). The 7th and 8th

cranial nerves were minimally indented at their exits near the prepontine cistern. Age-related parenchymal atrophy and microangiopathic changes were also noted. The patient was unwilling to undergo a neurovascular intervention. Antihypertensives (amlodipine 5 mg and telmisartan 40 mg once daily) and antiplatelets (clopidogrel 75 mg once daily) were initiated. For pain relief, he was prescribed carbamazepine 200 mg and gabapentin 300 mg twice daily. After 2 weeks, his blood pressure was 150/90 mmHg and NRS score was 5. The bothersome facial tics were also present. He also reported daytime drowsiness and sleep disturbances due to the persistent pain. Botulinum toxin injections were offered as a minimally invasive procedure to reduce hemifacial spasms and provide pain relief. Under aseptic precautions, 50 units of onabotulinum toxin (Botulax, Korea) was injected in a grid-like fashion intramuscularly over the spasmodic facial muscles and areas of pain (Fig. 2). Ten injections of 5 units at each site were administered. The patient experienced symptomatic relief and felt better at the 2-month follow up; the spasms were “greatly reduced,” and the NRS score was 3.

DISCUSSION

This case report was reviewed and approved by the Institutional Ethics Committee (approval number: CS23/03/2022). The incidence of intracranial arterial dolichoectasia (IADE) is reported between 0.06% and 5.2% [2], with a male preponderance. Although the vertebrobasilar system is considered to be involved more frequently [3], recent studies have shown that both the anterior and posterior circulations are equally affected; the basilar artery is the most commonly involved artery [4]. Most patients present with a stroke and are less commonly diagnosed with facial neuropathies. This disease is characterized by the irreversible destruction of the tunica media due to turbulence and the activation of metalloproteinases [5]. The diagnosis is based on imaging findings and the application of Smoker’s criteria [6]. The parameters follow the MRI findings in 5-mm cuts: a)

basilar artery diameter (5.3 mm), b) laterality (lateral to the lateral margin of the clivus), and c) height of bifurcation (at the 3rd ventricular floor). No specific treatment exists; however, blood pressure control, antithrombotic prophylaxis, and surgery have been recommended.

Our patient presented with only facial pain, which is unusual; he was initially referred to us for possible trigeminal neuralgia. While compression of the trigeminal nerve by the superior cerebellar artery is considered a common etiology of trigeminal neuralgia, dolichoectasia of the vertebrobasilar artery, which displaces the trigeminal nerve, was responsible for the patient’s symptoms. Our patient fell under the International Classification of Headache Disorders, 3rd edition (ICHD-3) category of painful trigeminal neuropathy, as the following conditions were fulfilled: pain in the trigeminal nerve region, continuous pain with superimposed paroxysms, and hyperalgesia. Other conditions that should be considered in the differential diagnosis include cerebrovascular accidents, intracranial space-occupying lesions, multiple sclerosis, and atypical facial pain. Physical examination revealed the presence of other cranial nerve deficits, prompting MRI, which confirmed the diagnosis. As ischemic stroke is the most common complication, antiplatelet therapy was initiated. While it may not produce pain relief per se, blood pressure control prevents further worsening of the ectasia; hence, the patient was started on antihypertensives. Carbamazepine is useful for pain relief in a variety of facial neuralgias [7] and gabapentin is widely used for neuropathic pain. Voltage-gated sodium channels generate ectopic activity in trigeminal afferents and are believed to play an important role in trigeminal neuropathy [8], which acts by decreasing high-frequency neuronal firing by sodium channel blockade. Anti-convulsants are the main treatment for neuropathic facial pain [8]. Gabapentinoids bind to the $\alpha 2\delta$ -1 subunit of calcium channels (which are overexpressed in neuronal injury), decreasing neurotransmitter release and peripheral ectopy; hence their effectivity in trigeminal neuropathy. Our patient experienced inadequate pain control and

troublesome sedation with these drugs, precluding dose escalation. The facial spasms persisted. Botulinum toxin has been used to treat several neuropathic conditions including trigeminal neuralgia. By preventing the release of neurotransmitters (substance P and calcitonin gene-related peptide), axonal transport, and surface expression of nociceptors, the toxin produces significant and sustained pain relief [9]. This procedure can be performed on an outpatient basis and does not cause any serious adverse effects. Hemifacial tics respond to botulinum toxin injections [10]. To the best of our knowledge, the use of botulinum toxin for treating facial pain due to dolichoectasia has not been reported before. The decrease in NRS scores after botulinum toxin injections with a concomitant decrease in facial tics suggests a beneficial effect of the toxin. The patient was followed up only for 2 months, which was the key limitation of this report. The effect of botulinum toxin lasts for a maximum of 3 months, after which repeated injections might be necessary. Disease progression also varies, with stroke being the most common cause of morbidity and mortality in these patients.

In conclusion, patients presenting with facial pain require clinical examination and appropriate imaging to identify cranial nerve involvement. Botulinum toxin can be a useful adjunct in facial neuropathic conditions and provides symptomatic relief.

AUTHOR ORCID*s*

Prasanna Vadhanan: <https://orcid.org/0000-0001-6060-3880>

AUTHOR CONTRIBUTIONS

Prasanna Vadhanan: Data curation, Investigation, Writing - original draft

CONFLICT OF INTEREST: The author declares no conflict of interests

CONSENT: Informed written consent has been obtained from the patient.

The Institutional Ethics Committee, Vinayaka Missions medical College, has approved the submission of this case report. (Approval Number CS23/03/2022)

REFERENCES

1. Lopez-Navarro ER, Park S, Willey JZ, Gutierrez J. Dolichoectasia: a brain arterial disease with an elusive treatment. *Neurol Sci* 2022; 43: 4901-8.
2. Del Brutto VJ, Ortiz JG, Biller J. Intracranial arterial dolichoectasia. *Front Neurol* 2017; 8: 344.
3. Yu Y, Moseley IF, Pullicino P, McDonald WI. The clinical picture of ectasia of the intracerebral arteries. *J Neurol Neurosurg Psychiatry* 1982; 45: 29-36.
4. Del Brutto VJ, Gutierrez J, Goryawala MZ, Sacco RL, Rundek T, Romano JG. Prevalence and clinical correlates of intracranial dolichoectasia in individuals with ischemic stroke. *Stroke* 2021; 52: 2311-8.
5. Pico F, Labreuche J, Amarenco P. Pathophysiology, presentation, prognosis, and management of intracranial arterial dolichoectasia. *Lancet Neurol* 2015; 14: 833-45.
6. Smoker WR, Corbett JJ, Gentry LR, Keyes WD, Price MJ, McKusker S. High-resolution computed tomography of the basilar artery: 2. Vertebrobasilar dolichoectasia: clinical-pathologic correlation and review. *AJNR Am J Neuroradiol* 1986; 7: 61-72.
7. Do TM, Unis GD, Kattar N, Ananth A, McCoul ED. Neuromodulators for atypical facial pain and neuralgias: a systematic review and meta-analysis. *Laryngoscope* 2021; 131: 1235-53.
8. Gambeta E, Chichorro JG, Zamponi GW. Trigeminal neuralgia: an overview from pathophysiology to pharmacological treatments. *Mol Pain* 2020; 16: 1744806920901890.
9. Park J, Park HJ. Botulinum toxin for the treatment of neuropathic pain. *Toxins (Basel)* 2017; 9: 260.
10. Tambasco N, Filidei M, Nigro P, Parnetti L, Simoni S. Botulinum toxin for the treatment of hemifacial spasm: an update on clinical studies. *Toxins (Basel)* 2021; 13: 881.