

Changes of melanocytic lesions induced by Melanotan injections and sun bed use in a teenage patient with FAMMM syndrome

Graham W. Sivyer, MBBS

Key words: Melanotan, UV tanning, familial atypical mole and malignant melanoma syndrome, atypical mole, dysplastic nevus

Citation: Sivyer GW. Changes of melanocytic lesions induced by Melanotan injections and sun bed use in a teenage patient with FAMMM syndrome. *Dermatol Pract Conc.* 2012;2(3):10. <http://dx.doi.org/10.5826/dpc.0203a10>.

History: Received: December 10, 2012; Accepted: March 31, 2012; Published: July 31, 2012

Copyright: ©2012 Sivyer. This is an open-access article distributed under the terms of the Creative Commons Attribution License, which permits unrestricted use, distribution, and reproduction in any medium, provided the original author and source are credited.

Funding: None.

Competing interests: The authors have no conflicts of interest to disclose.

All authors have contributed significantly to this publication. Written consent to publish this case study has been given by the patient's guardian.

Corresponding author: Graham W Sivyer, M.B.B.S. (Hons), Mermaid Beach Medical Centre, 2506 Gold Coast Highway, Mermaid Beach QLD 4218, Australia

Email: graham.sivyer@ipnet.com.au.

ABSTRACT A 16-year-old girl presented with general skin tanning, multiple dark melanocytic nevi and an enlarging nevus in her left groin following self-injections of Melanotan 2 and attending a UV tanning studio. She had been referred by her GP who was concerned that some of the darkened nevi were potentially malignant.

Case presentation

The patient had skin type 3 according to the Fitzpatrick classification and she had more than 50 moles present on her skin. Her mother had had a level 1 malignant melanoma removed from her abdomen in 2008.

She had been injecting subcutaneous 0.5 mg of Melanotan 2 daily over two months. During this time she was attending a solarium two to three times weekly. At each visit she spent at least 10 minutes on the UV tanning bed. (The patient had purchased the Melanotan 2 via the Internet and obtained needles and syringes from the local needle-exchange program. An ampule of Melanotan 2 is listed on the Internet as containing 10 mg, which is equivalent to 20 injecting doses.)

The patient and her mother had noticed general skin tanning and darkening of multiple moles within three weeks of

commencing Melanotan 2 injections and using the tanning bed. A mole in her left groin had been darkening and also enlarging. The patient was aware that many moles were darkening but that only the one in her groin had been enlarging.

The patient was advised to cease injecting Melanotan and to avoid solariums.

The patient and her mother were advised in the appropriate application of sunscreen. They were both given information about the FAMMM (familial atypical mole and malignant melanoma) syndrome. Due to clinical concern, the history and dermatoscopic appearance (Figures 1 and 2) the enlarging 14 mm x 8 mm pigmented lesion on her left groin was removed (on dermatoscopy, the nevus showed 4 colors, black dots and central blue white structures.). Histopathologically the lesion was diagnosed as dysplastic compound nevus (Figure 3).

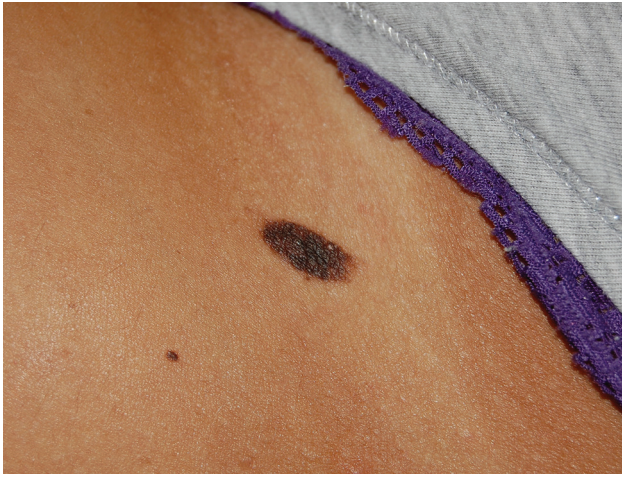

Figure 1. Clinical view of the nevus on the patients' left groin. [Copyright: ©2012 Sivyer.]

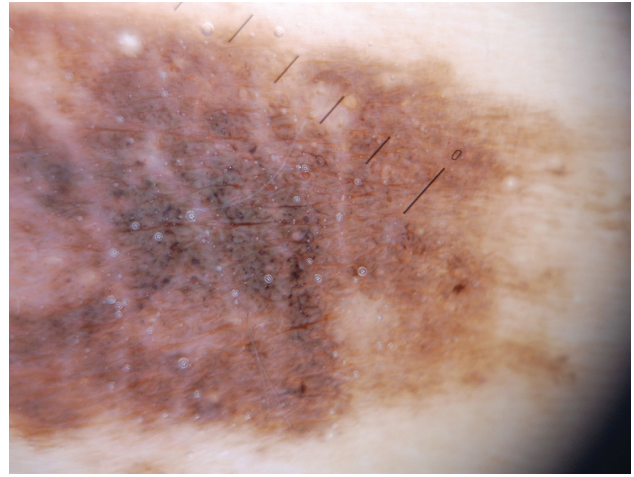


Figure 2. Dermatoscopic view. [Copyright: ©2012 Sivyer.]

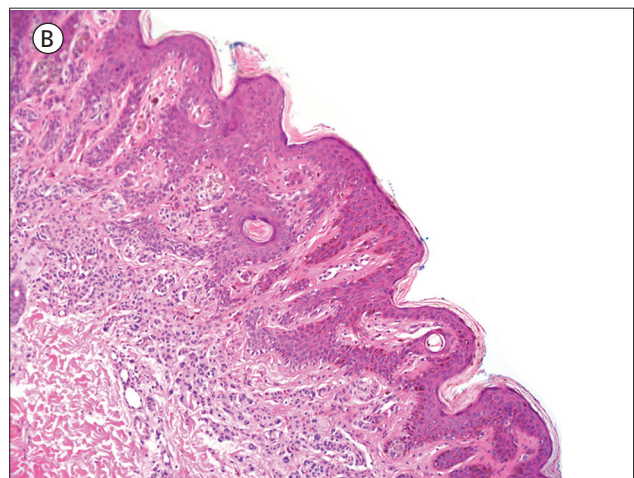
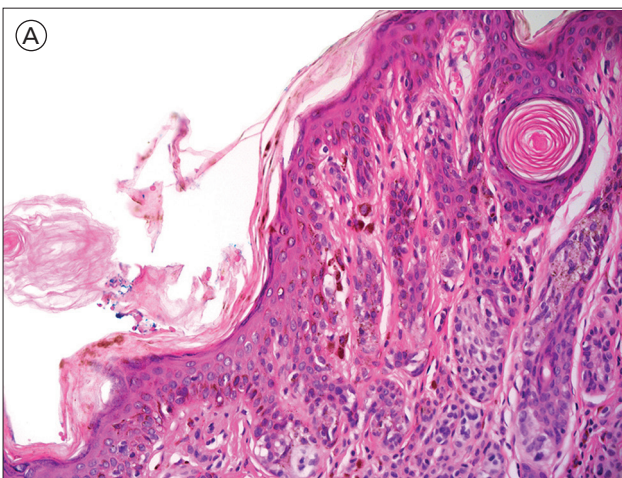


Figure 3. Histopathologic section of the nevus shown in Figure 1 and Figure 2. According to the histopathologic report, the “sections show a dysplastic compound nevus with moderate cytoarchitectural atypia.” [Copyright: ©2012 Sivyer.]

The patient was reviewed with her mother three months later. She ceased the injections of Melanotan 2 but still attended a solarium for at least 10 minutes every two weeks. On clinical examination, the patient's skin color was much paler and the moles had lightened in color (Figure 4A-D). Dermatoscopy of moles on her lower back and left neck were compared at the time of Melanotan 2 injection cessation (initial presentation of the patient) and then three months later (Figure 5). At the end of Melanotan use and sun tanning, the network of the moles appeared dark and thick with central black clumps. There was no evidence of streaming, pseudopods or blue-white structures. At three months, following cessation of Melanotan, the network had lightened considerably. Centrally there were black dots.

Discussion

The patient fulfils the criteria for familial atypical multiple mole melanoma syndrome. The criteria for FAMMM syn-

drome, as defined by the US National Institute of Health Consensus Conference on the diagnosis and treatment of early melanoma, are:

1. The occurrence of melanoma in one or more first-degree or second-degree relatives.
2. The presence of numerous (often greater than 50) melanocytic nevi, some of which are clinically atypical.
3. Many of the associated nevi show certain histological features. (Note: Some clinically atypical moles have normal histology.) [1]

Whilst atypical moles can be inherited or sporadic [2] genetic analysis has suggested an autosomal dominant mode of inheritance; however, genetic studies have not shown consistent data. UV light has been proposed as an initiator and a promoter in the transformation of melanocytes into atypical melanocytes or melanoma.

A meta-analysis concluded that the use of UV tanning beds before the age of 30 years increases the risk of melanoma by 75% [3]. UV light exposure may be required for full expression of the FAMMM syndrome. In Australia and

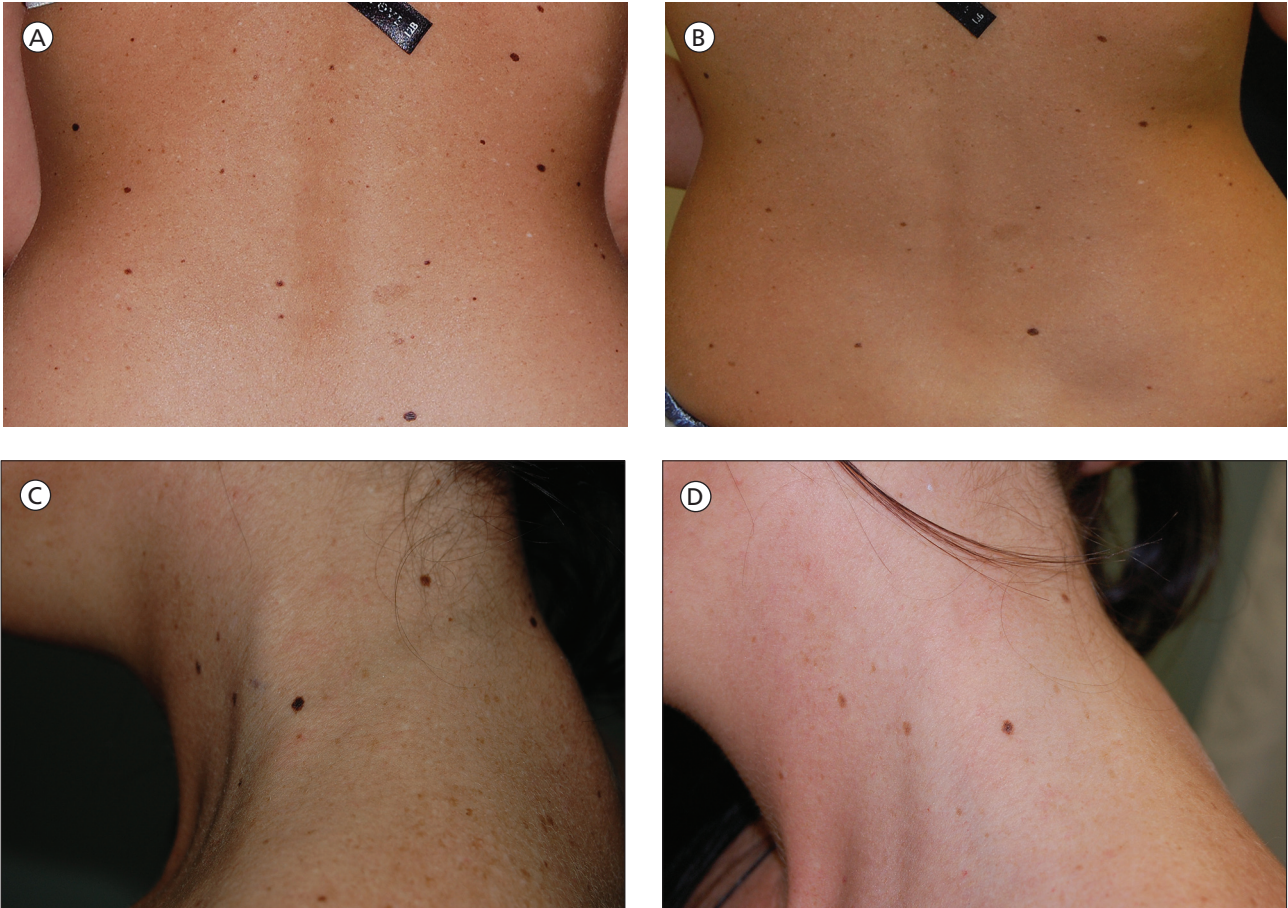


Figure 4. Baseline (A, B) and corresponding follow-up images (C, D) after three months. On clinical examination, the patient's skin color was much paler and the moles had lightened in color. [Copyright: ©2012 Sivyer.]

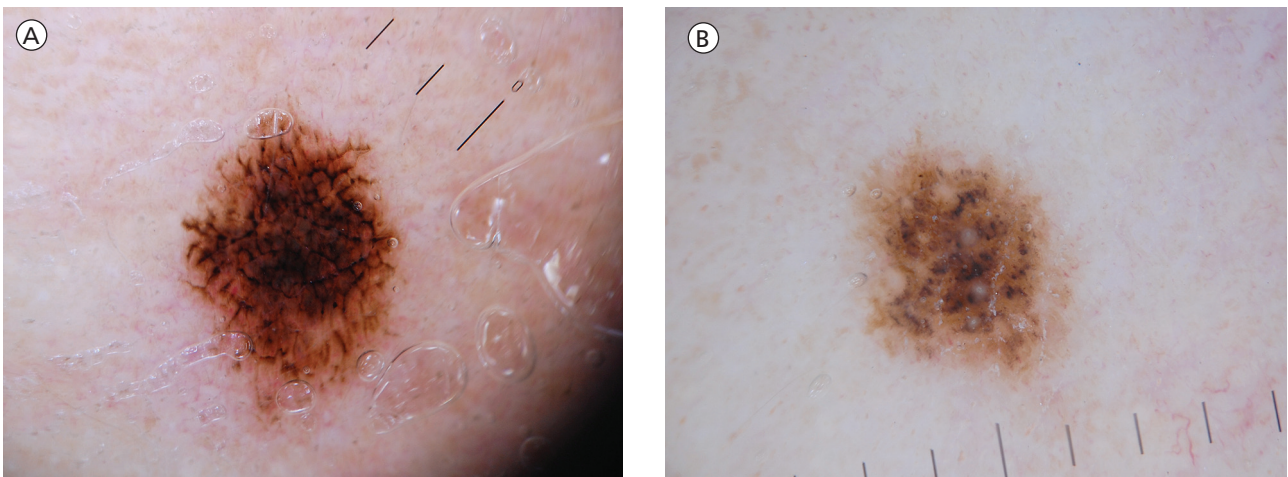


Figure 5. Dermoscopy at baseline (A) and after three-month follow-up (B). The network had lightened considerably. [Copyright: ©2012 Sivyer.]

New Zealand the prevalence of atypical moles has been reported to be 5 to 10% [4]. In some studies of FAMMM the overall lifetime risk of melanoma has been estimated to be 100% [5].

Atypical moles typically are large pigmented lesions usually larger than common moles and frequently measure 5 to 15 mm in diameter. The borders are usually irregular and ill defined. Macular and papular areas (“fried egg” appear-

ance) may be present within a single lesion. Color is highly variable and ranges from tan to dark brown to pink [6]. Several studies have shown that regular cutaneous examinations combined with color photography monitoring of the patient's skin decreases the biopsy rate and leads to earlier diagnosis of melanoma [7]. Changing lesions and any lesion suspicious for melanoma must be removed for histological diagnosis. Patients with atypical moles should be routinely

monitored and have a complete skin examination at least every 12 months. More frequent examinations may be indicated if compounding risk factors exist [8].

Melanotan 1 an alpha MSH analogue (Nle⁴DPhe⁷-Melanocyte-Stimulating Hormone) is a potent melanocortin developed in the 1980's [9]. Afamelanotide or SCENESSE® is undergoing trial for its potential photoprotective effect for patients with various dermatological conditions including vitiligo, erythropoietic protoporphyria, immunosuppressed transplant patients at risk of developing non-melanoma skin cancer, solar urticaria and polymorphic light eruption [10]. Melanotan 2 is a shorter cyclic variant of Melanotan 1 that was developed in the 1990's. Melanotan 2 was found to increase skin pigmentation at lower cumulative doses than Melanotan 1. However, in clinical trials it was found to have more side effects including nausea somnolence and penile erections [11]. Because of these effects (skin tanning, weight reduction due to suppressed appetite and penile erections), Melanotan 2 became known as the "Barbie drug." Lang et al first raised concerns about the potential adverse impact of illegally sold "Melanotan 1 and 2" in an article published in the *British Medical Journal* [12].

A case of eruptive melanocytic nevi following Melanotan injection was reported in the *British Journal of Dermatology* 2009 in which Cousin et al concluded "... we hope to raise awareness of its potential dangers including those associated with sharing needles ... it is important to be aware of the effects of Melanotan on pre-existing MN and as a trigger for new MN ..." [13] Another case of alpha melanocyte stimulating hormone induced eruptive nevi was reported by Cardones et al [14]. In 2011 a report of Melanotan associated melanoma was reported in the *British Journal of Dermatology*. The authors concluded "... as long as the question of carcinogenesis has not been adequately addressed, the harmlessness of melanotan should not be promoted. ..." [15]

Conclusion

This is a case study of a young teenage female with FAMMM syndrome participating in high-risk behavior of regular attendance at UV tanning studios and the potentially hazardous use of Melanotan over a period of two months. Generalized tanning of her skin, darkening of multiple moles, and enlargement of and development of suspicious dermatoscopic changes in one nevus, reported on histology as "dysplastic," occurred.

Two months after the Melanotan injections ceased the generalized tanning diminished and the moles became paler and clinically appeared to regress. This case also illustrates the potential for misdiagnosis in a patient presenting with changing moles because of the pigmentary changes induced by Melanotan and the use of sun beds, but further investigation is required to ascertain the stimuli of mole change apart from UV light.

References

1. NIH Consensus Conference. Diagnosis and treatment of early melanoma. JAMA. 1992;268(10):1314-9.
2. Elder DE, Goldman LI, Goldman SC, Greene MH, Clark WH Jr. Dysplastic nevus syndrome: a phenotypic association of sporadic cutaneous melanoma. Cancer. 1980;46(8):1787-94.
3. International Agency for Research on Cancer Working Group on artificial ultraviolet (UV) light and skin cancer. The association of use of sunbeds with cutaneous malignant melanoma and other skin cancers: a systematic review. Int J Cancer. 2007;120:1116-22.
4. Cooke KR, Spears GF, Elder DE, Green MH. Dysplastic nevi in a population-based survey. Cancer. 1989;63(6):1240-4.
5. Kanzler MH, Swelter SM. Malignant melanoma. J Am Acad Dermatol. 2003;48(5):780-3.
6. Tsao H, Sober AJ. Atypical melanocytic nevi. In: Fitzpatrick T, Freedburg IM, eds. *Fitzpatrick's Dermatology in General Medicine*, Vol 1. 6th ed. New York: McGraw Hill, 2003:906-16.
7. Salopek TG. The dilemma of the dysplastic nevus. Dermatol Clin. 2002;20(4): 617-28.
8. Tripp JM, Kopf AW, Marghoob AA, Bart RS. Management of dysplastic nevi: a survey of fellows of the American Academy of Dermatology. J Am Acad Dermatol. 2002;46(5) 674-82.
9. Sawyer TK, Sanfilippo PJ, Hruby VJ, et al. 4-Norleucine, 7-D-phenylalanine-alpha-melanocyte-stimulating hormone: a highly potent alpha-melanotropin with ultralong biological activity. Proc Natl Acad Sci USA. 1980;77(10):5754-8.
10. Clinuvel. Web site. <http://www.clinuvel.com/en/scenesse/afamelanotide>. Accessed October 4, 2011.
11. Dorr RT, Lines R, Levine N, et al. Evaluation of melanotan-II, a superpotent cyclic melanotropic peptide in a pilot phase-I clinical stud. Life Sci. 1996;58(20): 1777-84.
12. Langan EA, Ramlogan D, Jamieson LA, Rhodes LE. Change in moles linked to use of unlicensed "sun tan jab." BMJ. 2009; 338:b277.
13. Cousen P, Colver G, Helbling I. Eruptive melanocytic naevi following melanotan injection. Br J Dermatol. 2009;161(3):707-8.
14. Cardones AR, Grichnik JM. Alpha melanocyte-stimulating hormone-induced eruptive nevi. Arch Dermatol. 2009;145(4):441-4.
15. Paurobally D, Jason F, Dezfoulian B, Nikkels AF. Melanotan-associated melanoma. Br J Dermatol. 2011;164(6):1403-5.