

## Research article

# Microscopic reconstruction and immunohistochemical analysis of discomalleolar ligament



Michele Runci Anastasi<sup>a,b</sup>, Giuseppina Rizzo<sup>c</sup>, Fabiana Nicita<sup>c,\*</sup>, Alessia Bramanti<sup>a</sup>, Demetrio Milardi<sup>a,c</sup>, Veronica Macchi<sup>d</sup>, Dario Brunetto<sup>c</sup>, Piero Cascone<sup>b</sup>, Alba Arco<sup>c</sup>, Arianna Nicita<sup>e</sup>, Giuseppe Anastasi<sup>c</sup>, Angelo Favalaro<sup>c</sup>

<sup>a</sup> IRCCS Centro Neurolesi "Bonino Pulejo", Messina, Italy

<sup>b</sup> Department of Maxillo-Facial Surgery, "Sapienza" Università di Roma, Via del Policlinico, Roma, Italy

<sup>c</sup> Department of Biomedical and Dental Sciences and Morphofunctional Imaging, University of Messina, Via Consolare Valeria, 1, Messina, Italy

<sup>d</sup> Institute of Human Anatomy, Department of Neurosciences, University of Padova, Italy

<sup>e</sup> Department of Clinical and Experimental Medicine, University of Messina, Italy

## ARTICLE INFO

## Keywords:

Biological sciences  
Cell biology  
Health sciences  
Anatomy  
Medical imaging  
Discomalleolar ligament  
Petrotympic fissure  
Tympanic membrane  
Temporomandibular joint  
Tinnitus

## ABSTRACT

Discomalleolar ligament represents the vestiges of the primitive lateral pterygoid muscle which penetrates in the caudal end of Meckel's cartilage; during the development of newborn, the petrotympanic fissure close almost completely leaving inside the discomalleolar ligament. After entering in tympanic cavity, some fibers of the discomalleolar ligament insert to walls of cavity, other fibers continue with the lateral margin of the anterior ligament and insert in the neck of malleus; in contrast, other Authors demonstrated that discomalleolar ligament is an independent structure inserted in proximity of the neck of the malleus. Although the discomalleolar ligament can be considered as a structure of clinical importance, it is not described by anatomy textbooks. Moreover, it is likely that important correlations between temporomandibular diseases and otological symptoms exist. We have studied discomalleolar ligament submitting the specimens to the 3D volume rendering technique, light microscopy, reconstructing a wide light microscopic fields to analyze the real connection between retrodiscal connective tissue and middle ear, and immunofluorescence methods in order to analyze the consistence of ligament. We have shown two types of connections between TMJ and ear: first, with external acoustic meatus and, second, with middle ear through discomalleolar ligament. The different insertion represents a strong support in order to demonstrate that the TMJ disorders can determine variations of tension that are transmitted on the tympanic membrane provoking tinnitus in according to clinical features. Then, we propose that it is necessary to mention, also in anatomy textbook, the discomalleolar ligament as ligament distance of TMJ.

## 1. Introduction

The middle ear structures and the temporomandibular joint (TMJ) develop by Meckel's cartilage and, in particular malleus and incus, are derived from the first branchial arch, or dorsal end of Meckel's cartilage, which represents the intratympanic portion of this cartilage forming the primary fetal cranio-mandibular articulation [1, 2]. When the base of the fetal skull is formed, this portion separates from the rest of cartilage and it disappears leaving a fibrous tissue that forms the sphenomandibular ligament [3]. Moreover, the cranial attachment of the sphenomandibular ligament represents the tympanomandibular ligament described by

Cameron [4] and Burch [5]. The intra-tympanic portion of the tympanomandibular ligament represents the anterior malleolar ligament [6].

Ontogenetically, the tympanomandibular ligament was formed during the evolution for the passage from the aquatic life of reptiles to terrestrial adaptation, inducing important modification in morphology and physiology of the TMJ. Indeed, the several bones sagittally aligned, forming the reptilian lower jaw and articulating with cranial bone, have migrated toward the middle ear during phylogenesis, transforming themselves in the malleus and the incus [7].

These phylogenetic modifications left vestiges of primitive bones in the humans and can easily be seen in newborn. These vestiges are represented by tympanomandibular ligament which runs through the

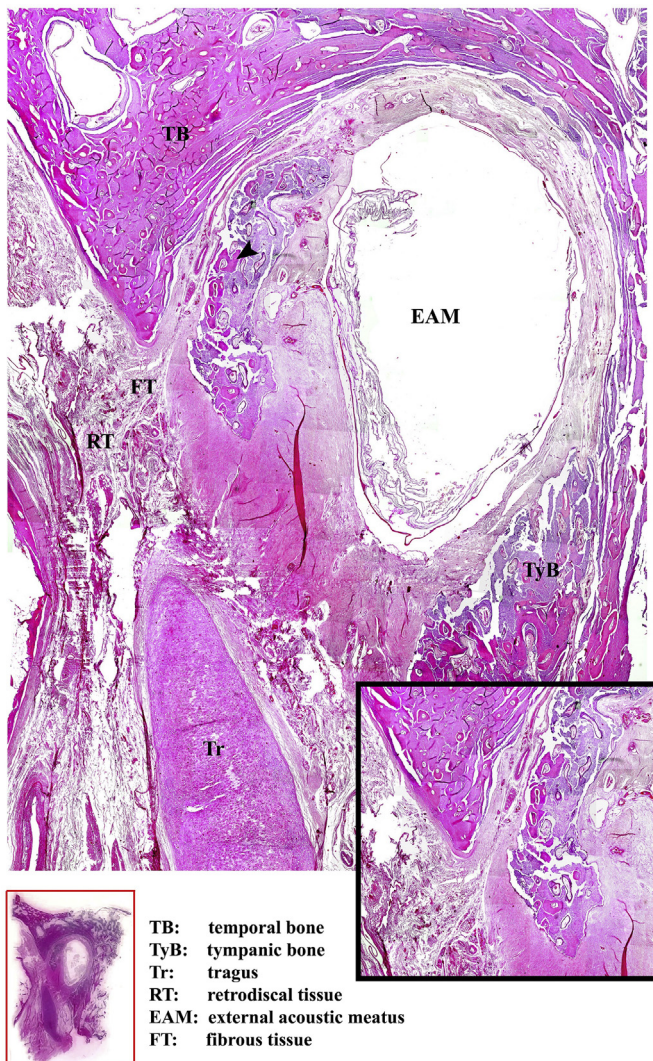
\* Corresponding author.

E-mail address: [fabin92@hotmail.it](mailto:fabin92@hotmail.it) (F. Nicita).

<https://doi.org/10.1016/j.heliyon.2020.e04651>

Received 5 February 2020; Received in revised form 22 July 2020; Accepted 4 August 2020

2405-8440/© 2020 The Authors. Published by Elsevier Ltd. This is an open access article under the CC BY-NC-ND license (<http://creativecommons.org/licenses/by-nc-nd/4.0/>).

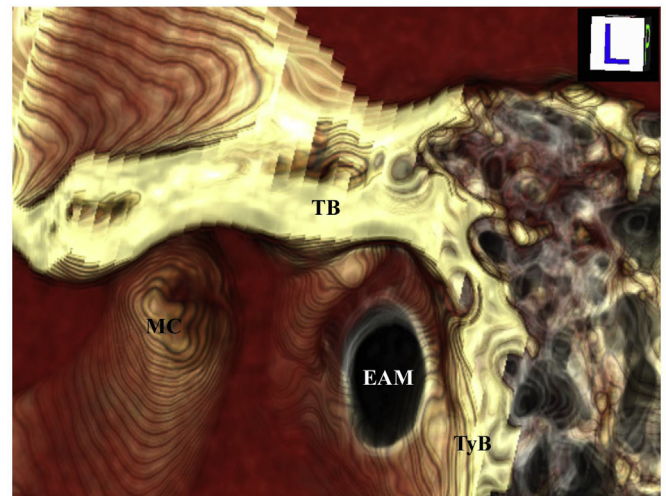


**Figure 1.** 7µm-thick-sections cutted in latero-medial direction and stained with hematoxylin and eosin method; sections were reconstructed in order to observe a wide microscopic field at the level of the lateral portion of external acoustic. The retrodiscal tissue runs from front to back and the fibrous tissue, arising from it, interposes between tragus and temporal bone; is possible to observe also several bone isles (arrowhead) replacing cartilage tissue. In this way, a fissure separating superior and inferior part of temporal bone is formed and the connective tissue continues with submucosa of epithelium of external acoustic meatus. In the black box, the fibrous tissue has been magnified in order to better visualize it. In the red block, the entire section on the glass is shown. TB, temporal bone; TyB, tympanic bone; Tr, tragus; RT, retrodiscal tissues; EAM, external acoustic meatus; FT, fibrous tissue.

posterior region of petrotympanic fissure (Glaserian fissure) open in fetus and in newborn [7].

Another fibrous structure passing through the Glaserian fissure, from the temporomandibular joint to the middle ear, is the discomalleolar ligament, also called, including “tiny ligament” [8], “fascicle of anterior malleolar ligament” [9] or “articular portion of anterior malleolar ligament” [10].

Discomalleolar ligament represents the vestiges of the primitive lateral pterygoid muscle which penetrates in the caudal end of Meckel’s cartilage. During the development of newborn, the petrotympanic fissure closes almost completely leaving inside the discomalleolar ligament [7]. According to Pinto [8] and Rodriguez-Vázquez et al. [6], this ligament is a triangular shaped band of connective tissue and it is located laterally in respect to the sphenomandibular ligament. After entering in tympanic cavity, some fibers of the discomalleolar ligament insert to walls of



**TB:** temporal bone  
**TyB:** tympanic bone  
**EAM:** external acoustic meatus  
**MC:** mandibular condyle

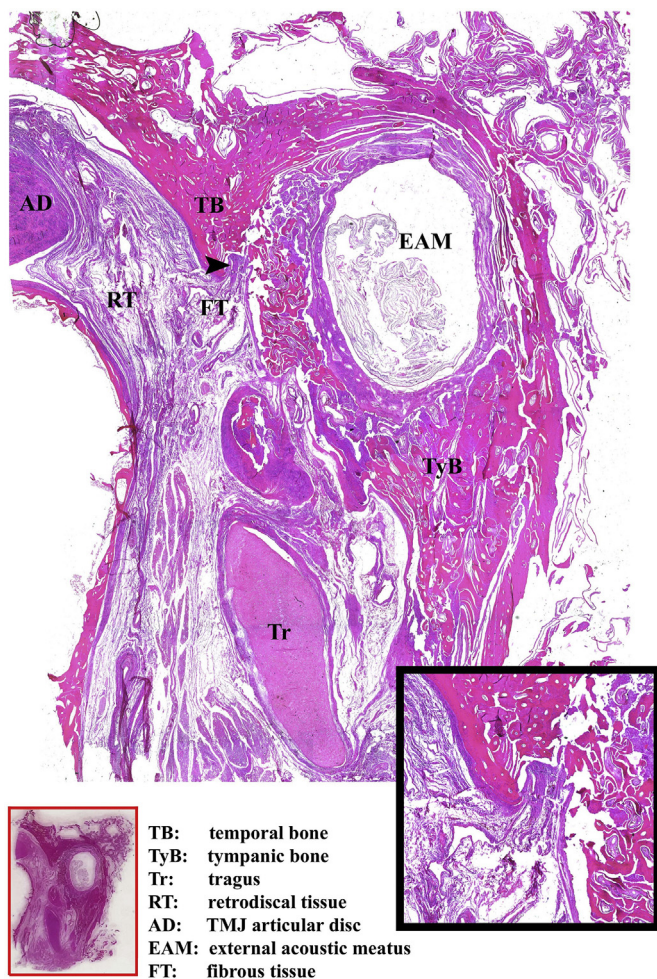
**Figure 2.** 3D volume rendering image corresponding to zone of previous image. It is possible to denote the absence of petrotympanic fissure between temporal bone and external acoustic meatus. TB, temporal bone; TyB, tympanic bone; EAM, external acoustic meatus; MC, mandibular condyle.

cavity, other fibers continue with the lateral margin of the anterior ligament and insert in the neck of malleus [11]. Other Authors demonstrated that discomalleolar ligament is an independent structure inserted in proximity of the neck of the malleus [12]. According to some Authors there is no evidence of this connection [13, 14], whereas other reports sustain that the discomalleolar ligament is better visible in newborn than in adult [7].

Correlations between temporomandibular disorders (TMD) and otological symptoms exist but are still not understood [15, 16]. Connections between TMJ and middle ear play an important clinical key role since the patients affected by TMD suffer otological symptoms as tinnitus, hearing loss, vertigo or earache [17, 18, 19, 20]. In particular, it has been demonstrated that tinnitus is more frequent in patients with TMD than in asymptomatic subjects [20, 21].

Although the discomalleolar ligament can be considered as a structure of clinical importance [22, 23], it is not described by anatomy textbooks [24] and it was always defined in controversial and inconstant ways by Authors in scientific literature. Furthermore, many studies about the morphology and localization of discomalleolar ligament have used the anatomical dissection with classical superior approach through the middle cranial fossa, causing possible macroscopic damages to the morphology of ligament [6, 7, 25]. Other reports on the composition of the discomalleolar ligament have used exclusively microdissection to take this ligament and to study it by light microscopy techniques [26, 27]. The extratympanic portion of the discomalleolar ligament, composed of collagenous fibres and abundant elastic fibres, could play a key role as a tensor of the synovial membrane in movement of the TMJ [27].

To demonstrate the presence, course and extension of the discomalleolar ligament and to obtain clear informations about its histological structure, for the first time, we submitted samples of TMJ and tympanic cavity from human cadavers to several methods. Before the fixation, we carried out a 3D volume rendering analysis to facilitate the identification of the regions. After performing light microscopy to study the structure of ligament, we obtained serial sections in order to identify the real presence and the course of discomalleolar ligament and to reconstruct a wide light microscopic fields, analyzing the real connection between retrodiscal connective tissue and middle ear. Finally, we



**Figure 3.** 7µm-thick-sections cutted in latero-medial direction and stained with hematoxylin and eosin method; sections were reconstructed in order to observe a wide microscopic field in a more medial section in respect to Figure 1. The fissure is tightly closed and fibrous tissue interrupted in correspondence of the bone tissue (black arrowhead); the retrodiscal tissue is better visible behind the articular disc of temporomandibular joint. In the black box, the fibrous tissue has been magnified in order to better visualize it. In the red block, the entire section on the glass is shown. TB, Temporal bone; TyB, tympanic bone; Tr, tragus; RT, retrodiscal tissues; AD, TMJ articular disc; EAM, external acoustic meatus; FT, fibrous tissue.

performed immunofluorescence reaction using antibodies against collagen type I and elastin to study the proteic composition of discomalleolar ligament.

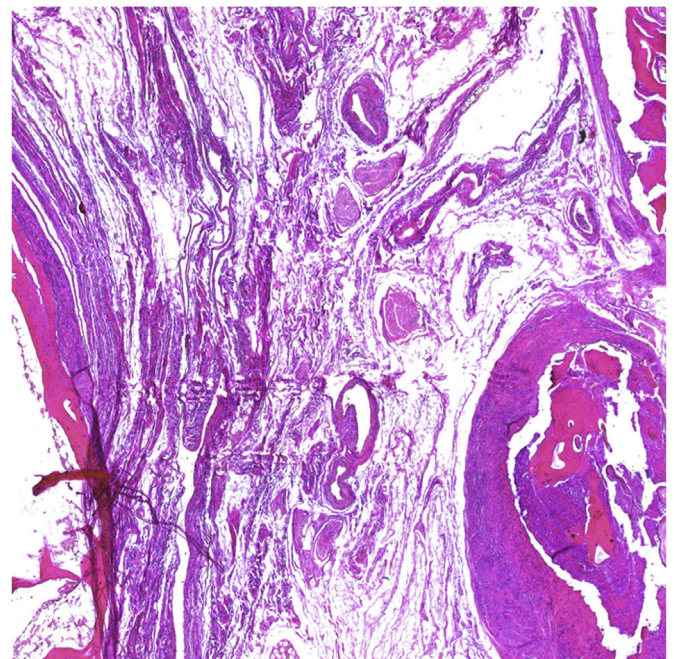
**2. Materials and methods**

The study was performed on 5 frozen intact block specimens of temporomandibular joint and tympanic cavity obtained from fresh adult cadavers (age range: 63–87 years, two males, three female) preserved in the anatomical museum of Department of Biomedical and Dental Sciences and Morphofunctional Images of University of Messina.

Before fixation, CT examinations and 3D volume rendering reconstruction were carried out. Subsequently, the analysis in optical microscopy was performed.

**2.1. CT examination and 3D volume rendering**

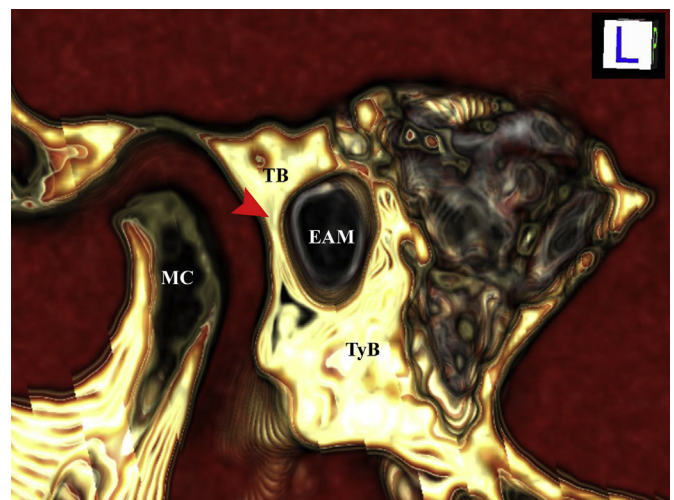
CT examinations were performed with a Somatom Definition scanner (Siemens) using the following parameters: Kv 120, mAs 400, slice thickness of 0.2 mm [28].



**Figure 4.** 7µm-thick-sections cutted in latero-medial direction and stained with hematoxylin and eosin method; a high magnification of previous image shows a massive presence of vessels in retrodiscal tissue.

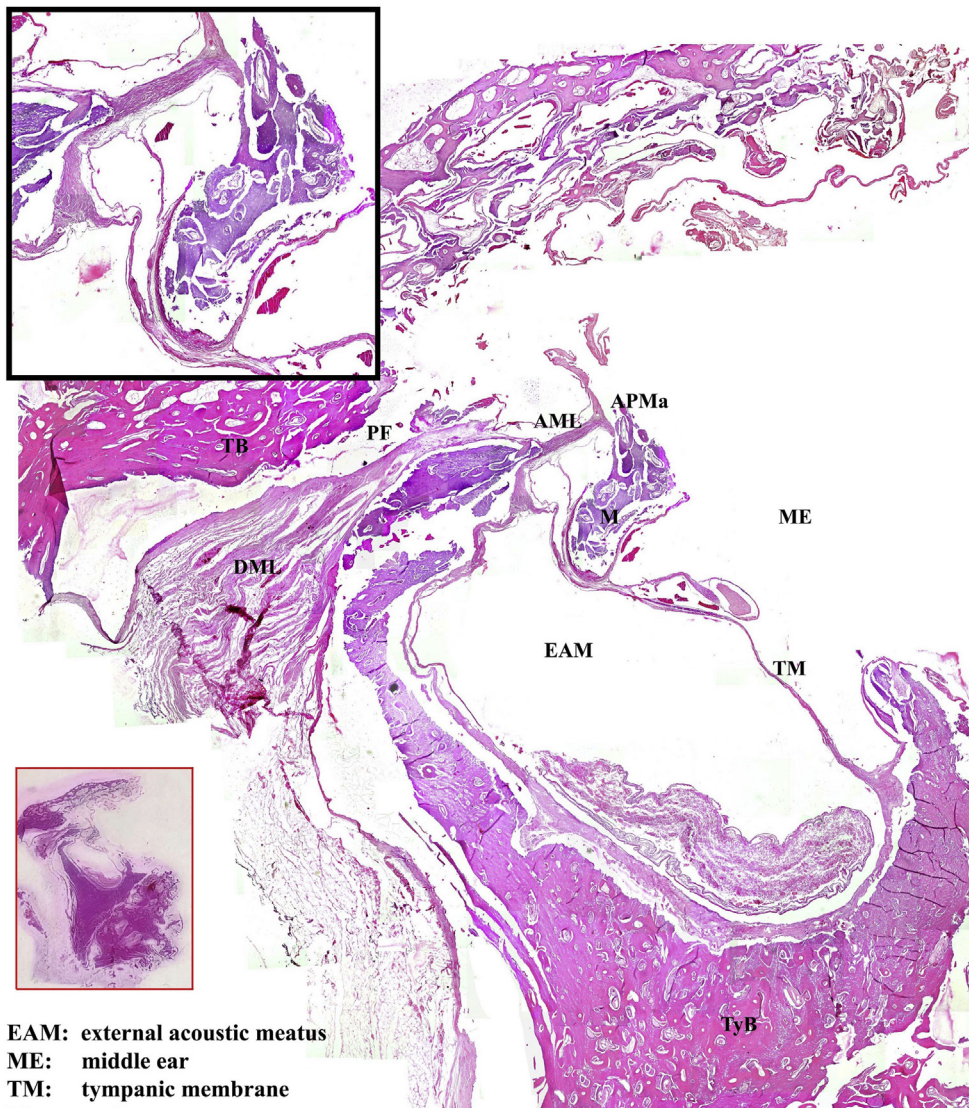
3D reconstruction was performed by using a freeware graphic software package (Osirix 3.3.1, 64-bit). The TMJ structure in the CT images was extracted from the skull by marking manually the regions of interest on the computer. Then, it was stacked to create new volumetric data. Bones, muscles, ligaments and bone cavities, were classified using interval thresholds based on Hounsfield Units (HU).

The transparency was set in relationship to the bone and muscle tissue (100%), or to the bone cavities (0%). The soft tissues were considered opaque or transparent in relationship to the region of interest and due to the tissue in exam.



- TB:** temporal bone
- TyB:** tympanic bone
- EAM:** external acoustic meatus
- MC:** mandibular condyle

**Figure 5.** 3D volume rendering image corresponding to zone of Figure 3. It is possible to visualize a fissure tightly closed. TB, Temporal bone; TyB, tympanic bone; EAM, external acoustic meatus; MC, mandibular condyle.



**Figure 6.** 7 $\mu$ m-thick-sections cutted in latero-medial direction and stained with hematoxylin and eosin method; sections were reconstructed in order to observe a wide microscopic field in a more medial section in respect to Figure 3. At this level a ligament, discomalleolar ligament, is visible in petrotympanic fissure. It has a triangular shape with an inferomedial and a superolateral band; the vertex of triangle enters into bone and it continues with anterior malleolar ligament forming a V shape and continuing with mucosa of external acoustic meatus and the tympanic membrane. In the black box, the V shape of ligament has been magnified in order to better visualize it. In the red block, the entire section on the glass is shown. EAM, external acoustic meatus; ME, middle ear; TM, tympanic membrane; M, malleus; APMs, anterior process of malleus; TyB, tympanic bone; TB, Temporal bone; PF, petrotympanic fissure; AML, anterior malleolar ligament; DML, discomalleolar ligament.

**EAM:** external acoustic meatus  
**ME:** middle ear  
**TM:** tympanic membrane  
**M:** malleus  
**APMa:** anterior process of malleus  
**TyB:** tympanic bone  
**TB:** temporal bone  
**PF:** petrotympanic fissure  
**AML:** anterior malleolar ligament  
**DML:** discomalleolar ligament

The reconstruction was performed with fields of view of  $21 \times 21$  cm, with the result that the voxel size of the in-plane became  $0.41 \times 0.41$  mm with a 512.512 matrix. Once the CT scan was acquired, the data were sent to the workstation Apple Mac Pro Eight-Core 2.8GHz Xeon Desktop Computer, the images were viewed as consecutive axial section and so performed manually for each axial image by editing with Osirix 3.3.1.

## 2.2. Light microscopy

The block specimens were decalcified in 5% nitric acid for 2 months replacing the solution every 15 days. After decalcification, the specimens were trimmed including final part of external acoustic meatus, laterally, ear ossicles, medially; superior and inferior borders have been cut above and below the tympanic cavity respectively.

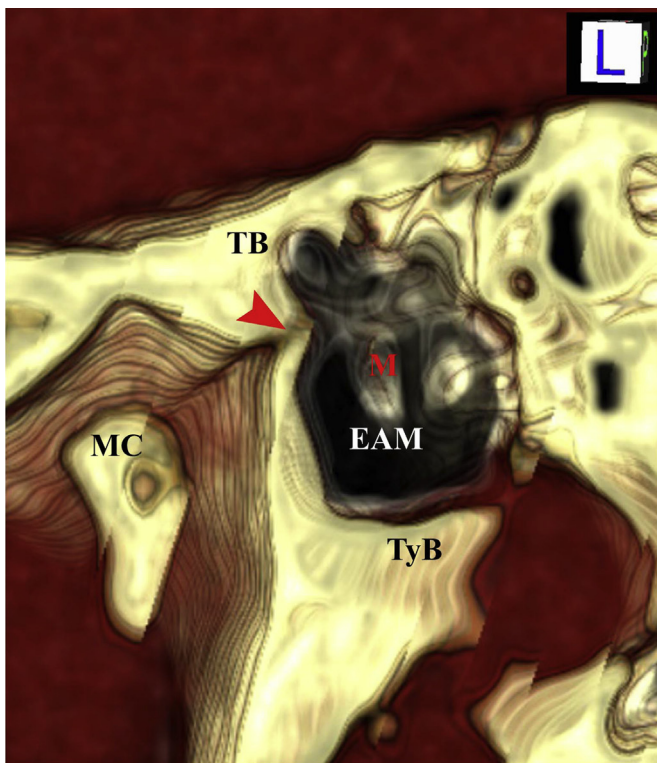
The specimens were fixated overnight in 2.5% glutaraldehyde plus 4% paraformaldehyde in 0.1 M sodium cacodylate buffer at  $4^\circ\text{C}$ , dehydrated in ethanol, and infiltrated with Technovit 9100.

Sections of 7 mm were cut with a LKB Ultratome V (LKB Instruments, Mt Waverley, Victoria, Australia) in lateromedial direction and, subsequently, they were counterstained with hematoxylin and eosin (10 min for hematoxylin and 5 min for eosin). Finally, the sections were examined and photographed with a light microscope Eclipse Ci-L (Nikon Corporation, Tokyo, Japan).

In order to obtain a wide microscopic field, we have photographed adjacent fields on the section combining them. Figure montages were prepared using Adobe Photoshop 7.0 (Adobe System).

## 2.3. Immunofluorescence

Biopsies of discomalleolar ligament were fixated in 3% paraformaldehyde in 0.2 M phosphate buffer, pH 7.4 for 2 h at room temperature. After numerous rinses in 0.2 M phosphate buffer, pH 7.4, and phosphate-buffered saline (PBS), the biopsies were infiltrated with saccharose at 12 and 18% to obtain a gradual substitution of saline solution



**TB:** temporal bone  
**TyB:** tympanic bone  
**EAM:** external acoustic meatus  
**MC:** mandibular condyle  
**M:** malleus

**Figure 7.** 3D volume rendering image corresponding to zone of Figure 6. It is possible to visualize a fissure, corresponding to petrotympanic fissure, clearly opened (red arrowhead). TB, Temporal bone; TyB, tympanic bone; EAM, external acoustic meatus; MC, mandibular condyle; M, malleus.

with glucose solution and to avoid disruption of cellular membranes during successive phases [29]. Then, the specimens were snap-frozen in liquid nitrogen [30]. Sections (20-mm thick) were cut on a cryostat and collected on glass slides coated with 0.5% gelatine and 0.005% chromium potassium sulfate. To block nonspecific binding sites and to permeabilize the membranes, the sections were preincubated with 1% bovine serum albumin, 0.3% Triton X-100 in PBS, for 15 min, at room temperature. Finally, the sections were incubated with primary antibodies [31, 32, 33]. The following primary goat polyclonal antibodies were used, diluted 1:100: anti-collagen type I and anti-elastin. Primary antibodies were detected using Texas Red-conjugated IgG antigoat (Jackson ImmunoResearch Laboratories, West Grove, PA).

The sections were observed and photographed using a Zeiss LSM 5 DUO (Carl-Zeiss, Jena, Germany) tested using META scanning module. For the detection of images, Laser Argon (458 e 488 nm) was utilized. All images were digitized at a resolution of 8 bits into an array of 2048 × 2048 pixels [34, 35].

Optical sections of fluorescence specimens were obtained using HeNe laser (543 nm) and Argon Laser (458) at a 1-min 2 s scanning speed with up to 8. Thick sections (1,50µm) were obtained using a pinhole of 250. Contrast and brightness were established by examining the most brightly labeled pixels and choosing a setting that allowed clear visualization of structural details, while keeping the highest pixel intensities near 200. The same settings were used for all images obtained from other samples had been processed in parallel.

### 3. Results

The intact block specimens, before the infiltration allow to observe, in lateral projection, the real anatomical structures studied in light microscopy (Figure 1). In particular, below the external acoustic meatus (EAM), cartilaginous external acoustic meatus (CEAM) and tragus (T) are clearly appreciable; above the external acoustic meatus, elix (El) is visible and, even above, it is possible to denote the temporal bone (TB). These images are from one of the 5 subjects in order to show a regularity in cut in latero-medial direction of specimens but also other samples gave the same results.

#### 3.1. Light microscopy and 3D volume rendering

Performing 7µm-thick-sections cutted in latero-medial direction and observing a several sections taken at the level of the lateral portion of external acoustic (Figure 1), it is possible to denote that the retrodiscal tissue (RT) runs from front to back and the fibrous tissue (FT), arising from it, passes superiorly and posteriorly interposing between tragus (Tr) and temporal bone (TB); in this region it is possible to observe also several bone isles (arrowhead) replacing cartilage tissue. In this way, a fissure separating superior and inferior part of temporal bone is formed and the connective tissue continues with submucosa of epithelium of external acoustic meatus (EAM).

The corresponding image, obtained by 3D volume rendering, shows a clear architecture of this region visualizing the external acoustic meatus (EAM), tympanic bone (TyB) and temporal bone (TB); furthermore, at this level, is clearly visible the absence of petrotympanic fissure between temporal bone and external acoustic meatus (Figure 2).

In a more medial section (Figure 3), it is possible clearly to denote that the fissure is tightly closed and fibrous tissue (FT) interrupted in correspondence of the bone tissue (black arrowhead); moreover, in this section, the retrodiscal tissue (RT) is better visible behind the articular disc of temporomandibular joint. In a high magnification of this image, it is possible to denote a massive presence of vessels in retrodiscal tissue (Figure 4). The corresponding images, obtained by 3D volume rendering, confirms that, at this level, the fissure is tightly closed (red arrowhead in Figure 5).

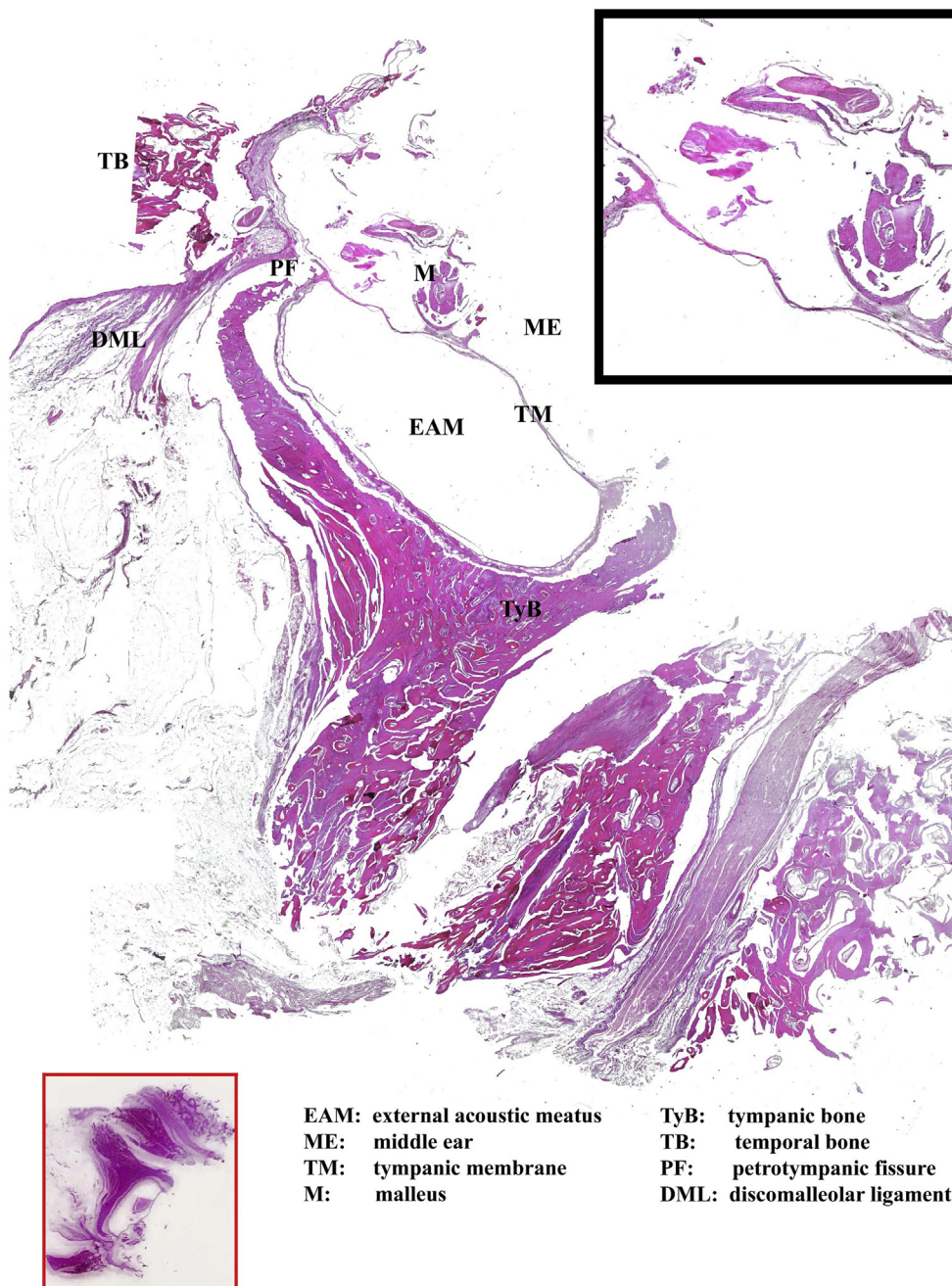
Cutting the specimen more medially (Figure 6), the tympanic membrane (TM) and the malleus (M) clearly are visible; at this level, a ligament, discomalleolar ligament (DML) lies in the petrotympanic fissure (PF) or Glaserian fissure. In particular, this ligament, arising from retrodiscal tissue, has a triangular shape with an inferomedial and a superolateral band; the vertex of triangle enters into bone and it continues with anterior malleolar ligament (AML) whereas a part of it, forming a V shape, continues with mucosa of external acoustic meatus and the tympanic membrane. The 3D volume rendering visualization, allows to confirm the presence of petrotympanic fissure clearly opened (red arrowhead in Figure 7).

Finally, in an even more medial section (Figure 8), it is possible to clearly denote that this ligament no longer inserts at the malleus but it continues both with epithelium of external acoustic meatus and with tympanic membrane. The 3D volume rendering observation denotes a clearly opened petrotympanic fissure (red arrowhead in Figure 9).

#### 3.2. Immunofluorescence

Immunofluorescence single reactions carried out on retrodiscal tissue and discomalleolar ligament, using antibody against collagen type I showed that this proteins presents clear staining pattern distribution localized in entire fibrous tissue; in particular collagen type I is clearly detectable in correspondence of TMJ articular disc (Figure 10A) in its main body (Figure 10B) and inside the cavity (Figure 10C).

Performing immunofluorescence single reactions with antibody against elastin, it is clearly evident the presence of this protein but it is more weaker in respect to collagen type I in external portion of



**Figure 8.** 7 $\mu$ m-thick-sections cutted in latero-medial direction and stained with hematoxylin and eosin method; sections were reconstructed in order to observe a wide microscopic field in a more medial section in respect to Figure 6. Ligament no longer inserts at the malleus but it continues both with epithelium of external acoustic meatus and with tympanic membrane. In the black box, the ligament has been magnified in correspondence of malleus in order to better visualize it. In the red block, the entire section on the glass is shown. EAM, external acoustic meatus; ME, middle ear; TM, tympanic membrane; M, malleus; TyB, tympanic bone; TB, Temporal bone; PF, petrotympanic fissure; DML, discomalleolar ligament.

discomalleolar tissue (Figure 10D), in its main body (Figure 10E) and in portion inside the cavity (Figure 10F).

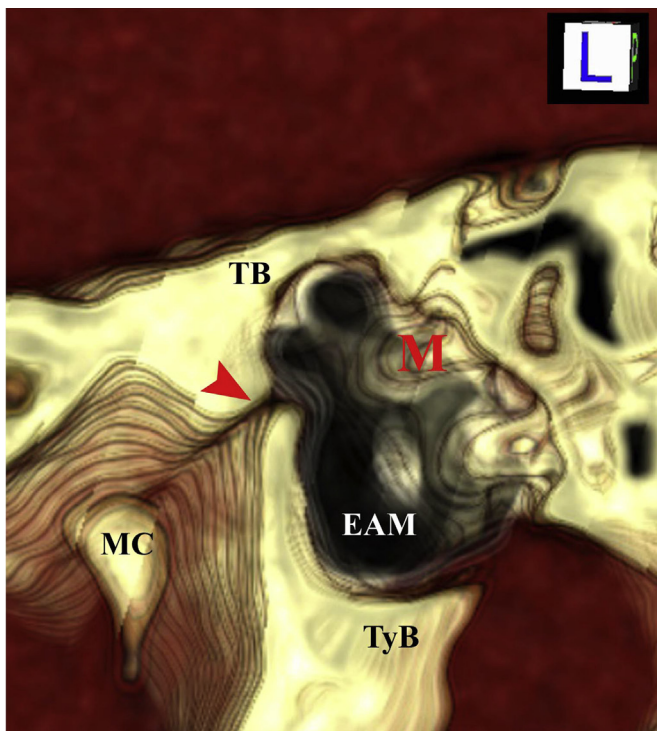
#### 4. Discussion

The discomalleolar ligament, also called mandibular-malleolar ligament, or “tiny” Pinto ligament, was described, for first time, as a structure reflecting the anatomical and ontogenic relationship between the temporomandibular joint and the middle ear [8]. Moreover, this ligament is not described by any classical textbooks of human anatomy [24] but it is mentioned in books of arthroscopy surgery of temporomandibular joint [36, 37].

Several controversial hypotheses about discomalleolar ligament exist regarding its presence, morphology and extension. In relation to its presence, this ligament has been shown during the development [13, 14] and in newborn [7], whereas other Authors have observed a fibrous tract

between the tympanomandibular joint and the middle ear during adult life [11, 38]. Furthermore, other reports have demonstrated that this ligament disappears during postnatal life [39, 40]. Reports about its extension hypothesized that some fibers of the anterior ligament of the malleus run in petrotympanic fissure inserting in the capsule and disc of temporomandibular joint [9], whereas others considered discomalleolar ligament as an individual structure inserting near the neck of the malleus [12].

Nevertheless, all these studies were performed by anatomical dissection with classical superior approach through the middle cranial fossa and this invasive technique could provoke important alterations to ligament with wrong exposition of region and relative internal structures [9, 12]. Our study is based on serial sections of a sample containing TMJ and ear structures, obtaining a wide microscopic field thanks to the 3D volume rendering analysis to facilitate the identification of the regions.



**TB:** temporal bone  
**TyB:** tympanic bone  
**EAM:** external acoustic meatus  
**MC:** mandibular condyle

**Figure 9.** 3D volume rendering image corresponding to zone of previous figure. It is possible to visualize the petrotympanic fissure clearly opened (red arrow-head). TB, Temporal bone; TyB, tympanic bone; EAM, external acoustic meatus; MC, mandibular condyle; M, malleus.

This method allowed us to study contemporarily the presence, the behavior and the structure of discomalleolar ligament. Indeed, our results confirmed the real presence of this ligament, displayed for the first time in its entire extension without invasive techniques, in all specimens. Moreover, we also showed another type of connection that exists between ear and TMJ that is a fibrous structure present between retrodiscal tissue and mucosa of external ear. Then, our histological study, supported also by 3D volume rendering techniques, showed that the prolongation of retrodiscal tissue runs under calcified region of temporal bone penetrating in the outer ear and continuing in the submucosa of external meatus; in this way it is possible to understand the sensation of wadding in subjects with TMD described previously [20]. A further important aspect about the discomalleolar ligament is its tympanic insertion. Some Authors demonstrated that the fibres of this ligament did not reach the malleus or its anterior ligament but were mainly attached to the walls of the petrotympanic fissure [25]; others affirmed that it attached to the neck of the malleus [12]. In the present report, we have demonstrated that the most fibres of discomalleolar ligament, after entering in tympanic cavity through petrotympanic fissure, takes a “V” shape and inserts both on malleus and on annulus of tympanic membrane. This double insertion strongly supports the correlation between discomalleolar ligament and tinnitus in temporomandibular disorders.

About the structure of discomalleolar ligament, its histological aspect was almost ignored. It was demonstrated that the extratympanic portion of the discomalleolar ligament is composed of collagenous fibres with abundant elastic fibres, hypothesizing that it could be a tensor of the synovial membrane in movement of the TMJ [27], whereas other studies hypothesized that only elastic fibers could transmit traction forces

causing mobility of malleolar ossicle [5, 41, 42]. On the contrary, other Authors showed that the collagenous fibres have no ability to stretch and then they can't have a compensatory mechanism to prevent the mobility of malleolar head [26]. Our results show clearly a retrodiscal tissue, with abundant vessels, and a ligamentous structure with several bundles running in parallel fashion and entering in petrotympanic fissure forming the discomalleolar ligament.

In order to individuate the composition of these bundles, an immunofluorescence analysis was performed, for the first time, in these structures, using antibodies against collagen type I and elastin. Our observations have revealed that in discomalleolar ligament is present both collagen type I, more abundant, and elastin, demonstrating that this structure is very dense conferring resistance to entire ligament. In relation to presence, insertion, extension and consistence of ligament is still only partially understood the correlation between temporomandibular disorders and otological symptoms [15, 16, 22, 42, 43, 44]. In particular, it was shown that aural symptoms may depend on mandibular over-closure and posterior displacement of the condyle, resulting in compression of the auriculotemporal nerve, chorda tympani nerve, and other direct or indirect influence of the eustachian tube [45].

Other Authors have hypothesized that the otological symptoms, and in particular tinnitus, can be a symptom of neurological disorders or alteration in blood pressure or temporomandibular disorders [17, 19]; however, it is important to remember that the tinnitus is more evident in patients with TMD than in asymptomatic patients [20]. On this basis, otological symptoms have been correlated with presence of anatomical structures lying in petrotympanic fissure as discomalleolar ligament [8, 46]. Moreover, previously it has been demonstrated that the attempt to move the malleus by pulling the discomalleolar ligament forward at the level of the temporomandibular joint resulted in a slight movement of the malleus and the tympanic membrane in rare cases [25].

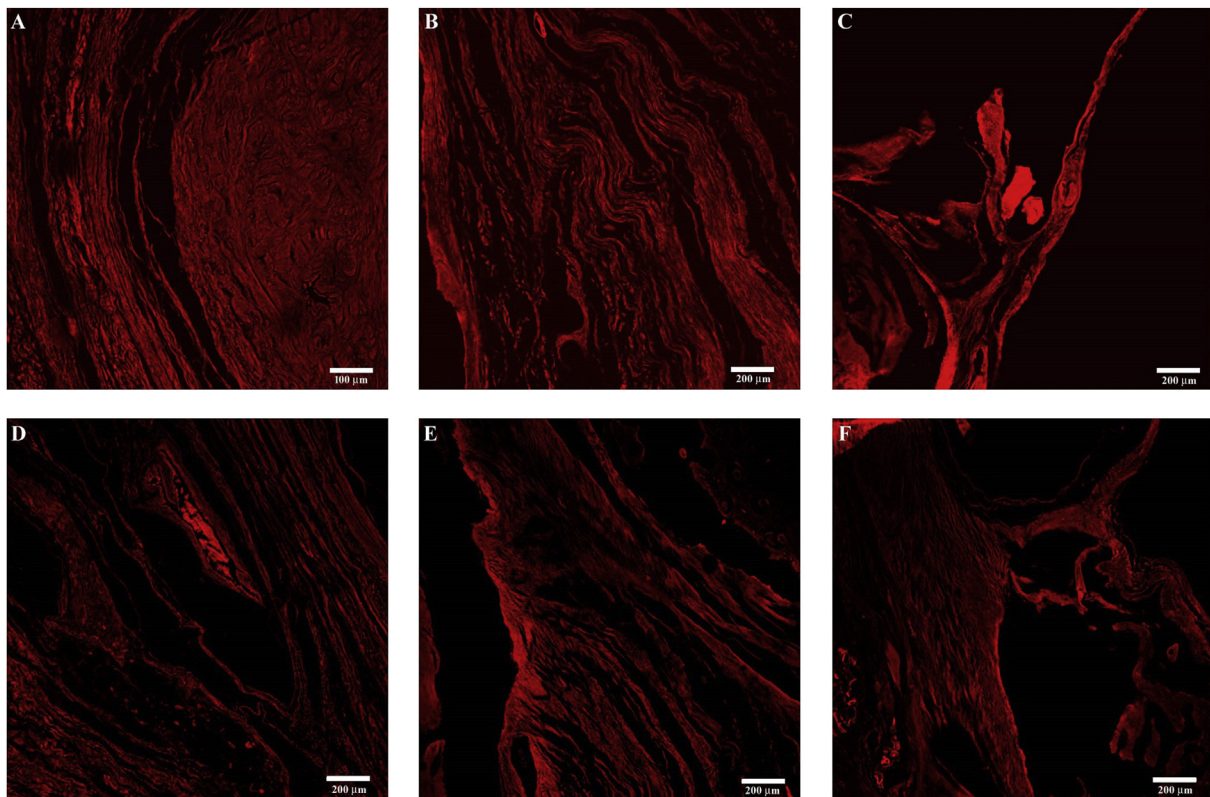
In our opinion, the existence of discomalleolar ligament, its density, its insertion on annulus of tympanic membrane demonstrated in this report, allow us to hypothesize that a minimal variation of tension on ligament in membrane is sufficient to generate different tension of tympanic membrane and then the tinnitus. This is in contrast to other Authors asserting that the tinnitus is generate by movement of tympanic membrane [25]; therefore, it is important to understand that the sound transduction movement involves a displacement of the membrane provoking generation of sound and not a tinnitus. In this way, discomalleolar ligament could have a critical role in pathogenesis of tinnitus since a minimal variation in tension of tympanic membrane, caused by a dislocation of TMJ, could cause several otological symptoms.

In this study, we have shown two types of connections between TMJ and ear: first, with external acoustic meatus and, second, with middle ear through discomalleolar ligament. The different insertion demonstrates that the TMJ disorders can determine variations of tension that are transmitted on the tympanic membrane causing tinnitus, according to the clinical features. Then, we propose that it is necessary to mention, also in anatomy textbook, the discomalleolar ligament as ligament distance of TMJ.

## Declarations

### Author contribution statement

M. Anastasi and P. Cascone: Conceived and designed the experiments.  
 G. Anastasi: Conceived and designed the experiments; Wrote the paper.  
 G. Rizzo: Performed the experiments; Analyzed and interpreted the data.  
 A. Arco and A. Favaloro: Performed the experiments; Wrote the paper.  
 V. Macchi and D. Milardi: Analyzed and interpreted the data.  
 D. Brunetto, F. Nicita, A. Nicita and A. Bramanti: Contributed reagents, materials, analysis tools or data.



**Figure 10.** Compound panel of immunofluorescence findings on ligamentous structures between ear and temporomandibular joint. Single reactions were performed using antibodies against collagen type I (A, B, C) and against elastin (D, E, F). Staining for collagen type I is clearly evident in correspondence of TMJ articular disc (A) in its main body (B) and inside the cavity (C). Staining pattern for elastin is clearly evident, but slightly weaker in respect to collagen type I, in external portion of discomalleolar tissue (D), in its main body (E) and in portion inside the cavity (F).

#### Funding statement

This research did not receive any specific grant from funding agencies in the public, commercial, or not-for-profit sectors.

#### Competing interest statement

The authors declare no conflict of interest.

#### Additional information

No additional information is available for this paper.

#### Acknowledgements

We would like to thank Mr. Sebastiano Brunetto for his help providing light microscopic sections.

#### References

- [1] B.C. Moffett Jr., The prenatal development of the human temporomandibular joint, in: *Contributions to Embryology*, No. Carnegie Institution of Washington Publication 611, Washington DC, 243, 1957, pp. 21–28.
- [2] G.B. Wong, S. Weinberg, J.M. Symington, Morphology of the developing articular disc of the human temporomandibular joint, *J. Oral Maxillofac. Surg.* 43 (1985) 565–569.
- [3] D.H. Enlow, *Handbook of Facial Growth*, second ed., W. B. Saunders Co, London, 1982, p. 362.
- [4] J. Cameron, The cranial attachment of the internal lateral ligament of the lower jaw: with an investigation into the fibrogenesis of this structure, *J. Anat. Physiol.* 49 (1915) 210–215.
- [5] J.G. Burch, The cranial attachment of the sphenomandibular (tympanomandibular) ligament, *Anat. Rec.* 156 (1966) 433–438.
- [6] J.F. Rodriguez-Vazquez, J.R. Mérida-Velasco, J.A. Mérida-Velasco, et al., Anatomical considerations on the discomalleolar ligament, *J. Anat.* 192 (1998) 617–621.
- [7] F. Cheynet, L. Guyot, O. Richard, et al., Discomalleolar and malleomandibular ligaments: anatomical study and clinical applications, *Surg. Radiol. Anat.* 25 (2003) 152–157.
- [8] O.F. Pinto, A new structure related to the temporomandibular joint and middle ear, *J. Prosthet. Dent.* 12 (1962) 95–103.
- [9] J.L. Toledo Filho, N. Luiz Zorzetto, J.A. Caldas Navarro, Structures and relationships of the anterior malleus ligament, *Anat. Anzeiger* 158 (1985) 13–22.
- [10] A. Cesarani, A. Tombolini, E. Fagnani, et al., The anterior ligament of the human malleus, *Acta Anat.* 142 (1991) 313–316.
- [11] R.D. Coleman, Temporomandibular joint: relation of the retrodiskal zone to Meckel's cartilage and lateral pterygoid muscle, *J. Dent. Res.* 49 (1970) 626–630.
- [12] E. Komori, M. Sugisaki, H. Tanabe, et al., Discomalleolar ligament in the adult human, *Cranio* 4 (1986) 300–305.
- [13] L. Furstman, The early development of the human temporomandibular joint, *Am. J. Orthod.* 49 (1963) 672–682.
- [14] R.A. Yuodelis, The morphogenesis of the human temporomandibular joint and its associated structures, *J. Dent. Res.* 45 (1966) 182–191.
- [15] G. Fernandes, J.T. Siqueira, D.A. Godoi Gonçalves, et al., Association between painful temporomandibular disorders, sleep bruxism and tinnitus, *Braz. Oral Res.* 28 (2014) 1–7.
- [16] E. Ferendiuk, K. Zajdel, M. Pihut, Incidence of otolaryngological symptoms in patients with temporomandibular joint dysfunctions, *BioMed Res. Int.* 2014 (2014) 824684.
- [17] E. Douek, Cochleo-vestibular correlates of tinnitus: tinnitogram, *J. Laryngol. Otol.* 4 (1981) 107–110.
- [18] H. Myrhaug, *The Theory of Otosclerosis and Morbus Meniere (Labirintine Vertigo) Being Caused by the Same Mechanism: Physical Irritants and Otognathic Syndrome*, Bergmanns Boktrykkeri A/S, Bergen, Norway, 1981.
- [19] H. Gelb, M.L. Gelb, M.L. Wagner, The relationship of tinnitus to craniocervical mandibular disorders, *Cranio* 15 (1997) 136–143.
- [20] G. Attanasio, A. Leonardi, P. Arangio, et al., Tinnitus in patients with temporomandibular joint disorder: proposal for a new treatment protocol, *J. Cranio-Maxillo-Fac. Surg.* 43 (2015) 724–727.
- [21] N.K. Edvall, E. Gunan, E. Genitsaridi, et al., Impact of temporomandibular joint complaints on tinnitus-related distress, *Front. Neurosci.* 22 (13) (2019) 879.
- [22] B.A. Loughner, L.H. Larkin, P.E. Mahan, Discomalleolar and anterior malleolar ligaments: possible causes of the middle ear damage during temporomandibular joint surgery, *Oral Surg. Oral Med. Oral Pathol.* 68 (1989) 14–22.



- [23] M. Ögütçen-Toller, R.P. Juniper, Audiologic evaluation of the aural symptoms in temporomandibular joint dysfunction, *Cranio* 21 (1993) 2–8.
- [24] L. Testut, A. Latarjet, in: *Trattato di Anatomia Umana*, 1, UTET, 1975, pp. 502–509.
- [25] T. Rowicki, J. Zakrzewska, A study of the discomalleolar ligament in the adult human, *Folia Morphol. (Wars.)* 65 (2006) 121–125.
- [26] M. Sencimen, B. Yalçın, N. Doğan, et al., Anatomical and functional aspects of ligaments between the malleus and the temporomandibular joint, *Int. J. Oral Maxillofac.* 37 (2008) 943–947.
- [27] J.R. Mérida-Velasco, C. de la Cuadra-Blanco, J.J. Pozo Kreiling, et al., Histological study of the extratympanic portion of the discomalleolar ligament in adult humans: a functional hypothesis, *J. Anat.* 220 (2012) 86–91.
- [28] M. Runci, F.S. De Ponte, R. Falzea, et al., Facial and orbital fractures: a fifteen years retrospective evaluation of north east Sicily treated patients, *Open Dent. J.* 11 (2017) 546–556.
- [29] F.S. De Ponte, A. Favalaro, E.N. Siniscalchi, et al., Sarcoglycans and integrins in bisphosphonate treatment: immunohistochemical and scanning electron microscopy study, *Oncol. Rep.* 30 (6) (2013) 2639–2646.
- [30] D. Di Mauro, R. Gaeta, A. Arco, et al., Distribution of costameric proteins in normal human ventricular and atrial cardiac muscle, *Folia Histochem. Cytobiol.* 47 (2009) 605–608.
- [31] G. Anastasi, G. Cutroneo, G. Santoro, et al., Integrins, muscle agrin and sarcoglycans during muscular inactivity conditions: an immunohistochemical study, *Eur. J. Histochem.* 50 (2006) 327–336.
- [32] G. Anastasi, G. Cutroneo, G. Rizzo, et al., Sarcoglycan subcomplex in normal and pathological human muscle fibers, *Eur. J. Histochem.* 51 (2007a) 29–33.
- [33] F.S. De Ponte, G. Cutroneo, R. Falzea, et al., Histochemical and morphological aspects of fresh frozen bone: a preliminary study, *Eur. J. Histochem.* 60 (4) (2016) 2642.
- [34] G. Anastasi, G. Cutroneo, A. Sidoti, et al., Sarcoglycan subcomplex expression in normal human smooth muscle, *J. Histochem. Cytochem.* 55 (2007b) 831–843.
- [35] G. Cutroneo, G. Vermiglio, A. Centofanti, et al., Morphofunctional compensation of masseter muscles in unilateral posterior crossbite patient, *Eur. J. Histochem.* 60 (2016) 86–90.
- [36] D.H. Morgan, L.R. House, W.P. Hall, et al., *Diseases of the Temporomandibular Apparatus. A Multidisciplinary Approach*, Mosby Company, St. Louis Toronto, 1982.
- [37] A.W. Tarro, *TMJ Arthroscopy: A Diagnostic and Surgical Atlas*, J.B. Lippincott Company, Philadelphia, 1993.
- [38] L.E. Smeele, Ontogeny of relationship of human middle ear and temporomandibular (squamosmandibular) joint. I. Morphology and ontogeny in man, *Acta Anat.* 131 (1988) 338–341.
- [39] J.F. Rodríguez-Vázquez, J.R. Mérida-Velasco, J. Jiménez-Collado, Relationships between the temporomandibular joint and the middle ear in human fetuses, *J. Dent. Res.* 72 (1993) 62–66.
- [40] J.R. Mérida Velasco, J.F. Rodríguez Vázquez, J. Jiménez Collado, Anterior tympanic artery: course, ramification and relationship with the temporomandibular joint, *Acta Anat (Basel)* 158 (1997) 222–226.
- [41] J.G. Burch, Activity of the accessory ligaments of the temporomandibular joint, *J. Prosthet. Dent* 24 (1970) 621–628.
- [42] J.S. Broussard Jr., Derangement, osteoarthritis, and rheumatoid arthritis of the temporomandibular joint: implications, diagnosis, and management, *Dent Clin North Am* 49 (2005) 327–342.
- [43] C.A. Ioannides, G.A. Hoogland, The disco-malleolar ligament: a possible cause of subjective hearing loss in patients with temporomandibular joint dysfunction, *J. Maxillofac. Surg.* 11 (1983) 227–231.
- [44] M. Rohlin, P.L. Westesson, L. Eriksson, The correlation of temporomandibular joint sounds with joint morphology in fifty-five autopsy specimens, *J. Oral Maxillofac. Surg.* 43 (1985) 194–200.
- [45] G. Fernandes, D.A. Gonçalves, J.T. de Siqueira, et al., Painful temporomandibular disorders, self reported tinnitus, and depression are highly associated, *Arq Neuropsiquiatr.* 71 (2013) 943–947.
- [46] C.M. Ash, O.F. Pinto, The TMJ and the middle ear: structural and functional correlates for aural symptoms associated with temporomandibular joint dysfunction, *Int. J. Prosthodont.* 4 (1991) 51–57.