

Received: 2019.07.08  
 Accepted: 2019.07.27  
 Published: 2019.09.27

# A Large Mitral Valve Vegetation Not Visualized on Transthoracic Echocardiography: A Case Report

Authors' Contribution:  
 Study Design A  
 Data Collection B  
 Statistical Analysis C  
 Data Interpretation D  
 Manuscript Preparation E  
 Literature Search F  
 Funds Collection G

ABCDEF 1 **Nabil Braitheh**  
 BDEF 2 **Kareem Ebeid**  
 ACD 1 **Alon Yarkoni**  
 CD 3 **Daniel L. Beckles**  
 ACD 4 **Christine Fenlon**

1 Department of Cardiology, United Health Services Hospitals (Heart and Vascular Institute), Wilson Medical Center, Johnson City, NY, U.S.A.  
 2 Department of Internal Medicine, United Health Services Hospitals (Heart and Vascular Institute), Wilson Medical Center, Johnson City, NY, U.S.A.  
 3 Department of Cardiothoracic Surgery, United Health Services Hospitals (Heart and Vascular Institute), Wilson Medical Center, Johnson City, NY, U.S.A.  
 4 Department of Infectious Disease and Internal Medicine, United Health Services Hospitals (Heart and Vascular Institute), Wilson Medical Center, Johnson City, NY, U.S.A.

**Corresponding Author:** Christine Fenlon, e-mail: [Christine.fenlon@nyuhs.org](mailto:Christine.fenlon@nyuhs.org)  
**Conflict of interest:** None declared

**Patient:** Male, 41  
**Final Diagnosis:** Mitral valve endocarditis  
**Symptoms:** Altered mental status • fatigue • fever • myalgia  
**Medication:** —  
**Clinical Procedure:** —  
**Specialty:** Cardiology

**Objective:** Unusual clinical course  
**Background:** Immediate evaluation, diagnosis, and treatment of a patient with infective endocarditis, an infection of the endocardium and/or integral structures found within the heart, is essential to patient survival.

**Case Report:** We present the case of a 41-year-old man who was brought to the Emergency Department for altered mental status and fever. He was found to have methicillin-susceptible *Staphylococcus aureus* (MSSA) bacteremia complicated with severe respiratory failure and metabolic encephalopathy, necessitating intubation and mechanical ventilation. As part of the workup for persistent Staphylococcal bacteremia, 2 transthoracic echocardiograms (TTE) failed to reveal any valvular abnormalities. However, a transesophageal echocardiogram (TEE) detected a 30×30 mm large vegetation on the anterior mitral valve leaflet. Due to the overall size and risk of systemic embolization, and the fact that the patient developed new-onset heart failure, the mitral valve was replaced using an open approach. The patient tolerated the procedure well and was discharged after an extended period of hospitalization.

**Conclusions:** Although the literature emphasizes that the sensitivity of TTE significantly increases when the vegetation size is above 1 cm, it is of utmost importance for clinicians to keep in mind that this is not always true, and clinicians should consider performing a TEE to rule out infective endocarditis whenever a TTE is unable to detect any vegetation in a patient with persistent Staphylococcal bacteremia. This is clearly demonstrated by the present case, in which two TTEs failed to detect a 30×30 mm vegetation.

**MeSH Keywords:** Echocardiography • Echocardiography, Transesophageal • Endocarditis, Bacterial

**Full-text PDF:** <https://www.amjcaserep.com/abstract/index/idArt/918592>

1959 — 3 9



## Background

Infective endocarditis remains a clinically challenging disease that requires a thorough multidisciplinary approach to properly diagnose and effectively treat this potentially fatal infection. Many complications (e.g., new-onset heart failure due to valvular insufficiency, perivalvular abscess leading to heart block, and metastatic embolization) can arise from infective endocarditis; therefore, prompt evaluation, diagnosis, and treatment of a patient with suspected infective endocarditis are essential for patient survival. With the implementation of the modified Duke's criteria, clinicians have the ability to use a systematic approach in a patient with suspected infective endocarditis utilizing the major and minor inclusion criteria. A subset of the major criteria includes evidence of endocardial involvement; specifically, redemonstrations of a vegetation, abscess, or partial dehiscence of a prosthetic valve on echocardiography [1].

Any patient for which there is a clinical suspicion of infective endocarditis should undergo a diagnostic transthoracic echocardiogram (TTE) as soon as possible, depending on the overall clinical presentation and picture. This is especially important in patients with *Staphylococcus aureus* bacteremia due to the increased propensity for patients to develop high-risk complications. TTE is the first-line imaging modality used in patients with suspected infective endocarditis to detect high-risk echocardiographic features. However, TTE may fail to detect some of the high-risk features and complications associated with infective endocarditis.

Valve prostheses, mechanical ventilation, obesity, and annular calcifications of a native valve can all potentially affect image quality, leading to a false-negative result. If the clinical suspicion for infective endocarditis remains high, such as with persistent *Staphylococcus aureus* bacteremia, a transthoracic echocardiogram (TTE) is needed to evaluate for echocardiographic evidence of infective endocarditis. Although TTE is noninvasive and can provide an array of clinically pertinent information, a meta-analysis of 16 studies assessing the diagnostic accuracy of TTE versus TEE as the reference standard found that TTE has a sensitivity of 66% and a specificity of 95% for native valves [2].

TEE has gained great popularity in recent years for its diagnostic accuracy and, most notably, its ability to detect extremely small vegetations. With this clinical context in mind, our case will illustrate the vast differences in detecting vegetations seen in infective endocarditis with these 2 cardiac imaging modalities.

## Case Report

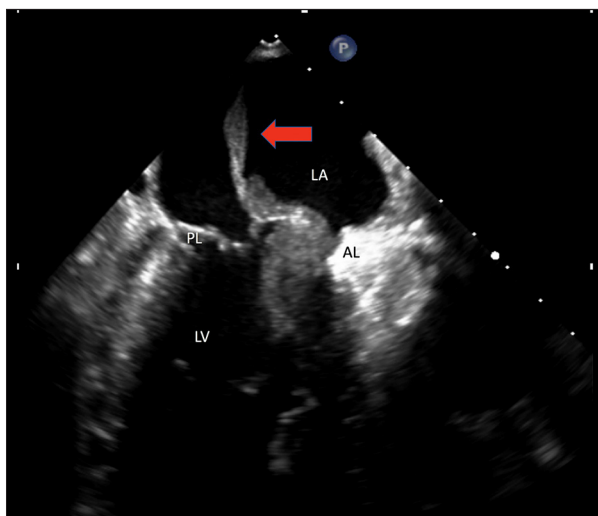
A 41-year-old man was brought to the Emergency Department (ED) by Emergency Medical Services (EMS) for altered mental status (AMS), fever, and diffuse myalgia. Five days prior to arriving at the ED, he began to develop flu-like symptoms, including fever, muscle pain, and severe fatigue. He then experienced a presyncopal event on the day of admission, prompting his fiancée to call EMS.

As a result of his severe AMS, the patient was intubated and placed on mechanical ventilation to protect his airway. His fiancée did not report any nausea, vomiting, diarrhea, or skin rashes prior to his presentation. His past medical history was significant for chronic hepatitis C infection secondary to IV drug use. Surgical and family history were noncontributory. He had no allergies and was not taking any medications. His social history was significant for smoking 15 cigarettes per day for the past 10 years. No current illicit drug abuse was reported.

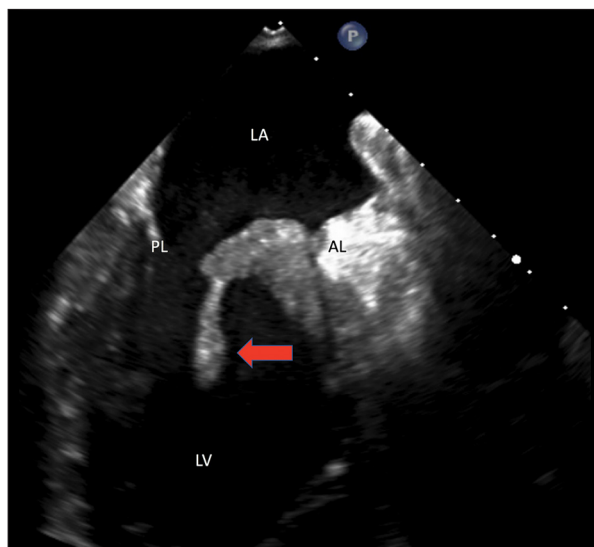
His vital signs prior to intubation revealed a blood pressure of 144/95 mmHg, a heart rate of 130 beats/minute, an oral temperature of 101.9°F, respiratory rate of 18 breaths/minute, and oxygen saturation of 97% on room air. On physical exam, he displayed AMS, appeared toxic, and was in moderate distress. His head exam revealed a normocephalic, atraumatic head with no palpable or visible masses. An oral exam revealed poor dentition. A neck exam revealed no lymphadenopathy, jugular venous distention, or carotid bruits. A cardiovascular exam was significant for tachycardia but normal S1 and S2 with no murmurs or thrills on auscultation. Breath sounds were clear and symmetric bilaterally, without any crackles, wheezes, or rhonchi. His abdomen was soft, nondistended, and non-tender, with normal bowel sounds and no organomegaly. A skin exam showed good turgor and mild cyanosis, but no rashes. The extremities showed no lesions or lower-extremity edema. Radial, posterior tibial, and dorsalis pedis pulses of all 4 extremities were 3+ throughout. A neurological exam revealed the patient was not alert, with a Glasgow coma score of 8.

An EKG showed sinus tachycardia at a ventricular rate of 115, normal axis, and PR duration of 138 milliseconds, with no ST or T wave abnormalities. A chest X-ray did not reveal any acute abnormalities, and a CT head scan showed normal ventricles, sulci, and cisterns, with no significant mass effect or midline shift.

Laboratory studies revealed a white blood cell count of 18 600/mm<sup>3</sup>, hemoglobin of 14.1 g/dL, and platelet count of 50 000/mm<sup>3</sup>. CRP was 24.3 MG/DL and the initial lactic acid was 3.1 mmol/L. Chemistry panel, renal function, liver function, and electrolytes were all within normal limits. Two sets of blood cultures were sent to the laboratory, and the patient



**Figure 1.** Transthoracic echocardiogram (2-chamber view) showing a large 3×3 cm vegetation (red arrow) on the A1/A2 scallop of the anterior mitral valve leaflet, protruding to the left atrium. LV – left ventricle; LA – left atrium; AL – anterior leaflet; PL – posterior leaflet; MV – mitral valve.



**Figure 2.** Transthoracic echocardiogram. Two chamber view. Shows a large 3×3cm vegetation (Red arrow) on the A1/A2 scallop of the anterior mitral valve leaflet that protrudes to the left ventricle. LV – left ventricle; LA – left atrium; AL – anterior leaflet; PL – posterior leaflet; MV – mitral valve.

was started on intravenous ceftriaxone 2 grams every 12 h and intravenous vancomycin 1 gram every 12 h for an initial working diagnosis of meningitis. A lumbar puncture was not done due to the risk of spinal bleed in the setting of thrombocytopenia. The patient was then admitted to the intensive care unit for further management.

One day after presentation, he was successfully extubated since his encephalopathy had improved dramatically, and he was able to tolerate mechanical ventilation weaning trials with no difficulty. Both blood cultures obtained on presentation grew methicillin-susceptible *Staphylococcus aureus* (MSSA) organisms. The patient did not have any skin wounds, lacerations, or oral lesions that could explain the MSSA bacteremia, so the decision then was made to perform a TTE, which produced essentially normal results, with a normal ejection fraction, no signs of valvular heart disease, and no vegetations.

Two sets of repeat blood cultures were obtained 72 h after the original culture on the day of presentation. Despite being on broad-spectrum antibiotics for that time, the blood cultures continued to grow MSSA. This was in conjunction with new CT chest findings showing bilateral diffuse alveolar disease that may represent septic emboli and bilateral pleural effusions, which were obtained due to the patient developing worsening respiratory distress. A repeat TTE was performed, as there was concern that performing a TEE would compromise the respiratory status and require repeat endotracheal intubation due to the fragile respiratory status. The result of the repeat TTE was essentially the same as the first one, and no vegetations

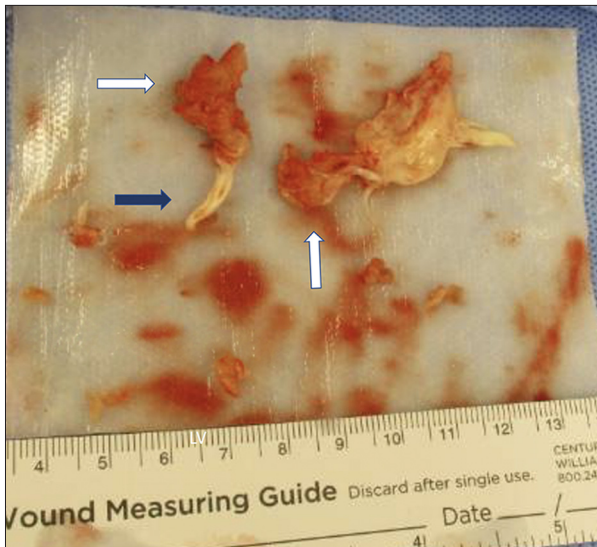
or valvular heart disease were found. After his respiratory status improved, a TEE was finally performed. Remarkably, this showed moderate mitral regurgitation and a 30×30 mm vegetation on the A1/A2 scallop of the anterior mitral valve leaflet, which protruded to the left atrium and ventricle (Figures 1, 2).

Given these remarkable new findings, cardiothoracic surgery was consulted to determine the patient's candidacy for a mitral valve replacement. The surgery was performed 3 weeks after the initial presentation, when the patient's overall critical condition had stabilized. Intraoperatively, a 30-mm mass was seen on the anterior leaflet and involving the endocardium, and on the side of the annulus near the A1 and P1. The mitral valve was deemed to be irreparable, and a #31 pericardial tissue valve was placed after annular and endocardial debridement, along with resection of the abscess (Figure 3).

The patient's blood cultures did not show any growth of organisms after 7 days of IV antibiotics. His mental and clinical status continued to gradually improve and was discharged after 25 days of hospitalization.

## Discussion

According to Duke's criteria, echocardiography is a crucial and determining factor in diagnosing infective endocarditis (IE) [3]. At least one of the following three echocardiographic findings are required to determine positivity for IE: A) Presence



**Figure 3.** Operative view of the mitral valve after resection. The chordae tendineae (blue arrow). Large vegetation (white arrows) divided into 2 parts.

of abscesses; B) Presence of a vegetation defined as an oscillating intracardiac mass implanted on a valve or supporting structures, in the trajectory of regurgitant jets, or implanted in prosthetic material in the absence of any anatomical explanation; or C) New valvular regurgitation or the presence of new partial dehiscence of a prosthetic valve [4].

According to the Infectious Disease Society of America, TTE is recommended as the first-line imaging modality when infective endocarditis is suspected [4]. While the sensitivity of TTE to detect valvular abnormalities that are consistent with endocarditis ranges from 40% to 80%, TEE has a sensitivity of 93–100% [5].

The sensitivity of TTE is also affected by the size of the vegetation. Shapiro et al. reported that TEE was better than TTE at detecting vegetations <10 mm [6]. Utilizing TTE, only 5/12 vegetations were detected, as compared with 12/12 patients with TEE ( $p=0.02$ ) [6]. Moreover, Erbel et al. reported that TTE detected 25% (6/24) of vegetations less than 5 mm, 69.2% (9/13) of vegetations measuring 6–10 mm, and 100% (14/14) of vegetations larger than 11 mm [7].

This case is an important example that does not agree with the aforementioned evidence indicating that a TTE will be able to detect vegetations greater than 10 mm. In this particular case, the two repeat TTE that failed to detect the vegetation could possibly be explained by not only the location of the vegetation on the mitral valve, but also due to the less than ideal acoustic windows obtained due to the patient's body habitus. It is also important to note in Habib et al., and in accordance with the new guidelines, neither TTE nor TEE are 100% sensitive

or specific in detecting a vegetation as part of the diagnostic workup in IE [9].

This update does not factor in the size or location of the vegetation, and taking into account other factors that could affect image quality, including but not limited to operator technique and suboptimal acoustic windows, providers should not hesitate to repeat a TTE and/or TEE if the clinical suspicion for IE remains high. In the present case, the 2 repeat TTE that failed to detect the vegetation could possibly be explained by not only the location of the vegetation on the mitral valve, but also due to the less than ideal acoustic windows obtained due to the patient's body habitus.

One of the most important reasons why an accurate vegetation size measurement should be obtained in IE is due to its prognostic value in predicting future complications. These complications include perivalvular abscess, new-onset heart failure, septic embolization including mycotic aneurysms, and immune-complex mediated renal disease. A study by Mügge et al. revealed that patients with a vegetation diameter greater than 10 mm had a significantly higher incidence of embolic events in comparison to individuals with a vegetation less than 10 mm (47% versus 19%), especially in patients with mitral valve vegetations [8].

In our case, the decision to perform surgery was made due to signs of heart failure and uncontrolled infection (presence of a possible abscess with a 30×30 mm vegetation), as well as for prevention of embolization (more than 15 mm) to systemic organs.

## Conclusions

Although the literature emphasizes that the sensitivity of TTE significantly increases when the vegetation is larger than 1 cm, it is of utmost importance for clinicians to keep in mind that this is not always true and that outliers may exist. Variables that must be taken into account when interpreting the results of a TTE when there is a high clinical suspicion of infective endocarditis include the size and location of the vegetation, operator technique, and anatomical and structural abnormalities [9].

As our case clearly demonstrates, two TTEs obtained in different clinical settings (the first one while the patient was intubated and the second one while the patient was extubated) failed to detect this 30×30 mm vegetation. There are many studies comparing the efficacy and reliability of TTE vs. TEE in fulfilling the diagnostic criteria necessary to diagnose IE, and the vast majority of them unanimously agree that TEE is more sensitive and specific.

## References:

---

1. Baddour LM, Wilson WR, Bayer AS et al: Infective endocarditis in adults: Diagnosis, antimicrobial therapy, and management of complications: A scientific statement for healthcare professionals from the American Heart Association. *Circulation*, 2015; 132(15): 1435–86
2. Bai AD, Steinberg M, Showler A et al: Diagnostic accuracy of transthoracic echocardiography for infective endocarditis findings using transesophageal echocardiography as the reference standard: A meta-analysis. *J Am Soc Echocardiogr*, 2017; 30(7): 639–46
3. Li JS, Sexton DJ, Mick N et al. Proposed modifications to the Duke criteria for the diagnosis of infective endocarditis. *Clin Infect Dis*, 2000; 30(4): 633–38
4. Mermel LA, Allon M, Bouza E et al: Clinical practice guidelines for the diagnosis and management of intravascular catheter-related infection: 2009 Update by the Infectious Diseases Society of America. *Clin Infect Dis*, 2009; 49(1): 1–45
5. Fowler VG Jr., Li J, Corey GR et al: Role of echocardiography in evaluation of patients with *Staphylococcus aureus* bacteremia: Experience in 103 patients. *J Am Coll Cardiol*, 1997; 30: 1072–78
6. Shapiro SM, Young E, De Guzman S et al: Transesophageal echocardiography in diagnosis of infective endocarditis. *Chest*, 1994; 105: 377–82
7. Erbel R, Rohmann S, Drexler M et al: Improved diagnostic value of echocardiography in patients with infective endocarditis by transesophageal approach. A prospective study. *Eur Heart J*, 1988; 9: 43–53
8. Mügge A, Daniel WG, Frank G, Lichtlen PR: Echocardiography in infective endocarditis: Reassessment of prognostic implications of vegetation size determined by the transthoracic and the transesophageal approach. *J Am Coll Cardiol*, 1989; 14(3): 631–38
9. Sekar P, Johnson JR, Thurn JR et al: Comparative sensitivity of transthoracic and transesophageal echocardiography in diagnosis of infective endocarditis among veterans with *Staphylococcus aureus* bacteremia. *Open Forum Infect Dis*, 2017; 4(2): ofx35