


# An Unusual Case of Drug-Induced Thrombocytopenia

Journal of Investigative Medicine High Impact Case Reports  
Volume 8: 1–4  
© 2020 American Federation for Medical Research  
DOI: 10.1177/2324709620947891  
journals.sagepub.com/home/hic  


Shiyu Wang, MD<sup>1</sup>, Khalid Sawalha, MD<sup>1</sup>, and Atif Khan, MD<sup>1</sup>

## Abstract

Drug-induced thrombocytopenia (DIT) is a differential diagnosis for consideration when acute thrombocytopenia is encountered in the outpatient or inpatient setting. The mechanism of thrombocytopenia induced by different antiplatelet therapies varies. DIT may occur due to antibody formation following the exposure to a drug, or naturally occurring preexisting antibodies may produce rapid-onset thrombocytopenia when a drug molecule binds to a platelet receptor inducing a conformational change thus rendering it to be an antigen target for naturally occurring antibodies. A 66-year-old female with history of hypertension presented with non-ST elevation myocardial infarction, had drug eluting stent placed in first obtuse marginal artery of left circumflex coronary artery. Started on antiplatelet medications aspirin 81 mg, ticagrelor 90 mg (which was later transitioned to clopidogrel 75 mg), as well as tirofiban 12.5 mg (for 12 hours only). Tirofiban is a GP IIb/IIIa antagonist, other drugs in this class have been documented to induce thrombocytopenia as well, but rates for tirofiban appear to be the highest, the reason is unclear. These antibodies are thought to be either naturally occurring or induced from conformational changes to GP IIb/IIIa binding site after binding to the GP IIb/IIIa receptor, binding of these drugs to the receptor precipitates an epitope much more specific for platelet surface antigens. Tirofiban and clopidogrel/ticagrelor can cause thrombocytopenia, but onset in this case is unusual: acute antibody reaction would be expected within hours, not delayed 30 hours after starting antiplatelet medication, and nonacute reaction would present 1 to 2 weeks out.

## Keywords

thrombocytopenia, tirofiban, GP IIb/IIIa antagonist

## Introduction

Drug-induced thrombocytopenia is a differential diagnosis for consideration when acute thrombocytopenia is encountered in the outpatient or inpatient setting. Percutaneous coronary intervention is a common procedure, following which patients require antiplatelet therapy to prevent acute thrombosis at the site of stent placement or balloon angioplasty. The mechanism of thrombocytopenia induced by different antiplatelet therapies varies. The timing of the onset of thrombocytopenia since the procedure and the antiplatelet therapy's underlying pathophysiologic mechanism, management, and resolution of thrombocytopenia are key data points that help implicate the drug responsible for the clinical manifestation of thrombocytopenia.

Drug-induced thrombocytopenia may occur due to antibody formation following the exposure to a drug, and this generally takes 5 to 7 days. Naturally occurring preexisting antibodies may produce rapid-onset thrombocytopenia when a drug molecule binds to a platelet receptor inducing a conformational change thus rendering it to be an antigen target for naturally occurring antibodies. Such platelets are cleared from the circulation rapidly, resulting in marked

thrombocytopenia in certain cases that could be potentially life threatening.<sup>1</sup>

## Case

A 66-year-old female with history of hypertension presented with non-ST elevation myocardial infarction, had drug eluting stent placed in first obtuse marginal artery of left circumflex coronary artery. Started on antiplatelet medications aspirin 81 mg, ticagrelor 90 mg (which was later transitioned to clopidogrel 75 mg), as well as tirofiban 12.5 mg (for 12 hours only). Platelet count was 195 000 along with hemoglobin 12.0 and white blood cells 7.6 of the morning of procedure, dropped to 15 000 platelet count, 11.6 hemoglobin and 12.6 white blood cell count the next morning. On physical

<sup>1</sup>White River Health System, Batesville, AR, USA

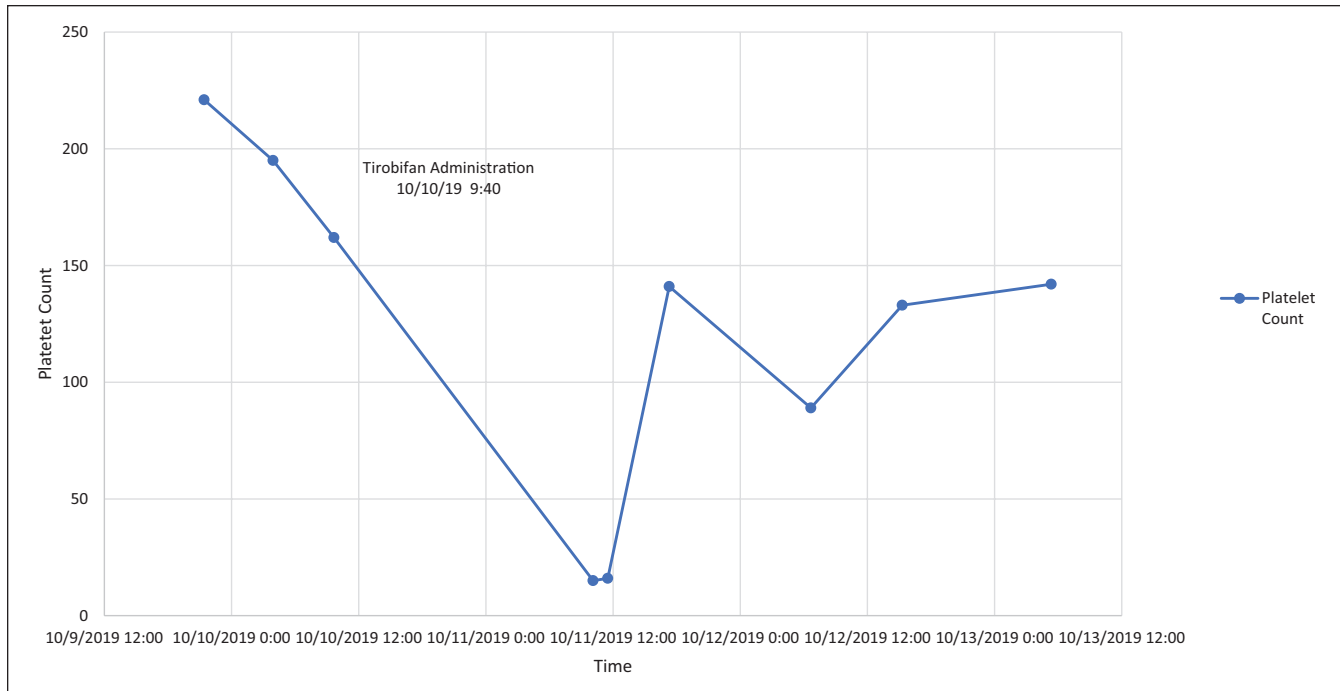
Received June 13, 2020. Revised July 12, 2020. Accepted July 14, 2020.

### Corresponding Author:

Shiyu Wang, MD, 4323 Harrison Street, Apartment 61, Batesville, AR 72501, USA.

Email: shiyuwang0@gmail.com





**Figure 1.** Platelet count over course of admission.

**Table 1.** Platelet and Blood Counts Throughout Admission.

Time	Platelet count (K/ $\mu$ L)	White blood cells (K/ $\mu$ L)	Hemoglobin (g/dL)	Hematocrit (%)
October 9, 2019; 21:25	221	8.6	12.8	40.0
October 10, 2019; 3:55	195	7.6	12.0	37.4
October 11, 2019; 10:07	15	12.6	11.6	35.9
October 11, 2019; 11:30	16	12.7	11.3	35.1
October 11, 2019; 17:18	141	11.4	10.6	33.4
October 12, 2019; 6:40	89	7.9	10.5	33.9
October 12, 2019; 15:17	133			
October 13, 2019; 5:21	142	8.6	10.7	33.5

examination, multiple petechiae on all extremities, bruising, and active bleeding at intravenous sites on arms were noted. At this time, differential diagnoses included disseminated intravascular coagulation, thrombotic thrombocytopenic purpura, immune thrombocytopenia, or heparin-induced thrombocytopenia. Due to active bleeding resulting in blood loss anemia, 2 units of platelets were transfused, following transfusion, patient was observed, and platelet count remained adequate and even increased the following day. Platelet count was 141 000, with hemoglobin of 10.6 and white blood cell count of 11.4 that night. The next morning, platelet count dropped to 89 000 with hemoglobin of 10.5 and white blood cell count of 7.9, but no more platelets were transfused, and platelet count 133 000 that afternoon, final platelet count was 142 000 with hemoglobin of 10.7 and white blood cell count of 8.6 next morning after which the patient was discharged on clopidogrel and aspirin (Figure 1 and Table 1). Peripheral blood smear and laboratory findings

during nadir of thrombocytopenia showed thrombocytopenia with large platelets, no platelet clumps or satellitosis, normal red blood cell morphology, no immature blasts, haptoglobin normal 67 mg/dL, D-dimer elevated to 0.64  $\mu$ g/mL FEU, and lactate dehydrogenase to elevated 1257 U/L (Table 2). Patient followed-up with hematologist 1 week after discharge.

## Discussion

The most likely agent to have induced the aforementioned case is tirofiban; there are documented cases of tirofiban drug-induced thrombocytopenia with proposed mechanism due to drug-dependent antibody formation (Table 3). Tirofiban is a GP IIb/IIIa antagonist; other drugs in this class have been documented to induce thrombocytopenia as well, but rates for tirofiban appears to be the highest, and the reason is unclear. These antibodies are thought to be either naturally occurring or induced from conformational changes to GP IIb/IIIa

**Table 2.** Laboratory Results to Rule Out Other Etiologies of Thrombocytopenia.

Time	Lactate dehydrogenase, normal (313-618 U/L)	D-dimer, normal (0.00-0.48 µg/mL FEU)	Haptoglobin, normal (43-212 mg/dL)	Peripheral blood smear
October 11, 2019; 11:30	1257	0.64	67	Thrombocytopenia with large platelets, negative for platelet clumps or satellitosis
October 12, 2019; 6:40	Heparin-induced platelet antibodies: 0.188 (normal <0.3)		Heparin-induced platelet antibodies ELISA: negative	

Abbreviation: ELISA, enzyme-linked immunosorbent assay.

**Table 3.** Previous Cases of Tirofiban Drug-Induced Thrombocytopenia.

Age and sex of patient in cases <sup>a</sup>	Initial platelet count	Post-tirofiban platelet count	Time (hours) <sup>b</sup>
50 years/Male <sup>3</sup>	246	<1	24
44 years/Male <sup>4</sup>	411	7	18
69 years/Female <sup>5</sup>	224	2	<24
79 years/Male <sup>6</sup>	233	6	23
68 years/Male <sup>7</sup>	234	3	8
58 years/Male <sup>8</sup>	403	7	7
50 years/Male <sup>9</sup>	265	5	4

<sup>a</sup>Represents patients in previous documented cases of tirofiban drug-induced thrombocytopenia.

<sup>b</sup>Represents time in hours for tirofiban drug-induced thrombocytopenia to manifest.

binding site after binding to the GP IIb/IIIa receptor; binding of these drugs to the receptor precipitates an epitope much more specific for platelet surface antigens. If there are no preformed antibodies, but epitopes induce antibody formation, thrombocytopenia onset is usually within 5 to 7 days of starting tirofiban, and thrombocytopenia is generally less severe. If antibodies are naturally occurring, which we believe to be the case for our patient, thrombocytopenia is rapid (onset within <24 hours) and severe, but also resolves quickly (usually within a day) after cessation of inducing drug. This rapid fall and rise of platelets is due to preformed antibodies binding platelets in presence of tirofiban, but when drug is stopped and cleared from circulation, bound platelets are cleared via antibody-mediated consumption by reticulo- cyte endothelial system, and new unbound platelets do not have epitopes that are recognized by antibodies, and thus the thrombocytopenia abates.<sup>2</sup>

## Conclusion

Tirofiban and clopidogrel/ticagrelor can cause thrombocytopenia, but onset in this case is unusual: acute antibody reaction would be expected within hours, not delayed 30 hours after starting antiplatelet medication, and nonacute reaction would present 1 to 2 weeks out. Other etiologies on differential were not supported by peripheral blood smear or laboratory findings, such as thrombotic thrombocytopenic purpura, disseminated intravascular coagulation, and heparin-induced thrombocytopenia (Table 2). Thus, we believe this case to be an abnormal presentation of drug-induced immune thrombocytopenia. It is important to keep this adverse reaction

of antiplatelet class drugs in mind especially when newly started for a patient, and to appropriately monitor and manage when thrombocytopenia does occur with transfusion or drug cessation.

## Acknowledgments

We would like to thank White River Health System and White River Medical Center Hematology/Oncology clinic for providing resources to make this project possible.

## Declaration of Conflicting Interests

The author(s) declared no potential conflicts of interest with respect to the research, authorship, and/or publication of this article.

## Funding

The author(s) received no financial support for the research, authorship, and/or publication of this article.

## Ethics Approval

Our institution does not require ethical approval for reporting individual cases or case series.

## Informed Consent

Written informed consent was obtained from the patient(s) for their anonymized information to be published in this article.

## References

1. George JN, Aster RH. Drug-induced thrombocytopenia: pathogenesis, evaluation, and management. *Hematology Am Soc Hematol Educ Program*. 2009;2009:153-158.

2. Junghans U, Seitz RJ, Aulich A, Freund HJ, Siebler M. Bleeding risk of tirofiban, a nonpeptide GPIIb/IIIa platelet receptor antagonist in progressive stroke: an open pilot study. *Cerebrovasc Dis.* 2001;12:308-312.
3. Rahman N, Jafary FH. Vanishing platelets: rapid and extreme tirofiban-induced thrombocytopenia after percutaneous coronary intervention for acute myocardial infarction. *Tex Heart Inst J.* 2010;37:109-112.
4. Panduranga P, Sulaiman K. Severe thrombocytopenia following tirofiban infusion. *Indian J Pharmacol.* 2011;43:726-728.
5. Muhammad SR, Amna SA, Kanna P, et al. Tirofiban induced thrombocytopenia: a rare but severe adverse effect. *J Community Hosp Intern Med Perspect.* 2020;10:171-173.
6. Meghrajani V, Sabharwal N, Namana V, et al. A case of hyperacute severe thrombocytopenia occurring less than 24 hours after intravenous tirofiban infusion. *Case Rep Hematol.* 2018;2018:4357981.
7. Li Y, Xu Q, Guo X. Thromboembolic events secondary to tirofiban-induced thrombocytopenia being treated with thrombopoietin: a case report. *Exp Ther Med.* 2016;12:1177-1180.
8. Sakellariou D, Pastromas S, Koulouris S, Manolis AS. First report of tirofiban-induced anemia (found in combination with severe thrombocytopenia). *Tex Heart Inst J.* 2009;36:55-57.
9. Yurtdaş M, Yaylali YT, Aladağ N, Ozdemir M, Atay MH. Acute serious thrombocytopenia associated with intracoronary tirofiban use for primary angioplasty. *Case Rep Med.* 2014; 2014:190149.