

[ CASE REPORT ]

## Efficacy of Lacosamide in a Patient with Refractory Generalized Epilepsy Based on Video Electroencephalography

Hidetada Yamada<sup>1</sup>, Shuichiro Neshige<sup>1,2</sup>, Takeo Shishido<sup>1,3</sup>, Hiroki Ueno<sup>1,2</sup>, Tomohiko Ohshita<sup>1</sup>, Hiroyuki Morino<sup>1</sup> and Hirofumi Maruyama<sup>1,2</sup>

### Abstract:

A 20-year-old man with drug-resistant generalized epilepsy (GE) was admitted for video electroencephalography (vEEG) monitoring under treatment with multiple antiepileptic drugs, including levetiracetam (3,000 mg/day), valproic acid (800 mg/day), and lacosamide (LCM) (100 mg/day). No seizures were noted after the withdrawal of levetiracetam. However, after the withdrawal of LCM, atypical absence seizures with a 2- to 2.5-Hz generalized spike and wave complex frequently appeared, followed by subsequent generalized-onset tonic-clonic seizures. After re-administration of LCM, the seizures and epileptic discharges clearly disappeared. Subsequent LCM titration was successful in achieving a seizure-free status. Our vEEG results suggest that LCM may be a worthwhile antiepileptic drug adjunct in refractory GE patients without a risk of worsening absence seizures.

**Key words:** idiopathic generalized epilepsy, generalized seizure, antiepileptic drug, generalized spike and wave complex, ictal EEG

(Intern Med 60: 3621-3624, 2021)

(DOI: 10.2169/internalmedicine.7295-21)

### Introduction

Idiopathic generalized epilepsy (IGE) encompasses three seizure types of absence seizures, myoclonic seizures, and generalized tonic-clonic seizures (GTCSs) and is referred to as genetic generalized epilepsy (GE) (1). Most patients with IGE achieve a seizure-free status following antiepileptic drug (AED) therapy. However, unstable seizures remain in a certain number of patients. Although several new drugs, including lamotrigine and levetiracetam (LEV), are potential alternatives to valproic acid (VPA) for refractory IGE, they are not always effective (2).

Seizures that do not cease with at least two properly indicated and tolerated AEDs are referred to as refractory IGE (3). Lacosamide (LCM), a newer AED, interacts with sodium channels and is a potential alternative for refractory IGE (4). Although classical AEDs, such as carbamazepine

and phenytoin, are effective in focal to bilateral tonic-clonic seizures, these sodium channel blockers confer a potential risk of exacerbation in generalized seizures, particularly in myoclonic or absence seizures (5). Thus, the efficacy of sodium channel blockers for IGE with these seizures remains unclear (6).

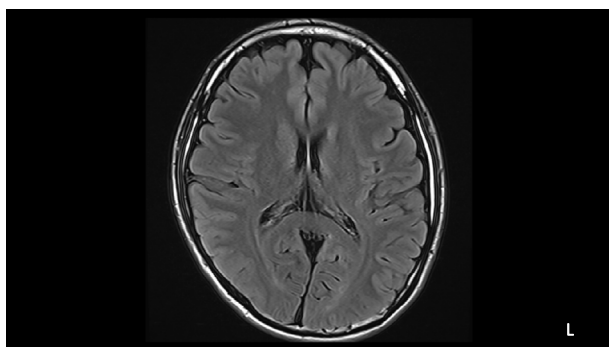
We herein report a patient with medically refractory GE in whom video electroencephalography (vEEG) confirmed that the seizures exhibited a favorable response to LCM.

### Case Report

A left-handed 20-year-old man was admitted to our hospital for the evaluation of refractory epileptic seizures. His initial seizures were GTCSs that had started at 15 years old. After AED treatment with LEV (2,000 mg/day), the GTCS frequency decreased from 3 times per year to once per year. However, transient loss of awareness seizures that were

<sup>1</sup>Department of Clinical Neuroscience and Therapeutics, Hiroshima University Graduate School of Biomedical and Health Sciences, Japan, <sup>2</sup>Epilepsy Center, Hiroshima University Hospital, Japan and <sup>3</sup>Department of Neurology, National Hospital Organization Yanai Medical Center, Japan  
Received: February 9, 2021; Accepted: April 12, 2021; Advance Publication by J-STAGE: May 29, 2021

Correspondence to Dr. Shuichiro Neshige, s-neshige@hiroshima-u.ac.jp



**Figure 1.** Brain magnetic resonance imaging. Axial-view brain fluid-attenuated inversion recovery images show no remarkable findings.

characterized by difficulty concentrating or paying attention recurred monthly. As the addition of VPA (800 mg/day) by the primary doctor was not effective, he was transferred to our hospital. However, VPA titration was difficult because he had intolerable sleepiness during the day. Thus, LCM was administered. After starting LCM (100 mg/day), the frequency of transient loss of awareness seizures decreased from monthly to once every several months. He had no history of myoclonic seizures and no episodes of nocturnal seizures. His neurological findings, including his cognitive function, were normal. He had no family history of epilepsy. Brain magnetic resonance imaging revealed normal findings, and interictal EEG showed no epileptic discharges (Fig. 1).

Because the incidence of loss of awareness seizures was self-reported, it was considered that the seizures might be psychogenic rather than epileptic. To clarify the type of seizure and epilepsy, we performed one-week vEEG monitoring that was initiated with LEV withdrawal. The blood concentrations before monitoring were as follows: LEV, 36.0  $\mu\text{g/mL}$ ; VPA, 35.1  $\mu\text{g/mL}$ ; and LCM, 2.6  $\mu\text{g/mL}$ . Although the blood concentration level of LEV decreased to 5.5  $\mu\text{g/mL}$  after the withdrawal, clinical seizures were absent on days 1-3 of the monitoring. In addition, interictal paroxysmal findings were not visible. After withdrawing LCM on day 3, he reported difficulty concentrating or paying attention and was occasionally unresponsive to the environment several times per hour on day 4. Although the clinical onset and offset of the seizure were unclear, ictal EEG revealed a 2- to 2.5-Hz generalized spike and wave complex (SWC) every 2-3 pages during these events (Fig. 2A). Interictal generalized SWCs were also predominant in the frontoparietal regions. However, the interictal SWCs showed no laterality during the recordings. In addition, interictal focal spikes or slows that were isolated in the frontal region was absent. Thus, he was diagnosed with GE, in which the seizure type included atypical absence.

Following these findings, he exhibited GTCSs that were characterized by motion arrest and vocalization followed by a symmetric tonic posture with bilateral limb abduction and extension, finally progressing to synchronous bilateral clonic jerks of the extremities. The present semiology did not show

focal findings, such as the “figure of 4 sign” or “head version”. Ictal EEG showed a 2.5- to 3-Hz generalized SWC followed by generalized rhythmic theta waves (Fig. 2B). After the re-administration of LCM (100 mg/day) on day 5, the seizures (including atypical absence seizures) immediately disappeared. The interictal SWC was also negligible. LEV (3,000 mg/day) was subsequently re-administered on day 6. After discharge, a gradual increase in LCM dosage to 300 mg/day was successful in achieving a seizure-free status for 6 months.

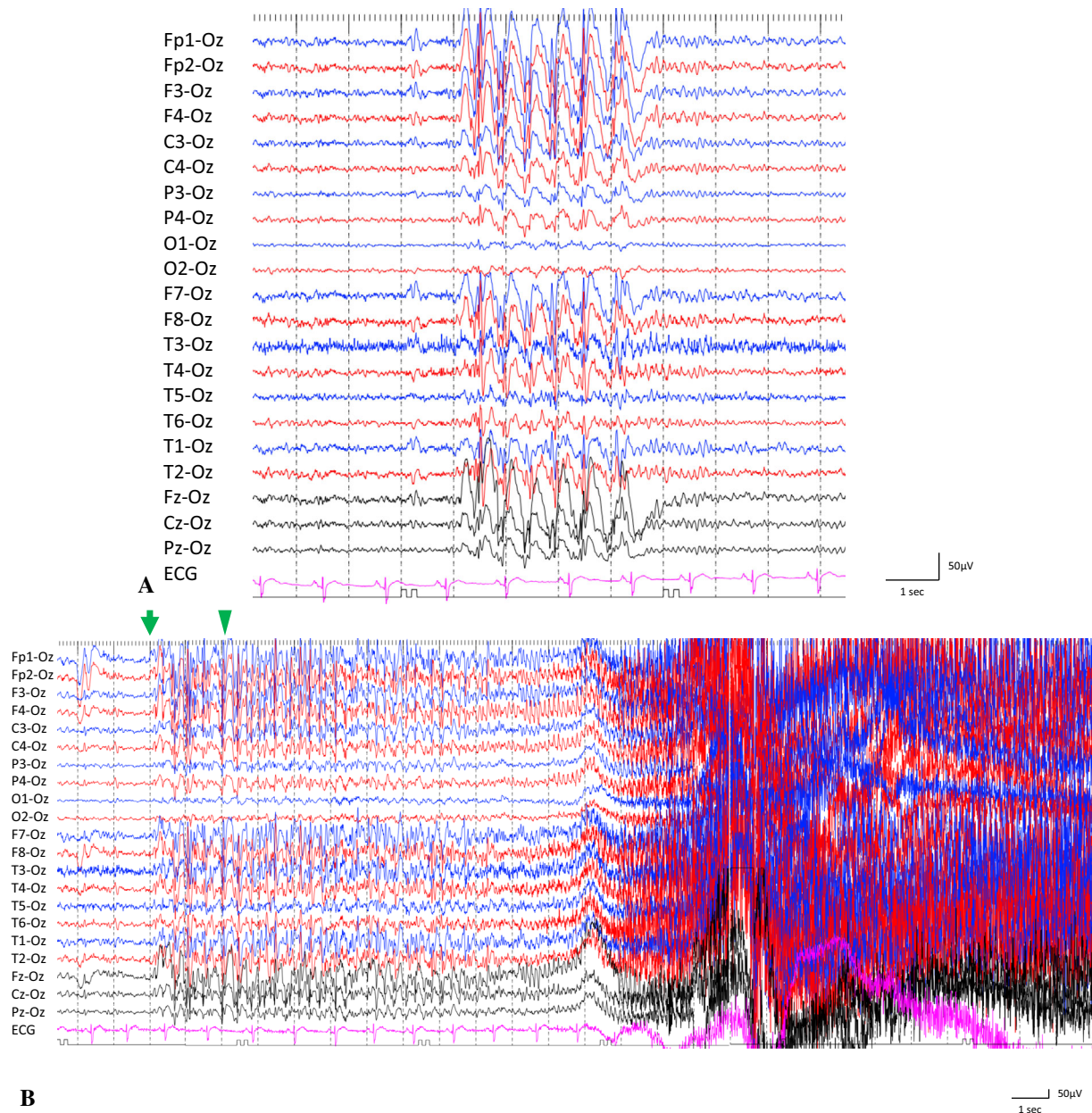
## Discussion

We encountered a case of refractory GE that was confirmed by a long-term vEEG examination. The semiology, interictal, and ictal EEG findings suggested that the seizures were consistent with atypical absence and GTCSs. Several lines of evidence exist to distinguish GE from frontal lobe epilepsy (FLE). First, he had no episodes of nocturnal seizure, which is a characteristic of FLE. Second, interictal EEG revealed no focal spike and slow isolated to the frontal region. Finally, there was no lateralizing value in the present semiology or EEG. As the onset and offset of an atypical absence seizure is often unclear, the details of the seizure reported by a patient may also be ambiguous or unclear; thus, such an incident can be mistaken for a psychogenic seizure, as shown in the present case. Although no seizures were detected following the withdrawal of LEV, atypical absence seizures with SWCs emerged. In addition, these epileptic events responded sharply to the re-administration of LCM. Although LEV and VPA achieved limited seizure control, at least in the atypical absence, the present vEEG data suggested that LCM had a notable effect on GE without resulting in the deterioration of atypical absence seizures.

LCM is a new AED that selectively enhances the slow inactivation of voltage-gated sodium channels. The profile of LCM is similar to that of conventional sodium channel-blocking AEDs (7). A previous study suggested that, similar to conventional AEDs, LCM might have the potential to worsen myoclonus and absence seizures in some patients with IGE (8-10). In contrast, our results showed a positive outcome, as reported recently (4). The novel observation in the present study was the vEEG findings during the withdrawal and re-administration of LCM. The rapid response of seizures to LCM is also noteworthy. These findings may help differentiate patients with IGE who will benefit from LCM from those who will not (11).

Since we discontinued two kinds of AEDs during monitoring, the impact of LEV withdrawal on clinical seizure occurrence during vEEG monitoring should be acknowledged. It is possible that discontinuation of LEV might contribute to the triggering of seizures. However, clinical seizures and EEG changes were absent even after a substantial decrease in the LEV blood concentration.

In conclusion, some patients with GE may exhibit inadequate seizure control, even with conventional AED treat-



**Figure 2.** Ictal electroencephalography findings. Electroencephalograms (EEGs) were recorded at a sampling rate of 500 Hz and a time constant of 0.1 s. Ictal EEGs during an atypical absence seizure (A) and generalized convulsions (B) are shown. Green arrows and arrowheads indicate the ictal EEG and clinical onset, respectively.

ment. LCM might be a worthwhile AED adjunction in these patients and might carry a low risk of worsening atypical absence seizures.

The authors state that they have no Conflict of Interest (COI).

## References

- Scheffer IE, Berkovic S, Capovilla G, et al. ILAE classification of the epilepsies: position paper of the ILAE Commission for Classification and Terminology. *Epilepsia* **58**: 512-521, 2017.
- Faught E. Treatment of refractory primary generalized epilepsy. *Rev Neurol Dis* **1** (Suppl 1): S34-S43, 2004.
- Kwan P, Arzimanoglou A, Berg AT, et al. Definition of drug resistant epilepsy: consensus proposal by the ad hoc Task Force of the ILAE Commission on Therapeutic Strategies. *Epilepsia* **51**: 1069-1077, 2010.
- Vossler DG, Knake S, O'Brien TJ, et al. Efficacy and safety of adjunctive lacosamide in the treatment of primary generalised tonic-clonic seizures: a double-blind, randomised, placebo-controlled trial. *J Neurol Neurosurg Psychiatry* **91**: 1067-1075, 2020.
- Chaves J, Sander JW. Seizure aggravation in idiopathic generalized epilepsies. *Epilepsia* **46** (Suppl 9): 133-139, 2005.
- Shih JJ, Whitlock JB, Chimato N, Vargas E, Karceski SC, Frank RD. Epilepsy treatment in adults and adolescents: expert opinion, 2016. *Epilepsy Behav* **69**: 186-222, 2017.
- Rogawski MA, Tofighty A, White HS, Matagne A, Wolff C. Current understanding of the mechanism of action of the antiepileptic drug lacosamide. *Epilepsy Res* **110**: 189-205, 2015.
- Abarrategui B, García-García ME, Toledano R, Parejo-Carbonell

- B, Gil-Nagel A, García-Morales I. Lacosamide for refractory generalized tonic-clonic seizures of non-focal origin in clinical practice: a clinical and VEEG study. *Epilepsy Behav Case Rep* **8**: 63-65, 2017.
9. Wechsler RT, Yates SL, Messenheimer J, Leroy R, Beller C, Doty P. Lacosamide for uncontrolled primary generalized tonic-clonic seizures: an open-label pilot study with 59-week extension. *Epilepsy Res* **130**: 13-20, 2017.
10. Birnbaum D, Koubeissi M. Unmasking of myoclonus by lacosamide in generalized epilepsy. *Epilepsy Behav Case Rep* **7**: 28-30, 2017.
11. Heavin SB, McCormack M, Wolking S, et al. Genomic and clinical predictors of lacosamide response in refractory epilepsies. *Epilepsia Open* **4**: 563-571, 2019.

The Internal Medicine is an Open Access journal distributed under the Creative Commons Attribution-NonCommercial-NoDerivatives 4.0 International License. To view the details of this license, please visit (<https://creativecommons.org/licenses/by-nc-nd/4.0/>).

---

© 2021 The Japanese Society of Internal Medicine  
*Intern Med* 60: 3621-3624, 2021