

A Population-Based Assessment of the Agreement Between Grading of Goniophotographic Images and Gonioscopy in the Chinese-American Eye Study (CHES)

Yohko Murakami,^{1,2} Dandan Wang,¹ Bruce Burkemper,¹ Shan C. Lin,² and Rohit Varma¹; for the Chinese-American Eye Study Group¹

¹University of Southern California Eye Institute, Keck School of Medicine, University of Southern California, Los Angeles, California, United States

²University of California, San Francisco, Department of Ophthalmology, San Francisco, California, United States

Correspondence: Rohit Varma, USC Eye Institute, Department of Ophthalmology, University of Southern California, Keck School of Medicine, 1450 San Pablo Street, Suite 400, Los Angeles, CA 90033, USA; rvarma@usc.edu.

See the appendix for members of the Chinese-American Eye Study (CHES) Group.

Submitted: October 16, 2015

Accepted: July 7, 2016

Citation: Murakami Y, Wang D, Burkemper B, Lin SC, Varma R; for the Chinese-American Eye Study Group. A population-based assessment of the agreement between grading of goniophotographic images and gonioscopy in the Chinese-American Eye Study (CHES). *Invest Ophthalmol Vis Sci.* 2016;57:4512–4516. DOI: 10.1167/iops.15-18434

PURPOSE. To compare grading of goniophotographic images and gonioscopy in assessing the iridocorneal angle.

METHODS. In a population-based, cross-sectional study, participants underwent gonioscopy and goniophotographic imaging during the same visit. The iridocorneal angle was classified as closed if the posterior trabecular meshwork could not be seen. A single masked observer graded the goniophotographic images, and each eye was classified as having angle closure based on the number of closed quadrants. Agreement between the methods was analyzed by calculating kappa (κ) and first-order agreement coefficient (AC1) statistics and comparison of area under receiver operating characteristic curves (AUC).

RESULTS. A total of 4149 Chinese Americans (3994 eyes) were included in this study. The agreement for angle closure diagnosis between gonioscopy and EyeCam was moderate to excellent ($\kappa = 0.60$, AC1 0.90, AUC 0.76–0.80).

CONCLUSIONS. Detection of iridocorneal angle closure based on goniophotographic imaging shows moderate to very good agreement with angle closure assessment using gonioscopy.

Keywords: glaucoma, angle closure, population based study, epidemiology

Primary angle-closure glaucoma is a major cause of visual impairment worldwide, especially in individuals of Asian descent. The diagnosis and evaluation of treatment efficacy are based on gonioscopy, which is a highly subjective examination technique that leads to variable interpretations of the angle structures depending on illumination conditions, variation in angle structure architecture, and experience of the examiner.¹ Gonioscopy is nonetheless considered the gold standard by which to assess the iridocorneal angle.

Problems with gonioscopy include its subjectivity across clinicians, which is compounded by its relative lack of usage among non-glaucoma specialists.^{2,3} With the use of the Posner or Zeiss lenses, there can be inadvertent dynamic compression leading to overestimation of the true angle grade. Other objective ways to examine the iridocorneal angle include ultrasound biomicroscopy (UBM), anterior-segment optical coherence tomography (AS-OCT), and Scheimpflug photography. However, UBM is usually too cumbersome and/or time intensive to be useful clinically in most situations. Anterior segment-OCT produces high-resolution imaging of the angle but is expensive and has limited availability. Scheimpflug photography is objective and has good reproducibility, but the image resolution is poor and there is often excessive reflection at the angle.

An ideal test would be one that provides a consistent image similar to gonioscopy and allows for more objective grading of the iridocorneal angle structures, as exemplified by optic disc photo grading. EyeCam (Clarity Medical Systems, Pleasanton, CA, USA) is a relatively new anterior segment imaging device that was modified from the RetCam (Clarity Medical Systems) to allow for direct angle visualization and photography.⁴ Recent studies in relatively small cohorts have shown good agreement between measurements using EyeCam and gonioscopy.^{5–8} The use of EyeCam imaging in large population-based studies has not yet been reported in the literature.

The aim of the present study was to evaluate the agreement of EyeCam goniophotographic grading by a glaucoma specialist with the gonioscopy grading of the principal examiner in the population-based Chinese-American Eye Study (CHES).

METHODS

The CHES is a prospective, population-based study of glaucoma and other ocular conditions of Chinese Americans. Details of the study design and procedures are described in detail elsewhere.⁹ In brief, the examination clinic is located in the city of Monterey Park, California, in Los Angeles County, which

TABLE 1. Agreement Between EyeCam and Gonioscopy in Iridocorneal Angle Assessment Using Binary (Open/Closed) Outcome Measures

Definition of Closure	Gonioscopy, <i>n</i> (%), 95% CI	EyeCam, <i>n</i> (%), 95% CI	<i>P</i> Value*	Kappa	AC1
≥1 quadrants closed, <i>n</i> = 3994	755 (18.9, 17.7–20.2)	738 (18.5, 17.3–19.7)	0.46	0.57	0.86
≥2 quadrants closed, <i>n</i> = 3994	557 (14.0, 12.9–15.1)	470 (11.8, 10.8–12.8)	<0.0001	0.60	0.90
≥3 quadrants closed, <i>n</i> = 3994	415 (10.4, 9.5–11.4)	324 (8.1, 7.3–9.0)	<0.0001	0.59	0.93
Inferior quadrant closed, <i>n</i> = 3986	552 (13.9, 12.8–15.0)	487 (12.2, 11.2–13.3)	0.001	0.54	0.89
Superior quadrant closed, <i>n</i> = 3976	595 (15.0, 13.9–16.2)	493 (12.4, 11.4–13.5)	<0.0001	0.52	0.88
Nasal quadrant closed, <i>n</i> = 3990	434 (10.9, 9.9, 11.9)	404 (10.1, 9.2–11.1)	0.10	0.57	0.91
Temporal quadrant closed, <i>n</i> = 3988	444 (11.1, 10.1–12.1)	354 (8.9, 8.0–9.8)	<0.0001	0.52	0.91

* Based on McNemar's test. CI, confidence interval; AC1, first-order agreement coefficient.

has a large Chinese-American population. The study enrollment began in 2010 and included a total of 4582 individuals of Chinese descent, aged 50 years and older.

Ethics committee approval was obtained from the institutional review board of the University of Southern California Health Sciences. Written informed consent was obtained from all subjects. All study procedures adhered to the recommendations of the Declaration of Helsinki.

Exclusion criteria included prior intraocular surgery (e.g., history of cataract extraction, corneal transplant, incisional glaucoma surgery, and retina surgery), penetrating eye injury, or the presence of corneal disorders such as corneal endothelial dystrophy, pterygium, or corneal scars that may preclude satisfactory imaging. Patients who had previously undergone laser peripheral iridotomy (LPI) were included.

Clinical Examination and Gonioscopy

After a detailed ophthalmic history was obtained, participants received a complete ocular examination, including visual acuity assessment, pupil assessment, visual field exam (SITA Standard 24-2), slit-lamp biomicroscopy, Goldmann applanation tonometry, gonioscopy, imaging with the EyeCam, and dilated fundus examination of the optic nerve, macula, and periphery. Clinical examinations were performed by two glaucoma-trained ophthalmologists (DW, CL).

Indirect gonioscopy was performed with a Posner-type 4-mirror lens (Model ODPSPG; Ocular Instruments, Inc., Bellevue, WA, USA) under dark ambient lighting. The slit was minimized to a 1-mm height and width to prevent light from entering the pupil. The light was also minimized to a level that was necessary to adequately observe the angle. Grading was according to a modified Shaffer scheme. Grade 0 was ascribed when no trabecular meshwork (TM) could be observed. Grade 1 was recorded for angles in which the width was judged to be 5° to 15°. Grade 2 was assigned for angles with a width of 15° to 25°. Grade 3 was used for 25° to 35° angles, and Grade 4 for greater than 35° angles.

EyeCam Imaging

Subjects were placed in a supine position, and the room was darkened during testing. Imaging with the EyeCam was performed by a single trained technician. Images were obtained from all four quadrants (inferior, superior, nasal, and temporal quadrants sequentially) of both eyes. Topical anesthetic drops (Proparacaine hydrochloride 0.5%; Alcon Laboratories, Inc., Fort Worth, TX, USA) were applied, followed by a coupling gel. Imaging was performed with the 130° lens on the EyeCam hand piece. The tip was placed near the limbus and directed at the opposite angle. Care was taken to avoid contact and potential compression of the eye. If the view of the angle was blocked by a convex lens curvature, the technician was allowed to move the tip approximately 10° anteriorly along the cornea, similar to

slightly tilting a gonioscopy lens. Evaluation of the angle structures was accomplished by adjusting the distance of the hand piece tip from the limbus, and the illumination was adjusted by the foot pedal control.

EyeCam Grading

EyeCam images were uploaded to a protected online data storage system. Images were graded by a single glaucoma-trained specialist (SCL). The observer was blinded to the patient's age, sex, and clinical information, including gonioscopy results. Parameters assessed included: (1) image quality, graded as 1 to 3, (2) angle grade by structures identified, (3) pigmentation level, (4) presence or absence of Sampaolesi's line, and (5) any abnormalities such as pigmented tumors.

Image quality was graded between 1 and 3, with grade 1 representing the best quality score in which the angle image was clear, grade 2 indicating a slightly blurred image in which angle structures remained distinguishable, and grade 3 a blurred image in which angle structures are difficult to identify. Grade 3 images were not included in the statistical analysis. Angle grading was according to the following: (1) grade 4 (wide open angle) in which ciliary body band is observed for the majority of the image, (2) grade 3 (open angle) in which scleral spur is observed for the majority of the image, (3) grade 2 (narrow but open angle) in which the posterior TM is the most posterior structure seen for the majority of the image, (4) grade 1 (narrow occludable angle) in which only the anterior TM is seen for the majority of the image, and (5) grade 0 (closed/appositional angle) in which no angle structures are seen for most of the image. These angle grading categories matched the Shaffer classification system used to grade the eyes clinically on gonioscopy. For both EyeCam and gonioscopy, angle closure was defined as grade 0 in the classification scheme described.

Sampaolesi's line was graded as positive if a linear pigmented deposition was observed anterior to the Schwabe's line. Abnormalities that were specifically denoted included focal peripheral anterior synechia, iris processes, patchy TM pigmentation, iris elevation, iris lesion (mass with increased pigmentation), and neovascular vessels.

Statistical Analysis

The right eye of each patient was used for analysis unless that eye met one or more of the exclusion criteria, in which case the left eye was used (provided it met no exclusion criteria). The McNemar test was used to test the null hypothesis of marginal homogeneity (rater agreement) in 2 × 2 cross classifications of paired responses to dichotomous items (quadrant/angle closure). The simple kappa (κ) statistic was used to assess the strength of agreement between dichotomized (open/closed) variables, while the weighted κ was used to measure agreement for ordinal variables (the polychotomous "grade" variable used to quantify angle width), and to

TABLE 2. Agreement Between EyeCam and Gonioscopy in Iridocorneal Angle Assessment Using Ordinal Outcome Measures (Angle Width in Degrees, Categorized Using the Shaffer Classification System)

Graded Angle	Weighted Kappa*	Weighted AC1
Inferior, <i>n</i> = 3986	0.58	0.88
Superior, <i>n</i> = 3976	0.56	0.86
Nasal, <i>n</i> = 3990	0.60	0.90
Temporal, <i>n</i> = 3988	0.52	0.89

* Fleiss Cohen (quadratic) weights.

measure intra- and interrater reliability. Weighted κ coefficients were computed using Fleiss-Cohen (quadratic) weights. The first-order agreement coefficient (AC1) statistic was used in addition to κ , as the latter statistic can yield coefficients that are paradoxically low relative to overall agreement under conditions where high trait prevalence causes a marked imbalance in contingency table marginals.¹⁰ Receiver operating characteristic curves with calculations of area under the curve (AUC) and 95% confidence intervals (CIs) were used as an index of performance for identification of eyes with angle closure, using gonioscopy as the reference standard. A *P* value less than 0.05 was considered statistically significant. Statistical analyses were performed using SAS version 9.4 (SAS Institute, Inc., Cary, NC, USA).

RESULTS

CHES identified a total of 5782 eligible subjects. Of these, 4582 completed both a home questionnaire and a clinical eye exam. One hundred forty-one subjects refused angle assessment, leaving 4441 who underwent both gonioscopy and EyeCam imaging. Of those who were assessed, 292 subjects were subsequently excluded due to previous intraocular surgery, resulting in an analytic sample of 4149 participants for analysis. Three participants had previously undergone LPI and had no history of other intraocular surgery. Individuals with incomplete, unavailable, or poor quality EyeCam images in some quadrants were excluded from the appropriate quadrant-specific analyses; no gonioscopy cases were excluded, incomplete, or unrecorded. The mean age of participants was 60.7 ± 8.1 years. The sample included 1523 men and 2626 women.

Inter- and intraobserver agreement for EyeCam (defining angle closure as 2 or more quadrants closed) was excellent (κ = 0.82 and 0.87, respectively). Tables 1 and 2 show the agreement between gonioscopy and EyeCam for various definitions of angle closure, as well as agreement between the two modalities on angle closure on a per-quadrant basis. Gonioscopy and EyeCam showed moderate agreement according to the κ statistic, and excellent agreement according to the AC1 statistic for all quadrants and angle closure definitions. Agreement was best when defining angle closure as two or

more quadrants on gonioscopy (κ = 0.60, AC1 0.90, *P* < 0.0001). When angle closure was examined by quadrant, the superior and temporal quadrants showed the least agreement between gonioscopy and EyeCam images (κ = 0.52) compared with the other quadrants (nasal quadrant κ = 0.57, inferior quadrant κ = 0.54). Gonioscopy identified angle closure at higher rates than EyeCam when angle closure was defined as closure in two or more quadrants, three or more quadrants, all four quadrants (*P* < 0.0001), and in the superior and temporal quadrants. There was no change in the agreement statistics when subjects with previous LPI were removed from the analysis (data not shown).

The AUC was greater than 70% for all definitions of angle closure, as well as for quadrant-specific angle closure (Table 3). When defined as two or more quadrants closed, angle closure was not diagnosed using EyeCam despite being classified in gonioscopy in 9.0% (359/3994 eyes) of cases, while 3.4% of cases saw angle closure diagnosed in EyeCam but not gonioscopy. The Figure demonstrates EyeCam images showing discrepancy with diagnosis of open and closed angles. Angles graded as open on EyeCam and closed on gonioscopy were attributed to partial angle closure within the quadrant (Fig. A) or the presence of a pigmented Schwalbe’s line within the quadrant (Fig. B).

DISCUSSION

This study is the first of its kind to use EyeCam in a population-based setting and reports the largest number of patients studied with EyeCam to date. While prior studies have used EyeCam in smaller, clinic-based populations constituting less than 200 patients,^{5-8,11} our study examined over 4000 individuals in a community setting. In our study, grading of EyeCam images showed moderate to excellent agreement with gonioscopic assessment, which is consistent with prior studies in smaller clinic-based populations.^{5-7,11} Our study also demonstrated excellent intra- and interobserver agreement equivalent to prior studies in a clinical setting.^{5-8,11}

Differences exist between our results and prior studies regarding the agreement rate between gonioscopy and EyeCam, which can be attributed to the different size and demographics of the populations studied, and the prevalence of angle closure within these populations. We noted a higher rate of angle closure detected by gonioscopy than by EyeCam in this study. This difference can be attributed to the presence of partial angle closure within the quadrant that was not detected by EyeCam but detected on gonioscopy, as well as a highly pigmented Schwalbe’s line that may have led to disparate interpretations of the angle structures. EyeCam is unlikely to replace gonioscopy as the reference standard, and disparities in angle assessment using the two methods must be interpreted with caution.

The moderate to high diagnostic performance of EyeCam in detecting angle closure and its agreement with gonioscopy

TABLE 3. Performance of EyeCam Relative to Gonioscopy for Each Quadrant and Various Definitions of Angle Closure

Definition of Closure	AUC (95% CI)	Sensitivity (95% CI)	Specificity (95% CI)	PPV	NPV
≥1 quadrants closed, <i>n</i> = 3994	0.78 (0.76-0.80)	0.64 (0.42-0.94)	0.92 (0.65-1.27)	0.65	0.92
≥2 quadrants closed, <i>n</i> = 3994	0.78 (0.76-0.80)	0.60 (0.58-0.62)	0.96 (0.95-0.97)	0.71	0.94
≥3 quadrants closed, <i>n</i> = 3994	0.77 (0.74-0.79)	0.56 (0.54-0.58)	0.97 (0.96-0.98)	0.72	0.95
Inferior quadrant closed, <i>n</i> = 3986	0.76 (0.74-0.78)	0.57 (0.55-0.58)	0.95 (0.94-0.96)	0.64	0.93
Superior quadrant closed, <i>n</i> = 3976	0.74 (0.72-0.76)	0.54 (0.52-0.56)	0.95 (0.94-0.96)	0.65	0.92
Nasal quadrant closed, <i>n</i> = 3990	0.77 (0.75-0.80)	0.59 (0.57-0.61)	0.96 (0.95-0.97)	0.63	0.95
Temporal quadrant closed, <i>n</i> = 3988	0.74 (0.71-0.76)	0.51 (0.49-0.53)	0.96 (0.95-0.97)	0.64	0.94

PPV, positive predictive value; NPV, negative predictive value.

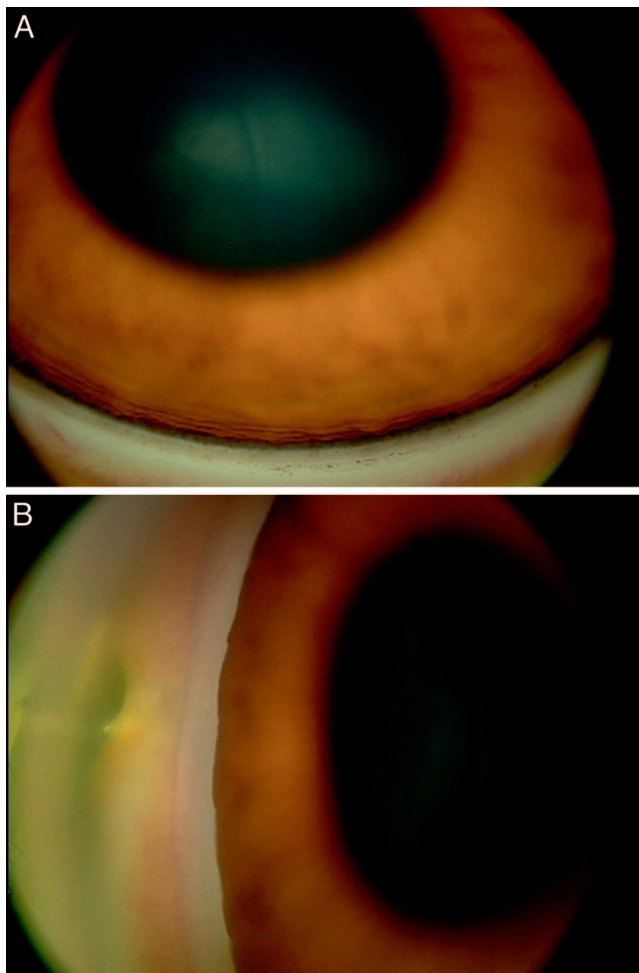


FIGURE. EyeCam images classified as (A) open versus (B) closed angles.

make it a useful screening tool in patient populations with known high rates of angle closure, such as Chinese and Chinese Americans.^{1,12-16} In this study, EyeCam demonstrated high specificity and moderate sensitivity in detecting angle closure. The utility of EyeCam in populations at high risk for angle closure includes: (1) the ability of EyeCam to be operated by a trained technician rather than a physician, allowing for a wider range of angle documentation across a greater number of patients, (2) providing a view of the angle similar to that observed with gonioscopy (apart from its inability to provide a dynamic view of the angle), allowing for 360° visualization of the iridocorneal angle, unlike the cross-sectional views afforded by traditional AS-OCT and UBM, and (3) the ability to monitor the angle over time.

EyeCam imaging provides an unprecedented objective method of gonioscopic angle documentation that can be followed longitudinally, in a manner similar to how optic disc stereophotographs are used to track glaucomatous disease progression.¹⁷⁻²⁰ These stored EyeCam images can also be used in training sessions to improve agreement of gonioscopic angle grading between ophthalmologists, which remain suboptimal and subjective.^{2,20-22} Furthermore, the standardization of the EyeCam image acquisition process, such that identical portions of the iridocorneal angle are obtained at each exam, provides the clinician with a baseline of the gonioscopic exam for each patient and each angle quadrant that can be referenced to evaluate disease progression and changes related to treatment. In our study, 72% and 96% of eyes identified as

closed and open angle using the EyeCam, respectively, were given the same diagnosis using gonioscopy. Separate clinicians assessed gonioscopy and EyeCam images in order to prevent bias in agreement between the two methods, but there was excellent intra- and interrater reliability.

There are several disadvantages to EyeCam imaging, such as the inability to perform dynamic imaging, as well as its requirement for supine patient positioning. However the EyeCam is not an invasive measure, and is similar to gonioscopy in this way. Obtaining EyeCam imaging also takes longer than gonioscopy, approximately 5 to 10 minutes per eye, which may present a challenge in employing it as a standard screening tool for all populations. This study was limited by the fact that there was little experience with the EyeCam prior to this study; additional experience may have resulted in better quality images with time.

In summary, our study suggests that expert grading of EyeCam images of the iridocorneal angle can provide moderate to excellent agreement with gonioscopic grading in a large population-based cohort. EyeCam can be an effective screening tool for the identification of closed angles or narrow angles developing creeping angle closure over time in populations with a known predisposition to angle closure.

Acknowledgments

This work was supported by Grants EY-017337 from the National Eye Institute, National Institute of Health, Bethesda, Maryland and an unrestricted Departmental grant from Research to Prevent Blindness, New York, New York.

Disclosure: **Y. Murakami**, None; **D. Wang**, None; **B. Burkemper**, None; **S.C. Lin**, None; **R. Varma**, None

References

1. See JL. Imaging of the anterior segment in glaucoma. *Clin Experiment Ophthalmol*. 2009;37:506-513.
2. Hertzog LH, Albrecht KG, LaBree L, Lee PP. Glaucoma care and conformance with preferred practice patterns. Examination of the private, community-based ophthalmologist. *Ophthalmology*. 1996;103:1009-1013.
3. Quek DT, Nongpiur ME, Perera SA, Aung T. Angle imaging: advances and challenges. *Indian J Ophthalmol*. 2011; 59(suppl):S69-S75.
4. Azad RV, Chandra P, Chandra A, Gupta A, Gupta V, Sihota R. Comparative evaluation of RetCam vs. gonioscopy images in congenital glaucoma. *Indian J Ophthalmol*. 2014;62:163-166.
5. Baskaran M, Aung T, Friedman DS, Tun TA, Perera SA. Comparison of EyeCam and anterior segment optical coherence tomography in detecting angle closure. *Acta Ophthalmol*. 2012;90:e621-e625.
6. Baskaran M, Perera SA, Nongpiur ME, et al. Angle assessment by EyeCam, gonioscopy, and gonioscopy. *J Glaucoma*. 2012;21:493-497.
7. Perera SA, Baskaran M, Friedman DS, et al. Use of EyeCam for imaging the anterior chamber angle. *Invest Ophthalmol Vis Sci*. 2010;51:2993-2997.
8. Perera SA, Quek DT, Baskaran M, et al. Demonstration of angle widening using EyeCam after laser peripheral iridotomy in eyes with angle closure. *Am J Ophthalmol*. 2010;149:903-907.
9. Varma R, Hsu C, Wang D, Torres M, Azen SP; for the Chinese American Eye Study Group. The Chinese American Eye Study: design and methods. *Ophthalmic Epidemiol*. 2013;20:335-347.
10. Gwet KL. Computing inter-rater reliability and its variance in the presence of high agreement. *Br J Math Stat Psychol*. 2008; 61(pt 1):29-48.

11. Baskaran M, Cheng J, Perera SA, Tun TA, Liu J, Aung T. Automated analysis of angle closure from anterior chamber angle images. *Invest Ophthalmol Vis Sci*. 2014;55:7669-7673.
12. Wang YX, Xu L, Yang H, Jonas JB. Prevalence of glaucoma in North China: the Beijing Eye Study. *Am J Ophthalmol*. 2010;150:917-924.
13. Cho HK, Kee C. Population-based glaucoma prevalence studies in Asians. *Surv Ophthalmol*. 2014;59:434-447.
14. Quek DT, Koh VT, Tan GS, Perera SA, Wong TT, Aung T. Blindness and long-term progression of visual field defects in Chinese patients with primary angle-closure glaucoma. *Am J Ophthalmol*. 2011;152:463-469.
15. Chew P, Aung T. Controversies in acute primary angle closure glaucoma in Chinese people. *Aust N Z J Ophthalmol*. 1999;27:358-359.
16. Wang N, Wu H, Fan Z. Primary angle closure glaucoma in Chinese and Western populations. *Chin Med J (Engl)*. 2002;115:1706-1715.
17. Abramoff MD, Alward WL, Greenlee EC, et al. Automated segmentation of the optic disc from stereo color photographs using physiologically plausible features. *Invest Ophthalmol Vis Sci*. 2007;48:1665-1673.
18. Giangiacomo A, Garway-Heath D, Caprioli J. Diagnosing glaucoma progression: current practice and promising technologies. *Curr Opin Ophthalmol*. 2006;17:153-162.
19. Xu J, Ishikawa H, Wollstein G, et al. Automated assessment of the optic nerve head on stereo disc photographs. *Invest Ophthalmol Vis Sci*. 2008;49:2512-2517.
20. Zeyen T, Miglior S, Pfeiffer N, Cunha-Vaz J, Adamsons I; for the European Glaucoma Prevention Study Group. Reproducibility of evaluation of optic disc change for glaucoma with stereo optic disc photographs. *Ophthalmology*. 2003;110:340-344.
21. Reus NJ, Lemij HG, Garway-Heath DE, et al. Clinical assessment of stereoscopic optic disc photographs for glaucoma: the European Optic Disc Assessment Trial. *Ophthalmology*. 2010;117:717-723.
22. Breusegem C, Fieuws S, Stalmans I, Zeyen T. Agreement and accuracy of non-expert ophthalmologists in assessing glaucomatous changes in serial stereo optic disc photographs. *Ophthalmology*. 2011;118:742-746.

APPENDIX

The Chinese-American Eye Study (CHES) Group

USC Roski Eye Institute, University of Southern California: Rohit Varma, MD, MPH (Principal Investigator); Roberta McKean-Cowdin, PhD (Co-Investigator); Stanley P. Azen, PhD (Co-Investigator); Mina Torres, MS (Project Director); Chunyi Hsu, MPH (Project Manager); David Dinh, BA (Research Assistant); Ruzhang Jiang, MD (Examiner); Jie Sun, MD, PhD, MPH (Examiner); Dandan Wang, MD (Examiner); YuPing Wang, COT (Examiner); Justine Wong, BA (Clinical Interviewer); Shuang Wu, MS (Statistician); Rucha Desai, MS (Programmer). The Battelle Survey Research Center: Lisa V. John, PhD (Recruitment Director); Michelle Cheng, MS (Field Supervisor).

CHES Data Monitoring and Oversight Committee

Alfred Sommer, MD, MHS (Chair); Anne Coleman, MD, PhD; Dennis Han, MD; Craig Hanis, PhD; Louise Wideroff, PhD; and Terri Young, MD.