

Imaging the spine in arthritis—a pictorial review

Anne Grethe Jurik

Received: 3 August 2010 / Revised: 6 November 2010 / Accepted: 16 December 2010 / Published online: 8 January 2011
© European Society of Radiology 2011

Abstract Spinal involvement is frequent in rheumatoid arthritis (RA) and seronegative spondyloarthritides (SpA), and its diagnosis is important. Thus, MRI and CT are increasingly used, although radiography is the recommended initial examination. The purpose of this review is to present the typical radiographic features of spinal changes in RA and SpA in addition to the advantages of MRI and CT, respectively. RA changes are usually located in the cervical spine and can result in serious joint instability. Subluxation is diagnosed by radiography, but supplementary MRI and/or CT is always indicated to visualise the spinal cord and canal in patients with vertical subluxation, neck pain and/or neurological symptoms. SpA may involve all parts of the spine. Ankylosing spondylitis is the most frequent form of SpA and has rather characteristic radiographic features. In early stages it is characterised by vertebral squaring and condensation of vertebral corners, in later stages by slim ossifications between vertebral bodies, vertebral fusion, arthritis/ankylosis of apophyseal joints and ligamentous ossification causing spinal stiffness. The imaging features of the other forms of SpA can vary, but voluminous paravertebral ossifications often occur in psoriatic SpA. MRI can detect signs of active inflammation as well as chronic structural changes; CT is valuable for detecting fracture.

Keywords Spine · Arthritis · Arthritis, rheumatoid · Spondyloarthropathies

Introduction

The spine can be involved in most inflammatory disorders encompassing rheumatoid arthritis (RA), seronegative spondyloarthritides (SpA), juvenile arthritides and less frequent disorders such as pustulotic arthro-osteitis and SAPHO (synovitis, acne, pustulosis, hyperostosis, osteitis) syndrome.

During the last decade the diagnostic use of magnetic resonance imaging (MRI) and computed tomography (CT) has increased considerably, although radiography is still the recommended initial examination. It is therefore important to know the characteristic radiographic findings in arthritides in addition to the advantages of supplementary MRI and CT. This review will focus on the different imaging features and be concentrated on the most frequent inflammatory spinal changes seen in RA and SpA, respectively. These two entities display somewhat different imaging features, which are important to recognise.

Rheumatoid arthritis

Involvement in RA is usually located in the cervical spine where erosive changes are predominantly seen in the atlanto-axial region. Inflamed and thickened synovium (pannus) can occur around the odontoid process (dens) and cause bone erosion and destruction of surrounding ligaments, most seriously if the posterior transverse ligament is involved. Laxity or rupture of the transverse ligament causes instability with a potential risk of spinal cord injury. Cervical RA involvement is a progressive, serious condition with reduced lifetime expectancy [1], and its diagnosis is therefore important [2, 3].

Radiography of the cervical spine is mandatory in RA patients with neck pain [3]. It should always include a

A. G. Jurik (✉)
Department of Radiology, Aarhus University Hospital,
Noerrebrogade 44, DK 8000 Aarhus, Denmark
e-mail: anne.jurik@aarhus.rm.dk

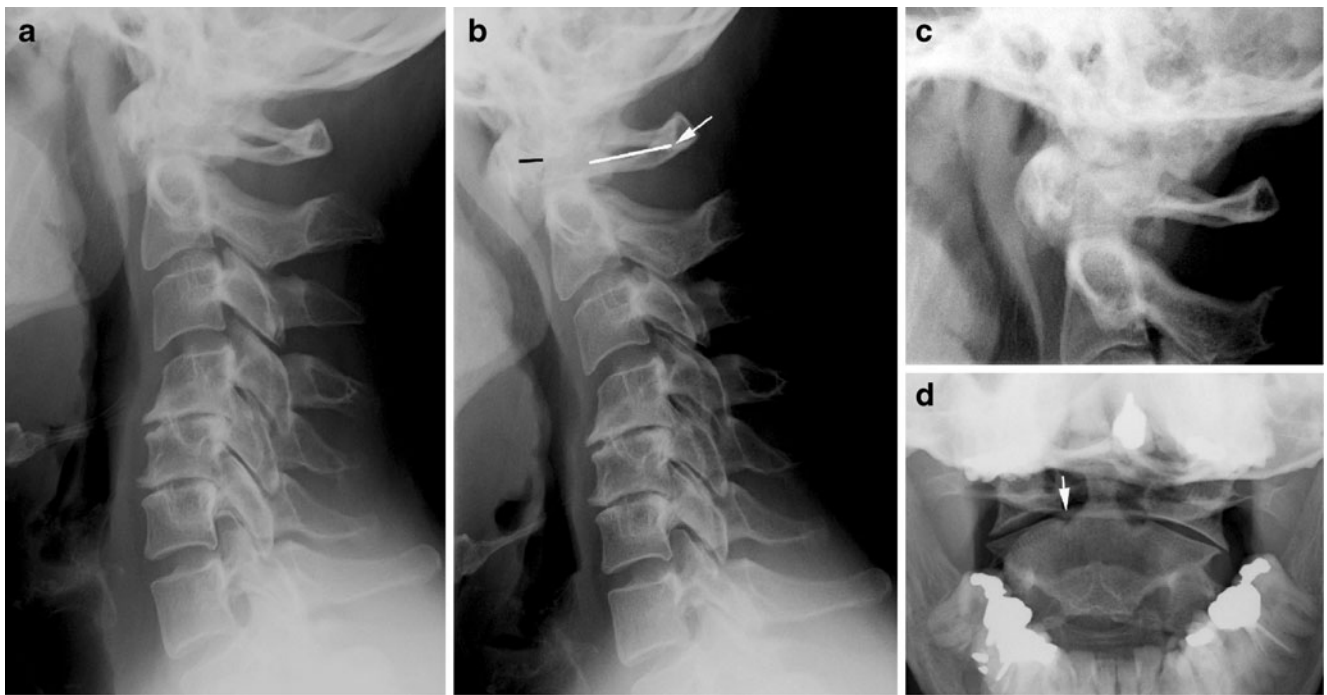


Fig. 1 Standard radiography of the cervical spine in rheumatoid arthritis (RA). (a) Lateral radiographs in neutral position and (b) during flexion in addition to (c) lateral and (d) anterior-posterior (AP) open-mouth view of the atlanto-axial region (45-year-old woman). The flexion view (b) shows abnormal distance (>3 mm) between the posterior aspect of the anterior arc of the atlas and the anterior aspect of the dens (black line). Note that the spino-laminar line of the atlas

(arrow) does not align with that of the other vertebrae, confirming the presence of anterior subluxation, but there is no stenosis of the atlanto-axial canal; the posterior atlanto-dental interval (white line) is >14 mm. The open-mouth view (d) shows erosion at the base of the dens (arrow). (a) and (b) show concomitant disc degenerative changes at the C4–C6 level

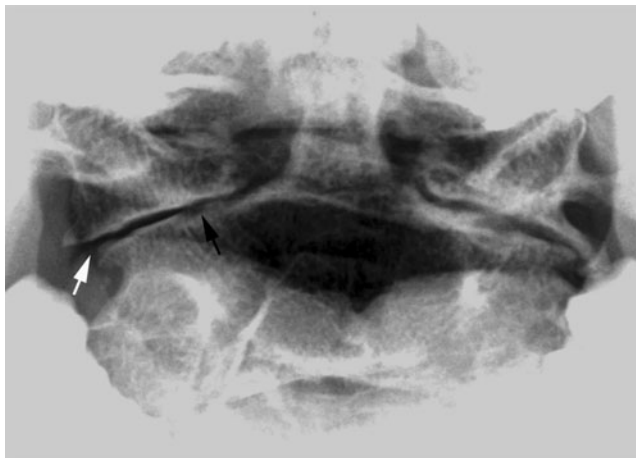


Fig. 2 Lateral and rotatory atlanto-axial subluxation. AP open-mouth view in a 53-year-old man with RA. There is narrowing of the atlanto-axial joints with superficial erosions (black arrow) and lateral displacement of the axis with respect to the lateral masses of the atlas (white arrow); in addition signs indicating rotatory displacement with asymmetry of the distance between the dens and the lateral masses of the atlas

lateral view in a flexed position compared with a neutral position in addition to special views of the dens area to detect any lesions and/or instability (Fig. 1). A supplementary lateral view during extension can be useful to assess reducibility of atlanto-axial subluxation possibly limited by pannus tissue between the anterior arc of the atlas and dens.

Anterior atlanto-axial subluxation is the most frequent form of RA instability in the occipito-atlanto-axial region, but lateral, rotatory and vertical subluxation can also occur. The definition of the different forms of instability by radiography is as follows [3].

Anterior atlanto-axial subluxation Distance between the posterior aspect of the anterior arc of the atlas and the anterior aspect of the dens exceeding 3 mm in a neutral position and/or during flexion (Fig. 1). It may cause stenosis of the atlanto-axial canal presenting as a posterior atlanto-dental interval <14 mm (Fig. 1).

Lateral and rotatory atlanto-axial subluxation Displacement of the lateral masses of the atlas more than 2 mm in relation to that of the axis and asymmetry of the lateral masses relative to the dens, respectively (Fig. 2). Rotatory

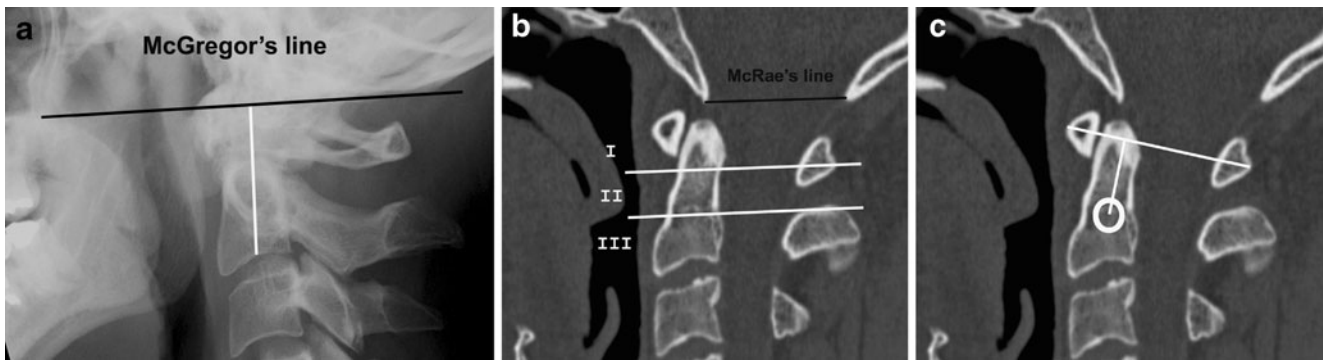
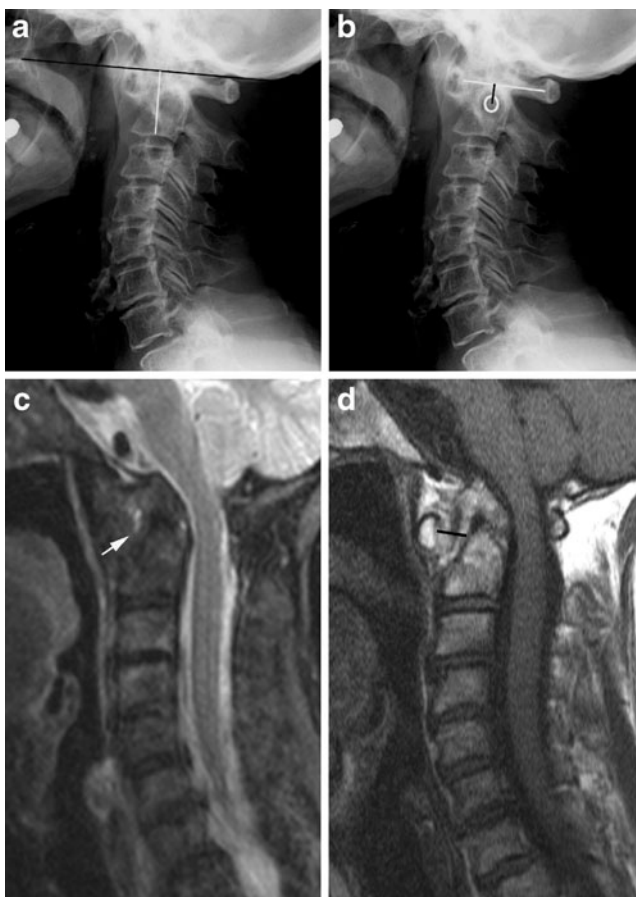

Fig. 3 Vertical atlanto-axial subluxation, measurement methods. (a) Lateral normal radiograph in neutral position showing the location of McGregor's line (black) between the postero-superior aspect of the hard palate and the most caudal point of the occipital curve. Migration of the tip of the dens >4.5 mm above McGregor's line indicates vertical subluxation. The distance indicated by the white line between McGregor's line and the midpoint of the inferior margin of the body of axis is used to evaluate vertical subluxation according to Redlund-Johnell and Pettersson's method. A distance less than 34 mm in men and 29 mm in women indicates vertical subluxation. (b) Sagittal CT

reconstruction of a normal cervical spine showing the location of McRae's line corresponding to the occipital foramen and the division of the axis into three equal portions used by Clark's method for diagnosing vertical subluxation. If the anterior arc of the atlas is in level with the middle or caudal third of the axis there is slight and pronounced vertical subluxation, respectively. (c) Ranawat's method includes determination of the distance between the centre of the second cervical pedicle and the transverse axis of the atlas. A distance less than 15 mm in males and 13 mm in females indicates vertical subluxation [4]



and lateral subluxation is diagnosed on open-mouth anterior-posterior (AP) radiographs. Anterior subluxation often coexists because of the close anatomical relation between the atlas and the axis.

Posterior atlanto-axial subluxation The anterior arc of the atlas moves over the odontoid process. This is rarely seen, but may coexist with fracture of the dens.

Vertical atlanto-axial subluxation is also referred to as atlanto-axial impaction, basilar invagination or cranial

Fig. 4 Vertical subluxation. (a) Lateral radiograph with McGregor's line (black line; 61-year-old man with RA). The tip of the dens is difficult to define, but measurement according to Redlund-Johnell's method (white line) results in a distance of 27 mm, which is below the normal limit. In accordance with this, the anterior arc of the atlas is level with the middle third of the axis. (b) Ranawat's method, the distance between the centre of the second cervical pedicle and the transverse axis of the atlas is below the normal limit (9 mm). Thus, all measurements indicate vertical subluxation. Supplementary MRI, (c) sagittal STIR and (d) T1-weighted images show erosion of the dens and protrusion of the tip into the occipital foramen causing narrowing of the spinal canal to 9 mm, but persistence of cerebrospinal fluid around the cord. There is a 9-mm-thick mass of pannus tissue between the dens and anterior arc (black line) exhibiting small areas with high signal intensity on the STIR image (arrow) compatible with slight activity, but signal void fibrous pannus tissue predominates

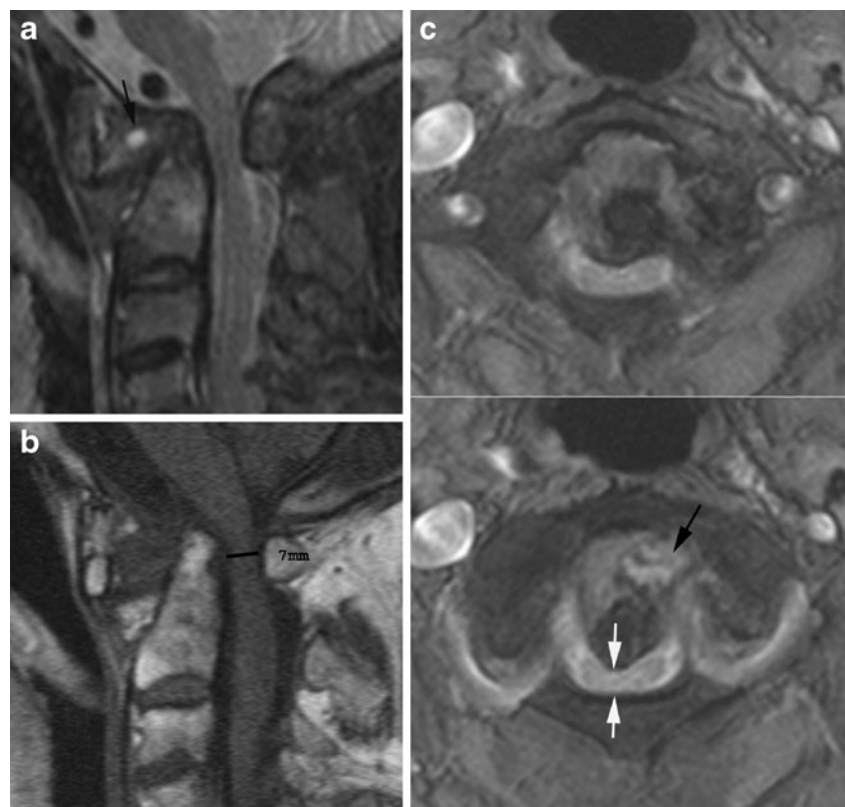setting, and is defined as migration of the odontoid tip proximal to McRae's line corresponding to the occipital foramen. This line can be difficult to define on radiographs, and vertical subluxation has therefore also been defined by several other methods. Migration of the tip of the odontoid process >4.5 mm above McGregor's line (between the postero-superior aspect of the hard palate and the most caudal point of the occipital curve) indicates vertical subluxation (Fig. 3).

The occurrence of dens erosion can, however, make this measurement difficult to obtain. The Redlund-Johnell method is therefore based on the minimum distance between McGregor's line and the midpoint of the inferior margin of the body of the axis on a lateral radiograph in a neutral position (Fig. 3) [4]. Visualisation of the palate may not always be obtained. Methods without dens and/or the palate as landmarks have therefore been introduced [4]. The method described by Clark et al. (described in [4]) includes assessment of the location of the atlas by dividing the axis into three equal portions on a lateral radiograph. Location of the anterior arc of the atlas in level with the middle or caudal third of the axis indicates vertical subluxation (Fig. 3). Ranawat et al. have proposed using the distance between the centre of the second cervical pedicle and the

transverse axis of the atlas at the odontoid process (Fig. 3) [4]. To obtain the diagnosis of vertical subluxation a combination of the Redlund-Johnell, Clark and Ranawat methods has been recommended (described in [4]). If any of these methods suggests vertical subluxation MRI should be performed to visualise the spinal cord (Fig. 4). Using this combination of methods vertical subluxation will be missed in only 6% of patients [4]. It is mandatory to diagnose vertical subluxation; this can be fatal because of the proximity of the dens to the medulla oblongata and the proximal portion of the spinal cord. Risk of cord compression/injury occurs, especially in patients with flexion instability accompanied by erosive changes in the atlanto-axial and/or atlanto-occipital joints, causing the vertical subluxation with protrusion of the dens into the occipital foramen (Figs. 4, 5).

Subaxial RA changes also occur in the form of arthritis of the apophyseal and/or uncovertebral joints, appearing as narrowing and superficial erosions by radiography. It can cause instability in the C2-Th1 region, which is mainly seen in patients with severe chronic peripheral arthritis. Anterior subluxation is far more frequent than posterior subluxation. It is defined as at least 3 mm forward slippage of a vertebra

Fig. 5 Vertical subluxation with spinal cord compression. MRI of the cervical spine in a 69-year-old woman with advanced peripheral RA, neck pain and clinical signs of myelopathy. (a) Sagittal STIR, (b) sagittal T1 and (c) axial T2 fat-saturated (FS) images show erosion of the dens and protrusion of the tip into the occipital foramen causing compression of the spinal cord, which exhibits irregular signal intensity (white arrows). The osseous spinal canal has a width of approximately 7 mm (black line). There is heterogeneous signal intensity pannus surrounding the dens compatible with a mixture of fibrotic and oedematous pannus tissue (black arrows) in the widened space between the dens and the anterior arc of the atlas



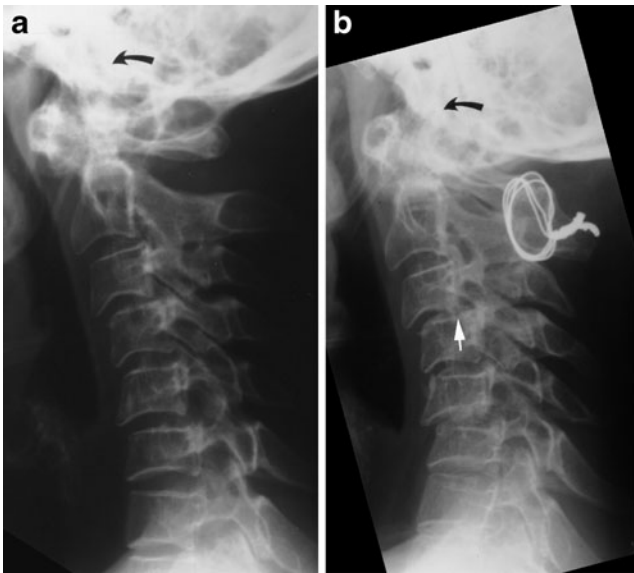


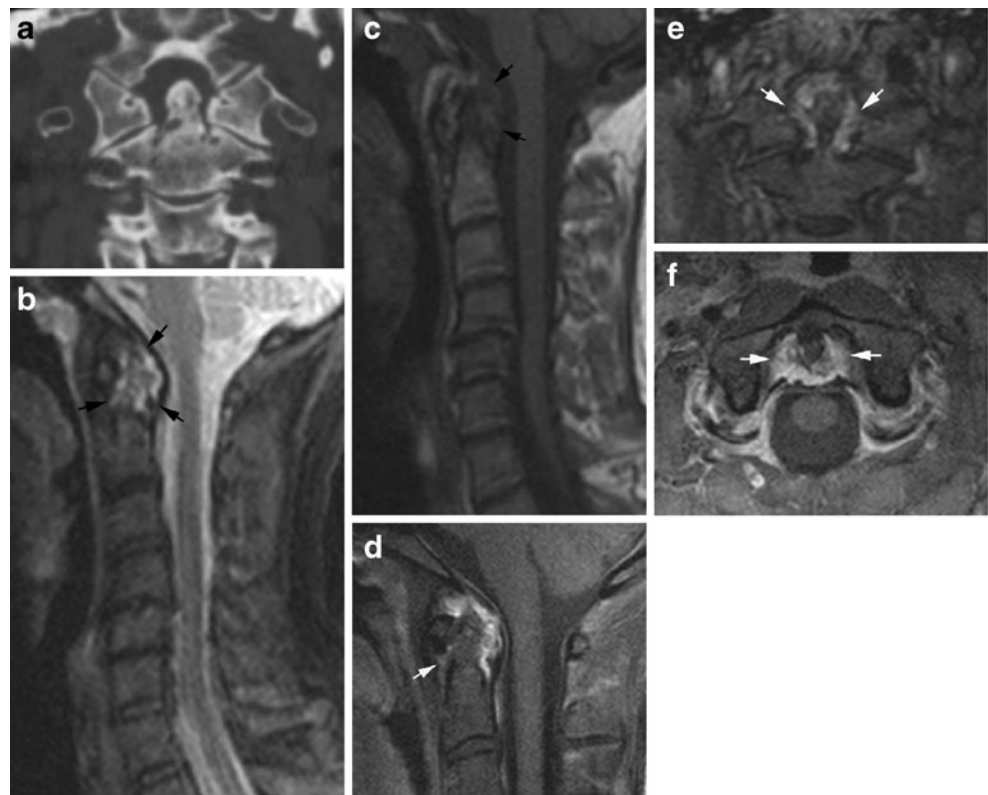
Fig. 6 Subaxial instability. (a) Flexion view in a 64-year-old woman with advanced peripheral RA showing anterior atlanto-axial instability as well as subaxial instability at multiple levels. (b) Flexion view 2 years later after surgical stabilisation of the atlanto-axial region demonstrates progression of the subaxial instability, especially between C3 and C4 (white arrow). There is a characteristic “stepladder” appearance, which also occurred on the initial radiographs (a), but is less pronounced

relative to the underlying vertebra by radiography including a flexion view (Fig. 6). Changes are particularly characteristic at the C3–4 and C4–5 level, but multiple levels may be involved, producing a typical “stepladder” appearance on lateral radiographs. The condition is serious if the subaxial sagittal spinal canal diameter is <14 mm, implying a possibility of spinal cord compression [2]. The instability may progress over time, especially if the C1–C2 region is stabilised surgically (Fig. 6) [5].

Discitis-like changes and spinous process erosion may also be detected by radiography in RA, but are relatively rare, whereas concomitant degenerative changes occur occasionally (Fig. 1).

Cross-sectional imaging in the form of CT and MRI eliminates overprojecting structures and can improve the detection of RA changes. Osseous changes (erosions, etc.) can be clearly delineated by CT [6]. Additionally, MRI visualises soft tissue structures (pannus; spinal cord, etc.), signs of disease activity and sequelae of inflammation in the form of fibrous pannus. These advantages of CT and MRI in patients with atlanto-axial involvement are illustrated in Figs. 7 and 8, including the possibility of detecting signs of arthritis by MRI before the occurrence of erosive changes (Fig. 8) [3].

Fig. 7 Advantages of CT and MRI. (a) Supplementary CT and (b–f) MRI of the patient shown in Fig. 1. CT demonstrates erosion not only at the base of the dens, but also at the tip and at the atlanto-axial and atlanto-occipital joints, which are difficult to visualise by radiography. MRI, (b) sagittal STIR and (c) sagittal T1 of the entire cervical spine and post-contrast T1FS images of the atlanto-axial region, (d) sagittal, (e) coronal and (f) axial. Oedematous voluminous pannus surrounding the dens is seen on the STIR and T1 images (black arrows) in addition to C4/5 and C5/6 disc degeneration with posterior protrusion of the disc at C4/5. The post-contrast T1FS images confirm the presence of vascularised enhancing pannus around the dens (white arrows) and demonstrate improved anatomical delineation compared with the STIR image. There is no sign of spinal cord compression



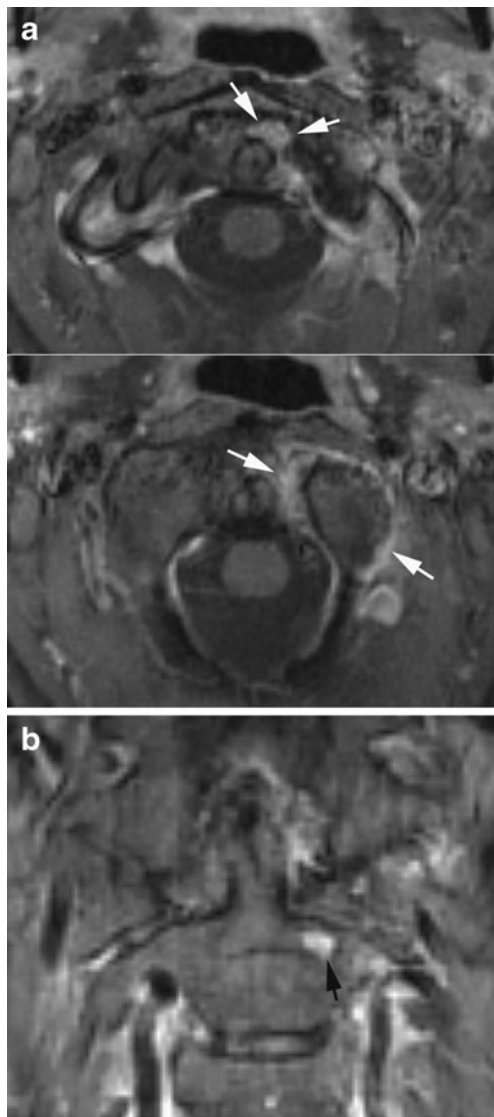


Fig. 8 *Non-radiographic MR findings.* MRI in a 41-year-old woman with peripheral erosive RA and neck pain, but normal cervical radiography. **(a)** Post-contrast axial and **(b)** coronal T1FS images show signs of active arthritis with synovial contrast enhancement at the left atlanto-axial joint in addition to enhancing pannus tissue at the left side of the dens (white arrows). There is also a subchondral enhancing area in the axis (black arrow) compatible with a pre-erosive lesion

A diagnostic strategy according to Younes et al. [3] is recommended (Fig. 9). This includes an indication for radiography in all RA patients with disease duration >2 years as cervical involvement may occur in over 70% of patients and has been reported to be asymptomatic in 17% of RA patients. It is recommended to monitor patients with manifest peripheral erosions accompanied by RF (rheumatoid factor) and antiCCP (antibodies to cyclic citrullinated peptide) positivity every second year and

patients with few peripheral erosions and RF negativity at 5-year intervals. MRI is indicated in patients with neurological deficit, radiographic instability, vertical subluxation and subaxial stenosis [2, 3]. Visualisation of the spinal cord is especially important to detect cord injury or risk of injury. MRI should therefore always be performed in RA patients with neck pain and/or neurological symptoms [3, 7].

Seronegative spondyloarthritides

According to European classification criteria [8, 9], SpA is divided into: (1) ankylosing spondylitis (AS), (2) psoriatic arthritis, (3) reactive arthritis, (4) arthritis associated with inflammatory bowel disorders (enteropathic arthritis) and (5) undifferentiated SpA. Inflammatory changes at the sacroiliac joints always occur in AS and are part of most other forms of SpA. Spinal changes are also a feature of SpA, especially in the late stages of AS.

Ankylosing spondylitis

Ankylosing spondylitis is the most frequent and usually the most disabling form of SpA. It has a genetic predisposition in the form of a frequent association with the human leukocyte antigen (HLA) B27 [10]. AS often starts in early adulthood and has a chronic progressive course. It is therefore important to diagnose this disorder. According to the modified New York Criteria [11], the diagnosis of definite AS requires the following: manifest sacroiliitis by radiography (grade ≥ 2 bilateral or unilateral grade 3–4 sacroiliitis; Fig. 10) and at least one of the following clinical criteria: (1) low back pain and stiffness for more than 3 months improving with activity, (2) limited movement of the lumbar spine and (3) reduced chest expansion. These criteria are still used in the diagnosis of AS despite the increasing use of MRI to detect the disease early. It is therefore important to know both the characteristic radiographic features and the MR features of AS.

Early radiographic spinal changes encompass erosion of vertebral corners (Romanus lesions) causing vertebral squaring and eliciting reactive sclerosis appearing as condensation of vertebral corners (shiny corners; Fig. 10). These changes are caused by inflammation at the insertion of the annulus fibrosus (enthesitis) at vertebral corners provoking reactive bone formation [12]. Later on slim ossifications appear in the annulus fibrosus (syndesmophytes) (Fig. 11) [13]. With disease progression the spine gradually fuses because of syndesmophytes crossing the intervertebral spaces in addition to fusion of apophyseal joints, resulting in complete spinal fusion (bamboo spine;

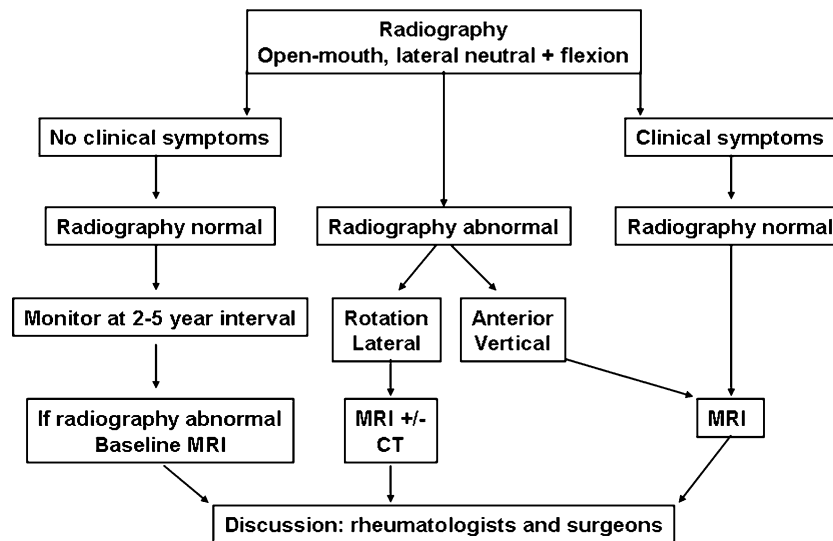


Fig. 9 *Diagnostic strategy.* According to Younes et al. [3] radiography of the cervical spine is indicated in all RA patients with disease duration >2 years. It should at least include open-mouth and lateral views in neutral and flexed positions. Because of the occurrence of asymptomatic cervical involvement in 17% of RA patients, it is recommended to monitor patients with intervals of 2–5 years depend-

ing on positivity for the rheumatoid factor. MRI is indicated in patients with neurological deficit, radiographic instability, atlanto-axial impaction and subaxial stenosis. CT may add information in rotatory and lateral subluxation because of the possibility of secondary reconstruction in arbitrary planes and a clear visualisation of the atlanto-occipital joints [6]

Fig. 12). In advanced disease the supra- and interspinous ligaments may ossify and be visible on frontal radiographs as a slim ossified streak (Fig. 12). The occurrence of a single central radiodense streak has been named the “dagger sign”. When the ligamentous ossification occurs together with ossification of apophyseal joint capsules, there are three vertical radiodense lines on frontal radiography (trolley-track sign).

Erosive changes within intervertebral spaces (Andersson lesions) have been detected by radiography in approximately 5% of patients with AS [14], but more frequently by MRI (Fig. 11) [15].

Persistent movement at single intervertebral spaces may occur in an otherwise ankylosed spine, sometimes caused by non-diagnosed fractures. This can result in pseudoarthrosis-like changes with the formation of surrounding reactive osteophytes due to excessive mechanical load at single movable intervertebral spaces [14]. The diagnosis of such changes may require a CT examination to obtain adequate visualisation (Fig. 13).

One of the life-threatening complications of AS is spinal fracture. Non-fatal fractures have been reported to occur in up to 6% of AS patients, especially in patients with long disease duration [16]. Fractures may occur after minor trauma because of the spinal stiffness and frequently accompanying osteoporosis. Fractures often occur at intervertebral spaces, but usually involve the ankylosed posterior structures and are thereby unstable (Fig. 14). Obvious fractures can be

diagnosed by radiography, but fractures may be obscured. It is therefore mandatory to supplement a negative radiography with CT if fracture is suspected (in the case of trauma history or a change in spinal symptoms). The occurrence of cervico-thoracic fractures may cause spinal cord injury and be lethal even following minor trauma [17].

Cross-sectional CT or MR imaging can be advantageous in the diagnosis of AS changes. CT providing a clear delineation of osseous structures is the preferred technique for visualising pseudoarthrosis and detecting fractures (Figs. 13, 14). CT is superior to MRI in detecting minor osseous lesions such as erosion and ankylosis of the apophyseal, costo-vertebral and costo-transversal joints (Fig. 15). MRI can visualise signs of active inflammation in the form of bone marrow and soft tissue oedema and/or contrast enhancement. It has therefore gained a central role in the evaluation of disease activity [15]. MRI can, however, also detect sequelae of inflammation consisting of fatty deposition in the bone marrow and chronic structural changes such as erosion and fusion of vertebral bodies [15].

Characteristic MR findings early in the disease are activity changes mainly consisting of oedema at vertebral corners and/or costo-vertebral joints (Fig. 16) [13]. The inflammatory changes at vertebral corners are characteristic of AS. Based on the occurrence of severe or multiple (≥ 3) lesions in young patients, AS changes can be distinguished from degenerative changes with a high reliability [18].

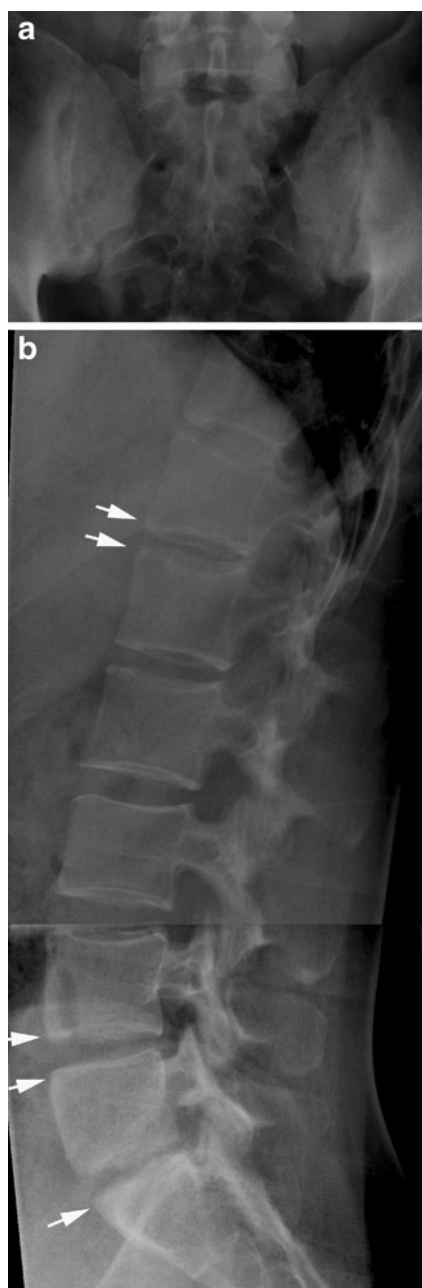

Fig. 10 Relatively early changes in ankylosing spondylitis (AS). (a) AP radiograph of the sacroiliac joints in a 28-year-old man presenting with typical definite bilateral AS sacroiliitis (grade 3) in the form of bilateral joint erosion accompanied by subchondral sclerosis. (b) Initial spinal changes consisting of erosion of vertebral corners (Romanus lesion) with vertebral squaring corresponding to Th11, Th12, L4 and L5 accompanied by condensation of the vertebral corners—shiny corners (arrows)

During the disease course signs of activity can also occur at syndesmophytes, apophyseal joints and interspinous ligaments (Fig. 16). Detection of inflammation at apophyseal joints by MRI, however, demands pronounced involvement

histopathologically [19]. The inflammation at vertebral corners is the most valid feature and has been observed related to the development of syndesmophytes by radiography [12], establishing a link between signs of disease activity and chronic structural changes.

Chronic AS changes detectable by MRI mainly consist of fatty marrow deposition at vertebral corners (Fig. 17), erosion (Fig. 11) and vertebral fusion in advanced disease (Fig. 12). Fatty marrow deposition seems to be an important sign of chronicity being significantly correlated with radiographic changes, in particular vertebral squaring [15]. Erosions are more frequently detected by MRI than by radiography (Fig. 11) [15] and can present with signs of active inflammation and/or surrounding fatty marrow deposition compatible with sequels of osseous inflammation. Syndesmophytes, however, may not always be visible by MRI because they may be difficult to distinguish from fibrous tissue unless there is concomitant active inflammation or fatty deposition (Figs. 11, 16) [15, 20].

The possibility of visualising disease activity by MRI has increased its use to monitor AS, especially during anti-TNF (anti-tumour necrosis factor) therapy [21, 22]. Several studies have shown that MR changes are frequent in the thoracic spine (Fig. 16) [15, 23]. It is therefore important to examine the entire spine using sagittal STIR or T2 fat-saturated (FS) and T1-weighted sequences. Supplementary axial slices can be necessary for visualising involvement of apophyseal, costo-vertebral and costo-transverse joints (Fig. 16) [24, 25]. Post-contrast T1FS sequences can sometimes be advantageous as they provide better anatomical delineation [26]. Additionally, dynamic contrast-enhanced MRI may be superior to static MRI in monitoring disease activity during anti-TNF therapy [27]. Whole-body MRI gives the possibility of detecting involvement in other areas without losing important information about spinal and sacroiliac joint involvement [28, 29].

Other forms of SpA

Radiographic changes in reactive and psoriatic arthritis are often characterised by voluminous non-marginal syndesmophytes (parasyndesmophytes) or coalescing ossification of the paravertebral ligaments in addition to asymmetrical sacroiliitis (Fig. 18) [30].

Reactive arthritis is self-limiting in most patients. However, in patients with chronic reactive arthritis and HLA B27 the axial changes may progress to changes somewhat similar to those seen in AS and can then be regarded as AS elicited by infection [10].

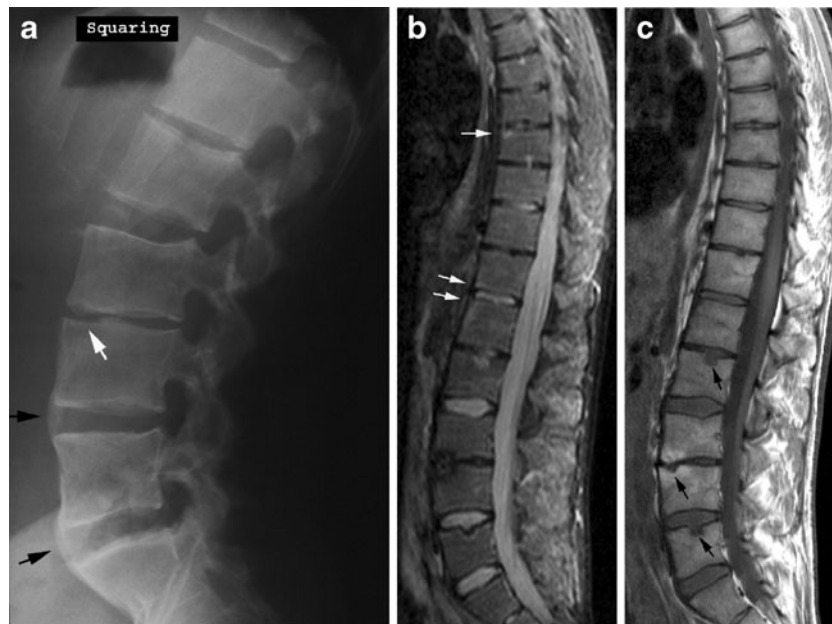
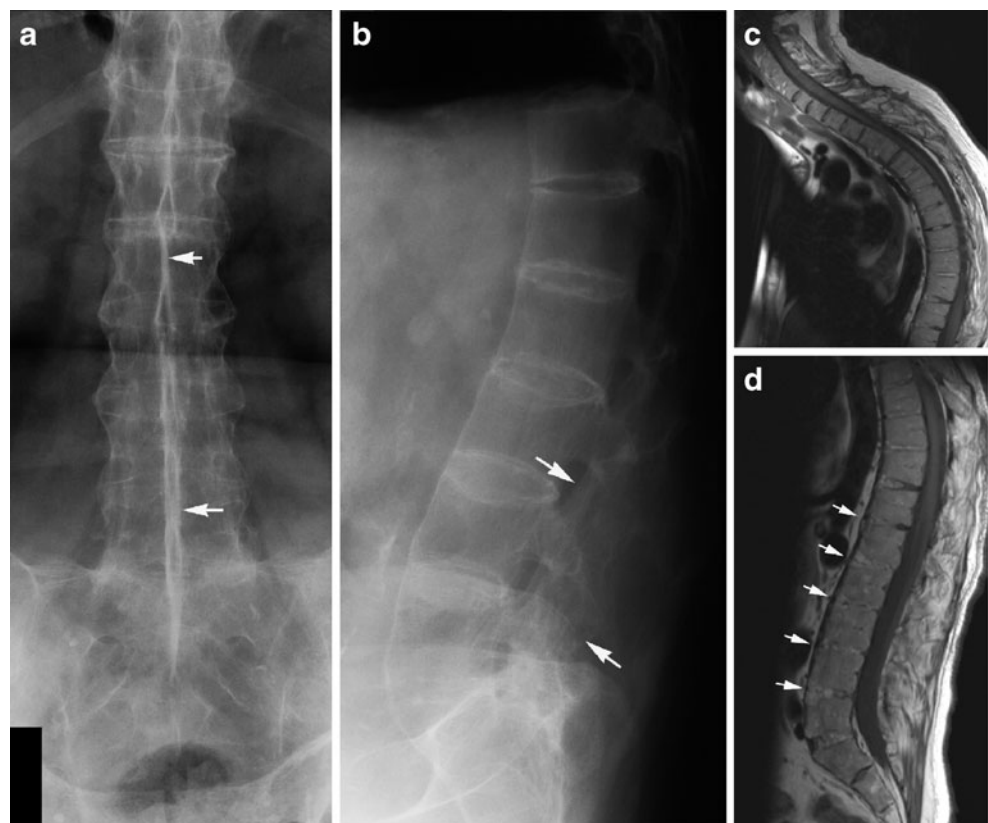


Fig. 11 Syndesmophytes and erosions in AS. (a) Lateral radiograph in a 29-year-old man with the characteristic slim ossification (syndesmophytes) at the periphery of the annulus fibrosus (black arrows) in addition to erosion of the endplates at the intervertebral (iv) space between L3 and L4 (white arrow). Supplementary MRI, (b) sagittal STIR and (c) T1-weighted images show small oedematous areas in the

erosion at iv L3/4 on the STIR image and surrounding fatty marrow deposition on T1 as a sign of previous osseous inflammation. There are additional erosive changes (black arrows, c) not clearly delineated by radiography and slight oedema at the vertebral corners (white arrows, b). Note that the syndesmophytes demonstrated by radiography are not visible on MRI

Fig. 12 Advanced AS. (a) AP and (b) lateral radiograph in a 55-year-old man showing vertebral fusion due to syndesmophytes crossing the intervertebral spaces in addition to fusion of the apophyseal joints (bamboo spine). The interspinous ligaments are ossified, presenting as a slim ossified streak on the frontal radiograph (dagger sign; arrows). MRI, sagittal T1-weighted images of (c) the cervico-thoracic and (d) lumbar region, respectively, shows a general narrowing of the intervertebral discs with partial osseous fusion of the vertebral bodies, especially in the lumbar region (arrows). In addition a characteristic AS deformity with reduced lumbar lordosis and thoracic kyphosis



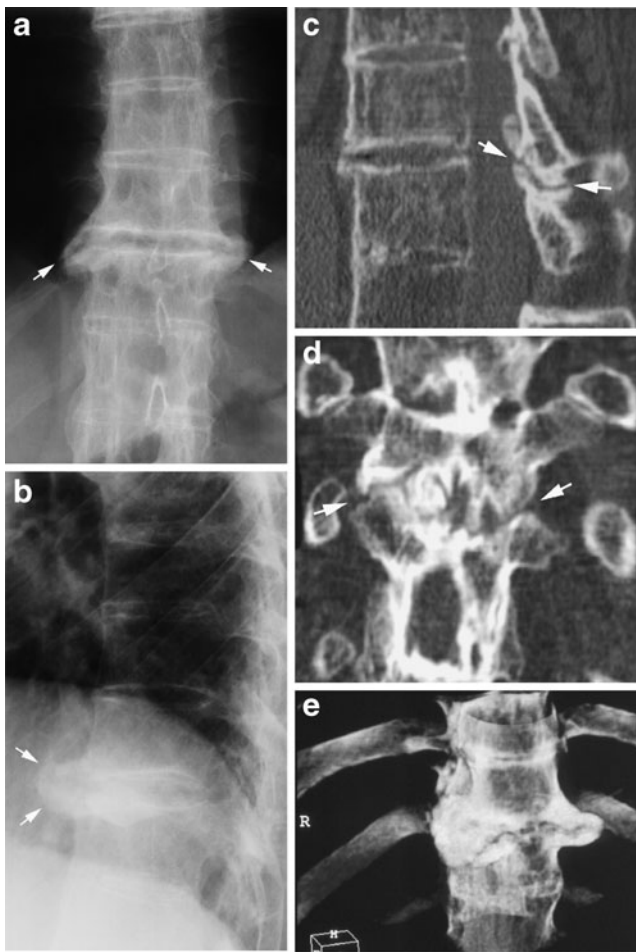


Fig. 13 Pseudo-arthritis-like changes in AS. (a) AP and (b) lateral radiograph showing vertebral fusion except at iv Th10/11. There is surrounding osteophyte formation at this iv space (arrows). Supplementary CT, (c) sagittal and (d) coronal 2D reconstruction, demonstrates lack of fusion of the vertebral bodies and apophyseal joints at this level (arrows). (e) 3D reconstruction clearly demonstrates the exuberant surrounding reactive osteophytes

Axial psoriatic arthritis (PsA) occurs in approximately 50% of patients with peripheral PsA [31]. It differs radiographically from AS by the voluminous paravertebral ossifications and the occurrence of spinal changes without concomitant sacroiliitis in 10% of patients [32]. Axial PsA may be clinically silent [33], and involvement of the cervical spine is frequent (atlanto-axial or apophyseal joint changes). The cervical changes may include atlanto-axial instability as seen in RA (Fig. 19), but the pathogenesis and thereby imaging findings are different. In PsA radiography and CT usually visualise new bone formation in the region of the dens. This is elicited by osseous inflammation (osteitis) and/or inflammation at ligament/tendon attachments (enthesitis) detectable by MRI (Fig. 19). Osteitis is often a feature of spinal PsA and can occur together with paravertebral ossification/parasyndesmophytes and erosion of vertebral plates (Fig. 20). The above-mentioned and illustrated MR findings in PsA are based on personal observations and seem to reflect the radiographic changes encompassing a mixture of osteitis, enthesitis and erosion. Unfortunately, there is a lack of

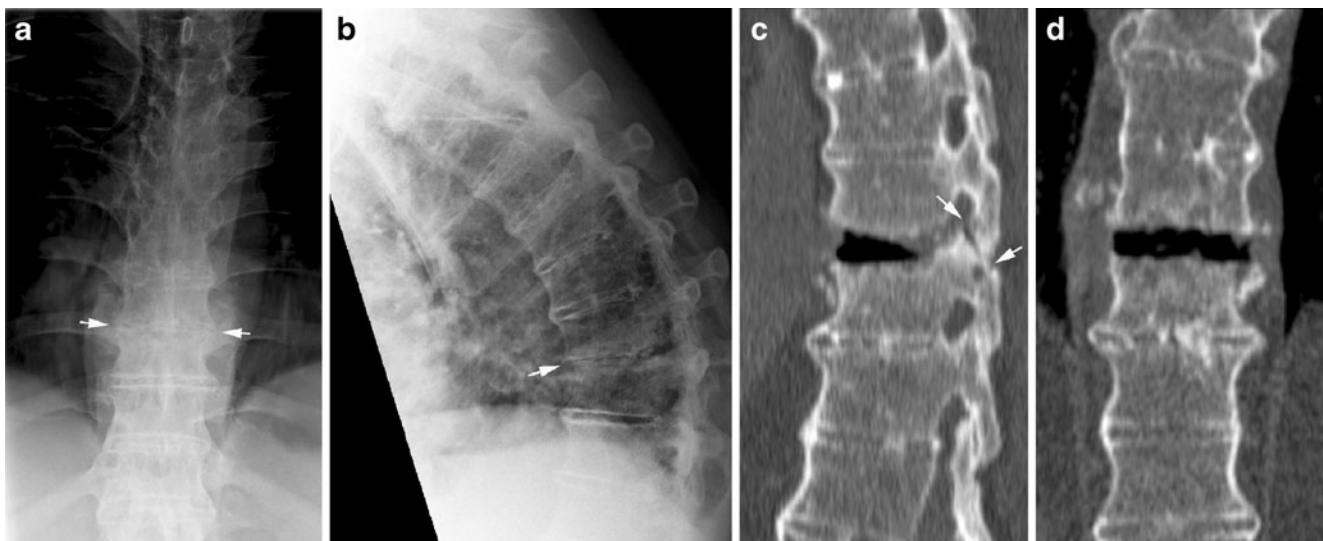


Fig. 14 Spinal fracture in AS. (a) AP and (b) lateral radiograph of the thoracic spine in a 64-year-old man with advanced AS and increasing back pain over 4 weeks. The lateral view demonstrates a slight malalignment at the anterior aspects of the vertebral bodies of Th9 and Th10, and the iv is irregularly narrowed on the AP view, all

suggesting fracture (arrows). CT, (c) sagittal and (d) coronal reconstruction, shows fracture through the iv space and the posterior structures (arrows). There is widening of the intervertebral space anteriorly in the supine position used for CT compared with the upright position used during radiography

Fig. 15 CT detection of costo-vertebral changes in AS. Axial CT slices showing erosive changes (a) and ankylosis of costo-vertebral joints (b), respectively (arrows)

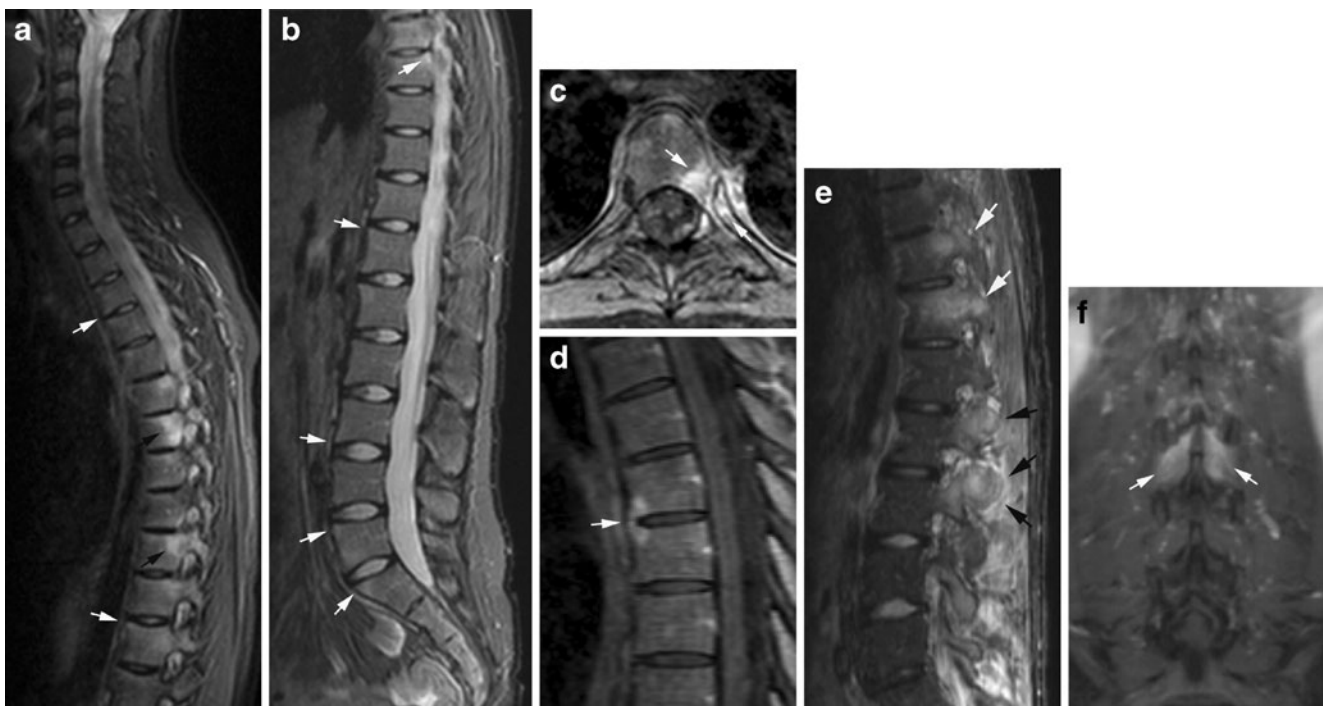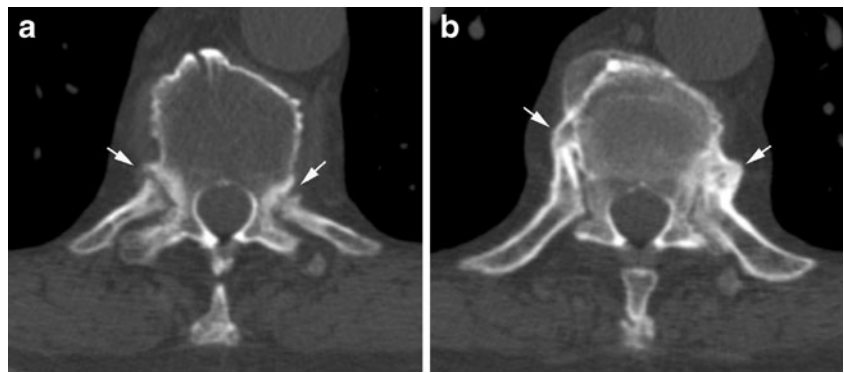


Fig. 16 Activity changes in AS by MRI. Sagittal STIR of (a) the cervico-thoracic and (b) the lumbar spine of the patients shown in Fig. 10 obtained 3 years before the radiography. There are multiple high signal intensity areas corresponding to vertebral corners (white arrows). Additionally, osseous oedema of the costo-vertebral joints (a, black arrows) seen on the lateral sagittal slice of the thoracic spine. (c) Axial post-contrast T1FS of an inflamed costo-vertebral joint confirmed the presence of joint inflammation in the form of osseous enhancement in both the vertebra and the rib (arrows) in addition to joint erosion. (d) Midline sagittal post-contrast T1FS shows an

enhancing syndesmophyte. (e) Inflammatory changes at the apophyseal joint in a 27-year-old man; sagittal STIR image of the lumbar region showing subchondral osseous oedema in the lower thoracic region (white arrows), and both osseous and soft tissue oedema corresponding to the lumbar apophyseal joints (black arrows). Note that the osseous oedema in the pedicle of Th12 extends to the region of the costo-vertebral joint. (f) Coronal post-contrast T1FS of the lumbar spine shows additional enhancement corresponding to the interspinous ligament between L2 and L3 (arrows)

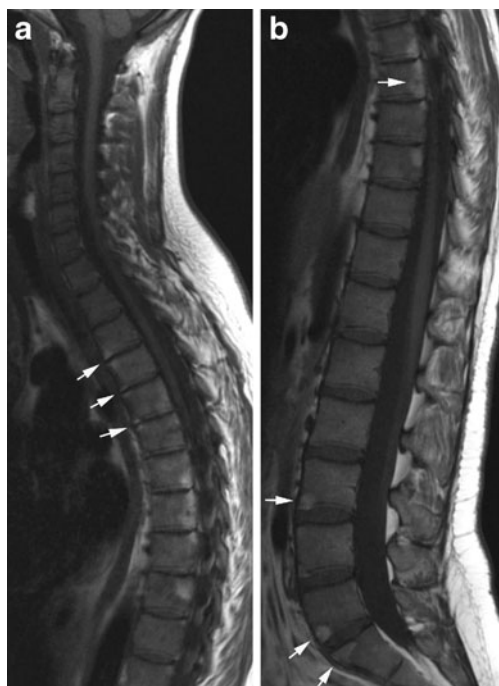

Fig. 17 Chronic changes in AS by MRI. Sagittal T1 of (a) the cervicothoracic and (b) the lumbar spine of the patients shown in Fig. 10. There are multiple fatty marrow depositions at vertebral corners and also posteriorly in thoracic vertebral bodies (b, arrows). This was observed to have developed since the MRI performed 3 years previously (shown in Fig. 16 a–d) and corresponds to areas of previous inflammation

systematic description of spinal changes in PsA by MRI. Some of the patients described under the term SAPHO (synovitis, acne, pustulosis, hyperostosis, osteitis) syndrome may have PsA. SAPHO is a collective term often used for inflammatory disorders primarily presenting with osseous hyperostosis and sclerosis, and they are frequently associated with skin disorders. The most commonly affected site in SAPHO is the anterior chest followed by the spine [34]. The PsA changes shown in Fig. 20 are characterised by hyperostosis and sclerosis, both main features of SAPHO. However, this patient did not have anterior chest involvement.

In patients with enteropathic arthritis associated with Crohn's disease or ulcerative colitis, the spine is often osteoporotic with various accompanying SpA features by radiography, mostly AS-like changes. However, by MRI there may be more pronounced inflammation in the posterior ligaments than seen in the other forms of SpA (Fig. 21).

Conclusion

Radiography is still valuable in the diagnosis of spinal inflammatory disorders. It is necessary for visualising instability and is superior to MRI for detecting syndesmophytes. However, MRI and CT can detect signs of spinal involvement before they can be visualised by radiography. MRI adds information about potential involvement of the spinal cord and nervous roots in addition to signs of disease activity and chronic changes such as fibrous pannus in RA and fatty marrow deposition, erosion and vertebral fusion in SpA. MRI is

Fig. 18 Psoriatic arthritis (PsA), paravertebral ossifications. (a) AP and (b) lateral radiograph of the lumbar spine in a 48-year-old man with PsA showing voluminous paravertebral new bone formation (arrows) in addition to fusion of the second and third vertebral bodies. There was no concomitant sacroiliitis. (c) AP radiograph of the thoracolumbar junction in a female patient with axial PsA demonstrating coalescing paravertebral ossifications (arrows)

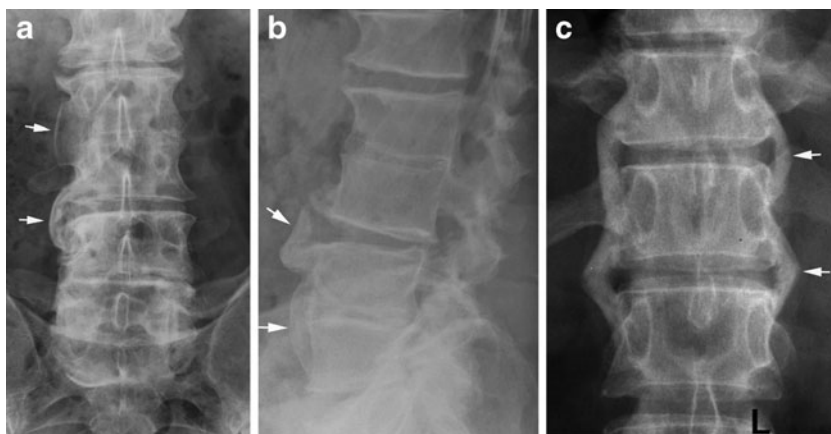


Fig. 19 *Cervical PsA.* (a) Lateral radiographs in the neutral position and (b) during flexion in a 61-year-old woman show atlanto-axial instability with a 4-mm distance between the anterior arc and the dens (white line). Additionally, ankylosis of the apophyseal joints (black arrows) and new bone formation anterior to the C4-7 vertebral bodies (white arrows). CT, (c) axial slice and coronal reconstruction of the dens area, demonstrates new bone formation in the atlanto-axial region (arrows); (d) coronal reconstruction of the lower cervical region shows voluminous new bone formation on the right side of the vertebral bodies (arrows). MRI, (e) sagittal STIR and (f) T1-weighted images, shows homogeneous osseous inflammation corresponding to the dens (arrows) with surrounding irregular oedema compatible with a mixture of osteitis and enthesitis. Note that the anterior new bone formation visualised by radiography is difficult to detect on MRI

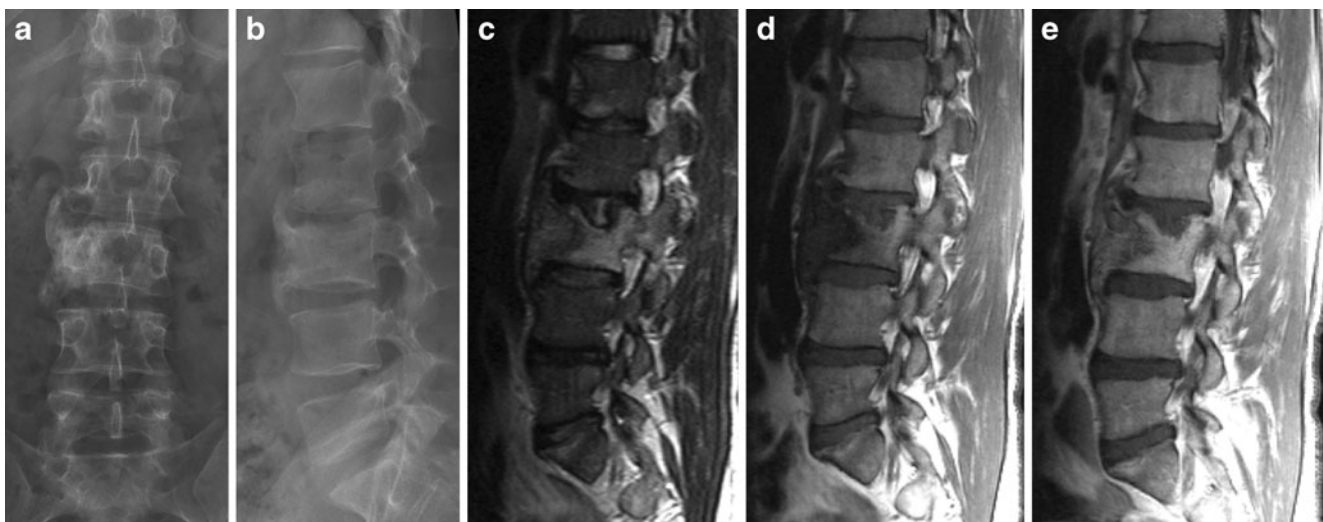
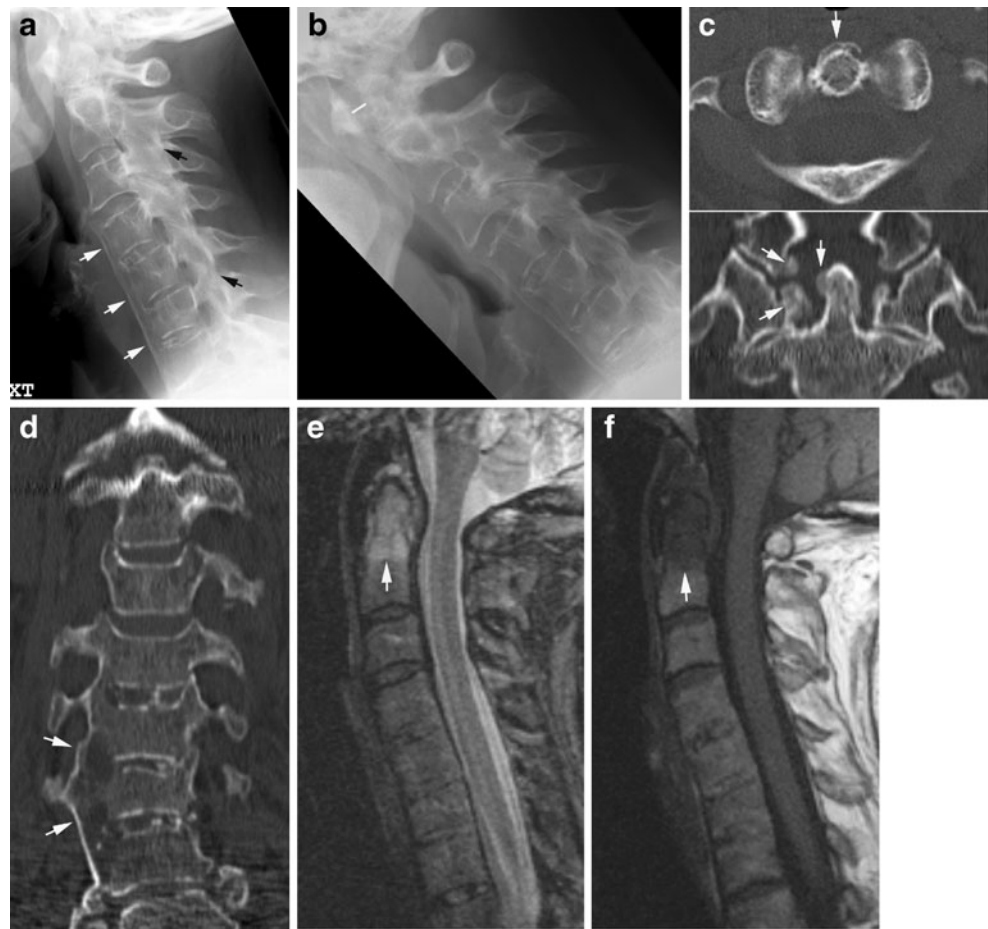
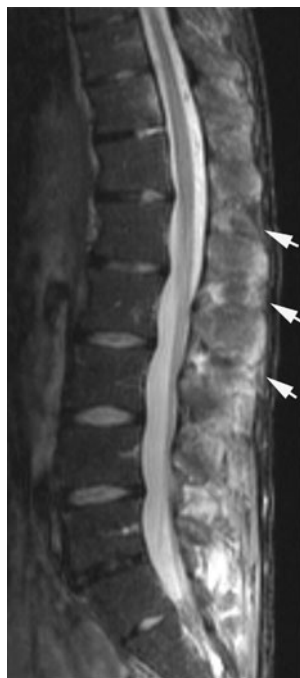
Fig. 20 *Lumbar PsA.* (a) AP and (b) lateral radiograph in a 50-year-old man show voluminous paravertebral ossifications anteriorly and at the right side of the third lumbar vertebra and adjacent iv spaces. MRI, (c) sagittal STIR, (d) T1 and (e) post-contrast T1-weighted images, demonstrates manifest osseous inflammation (osteitis) in the form of

oedema and enhancement of the vertebral body, slight enhancement in the paravertebral new bone formation and erosion of the upper vertebral plate compatible with a mixture of osteitis, enthesitis and erosive changes

Fig. 21 *Enteropathic SpA.* Sagittal STIR image of the lumbar spine in a 27-year-old man with ulcerative colitis demonstrates oedema corresponding to the interspinous ligaments (arrows) and spinous processes as signs of inflammation. There are only minimal activity changes corresponding to the vertebral bodies, located to the anterior vertebral corners



therefore widely used to monitor inflammatory spinal diseases, especially during anti-TNF therapy.

Computed tomography is particularly valuable in the detection of fracture and minor osseous lesions as well as in the evaluation of pseudo-arthritis.

References

- Paus AC, Steen H, Roislien J, Mowinckel P, Teigland J (2008) High mortality rate in rheumatoid arthritis with subluxation of the cervical spine: a cohort study of operated and nonoperated patients. *Spine* 33(21):2278–2283
- Kim DH, Hilibrand AS (2005) Rheumatoid arthritis in the cervical spine. *J Am Acad Orthop Surg* 13(7):463–474
- Younes M, Belghali S, Kriaa S, Zrou S, Bejia I, Touzi M et al (2009) Compared imaging of the rheumatoid cervical spine: prevalence study and associated factors. *Joint Bone Spine* 76(4):361–368
- Riew KD, Hilibrand AS, Palumbo MA, Sethi N, Bohlman HH (2001) Diagnosing basilar invagination in the rheumatoid patient. The reliability of radiographic criteria. *J Bone Joint Surg Am* 83(2):194–200
- Ishii K, Matsumoto M, Takahashi Y, Okada E, Watanabe K, Tsuji T et al (2010) Risk factors for development of subaxial subluxations following atlantoaxial arthrodesis for atlantoaxial subluxations in rheumatoid arthritis. *Spine* 35(16):1551–1555
- Iizuka H, Sorimachi Y, Ara T, Nishinome M, Nakajima T, Iizuka Y et al (2008) Relationship between the morphology of the atlanto-occipital joint and the radiographic results in patients with atlanto-axial subluxation due to rheumatoid arthritis. *Eur Spine J* 17(6):826–830
- Narvaez JA, Narvaez J, Serrallonga M, De Lama E, de AM, Mast R et al (2008) Cervical spine involvement in rheumatoid arthritis: correlation between neurological manifestations and magnetic resonance imaging findings. *Rheumatology (Oxford)* 47(12):1814–1819
- Dougados M, van der Linden S, Juhlin R, Huitfeldt B, Amor B, Calin A et al (1991) The European Spondylarthropathy Study Group preliminary criteria for the classification of spondylarthropathy. *Arthritis Rheum* 34:1218–1227
- Rudwaleit M, van der Heijde D, Landewe R, Listing J, Akkoc N, Brandt J et al (2009) The Development of Assessment of SpondyloArthritis international Society (ASAS) classification criteria for axial spondyloarthritis (Part II): validation and final selection. *Ann Rheum Dis* 68(6):777–783
- Sieper J, Rudwaleit M, Khan MA, Braun J (2006) Concepts and epidemiology of spondyloarthritis. *Best Pract Res Clin Rheumatol* 20(3):401–417
- van der Linden S, Valkenburg HA, Cats A (1984) Evaluation of diagnostic criteria for ankylosing spondylitis. A proposal for modification of the New York criteria. *Arthritis Rheum* 27:361–268
- Maksymowych WP, Chiowchanwisawakit P, Clare T, Pedersen SJ, Ostergaard M, Lambert RG (2009) Inflammatory lesions of the spine on magnetic resonance imaging predict the development of new syndesmophytes in ankylosing spondylitis: evidence of a relationship between inflammation and new bone formation. *Arthritis Rheum* 60(1):93–102
- Sieper J, Rudwaleit M, Baraliakos X, Brandt J, Braun J, Burgos-Vargas R et al (2009) The Assessment of SpondyloArthritis international Society (ASAS) handbook: a guide to assess spondyloarthritis. *Ann Rheum Dis* 68(Suppl 2:ii):1–44
- Park WM, Spencer DG, McCall IW, Ward J, Buchanan WW, Stephens WH (1981) The detection of spinal pseudarthrosis in ankylosing spondylitis. *Br J Radiol* 54(642):467–472
- Madsen KB, Jurik AG (2009) MRI grading method for active and chronic spinal changes in spondyloarthritis. *Clin Radiol* 65:6–14
- Feldtkeller E, Vosse D, Geusens P, van der Linden S (2006) Prevalence and annual incidence of vertebral fractures in patients with ankylosing spondylitis. *Rheumatol Int* 26(3):234–239
- Thomsen AH, Uhreholt L, Jurik AG, Vesterby A (2010) Traumatic death in ankylosing spondylitis—a case report. *J Forensic Sci* 55(4):1126–1129
- Bennett AN, Rehman A, Hensor EM, Marzo-Ortega H, Emery P, McGonagle D (2009) Evaluation of the diagnostic utility of spinal magnetic resonance imaging in axial spondylarthrosis. *Arthritis Rheum* 60(5):1331–1341
- Appel H, Loddenkemper C, Grozdanovic Z, Ebhardt H, Dreimann M, Hempfing A et al (2006) Correlation of histopathological findings and magnetic resonance imaging in the spine of patients with ankylosing spondylitis. *Arthritis Res Ther* 8(5):R143
- Braun J, Baraliakos X, Golder W, Hermann KG, Listing J, Brandt J et al (2004) Analysing chronic spinal changes in ankylosing spondylitis: a systematic comparison of conventional x rays with magnetic resonance imaging using established and new scoring systems. *Ann Rheum Dis* 63(9):1046–1055
- Baraliakos X, Listing J, Brandt J, Haibel H, Rudwaleit M, Sieper J et al (2007) Radiographic progression in patients with ankylosing spondylitis after 4 years of treatment with the anti-TNF-alpha antibody infliximab. *Rheumatology (Oxford)* 46(9):1450–1453
- Lambert RG, Salonen D, Rahman P, Inman RD, Wong RL, Einstein SG et al (2007) Adalimumab significantly reduces both spinal and sacroiliac joint inflammation in patients with ankylosing spondylitis: a multicenter, randomized, double-blind, placebo-controlled study. *Arthritis Rheum* 56(12):4005–4014
- Baraliakos X, Landewe R, Hermann KG, Listing J, Golder W, Brandt J et al (2005) Inflammation in ankylosing spondylitis: a systematic description of the extent and frequency of acute spinal

- changes using magnetic resonance imaging. *Ann Rheum Dis* 64 (5):730–734
24. Khanna M, Keightley A (2005) MRI of the axial skeleton manifestations of ankylosing spondylitis. *Clin Radiol* 60(1):135–136
 25. Levine DS, Forbat SM, Saifuddin A (2004) MRI of the axial skeletal manifestations of ankylosing spondylitis. *Clin Radiol* 59 (5):400–413
 26. Baraliakos X, Hermann KG, Landewe R, Listing J, Golder W, Brandt J et al (2005) Assessment of acute spinal inflammation in patients with ankylosing spondylitis by magnetic resonance imaging: a comparison between contrast enhanced T1 and short tau inversion recovery (STIR) sequences. *Ann Rheum Dis* 64 (8):1141–1144
 27. Gaspersic N, Sersa I, Jevtic V, Tomsic M, Praprotnik S (2008) Monitoring ankylosing spondylitis therapy by dynamic contrast-enhanced and diffusion-weighted magnetic resonance imaging. *Skeletal Radiol* 37(2):123–131
 28. Weber U, Maksymowych WP, Jurik AG, Pfirmann CW, Rufibach K, Kissling RO et al (2009) Validation of whole-body against conventional magnetic resonance imaging for scoring acute inflammatory lesions in the sacroiliac joints of patients with spondylarthritis. *Arthritis Rheum* 61(7):893–899
 29. Weber U, Hodler J, Jurik AG, Pfirmann CW, Rufibach K, Kissling RO et al (2010) Assessment of active spinal inflammatory changes in patients with axial spondyloarthritis: validation of whole body MRI against conventional MRI. *Ann Rheum Dis* 69 (4):648–653
 30. Helliwell PS, Hickling P, Wright V (1998) Do the radiological changes of classic ankylosing spondylitis differ from the changes found in the spondylitis associated with inflammatory bowel disease, psoriasis, and reactive arthritis? *Ann Rheum Dis* 57(3):135–140
 31. Chandran V, Barrett J, Schentag CT, Farewell VT, Gladman DD (2009) Axial psoriatic arthritis: update on a longterm prospective study. *J Rheumatol* 36(12):2744–2750
 32. Lubrano E, Marchesoni A, Olivieri I, D'Angelo S, Spadaro A, Parsons WJ et al (2009) Psoriatic arthritis spondylitis radiology index: a modified index for radiologic assessment of axial involvement in psoriatic arthritis. *J Rheumatol* 36(5):1006–1011
 33. Hanly JG, Russell ML, Gladman DD (1988) Psoriatic spondyloarthritis: a long term prospective study. *Ann Rheum Dis* 47 (5):386–393
 34. Takigawa T, Tanaka M, Nakanishi K, Misawa H, Sugimoto Y, Takahata T et al (2008) SAPHO syndrome associated spondylitis. *Eur Spine J* 17(10):1391–1397