

Available online at [www.sciencedirect.com](http://www.sciencedirect.com)

ScienceDirect

Biomedical Journal

journal homepage: [www.elsevier.com/locate/bj](http://www.elsevier.com/locate/bj)

## Original Article

# Comparison of 3-dimensional postoperative dental movement in Class III surgical correction with and without presurgical orthodontic treatment



Rutapakon Insawak<sup>a</sup>, Cheng-Hui Lin<sup>b,d</sup>, Ying-An Chen<sup>b,d</sup>,  
Ellen Wen-Ching Ko<sup>a,c,d,\*</sup>

<sup>a</sup> Graduate Institute of Craniofacial and Oral Science, Chang Gung University, Taoyuan, Taiwan

<sup>b</sup> Department of Plastic and Reconstructive Surgery, Chang Gung Memorial Hospital at Linkou, Taoyuan, Taiwan

<sup>c</sup> Department of Craniofacial Orthodontics, Chang Gung Memorial Hospital at Taipei, Taipei, Taiwan

<sup>d</sup> Craniofacial Research Center, Chang Gung Memorial Hospital at Linkou, Taoyuan, Taiwan

## ARTICLE INFO

## Article history:

Received 15 September 2019

Accepted 21 December 2020

Available online 25 December 2020

## Keywords:

Surgery-first approach (SFA)

Postoperative dental movement

Molar extrusion

3D regional superimposition

Cone-beam computed tomography (CBCT)

## ABSTRACT

**Background:** Surgery-first approach (SFA) is an emerging concept that surgically reposition the jaw bones without presurgical orthodontic treatment phase. The study investigated 3D dental movement in the postoperative orthodontic phase with orthodontic-first (OF) and SFA in orthognathic surgery (OGS).

**Methods:** This study included consecutive 40 patients (20, SF group; 20, OF group) skeletal Class III who underwent 2-jaw OGS correction. The data of cone-beam computed tomography were acquired at 3 stages with the scan of dental models to replace the dentition of the craniofacial images; at before OGS (T0), 1 week after OGS (T1) and at the completion of treatment (T2). The skeletal changes were obtained by overall superimposition. The post-operative dental movement was measured by 3D regional superimposition between T1 and T2.

**Results:** There were no significant difference in the postsurgical orthodontic movement in both groups except significant upper and lower molars extrusion by 2 mm in the SF group. Both groups exhibited no significant difference in mandibular stability in sagittal and vertical directions. The amount of extrusion in the molars was correlated with a post-operative sagittal mandibular forward movement. The total treatment duration was significantly shorter 230 days in the SF group.

**Conclusion:** The completion of the orthodontic treatment after OGS in the SFA was mainly accomplished through molar extrusive movement in both arches. The surgical setup of dental occlusion with 4 mm posterior open bite could be corrected during the postsurgical orthodontics in SFA through molar extrusion. The dental occlusion outcome was no different between OF and SFA.

\* Corresponding author. Department of Craniofacial Orthodontics, Chang Gung Memorial Hospital at Taipei, 199, Tung Hwa North Rd., Taipei 105, Taiwan.

E-mail address: [ellenko.wc@msa.hinet.net](mailto:ellenko.wc@msa.hinet.net) (E.W.-C. Ko).

Peer review under responsibility of Chang Gung University.

<https://doi.org/10.1016/j.bj.2020.12.005>

2319-4170/© 2020 Chang Gung University. Publishing services by Elsevier B.V. This is an open access article under the CC BY-NC-ND license (<http://creativecommons.org/licenses/by-nc-nd/4.0/>).

## At a glance of commentary

### Scientific background on the subject

Non-bismuth containing quadruple therapy (concomitant therapy) is an alternative treatment for *Helicobacter pylori* (*H. pylori*) eradication with increasing clarithromycin-resistant strains over times.

### What this study adds to the field

This study reported the success rate of 7-days concomitant therapy encountered an approximately 5% decrease across 4-year time interval (2013–2017) with the changes of clarithromycin resistance from 11.8% to 17.8% in Taiwan. Provided that the local clarithromycin resistance rate has exceeded the bound of 15% and may have further increased up to now, prolongation of concomitant therapy to 10–14 days appears to be a considerable option. A change of treatment regimens such as bismuth quadruple therapy, high dose dual therapy, hybrid or reverse hybrid therapy should be also considered.

Skeletal Class III malocclusion is considered to be one of the most difficult and complex orthodontic problems to solve. These complex cases require thoughtful treatment planning, an integrated approach, and patient cooperation. The treatment of malocclusion with overriding skeletal discrepancies requires orthognathic surgery (OGS) in combination with orthodontic treatment [1,2].

Traditionally, conventional surgical orthodontic treatment is sequenced by presurgical orthodontics, OGS and post-surgical orthodontic treatment. However, one disadvantage of this approach is the deterioration of the facial profile prior to surgery due to dentoalveolar decompensation in the preoperative treatment phase [3–5].

In the surgery-first approach (SFA) concept, the jaws are surgically repositioned into a desired relation without presurgical orthodontic treatment phase. It was reported to facilitate the remaining orthodontic tooth movement and reduce the total treatment duration [2,4,6,7]. The advantages include early improvement of the facial profile and symmetry, establishing a proper inter-jaw relation before orthodontic alignment and a shorter treatment time [6,8–10]. Reduced treatment duration has become a major concern in surgical orthodontics. An accurate prediction of the final occlusion and jaw bone relation is the key to the success of OGS, especially in SFA cases. Thus, to accomplish a well aligned dentition with solid occlusal interdigitation in a frame of facial harmony, orthodontists should be aware of orthognathic principles, the limitation of orthodontic movement, and the prospective position of the teeth in the postoperative orthodontic treatment.

In the past, lateral and posteroanterior cephalometric films were used to plan surgical orthodontics. The disadvantages of 2D cephalometric analysis are tracing and landmark

identification errors, as well as the inability to detect side-effects from OGS. Thus, 3D images and digital dental model images were applied to evaluate the dental movement and orthodontic treatment outcomes instead [7,11–15]. In surgical-orthodontics, 3D craniofacial and dental model images are essential for treatment simulation and outcome evaluation. So far, no study has focused on 3D dental movement among different phases of surgical-orthodontic treatment.

The aim of this study was to investigate 3D dental movement in the postoperative orthodontic phase between patients with or without presurgical orthodontic tooth movement, as well as the occlusal factors relating to the mandibular surgical stability.

## Materials and methods

### Participants

This retrospective cohort study evaluated 40 consecutive patients who completed surgical orthodontic treatment. There were 20 patients that underwent complete presurgical orthodontic leveling, defined as the orthodontic-first (OF) group, and 20 patients did not have presurgical orthodontic movement, defined as the surgery-first (SF) group.

The inclusion criteria were: (1) patients over 18 years of age; (2) skeletal Class III and ANB  $\leq 0^\circ$ ; (3) patients who had undergone 2-jaw OGS, Le Fort I and bilateral sagittal split osteotomies for skeletal Class III malocclusion correction. All of the patients received non-extraction orthodontic therapy except the extraction of third molars. The treatments were performed by single orthodontist and 2 surgeons from the same team.

Ethical approval was obtained from the Institutional Review Board of Chang Gung Memorial Hospital, Taiwan (NO. 201600629A3).

### Data collection

Cone beam computer tomography (CBCT) images was acquired at 3 time points: before OGS (T0), 1 week after OGS (T1), and after the completion of orthodontic treatment (T2). The dental models were obtained at 2 time points: before OGS (T0) and after the completion of orthodontic treatment (T2).

### 3D composite skull reconstruction

The composite skull model was reconstructed from the skull CBCT and dental cast scan files. The CBCT images of all patients at T0, T1, and T2 were obtained using an i-CAT CBCT scanner (Imaging Science International, Halfield, PA) at a natural head orientation. The dental models at T0 and T2 were scanned and digitalized using an orthodontic dental surface scanner (3Shape, Copenhagen, Denmark). Both image files of dental models were imported into SimPlant O&O software (Materialise, Leuven, Belgium). The maxillary and mandibular digital dental scan were aligned and replaced the maxillary and mandibular teeth of the CBCT skull. In this study, we were unable to obtain the dental model at T1 because of open mouth limitations and soft tissue swelling. The dental model at T0 was aligned and

**Table 1 3D landmarks of reference planes and overall skeletal measurement and general data of patients.**

Landmark	Abbreviation	Definition
Sella tursica	S	The center of hypophyseal fossa.
Nasion	N	The middle point of the frontonasal suture.
Point A	A	The innermost point on the contour of the anterior maxilla between the anterior nasal spine and upper incisors.
Point B	B	The innermost point on the contour of the mandible between the bony chin and lower incisors.
Orbitale	OrL	The most inferior point of left infraorbital rim.
	OrR	The most inferior point of right infraorbital rim.
Porion	PoL	The highest points of the left external acoustic meatus.
	PoR	The highest points of the right external acoustic meatus.
Average portion	PoA	Midpoint between the PoL and PoR.
Basion	Ba	The most anterior point of foramen magnum.

replaced the dentition in the CBCT skull at T1 with the assumption of limited tooth movement in one week after OGS.

### 3D overall superimposition

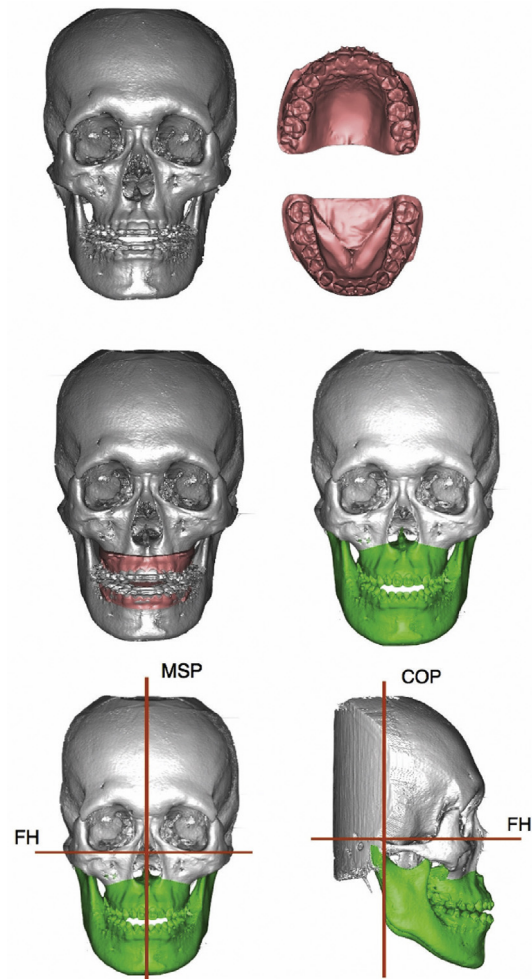
In this study, we evaluated the surgical change (T0–T1) and skeletal stability (T1–T2) through the overall superimposition of the 3D composite skull image. To compare the differences between the T0–T1 and T1–T2 images, the T1 and T2 composite 3D skulls were registered to the T0 at the cranial base and frontal bone by using the best-fit method. The accuracy of the cranial base registration was verified through the color mapping. The deviation value was automatically calculated, and a value of 0.5 mm or less was considered to be qualified. Eight skeletal landmarks were identified to define the reference planes and overall skeletal measurements [Table 1] [16,17]. The Frankfort horizontal (FH) plane is defined by connecting the right and left orbitale, and the middle point of the right and left porions (Po). The midsagittal plane (MSP) is parallel to the sagittal plane in patient's true head orientation and passes through the nasion. The COP plane is defined by perpendicular to the FH and MSP and passing through the basion (Ba) [Fig. 1] [16,17]. The linear measurements included vertical and horizontal distances from point B to the FH plane and COP plane to evaluate the surgical change and stability in both groups. In addition, the angular measurements of SNA, SNB, and ANB were obtained at T0, T1, and T2.

### 3D regional superimposition

The maxilla and mandible sections were segmented from the composite 3D skull. The surface best-fit matching method was used for the registration of the maxillary or mandibular basal bone at T1 and T2 individually. The dentition part was hidden when perform the basal bone registration to avoid the visual bias during image registration [18]. All the standard tessellation language (STL) files of maxillary and mandibular (only the distal segment) basal bone were imported to Geomagic studio version 12 (North Carolina, USA). The accuracy of the superimposition of the matching surfaces was calculated.

In the maxilla, the palatal surface region was considered as a stable anatomical structure for maxillary superimposition. Two lines and 3 referent points were identified for the

registration of the maxillary objects in T1 and T2 [Fig. 2]. Three reference points were selected, including the incisive papilla point (IF), and 2 points on the palatal vault (PV). The 2 reference lines were the midpalatal raphe line passing through the



**Fig. 1 The composite skull construction and reference planes.** The composite 3D skulls were composed of CBCT imaging and 3D scans of the dental models. The 3 main reference planes for analysis were the FH, MSP, and COP.

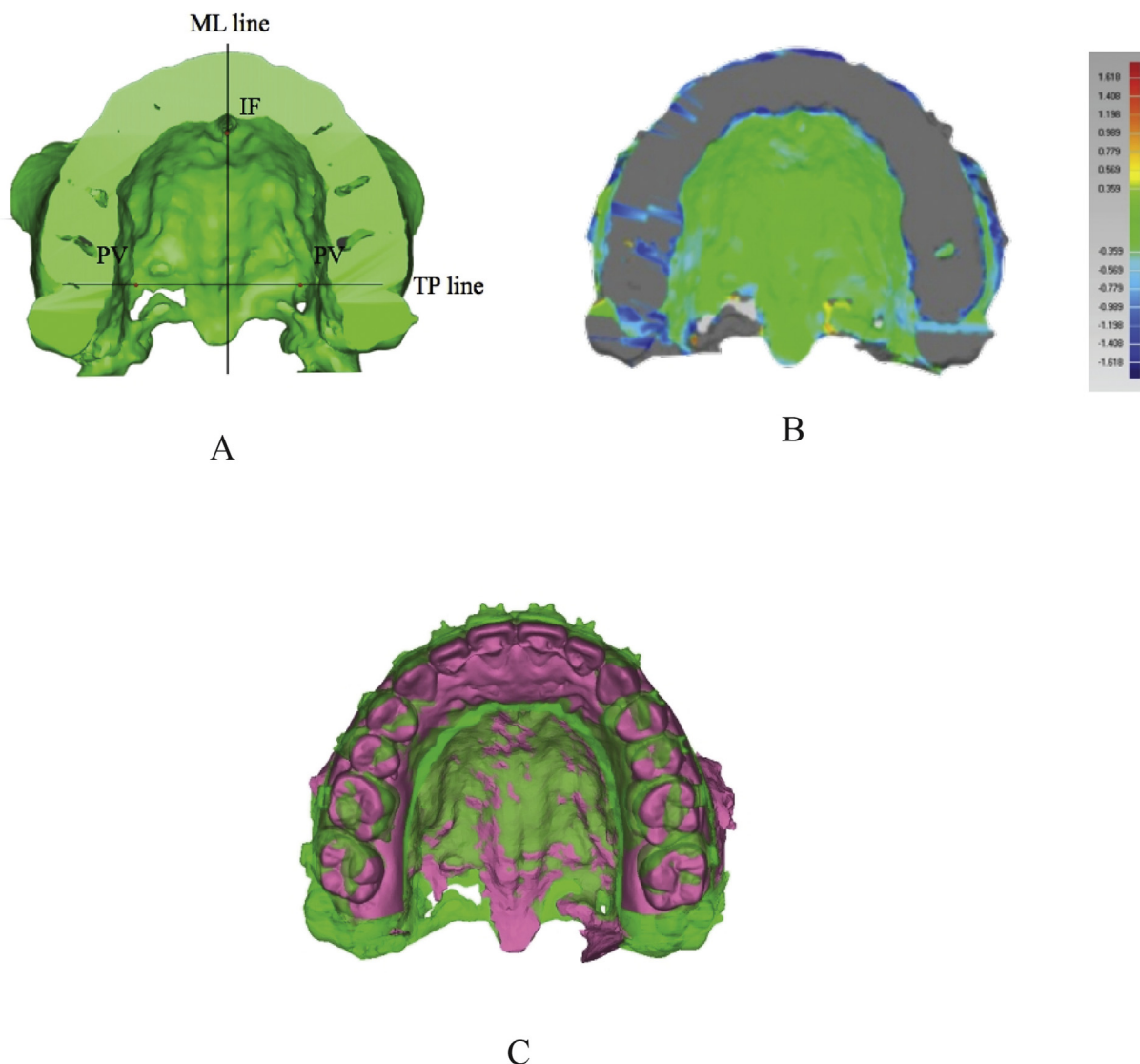


Fig. 2 3D regional superimposition in the maxilla. (A) Palatal area was considered as a stable anatomical structure for maxilla superimposition. ML, midpalatal raphe line through the incisive foramen; TP, transverse palatal suture line perpendicular to midpalatal raphe line; IF, incisive papilla point; PV, point on the palatal vault. (B) The color-coding system demonstrated the fitness of surface matching outcomes. (C) The dentition part was reappeared to the original bone objects after the completion of the basal bone superimposition. T1, the green color; T2, the pink color.


incisive foramen, and the transverse palatal suture line, which was perpendicular to the midpalatal raphe line. After the reference points had been defined, automatching superimposition was conducted in Geomagic studio [12,14].

In the mandible, the mental foramen and lingual surface of the body area were considered as stable anatomical structures for mandible superimposition [19,20]. Two lines and 3 reference points were identified for the registration of the mandibular objects in T1 and T2 [Fig. 3]. Three reference points were selected, including 2 points at the anteroinferior positions of the mental foramen on both sides and one point located at the lingual surface; it was identified at the line perpendicular to the midpoint of the connecting line between the left and right mental foramen. After defining these reference points, automatching superimposition was conducted.

A color map was used to evaluate the results of the superimposition. The green color indicated perfect fit. The red represented insufficient fit by a mismatch of 0.5 mm. A value of 0.5 mm or less was considered to be qualified.

After basal bone superimposition, the dentition part was reappearing from the original bone objects to access the post-operative dental movement (T1 vs. T2). There were 22 3D landmarks which identified for dental movement, included 18 dental points and 8 skeletal points at basal bones [Table 1; Fig. 4]. Three constructed reference planes in the T1 composite skull were used as common coordinates to measure the post-operative dental movement. The FH plane was employed to measure vertical tooth movement. In the maxilla, positive value (+) indicated the extrusive movement; in the mandible, negative value (–) indicated extrusive movement. The MSP was





**Fig. 3 3D regional superimposition in the mandible.** (A) The mental foramen and lingual surface of the body area were considered as stable anatomical structures for mandible superimposition; MF: mental foramen point; LF: a point on the lingual surface identified by the line perpendicular to the midpoint of the connecting line between the left and right mental foramen. (B) The color-coding system demonstrated the fitness of surface matching outcomes. (C) The dentition part was reappeared to the original bone objects after the completion of the basal bone superimposition. T1, the green color; T2, the pink color.

used to measure the transverse tooth movement (medial or lateral). Positive value (+) indicated lateral (expansive) movement and negative value (-) indicated medial (constrictive) movement. The COP was used to measure sagittal tooth movement. Positive value (+) indicated forward movement and negative value (-) indicated backward movement [Fig. 5].

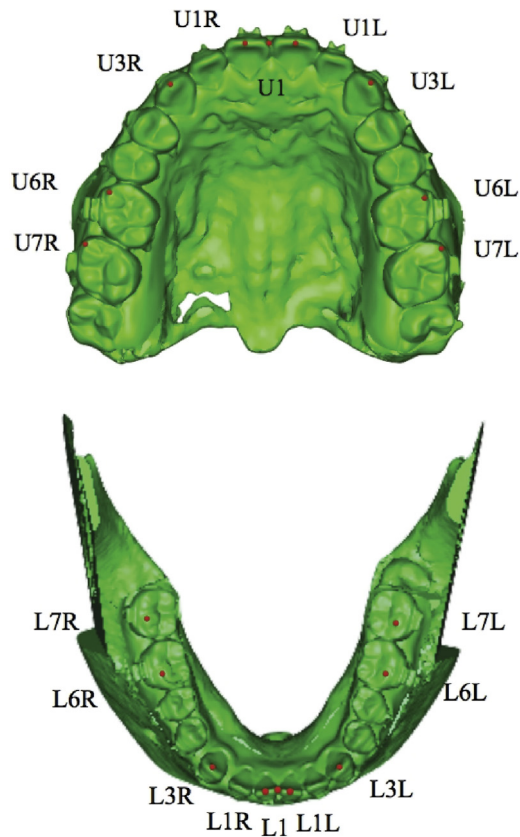
#### Statistical analysis

The statistics was performed using SPSS Software for Windows, version 17.0 (SPSS, Chicago, IL). The measurements between the SF and OF group were compared by the

Mann–Whitney U test. The measurements at different time points were compared using the Wilcoxon Signed rank test. The differences were considered significant at the level of  $p < .05$ . The Pearson's correlation coefficients were analyzed between postoperative dental movement and post-operative mandibular movement at B point.

#### Result

The participants were divided into 2 groups according to whether they received presurgical orthodontics or not. The SF



**Fig. 4 The 3D dental landmarks in maxilla and mandible.** (A) U1, point between U1L and U1R; U1L, incisor edge of upper left central incisor; U1R, incisor edge of upper right central incisor; U3L, cusp tip of upper left canine; U3R, cusp tip of upper right canine; U6L, mesiobuccal cusp of upper left first molar; U6R, mesiobuccal cusp of upper right first molar; U7L, mesiobuccal cusp of upper left second molar; U7R, mesiobuccal cusp of upper right second molar. (B) L1, point between L1L and L1R; L1L, incisor edge of lower left central incisor; L1R, incisor edge of lower right central incisor; L3L, cusp tip of lower left canine; L3R, cusp tip of lower right canine; L6L, mesiobuccal cusp of lower left first molar; L6R, mesiobuccal cusp of lower right first molar; L7L, mesiobuccal cusp of lower left second molar; L7R, mesiobuccal cusp of lower right second molar.

group comprised 20 patients (8 males and 12 females) with an average age of 23.5 years old and the OF group comprised 20 patients (6 males and 14 females) with an average age of 26.8 years old [Table 2]. There was no group difference in age and gender. The power of sampling is 0.94 for total of 40 sample size.

#### Treatment duration

The treatment duration demonstrated the presurgical orthodontic treatment time was significant difference in 2 groups (20 days and 295 days in SF and OF respectively). The post-surgical orthodontic was longer in SF group. But there was no significant difference between 2 groups. In the total treatment duration, it was significantly shorter in SF group (584 days and 354 days in OF and SF respectively; Table 2).

#### The skeletal measurements

The Class III pattern demonstrated similar characteristics at the initial status (T0) of the OF and SF groups in the SNA, SNB, and ANB angles. The ANB was smaller in the SF group ( $-3.40^\circ$ ) compared with the OF group ( $-2.51^\circ$ ) without statistical difference [Table 3].

One week after surgery (T1), the SNB and ANB normalized within a similar range in both groups. The SNA increased in both groups. The amounts of mandibular setback were 10.11 mm and 10.70 mm with a vertical decrease of 1.05 mm and 1.03 mm at point B respectively in the SF and OF groups [Table 4].

At the completion of treatment (T2), the skeletal measurements in both groups were similar. All angular measurements (SNA, SNB, and ANB) were slightly higher in the SF group, but there were no significant differences. In the post-operative phase ( $\Delta T2-T1$ ), point B moved forward 1.08 mm and upward 0.82 mm in the SF group, and forward 0.89 mm and downward 0.32 mm in the OF group. There were no significant differences of postoperative surgical change in the sagittal and vertical dimensions between the 2 groups.

#### The dental movement in the postoperative phase

In the vertical movement, the molars were extruded in both groups [Table 5; Figs. 6A and 7A]. The amounts of upper and lower molar extrusion were greater in the SF than in OF group, including 1.86 mm in U6, 2.13 mm in U7, 2.29 mm in L6 and 2.18 mm in L7. In the OF group, the posterior teeth demonstrated only mild extrusion. There were significant differences in vertical molar movements ( $p < .05$ ) between the 2 groups.

The maxillary incisors and canines demonstrated mild extrusion in both groups. On the other hand, the mandibular incisors and canines showed mild intrusion in both groups. The changes had no significant difference in both groups [Table 5].

In the transverse dimension, the upper intermolar distance and lower intercanine distance decreased in the SF group [Table 6; Figs. 6B and 7B]. While in the upper intercanine distance and lower intermolar distance increased. In the OF group, the upper intermolar and intercanine distances decreased. While in the lower intercanine and intermolar distances increased. There was no significant difference at T2 between the 2 groups.

In the sagittal dimension, the position of the upper incisor (U1) demonstrated a slight forward movement in both groups during the postoperative phase. The lower incisor (L1) also showed mild forward movement of 0.48 mm in SF group. On the other hand, the lower incisor indicated a backward movement of 0.31 mm in the OF group. The upper and lower incisors in both groups were in the similar range and no significant differences at T2 between the 2 groups [Table 7; Figs. 6C and 7C].

The maxillary molars demonstrated slightly backward movement in SF group but slightly forward in OF group, the difference had no significant difference. The mandibular molars demonstrated slightly forward movement in SF group but slightly backward in OF group, the difference was not significant [Table 7].

The Pearson's correlation coefficient demonstrated significant correlation between sagittal postsurgical mandibular

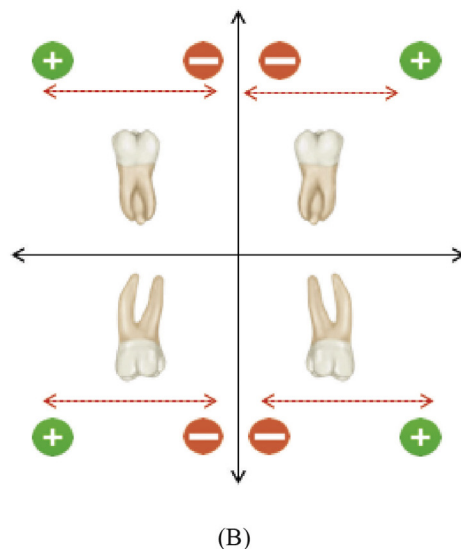
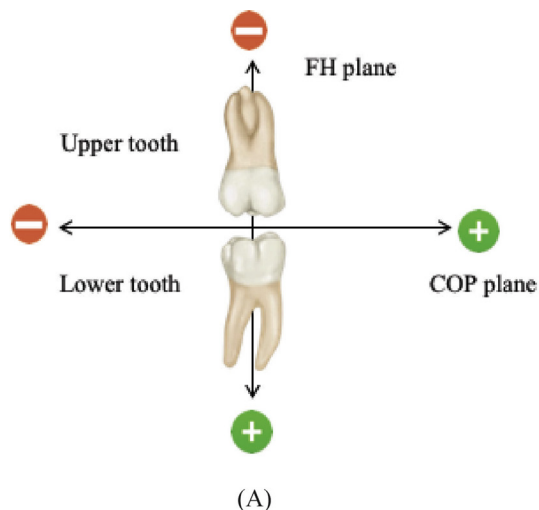


Fig. 5 Sign of dental movement in vertical, transverse and sagittal dimension.

change and the amount of vertical molar movement. This demonstrated that the correlation was highest between the postsurgical sagittal relapse and the amount of extrusion in

**Table 2** General information of SF and OF groups.

	SF		OF		p value
	mean	SD	mean	SD	
Patient number	20		20		
Gender	60 (12)		70 (14)		0.608
Women, % (n)					
Age	23.53	2.9	26.85	4.2	0.417
Presurgical phase (days)	20	4.2	295	60.52	0.000**
Postsurgical phase (days)	334	60.53	289	95.45	0.069
Total treatment (days)	354	90.68	584	80.29	0.025*

Significant level: \* $p < 0.05$ , \*\* $p < 0.001$ .

lower first molars among all 40 patients without grouping [Table 8].

For the error study, 10 images from the 40 patients were randomly selected. The 3D landmarks were re-identified and re-measured at 1-month interval. The angular and linear measurements were compared between the 2 time sets using Dahlberg's formula ( $S^2 = \Sigma D^2/N^2$ ) where D is the difference between 2 measurements and N is the number of double determinations. The maximum error of the reference points was 0.30 mm. The random errors of the linear and angular measurements ranged from 0.42 to 0.55 mm and from 0.52 to 0.62°. The systemic errors were obtained by pair-t test, which presented no significant difference between the 2 pairs of measurements.

## Discussion

This study evaluated dental changes in the postoperative orthodontic treatment in patients who underwent surgical correction of Class III malocclusion. The difference between 2 methods of surgical orthodontic approaches (SF and OF) were examined basing on an investigation of 3D craniofacial images.

The sagittal relation and severity of the skeletal Class III malocclusion before treatment were similar in both groups. The surgical correction included midface forward positioning and impaction by Le Fort I osteotomy and mandible setback by bilateral sagittal split osteotomies. In the present study, the surgical change (T2-T1) at point B in the mandible was 10.11 mm and 10.70 mm of the SF and OF, respectively. The mandible tended to move forward 1.08 mm in the SF group and 0.89 mm in the OF group during the postoperative phase, but without significant difference. In previous studies, sagittal relapse after mandible surgery for skeletal Class III malocclusion has been reported with various results. The amount of mandibular setback ranged from 4.80 to 8.70 mm. The anterior relapse movement ranged from 0.60 to 2.87 mm after surgery with the relapse rate from 7.1% to 51.4% (mean, 22.6%) [6,8,9]. Ko et al. reported that the relapse rate of the mandible setback was not significantly different between groups (14.3% in the OF group, 15.7% in the SF group) [9]. Mah et al. indicated that sagittal postsurgical relapse in the SF group at point B had forward position of 3.41 mm after a surgical change of 11.81 mm [8]. As comparing the minimal presurgical orthodontics with the conventional approach, the surgical stability of mandible setback was similar [21]. Less presurgical orthodontic preparation or SFA was not contributed to a greater surgical relapse but reduce the total treatment duration [21–23].

In the vertical dimension, the mandible exhibited a similar downward movement at point B during surgery due to the clockwise rotation of the maxillary–mandibular complex. After surgery, the SF group displayed a mild upward movement, and the OF group manifested a mild downward movement, but no significant difference. In the SFA, a proper surgical occlusion setup within the frame of appropriate facial proportions and symmetry can be guided by 3D surgical simulation [24]. The principle for SFA occlusion setup in Class III OGS included: proper incisor overbite, mild Class II canine

**Table 3 Skeletal measurement of SF (n = 20) and OF (n = 20) groups at different time points.**

Variables	T0		T1		p value	T0		T1		p value	T2		T2		p value
	SF		OF			SF		OF			SF		OF		
	mean	SD	mean	SD		mean	SD	mean	SD		mean	SD	mean	SD	
SNA (°)	82.12	2.67	83.98	1.90	0.323	84.64	3.09	84.15	2.03	0.702	84.52	1.12	84.02	2.99	0.521
SNB (°)	85.52	3.31	86.49	2.65	0.070	81.23	2.76	81.30	3.43	0.511	81.81	2.81	81.36	1.29	0.563
ANB (°)	-3.40	2.05	-2.51	3.99	0.522	3.41	3.13	2.85	2.56	0.547	2.73	3.21	2.66	3.36	0.842
B-FH (mm)	76.68	4.95	77.90	4.21	0.589	77.57	4.59	76.87	4.79	0.742	76.81	5.64	77.19	4.52	0.912
B-COP (mm)	93.56	3.32	94.27	5.51	0.910	83.45	3.02	83.57	3.44	0.510	85.03	3.17	84.59	3.67	0.679

Abbreviations: T0: before surgery; T1: 1 week after surgery; T2: after the completion of the orthodontic treatment.

**Table 4 Comparison of surgical change and stability at point B between the SF (n = 20) and OF (n = 20) groups.**

Variables	SF		OF		p value	SF		OF		p value
	T1-T0		T1-T0			T2-T1		T2-T1		
	SD	SD	SD	SD		SD	SD	SD	SD	
B-FH	1.05	3.89	1.03	2.942	0.94	-0.82	3.05	0.32	3.12	0.571
B-COP	10.11	2.95	10.70	2.365	0.62	1.08	2.13	0.89	2.94	0.653

Abbreviations: T1-T0, surgical changes; T2-T1, surgical stability; B-FH indicated vertical dimensions; B-COP indicated sagittal dimension. Positive value (+) indicates forward or downward movement; Negative value (-) indicates backward or upward movement.

and molar relation (10% of sagittal overcorrection), general arch coordination, and avoiding dental interference through posterior occlusal clearance. Therefore, participants who were candidates for SFA could undergo a setup occlusion with

proper anterior contact but leave open bite in posterior region if the occlusal plane was not flat. The amount of maxillary compensating curve would be larger in patients with anterior open bite. By combining the 2-jaw OGS, posterior maxillary

**Table 5 Comparison of dental movement in the postoperative phase (T2-T1) between SF (n = 20) and OF (n = 20) groups in vertical changes.**

Variable	SF		T2-T1	p value	OF		T2-T1	p value					
	T1				T2								
	mean	SD			mean	SD			mean	SD			
Vertical distance (mm): FH													
U1	52.15	1.82	52.26	1.70	0.11	0.750	51.95	3.53	52.03	3.50	0.08	0.952	0.512
U1L	52.16	1.60	52.26	1.67	0.10	0.771	51.98	3.62	52.05	3.45	0.07	0.781	0.589
U1R	52.14	1.74	52.25	1.68	0.11	0.751	51.93	3.63	52.02	3.46	0.09	0.706	0.608
U3	52.10	1.66	52.37	1.61	0.27	0.700	51.97	3.66	52.02	3.49	0.05	0.924	0.534
U3L	52.03	1.76	52.37	1.61	0.34	0.683	51.99	3.66	52.05	3.56	0.06	0.894	0.138
U3R	52.17	1.62	52.37	1.63	0.20	0.726	51.94	3.70	51.99	3.58	0.05	0.924	0.435
U6	47.97	2.67	49.83	2.12	1.86	0.045*	50.09	3.82	50.66	3.85	0.56	0.255	0.010*
U6L	48.58	2.68	50.39	2.12	1.81	0.044*	50.11	3.84	50.62	3.88	0.51	0.281	0.010*
U6R	47.35	2.59	49.26	2.16	1.91	0.049*	50.07	3.78	50.69	3.75	0.62	0.232	0.021*
U7	47.26	2.33	49.39	2.66	2.13	0.020*	49.28	3.66	49.77	6.89	0.49	0.350	0.004**
U7L	47.28	2.31	49.42	2.94	2.14	0.025*	49.03	3.66	49.52	3.90	0.49	0.350	0.004**
U7R	47.25	2.36	49.32	2.14	2.08	0.044*	49.52	3.69	50.02	9.93	0.50	0.275	0.003**
L1	53.45	1.42	53.79	1.39	0.33	0.688	53.11	5.22	53.18	5.34	0.07	0.823	0.433
L1L	53.47	1.44	53.84	1.41	0.37	0.609	53.26	5.37	53.32	5.38	0.06	0.782	0.098
L1R	53.42	1.42	53.73	1.39	0.31	0.513	52.95	5.35	53.03	5.24	0.08	0.977	0.311
L3	53.30	1.45	53.69	1.44	0.39	0.553	52.80	5.22	52.87	5.23	0.07	0.822	0.185
L3L	53.27	1.50	53.68	1.42	0.41	0.463	52.98	5.13	53.03	5.37	0.05	0.954	0.085
L3R	53.32	1.37	53.69	1.47	0.37	0.609	52.62	5.36	52.71	4.99	0.09	0.706	0.164
L6	52.70	2.67	50.41	2.55	-2.29	0.038*	51.30	4.05	50.78	3.98	-0.52	0.469	0.002**
L6L	52.81	2.58	50.10	2.72	-2.15	0.024*	51.46	4.02	51.01	3.92	-0.45	0.30	0.002**
L6R	52.69	2.81	50.47	2.28	-2.22	0.039*	51.14	4.23	50.55	4.00	-0.59	0.511	0.001**
L7	51.86	2.80	49.68	2.45	-2.18	0.020*	50.85	4.00	50.57	3.88	-0.28	0.408	0.001**
L7L	51.75	2.87	49.61	2.44	-2.17	0.021*	50.91	3.98	50.62	3.84	-0.29	0.477	0.001**
L7R	51.96	2.71	49.76	2.53	-2.20	0.038*	50.78	4.02	50.52	3.75	-0.26	0.483	0.001**

P value indicated the comparison of T2-T1 between SF and OF groups. Significant level: \*p < 0.05, \*\*p < 0.01; In the maxilla, positive value (+) indicated downward or extrusive movement; In the mandible, positive value (+) indicated downward or intrusive movement; negative value (-) indicated upward movement or extrusive movement.



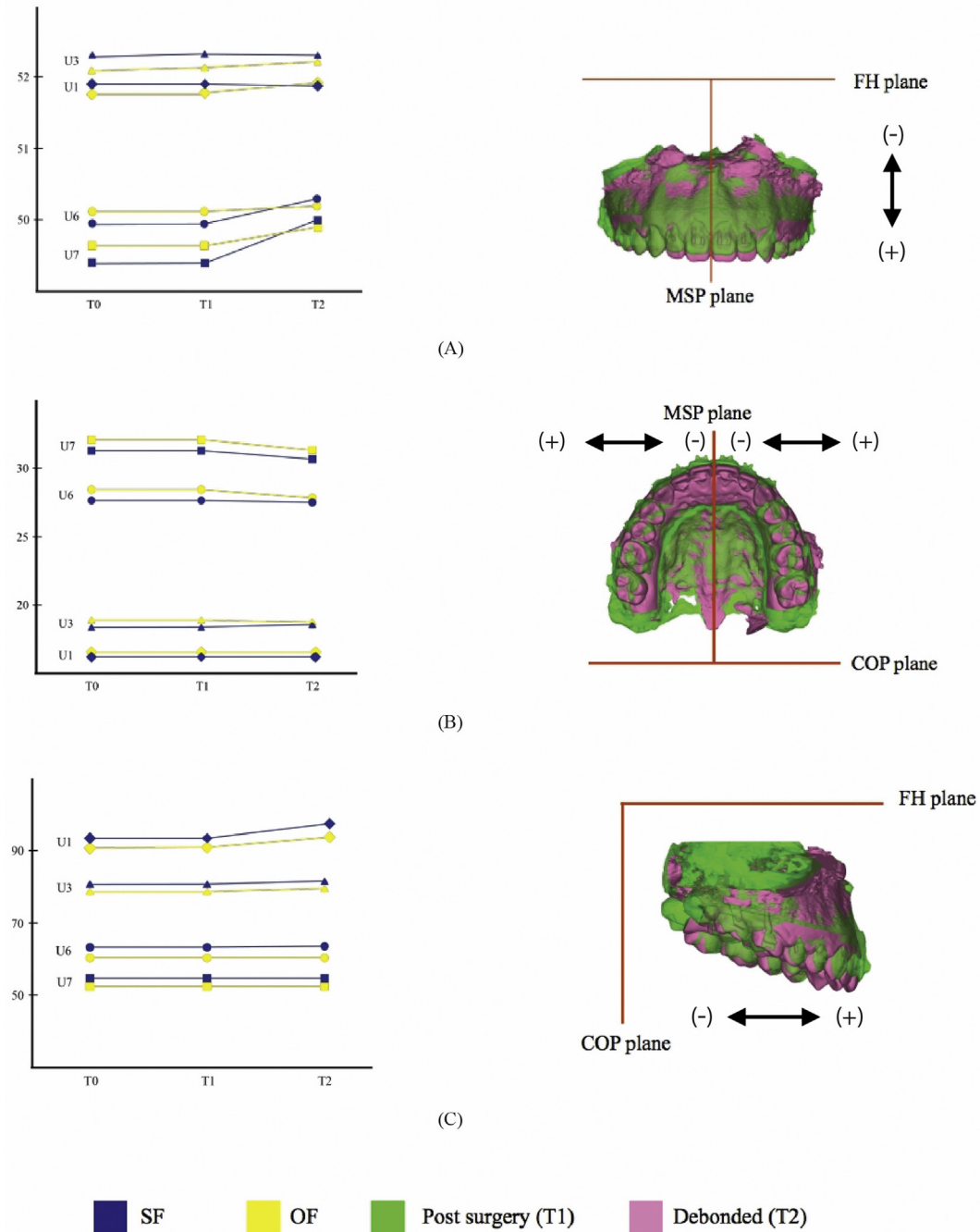


Fig. 6 Dental movement measurement in the maxilla. (A) Plot of vertical movement of U6 and U7. (B) Plot of transverse movement of U3, U6 and U7. (C) Plot of sagittal movement of U1 and U3. The blue color represented the SF group; the yellow color represented OF group; T1, the green color; T2, the pink color. In vertical plane, (+), downward or extrusive movement; (-) upward or intrusive movement. In transverse plane, (+), lateral and outward movement; (-), mesial and inward movement. In sagittal plane, (+), forward movement; (-) backward movement.

impaction and clockwise movement of the occlusal plane, the mandibular plane can be maintained with the occlusion setup of posterior open bite. Lee et al. indicated that surgical increase in posterior vertical dimension in the molar occlusion could contribute to unpredictable position of B-point in the postsurgical phase [25]. To maintain the similar mandibular plane and anterior facial height, maxillary posterior

impaction with the occlusion setup in posterior open might be a solution for surgical stability in SFA.

In this study, there were significant differences in the amount of molar extrusive movement between SF and OF groups. In the postsurgical orthodontic phase, the teeth began to align and level in the early phase after surgery because light active arch wires (0.014 in NiTi wire) were applied to the

**Table 6 Comparison of dental movement in the postoperative phase (T2-T1) between the SF (n = 20) and OF (n = 20) groups in transverse changes.**

Variable	SF						OF						p value
	T1		T2		T2-T1	p value	T1		T2		T2-T1	P value	
	mean	SD	mean	SD			mean	SD	mean	SD			
Horizontal distance (mm): MSP													
U1	0.64	0.97	0.72	1.00	0.08	0.856	1.00	1.20	0.62	0.95	-0.05	0.690	0.734
U1L	3.90	1.18	4.01	1.17	0.12	0.712	4.18	1.48	4.18	1.44	-0.04	0.700	0.783
U1R	4.58	1.09	4.38	1.20	0.11	0.710	4.61	1.35	4.53	1.32	-0.02	0.745	0.735
U3	17.25	2.28	17.72	3.23	0.47	0.468	17.62	3.25	17.36	3.54	-0.27	0.284	0.512
U3L	17.16	2.30	17.47	3.25	0.31	0.608	17.78	3.32	17.46	3.22	-0.32	0.124	0.573
U3R	17.33	2.25	17.97	3.22	0.64	0.370	17.46	3.03	17.25	3.86	-0.21	0.356	0.374
U6	27.04	2.75	26.27	3.80	-0.77	0.324	27.69	2.98	27.09	3.63	-0.60	0.090	0.764
U6L	27.56	2.79	26.88	3.86	-0.68	0.405	28.32	3.31	27.63	2.96	-0.69	0.089	0.842
U6R	26.52	2.67	25.66	2.61	-0.86	0.210	27.05	2.78	26.55	3.74	-0.50	0.113	0.731
U7	32.46	3.08	32.07	2.68	-0.39	0.635	33.28	3.69	33.02	3.92	-0.26	0.302	0.383
U7L	32.81	3.19	32.28	2.66	-0.52	0.512	33.27	3.90	33.07	3.91	-0.11	0.442	0.092
U7R	32.12	2.91	31.86	3.17	-0.43	0.642	33.31	3.51	32.99	3.75	-0.17	0.452	0.463
L1	1.95	2.54	1.75	2.88	-0.20	0.711	3.04	3.26	2.23	3.74	-0.01	0.868	0.655
L1L	2.75	2.20	2.97	2.45	-0.16	0.792	4.35	2.70	3.56	3.32	-0.06	0.643	0.462
L1R	3.55	2.81	3.51	2.91	-0.04	0.885	4.93	4.00	4.56	4.49	0.03	0.710	0.672
L3	13.05	2.67	12.55	4.08	-0.50	0.522	12.92	3.56	13.28	4.09	0.36	0.123	0.084
L3L	12.93	2.54	12.53	4.09	-0.42	0.510	12.93	3.26	13.28	4.09	0.35	0.112	0.089
L3R	13.17	2.97	12.58	4.01	-0.59	0.531	12.91	4.05	13.27	4.10	0.36	0.118	0.095
L6	24.96	3.14	25.47	3.35	0.51	0.583	26.06	3.89	26.34	3.72	0.28	0.301	0.124
L6L	25.02	3.25	25.61	3.62	0.59	0.530	26.05	3.65	26.34	3.62	0.29	0.259	0.126
L6R	24.89	2.34	25.32	2.36	0.43	0.642	26.08	4.40	26.33	3.86	0.25	0.223	0.105
L7	28.06	2.53	28.41	2.69	0.34	0.690	26.80	3.03	26.82	3.53	-0.02	0.521	0.568
L7L	28.02	2.77	28.36	2.70	0.34	0.690	26.75	3.34	26.58	3.36	-0.05	0.690	0.395
L7R	28.08	2.42	28.45	2.69	0.37	0.622	26.85	2.26	27.05	3.90	0.20	0.321	0.621

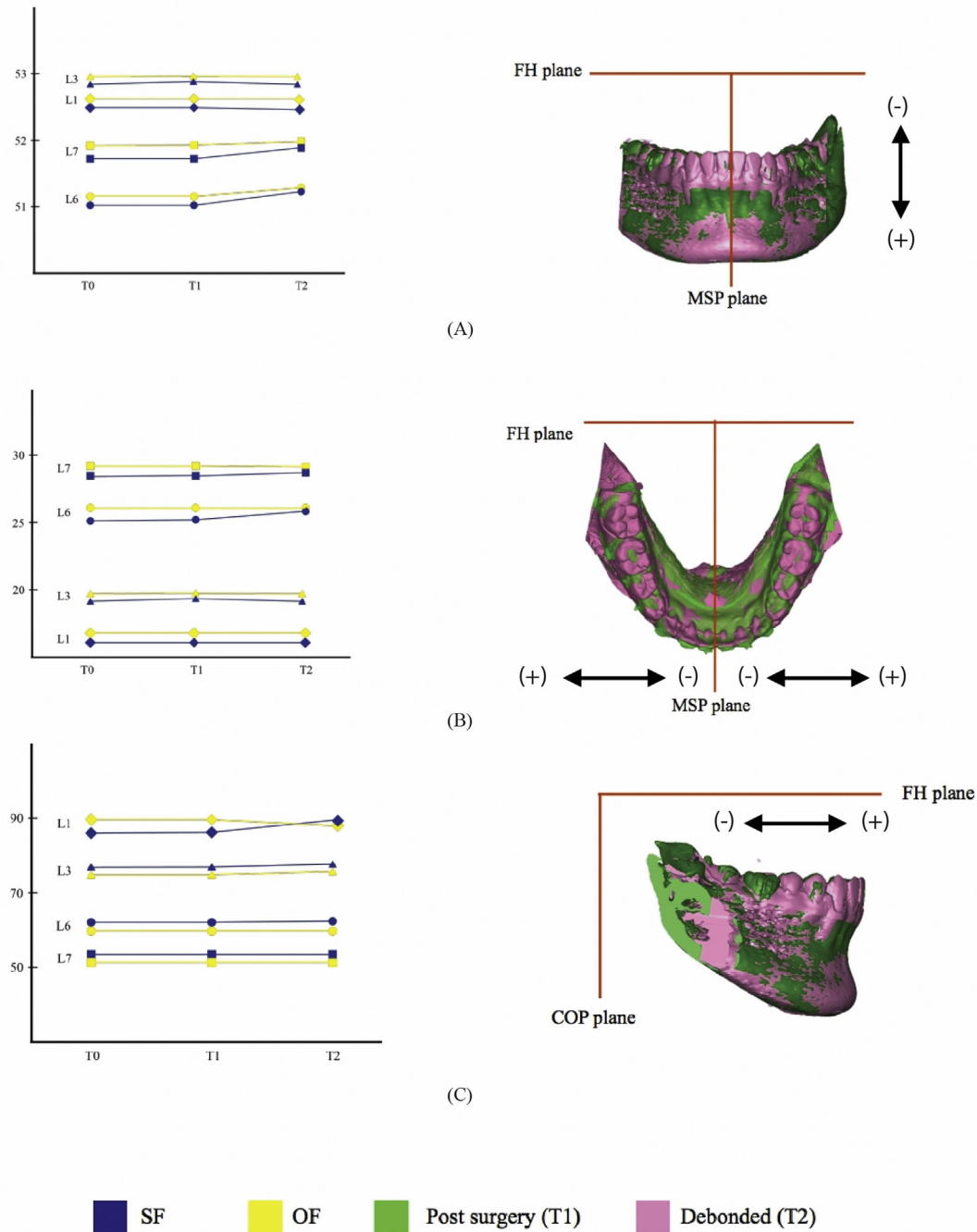
p value indicated the comparison of T2-T1 between SF and OF groups. The positive value (+) indicated lateral or outward movement; negative value (-) indicated medial movement or inward movement.

participants' teeth one day before surgery, and thus took advantage of rapid accelerated tooth movement following surgery. Light intermaxillary elastics were applied to guide the proper occlusal interdigitation, starting from the front teeth and gradually moving toward the molars after the interdigitation became solid in the front part of the dentition. For this reason, the molar demonstrated significant extrusion in the SF group. But the cases with severe maxillary compensating curve or mandibular curve of Spee, the osteotomies could be modified to segmental osteotomies to facilitate the postoperative orthodontic tooth movement.

In the transverse dimension, the upper intermolar distance at first molar and lower intercanine tended to decrease, and the upper intercanine distance and lower distance at first molar tended to increase in the SF group. In the OF group, the upper arch width tended to decrease, and the lower arch width tended to increase. No significant difference of these dental changes was noted between the 2 groups. The transverse distances of the maxillary canine and molar in OF the group were greater than the SF group before surgery and became narrow in the postoperative phase. In Class III malocclusion, it quite common to exhibit posterior lingual cross bite before treatment. This cross bite was caused mainly from sagittal jaw discrepancy, in which the wider part of the lower jaw has grown forward. This phenomenon caused dental compensation of buccally tilted upper posterior teeth and lingually tilted lower posterior teeth. For example, the

presurgical orthodontic leveling would have mild expansion in the upper arch (buccally tilt). Once the sagittal jaw discrepancy had been corrected, the preoperative presentation of a transverse discrepancy was not present after OGS. The upper molar need to tilt lingually more to settle the occlusion after OGS in OF group. However, the transverse adaption in upper molar went straightly lingually tilt in the SF group, no round tripping movement. These findings were similar to the previous 2D study performed by Wang et al. [26] Therefore, maxillary expansion may not be required for most skeletal Class III malocclusions. If there is a maxillary transverse discrepancy, segmental osteotomies to surgically expand the maxillary arch could be performed to provide treatment efficiency and stability [2,4,24].

In the sagittal dimension, the position of the upper incisor edge demonstrated a minor forward movement in both groups during the postsurgical phase, and the lower incisor manifested a minor forward movement in the SF group and a minor backward movement in the OF group. There were no statistically significant differences. The proclination in the incisors in the SF group resulted from leveling of the crowded dentition. The retroclination of the lower incisors in the OF group might have partially compensated for the mild skeletal relapse in Class III correction. The findings in this study were similar to the previous 2D study by Ko et al. [9] The presurgical decompensation of the incisor inclination might not be a requirement for a 2-jaw OGS. Troy et al. had compared the



**Fig. 7 Dental movement measurement in the mandible.** (A) Plot of vertical movement of L6 and L7. (B) Plot of transverse movement of L6 and L7. (C) Plot of sagittal movement of L1 and L3. The blue color represented the SF group; the yellow color represented the OF group; T1, green color; T2, the pink color. In vertical plane, (+), downward or extrusive movement; (–) upward or intrusive movement. In transverse plane, (+), lateral and outward movement; (–), mesial and inward movement. In sagittal plane, (+), forward movement; (–) backward movement.

incisor inclination in patients with Class III malocclusion treated with OGS or orthodontic camouflage [27]. They indicated that limited amount of upper incisor decompensation could be achieved before OGS; the lower incisors retroclined after OGS even with presurgical decompensation; the final lower incisor inclination was similar between the 2 treatment

modalities. In the SFA, the maxillary incisor can be uprighted through a clockwise rotation of the maxilla–mandibular complex. By leaving the overjet space during surgical occlusion setup, the lower incisors could be proclined naturally through crowding relief and adaptation to new dental occlusion in the postoperative phase.

**Table 7 Comparison of dental movement in the postoperative phase (T2-T1) between the SF (n = 20) and OF (n = 20) groups in sagittal changes.**

Variable	SF						OF						p value
	T1		T2		T2-T1	p value	T1		T2		T2-T1	p value	
	mean	SD	mean	SD			mean	SD	mean	SD			
Sagittal distance (mm): COP													
U1	90.48	5.10	90.85	5.35	0.37	0.074	89.31	4.29	89.60	5.12	0.29	0.092	0.088
U1L	90.49	4.56	90.88	5.37	0.39	0.069	89.31	5.23	89.59	6.01	0.28	0.098	0.089
U1R	90.46	5.13	90.83	5.30	0.37	0.074	89.31	5.24	89.60	5.82	0.29	0.092	0.082
U3	85.45	4.90	85.78	4.95	0.33	0.079	83.07	4.48	83.15	4.39	0.08	0.240	0.235
U3L	85.41	4.92	85.72	4.96	0.31	0.086	83.09	4.49	83.14	4.42	0.05	0.319	0.123
U3R	85.48	4.86	85.84	4.90	0.36	0.085	83.05	4.50	83.15	4.36	0.10	0.176	0.156
U6	64.16	4.54	63.91	5.30	-0.26	0.094	63.26	4.32	63.33	4.25	0.07	0.289	0.088
U6L	64.03	4.64	63.80	5.31	-0.23	0.099	63.42	4.35	63.50	4.27	0.08	0.240	0.083
U6R	64.28	4.64	64.01	5.29	-0.27	0.091	63.10	4.29	63.16	4.27	0.06	0.308	0.093
U7	53.84	5.37	53.61	5.39	-0.23	0.099	52.44	4.82	52.53	4.73	0.09	0.163	0.085
U7L	53.84	5.38	53.61	5.39	-0.23	0.099	52.45	4.80	52.53	4.71	0.08	0.240	0.073
U7R	53.84	5.38	53.61	5.39	-0.23	0.099	52.42	4.82	52.52	4.70	0.09	0.163	0.066
L1	89.29	3.98	89.77	3.93	0.48	0.063	88.88	5.11	88.57	6.03	-0.31	0.089	0.153
L1L	89.30	3.86	89.77	4.90	0.47	0.063	88.88	6.13	88.58	6.25	-0.30	0.099	0.165
L1R	89.28	4.98	89.78	3.89	0.50	0.060	88.87	6.11	88.57	6.00	-0.30	0.099	0.165
L3	86.36	4.59	86.70	4.65	0.34	0.084	85.45	6.12	85.00	6.06	-0.45	0.215	0.087
L3L	86.37	4.62	86.70	4.67	0.33	0.079	85.45	6.12	85.04	6.08	-0.41	0.206	0.098
L3R	86.34	4.62	86.69	4.65	0.35	0.088	85.44	6.11	84.96	6.03	-0.48	0.188	0.053
L6	74.74	4.82	74.82	4.75	0.08	0.098	74.59	5.97	74.47	5.88	-0.12	0.156	0.184
L6L	74.73	4.83	74.85	4.77	0.12	0.104	74.55	5.98	74.49	5.89	-0.06	0.200	0.117
L6R	74.75	4.83	74.78	4.80	0.03	0.151	74.63	5.94	74.45	5.93	-0.02	0.340	0.621
L7	64.80	4.89	64.84	4.99	0.04	0.138	63.74	5.43	63.70	5.66	-0.04	0.206	0.618
L7L	64.84	4.88	64.87	4.85	0.03	0.151	63.84	5.56	63.61	5.52	-0.04	0.206	0.644
L7R	64.76	4.94	64.81	4.91	0.05	0.119	63.43	5.58	63.78	5.57	-0.01	0.362	0.595

p value indicated the comparison of T2-T1 between SF and OF groups. The positive value (+) indicated forward movement, the negative value (-) indicates backward movement.

In our study, the relationship between the postoperative sagittal mandibular surgical changes and the vertical change in molars exhibited a statistical correlation. Although there was no significant difference in the postoperative mandibular change of both the vertical and horizontal dimensions between the 2 groups. The extrusion of the lower first molar demonstrated the highest correlation with the B-point

relapse, with the second being the upper first molar extrusion. It could be explained that if the occlusion setup contained an increased posterior open bite, the postoperative settling of the mandible position tended to move forward and upward while the interdigitation became solid in the SFA. The molar extrusion was necessary for achieving postoperative occlusion in the SFA cases. Our previous study indicated that a larger overbite, a deeper curve of Spee, a greater negative overjet, and a greater mandibular setback could be associated with mandibular relapse in the SFA [16]. When a large interarch gap is presented in the occlusion setup occurred in the SFA, a clockwise rotation and overcorrection of the mandible setback might be required to compensate for the upward and forward mandibular movement after surgery. Further long-term outcomes should be investigated to clarify the skeletal stability after achievement of molar occlusion in SFA cases.

In this study, the total treatment in the OF group was longer significantly than the SF group (354 days and 584 days in SF and OF respectively). The tooth decompensating treatment which help to reveal the true dentoskeletal relationship, correct crowding and level the curve of Spee presurgically would require a period of time in the OF group. But in SF group, the decompensation, leveling and alignment, occlusal interdigitation could be corrected in postsurgical orthodontic phase more straight forward. After surgery, orthodontic tooth movement can be easily achieved because the teeth are usually not occluded. The rapid tooth movement could occur

**Table 8 Correlation between postoperative skeletal change (B-COP, T2-T1) and the postoperative dental movement.**

Variable (T2-T1)	B-COP (T2-T1) R	p value
U6L-FH	-0.409	0.025*
U6R-FH	-0.421	0.009**
U7L-FH	-0.358	0.042*
U7R-FH	-0.386	0.039*
L6L-FH	-0.427	0.007**
L6R-FH	-0.434	0.005**
L7L-FH	-0.403	0.031*
L7R-FH	-0.412	0.019*

Pearson's correlation coefficient was employed for this analysis. The table only demonstrated the significant correlation pairs, indicated only vertical dental movements in molars were significantly correlated. Significant level: \*p < 0.05, \*\*p < 0.01.



because of the regional acceleratory phenomenon effect. Min et al., Huang et al. reported the postoperative orthodontic treatment could be completed within approximately 1 year or in even 6–9 months [2,23]. The total treatment time was approximately 6–12 months shorter using a SFA compared with using a conventional OF approach [10].

The SFA could provide patients with satisfactory and immediate facial improvement after surgery. Over time, this approach has gained popularity among orthodontists and surgeons for several reasons: (1) the esthetic concern for the patient is addressed from the beginning; (2) the length of the orthodontic treatment duration [10,22]; (3) achieve good final occlusion without round tripping in dental movement.

In previous study, the 2D image of lateral and PA cephalometric radiographs were commonly used for evaluating the treatment outcome. But the disadvantages are errors from tracing on overlapped anatomical structures and landmark identification. The 3D image had great impact on the imaging research field. For the skull, most studies used CBCT image for superimposition to compare the progression and skeletal treatment outcome. The application of CBCT to investigate the dental movement was not well explored. In recently studies, digital dental models were applied to evaluate and compare the dental change before and after treatment in both growing and non-growing subject [7,28,29]. Park et al. has suggested that the dental movement could be measured by 3D regional superimposition though CBCT in which the dentition were replaced with digital dental models [30]. They used the overall surface of maxillary and mandibular segments as stable structures for image registration by a best-fit method. The method has not well applied in the OGS cases for its considerate bone remodeling after surgery. We have identified the reliable stable structure of maxillary and mandibular bone segment for regional superimposition to compare the serial dental change in the OGS cases.

The limitation of the present study was the dental casts constructed from dental stone may have lost details and wore out at the surface, especially at the sharp cusp tip. In addition, we were not able to obtain the dental impression at the time point of 1 week after surgery (T1). Thus, the preoperative dental models were replaced in T1 by assuming limited dental movement in the first postoperative week. However, minor dental movement could still be detected in some cases. To overcome this limitation, a 3D intraoral scanner could be used instead of a 3D dental model scan in future study.

## Conclusion

1. The stability of skeletal mandibular movement was no different in individuals who were assigned to the SF or the OF approach.
2. The postsurgical dental interdigitation was achieved mainly through posterior teeth extrusion, especially in the SFA participants. The amounts of extrusion were 1.86 mm in U6, 2.13 mm in U7, 2.29 mm in L6 and 2.18 mm in L7. The surgical setup of a dental occlusion with an average of 4 mm posterior open bite could be successfully closed during the postoperative orthodontic correction in cases with SFA.

3. The sagittal postoperative mandibular relapse were correlated with molar extrusive movement, with highest correlation was noted in the extrusion of lower first molars. Skeletal overcorrection might be required for cases with an occlusion setup as the posterior open bite in cases with SFA.
4. The occlusion outcome was no different after completed orthodontic treatment in both SF and OF approach.

## Funding

This study was supported by a research grant (CRRPG1G0013) from Chang Gung Memorial Hospital, Linkou, Taiwan. This study was also approved by the Institutional Review Board and Medical Ethics Committee at Chang Gung Memorial Hospital (No.201600629A3). Guidelines of Helsinki Declaration were followed.

## Conflicts of interest

The authors declare no conflicts of interest.

## Acknowledgements

We thank Ms. Emily Yu-Ting Lin and Mr. Chen Cheng-Wei for their technical support in the 3D data management. We are also grateful for the support of research grant (CRRPG1G0013) from Chang Gung Memorial Hospital, Linkou, Taiwan.

## REFERENCES

- [1] Johnston C, Burden D, Kennedy D, Harradine N, Stevensond M. Class III surgical-orthodontic treatment: a cephalometric study. *Am J Orthod Dentofacial Orthop* 2006;130:300–9.
- [2] Huang CS, Hsu SS, Chen YR. Systematic review of the surgery-first approach in orthognathic surgery. *Biomed J* 2014;37:184–90.
- [3] Liou EJ, Chen PH, Wang YC, Yu CC, Huang CS, Chen YR. Surgery-first accelerated orthognathic surgery: postoperative rapid orthodontic tooth movement. *J Oral Maxillofac Surg* 2011;69:781–5.
- [4] Hernández-Alfaro F, Guijarro-Martínez R, Peiró-Guijarro MA. Surgery first in orthognathic surgery: what have we learned? A Comprehensive workflow based on 45 consecutive cases. *J Oral Maxillofac Surg* 2014;72:376–90.
- [5] Leelasinjaroen P, Godfrey K, Manosudprasit M, Wangrimongkol T, Surakunprapa P, Pisek P. Surgery first orthognathic approach for skeletal class III malocclusion corrections a literature review. *J Med Assoc Thai* 2012;95:S172–80.
- [6] Tseng YC, Pan CY, Chou HT, Liao CY, Lai HT, Chen CM, et al. Treatment of adult class III malocclusions with orthodontic therapy or orthognathic surgery: receiver operating characteristic analysis. *Am J Orthod Dentofacial Orthop* 2011;139:e485–93.

- [7] Thiruvengkatahari B, Ai-Abdallah M, Akram NC, Sandler J, O'Brien K. Measuring 3-dimensional tooth movement with a 3-dimensional surface laser scanner. *Am J Orthod Dentofacial Orthop* 2009;135:480–5.
- [8] Mah DH, Kim SG, Oh JS, You JS, Jung SY, Kim WG, et al. Comparative study of postoperative stability between conventional orthognathic surgery and a surgery-first orthognathic approach after bilateral sagittal split ramus osteotomy for skeletal class III correction. *J Korean Assoc Oral Maxillofac Surg* 2017;43:23–8.
- [9] Ko EW, Hsu SS, Heieh HY, Wang YC, Chen YR. Comparison of progressive cephalometric changes and postsurgical stability of skeletal Class III correction with and without presurgical orthodontic treatment. *J Oral Maxillofac Surg* 2011;69:1469–77.
- [10] Liao YF, Chiu YT, Huang CS, Ko EW, Chen YR. Presurgical orthodontics versus no presurgical orthodontics: treatment outcome of surgical-orthodontic correction for skeletal class III open bite. *Plast Reconstr Surg* 2010 Dec;126:2074–83.
- [11] Penedo ND, Elias CN, Pacheco MCT, Gouvea JP. 3D simulation of orthodontic tooth movement. *Dental Press J Orthod* 2010;15:98–108.
- [12] Bailey LJ, Almeida MA. Stability of the palatal rugae as landmark for analysis of dental casts in extraction and nonextraction cases. *Angle Orthod* 1996;66:73–8.
- [13] Fourie Z, Damstra J, Schepers RH, Gerrits PO, Ren Y. Segmentation process significantly influences the accuracy of 3D surface models derived from cone beam computed tomography. *Eur J Radiol* 2012;81:e524–30.
- [14] Nalcacia R, Kocoglu-Altan AB, Bicakcic AA, Ozturkd F, Babacand H. A reliable method for evaluating upper molar distalization: superimposition of three-dimensional digital models. *Korean J Orthod* 2015;45:82–8.
- [15] Ali D, Mohammed H, Koo SH, Kang KH, Kim SC. Three-dimensional evaluation of tooth movement in Class II malocclusions treated without extraction by orthodontic mini-implant anchorage. *Korean J Orthod* 2016;46:280–9.
- [16] Ko EW, Lin SC, Chen YR, Huang CS. Skeletal and dental variables related to the stability of orthognathic surgery in skeletal class III malocclusion with a surgery-first approach. *J Oral Maxillofac Surg* 2013;71:e215–23.
- [17] Lin HH, Chuang YF, Weng JL, Lo LJ. Comparative validity and reproducibility study of various landmark-oriented reference planes in 3-dimensional computed tomographic analysis for patients receiving orthognathic surgery. *PloS one* 2015; 10:e0117604.
- [18] Jang I, Tanaka M, Koga Y, Iijima S, Yozgatian JH, Cha BK, et al. A novel method for the assessment of three-dimensional tooth movement during orthodontic treatment. *Angle Orthod* 2009;79:447–53.
- [19] Ruellas AC, Yatabe MS, Souki BQ, Benavides E, Nguyen T, Luiz RR, et al. 3D mandibular superimposition: comparison of regions of reference for voxel-based registration. *PLoS One* 2016;11:e0157625.
- [20] An K, Jang I, Choi DS, Jost-Brinkmann PG, Cha BK. Identification of a stable reference area for superimposing mandibular digital models. *J Orofac Orthop* 2015;76:508–19.
- [21] Joh B, Bayome M, Park JH, Park JU, Kim Y, Kook YA. Evaluation of minimal versus conventional presurgical orthodontics in skeletal class III patients treated with two-jaw surgery. *J Oral Maxillofac Surg* 2013;71:1733–41.
- [22] Min BK, Choi JY, Baek SH. Comparison of treatment duration between conventional three-stage method and surgery-first approach in patients with skeletal Class III malocclusion. *J Craniofac Surg* 2014;25:1752–6.
- [23] Zhou Y, Li Z, Wang X, Zou B, Zhou Y. Progressive changes in patients with skeletal Class III malocclusion treated by 2-jaw surgery with minimal and conventional presurgical orthodontics: a comparative study. *Am J Orthod Dentofacial Orthop* 2016;149:244–52.
- [24] Lee J, Kim YI, Hwang DS, Kim KB, Park SB. Effect of occlusal vertical dimension changes on postsurgical skeletal changes in a surgery-first approach for skeletal Class III deformities. *Am J Orthod Dentofacial Orthop* 2014;146:612–9.
- [25] Ho CT, Lin HH, Liou EJ, Lo LJ. Three-dimensional surgical simulation improves the planning for correction of facial prognathism and asymmetry: a qualitative and quantitative study. *Sci Rep* 2017;7:40423.
- [26] Wang YC, Ko EW, Huang CS, Chen YR, Takano-Yamamoto T. Comparison of transverse dimensional changes in surgical skeletal Class III patients with and without presurgical orthodontics. *J Oral Maxillofac Surg* 2010;68:1807–12.
- [27] Troy BA, Shanker S, Field HW, Vig K, Johnston W. Comparison of incisor inclination in patients with Class III malocclusion treated with orthognathic surgery or orthodontic camouflage. *Am J Orthod Dentofacial Orthop* 2009;135:146. e1-9;discussion 146-7.
- [28] Vasilakos G, Schilling R, Halazonetis D, Gkantidis N. Assessment of different techniques for 3D superimposition of serial digital maxillary dental casts on palatal structures. *Sci Rep* 2017;7:5838.
- [29] Talaat S, Kaboudan A, Bourauel C, Ragy N, Kula K, Ghoneima A. Validity and reliability of three-dimensional palatal superimposition of digital dental models. *Eur J Orthod* 2017;39:365–70.
- [30] Park TJ, Lee SH, Lee KS. A method for mandibular dental arch superimposition using 3D cone beam CT and orthodontic 3D digital model. *Korean J Orthod* 2012;42:169–81.