

PEP-1-FK506BP inhibits alkali burn-induced corneal inflammation on the rat model of corneal alkali injury

Dae Won Kim^{2,#}, Sung Ho Lee^{3,#}, Min Jea Shin^{1,#}, Kibom Kim³, Sae Kwang Ku⁴, Jong Kyu Youn¹, Su Bin Cho¹, Jung Hwan Park¹, Chi Hern Lee¹, Ora Son¹, Eun Jeong Sohn¹, Sung-Woo Cho⁵, Jong Hoon Park⁶, Hyun Ah Kim⁷, Kyu Hyung Han¹, Jinseu Park¹, Won Sik Eum^{1,*} & Soo Young Choi^{1,*}

¹Department of Biomedical Science and Research Institute of Bioscience and Biotechnology, Hallym University, Chunchon 24252,

²Department of Biochemistry and Molecular Biology, Research Institute of Oral Sciences, College of Dentistry, Gangnung-Wonju National University, Gangneung 25457, ³R&D Center, Lumieye Genetics Co., Ltd. Seoul 06198, ⁴Department of Anatomy and Histology, College of Korean Medicine, Daegu Haany University, Gyeongsan 38610, ⁵Department of Biochemistry and Molecular Biology, University of Ulsan College of Medicine, Seoul 05505, ⁶Department of Biological Sciences, Sookmyung Women's University, Seoul 04310, ⁷Division of Rheumatology, Department of Internal Medicine, Hallym University Sacred Heart Hospital, Pyongchon 14068, Korea

FK506 binding protein 12 (FK506BP) is a small peptide with a single FK506BP domain that is involved in suppression of immune response and reactive oxygen species. FK506BP has emerged as a potential drug target for several inflammatory diseases. Here, we examined the protective effects of directly applied cell permeable FK506BP (PEP-1-FK506BP) on corneal alkali burn injury (CAI). In the cornea, there was a significant decrease in the number of cells expressing pro-inflammation, apoptotic, and angiogenic factors such as TNF- α , COX-2, and VEGF. Both corneal opacity and corneal neovascularization (CNV) were significantly decreased in the PEP-1-FK506BP treated group. Our results showed that PEP-1-FK506BP can significantly inhibit alkali burn-induced corneal inflammation in rats, possibly by accelerating corneal wound healing and by reducing the production of angiogenic factors and inflammatory cytokines. These results suggest that PEP-1-FK506BP may be a potential therapeutic agent for CAI. [BMB Reports 2015; 48(11): 618-623]

INTRODUCTION

Alkali injuries of the eye represent one of the most serious forms of eye trauma and may cause extensive damage to the ocular surface epithelium, cornea, and anterior segment, re-

sulting in irreversible vision loss (1-3). Corneal alkali burn injury (CAI) occurs rarely, but is accompanied by a poor prognosis for rehabilitation. Acute inflammation of CAI is characterized by rapid infiltration of neutrophils into the cornea; the chronic inflammation involves migration and recruitment of inflammatory cells over extended periods into the cornea with resultant damage to the normal tissue. This damage is induced by secretion of proteolytic enzymes and/or oxidative derivatives into the extracellular matrix (4). In an effort to preserve epithelial integrity and prevent stromal ulceration, a number of therapeutic strategies have been tried, including treatment with fibronectin, retinoic acid, sodium hyaluronate, as well as conjunctival transplant (5-8). In this report, we tested the anti-inflammatory effect of PEP-1-FK506BP and found it to be an effective anti-inflammatory agent in a CAI rat model. The rat model of CAI has been used as a valuable animal model for developing ocular drugs (9-11).

FK506-binding proteins (FK506BPs) belong to a family of immunophilins named for their ability to bind to immunosuppressive drugs. FK506BP is a small peptide (12 kDa) with a single FK506BP domain. FK506BP is involved in multiple biological processes, including binding to rapamycin and the formation of a complex of rapamycin-mediated PI3K/Akt (12, 13). It has been demonstrated that protein transduction domains (PTDs) can deliver various exogenous molecules into living cells and tissues. In a previous study, we showed that topical application of PEP-1-FK506BP to mice ears significantly inhibited 12-O-tetradecanoylphorbol-13-acetate (TPA)-induced inflammation (14-18).

Inflammatory enzymes such as cyclooxygenase-2 (COX-2) as well as cytokines, IL-1 β , and TNF- α contribute to the pathogenesis of several inflammatory diseases (19, 20). COX-2 is an inducible isoform generated by a number of pro-inflammatory stimuli, lipopolysaccharide (LPS) and tumor promoters including TPA (21, 22). Additionally, it is well known that COX-2, Caspase-3, and vascular endothelial growth factor (VEGF) ex-

*Corresponding authors. Soo Young Choi, Tel: +82-33-248-2112; Fax: +82-33-248-3201; E-mail: sychoi@hallym.ac.kr, Won Sik Eum, Tel: +82-33-248-2112; Fax: +82-33-248-3201; E-mail: wseum@hallym.ac.kr

[#]These authors equally contributed to this work.

<http://dx.doi.org/10.5483/BMBRep.2015.48.11.041>

Received 4 March 2015, Revised 20 March 2015,
Accepted 26 March 2015

Keywords: Corneal alkali burn injury, Corneal inflammation, Corneal neovascularization, PEP-1-FK506BP, Protein therapy

pression levels are increased in conjunction with CAI (23-25). It has been shown that treatment with PEP-1-FK506BP decreased elevated levels of pro-inflammatory cytokines in dry eye syndrome and ameliorated atopic dermatitis. In this report, we investigated the protective effects of PEP-1-FK506BP in a rat CAI model. The results suggest that PEP-1-FK506BP may be a potential drug target for CAI, although the precise action of FK506BP needs to be further elucidated.

RESULTS AND DISCUSSION

Changes on the epithelial wound healing

Topical application of PEP-1-FK506BP to CAI-induced rats significantly inhibited corneal damage and infiltration of mononuclear cells which express apoptosis markers, pro-inflammatory cytokines, angiogenic factors, and inflammatory factors. This study demonstrated that a PEP-1-FK506BP protein can be directly transduced into mouse corneal and conjunctival tissue where it effectively rescued mice from Botulinum toxin A-induced dry eye (26). The protective mechanism of PEP-1-FK506BP needs further exploration, but it has also been shown that PEP-1-FK506BP protected several cells from oxidative stress-induced cell toxicity and could be a potential therapeutic agent against atopic dermatitis because of its anti-inflammatory effects (26-28).

The potential consequence of PEP-1-FK506BP on wound healing of the cornea was examined using a corneal alkali injury (CAI) rat model. Corneal reepithelialization after CAI plays

a crucial role in the cessation of eye damage (29). Significant ($P < 0.01$) increases in corneal damage were detected in the CAI control group throughout experimental periods compared with intact control and correspond well with previous studies (30, 31). 0.1% sodium hyaluronate was used as a positive control to test the *in vivo* efficacy of PEP-1-FK506BP on CAI. Corneal damage was significantly decreased in the 0.1% sodium hyaluronate treated control group. Topically applied PEP-1-FK506BP effectively decreased corneal damage from 7-14 days after initiation of treatment (CAI to one group and 0.1% sodium hyaluronate to another group) (Fig. 1). The extent of damage in the PEP-1-FK506BP treated group was similar to that of the 0.1% sodium hyaluronate treated control group.

CAI induced histopathologic changes on eye

Acute corneal inflammation is characterized by rapid infiltration of neutrophils into the cornea. Chronic inflammation involves recruitment and migration of inflammatory cells over extended periods into the cornea with resultant damage to the normal tissue due to release of proteolytic enzymes and/or oxidative derivatives into the extracellular matrix (4, 32).

To evaluate the degree of corneal damage to rats, inflammatory cells were detected on the cornea, anterior chambers, and lens by H&E staining (Fig. 2). Note that infiltration of inflammatory cells was detected in CAI induced rats. Numerous mononuclear inflammatory cells infiltrated into stroma, cornea, anterior chambers, and lens in the CAI control group

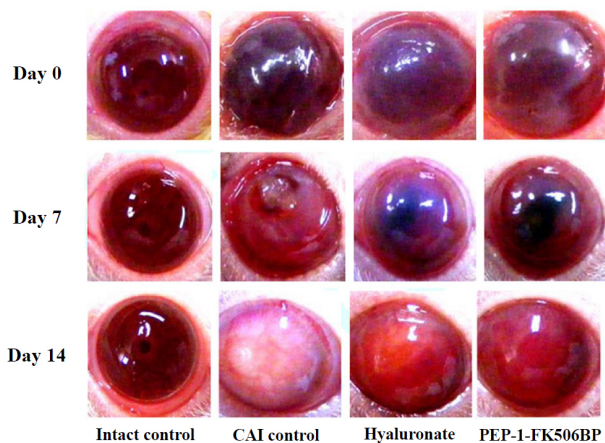


Fig. 1. Changes in corneal damage during topical application of test materials (5 µl/eye; twice a day for 14 days) in CAI-induced rats. 5 mm of filter paper was soaked with 1N NaOH and was placed onto the center of cornea for 60 seconds to induce CAI. After rinsing with sterile saline (10 ml) as previously described, corneal damage was monitored for 14 days (20). Saline soaked filter papers were used for the intact control in place of alkali soaked filter paper. For each treated group, 5 µl of PEP-1-FK506BP or 0.1% sodium hyaluronate (Samil Pharm. Co., Korea) was topically administered to eyes, twice a day for 14 days.

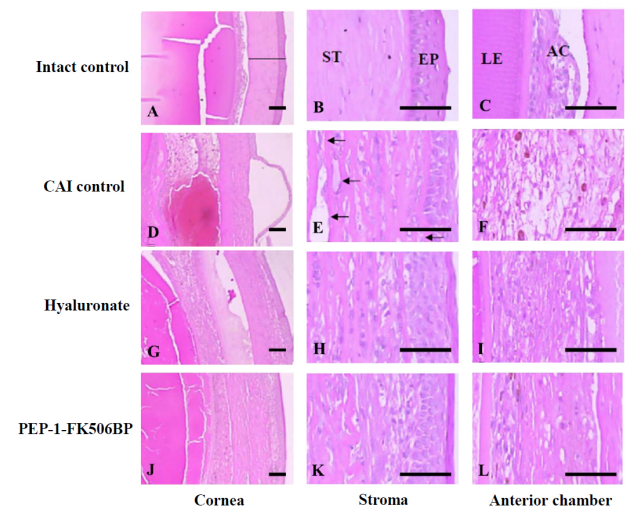


Fig. 2. Anti-inflammatory effects of PEP-1-FK506BP in corneal tissue. Images of H&E staining of corneal tissues of CAI induced rats after PEP-1-FK506BP or 0.1% sodium hyaluronate treatment as well as intact control and CAI controls. H&E staining of cornea to anterior chambers in the intact control (A-C), CAI control (D-F), 0.1% sodium hyaluronate (G-I), and PEP-1-FK506BP (J-L) treated groups. Scale bars = 200 µm. Original magnification ×40 and ×200 (EP, epithelium; ST, stroma; AC, anterior chambers; LE, lens).

(Figs. 2D-F). Damage to surrounding tissue and stroma neovascularization (arrows) in corneal epithelia was also dramatically increased in the CAI control group (Figs. 2D-F). This corneal damage was significantly inhibited in both the hyaluronate and PEP-1-FK506BP treated groups (Fig. 2G-L) relative to the CAI control. Not only were the number of infiltrated inflammatory cells in the cornea, but also various histopathologic changes including thicknesses of cornea, anterior chambers, and neovasculatures decreased to the same degree in both of PEP-1-FK506BP and sodium hyaluronate treated groups.

CAI induced infiltration of immunoreactive cells

To test the protective effects of PEP-1-FK506BP on eye inflammation, we evaluated the number of infiltrated immunoreactive mononuclear cells after corneal alkali injury. Infiltration of inflammatory cells, mainly polymorphonuclear cells (PMNs) on the cornea and anterior chambers, between the inner limiting membranes of the cornea and the lens are common histopathological features of CAI. Infiltration of PMNs induce corneal neovascularization, fibrosis, and increases corneal thicknesses (33). The number of cells which express apoptotic markers (caspase-3 and PARP), pro-inflammatory cytokines (TNF- α

and IL-1 β), and angiogenic or inflammatory factors (VEGF, COX-2, and iNOS) were counted by immunohistochemistry. VEGF, COX-2, IL-1 β , and iNOS immunoreactive cells were remarkably increased in corneal epithelium (Fig. 3). Statistically significant ($P < 0.01$) decreases in the numbers of caspase-3, PARP, TNF- α , VEGF, COX-2, IL-1 β , and iNOS-immunoreactive cells were observed in the corneal epithelium in response to PEP-1-FK506BP treatment. Significant ($P < 0.01$) decreases of caspase-3, PARP, TNF- α , COX-2, and iNOS were detected while VEGF and IL-1 β -immunoreactive cells decreased non-significantly in 0.1% sodium hyaluronate treated rats compared with CAI control rats. The overall inhibitory efficacy of test materials on the eye demonstrated that PEP-1-FK506BP may provide a therapeutic agent for immunoreactivities of apoptotic markers, pro-inflammatory cytokines, and angiogenic factors.

PEP-1-FK506BP reduced CAI induced corneal opacity and angiogenesis

Cornea opacification and CNV have been used as a predictable index for detecting the efficacy of various test materials in CAI models (34, 35). In this system, cornea opacification was evaluated using a corneal opacity scoring system of subcorneal

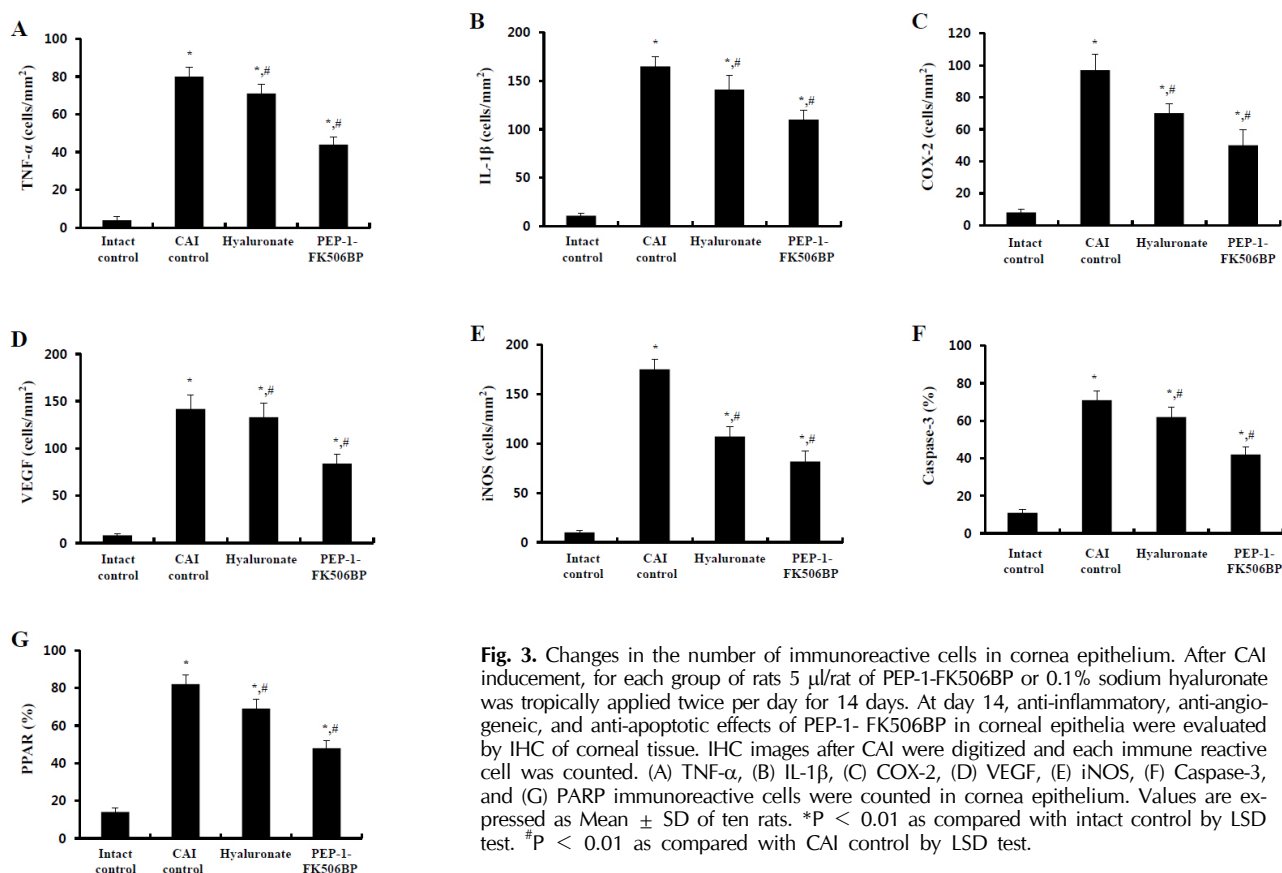


Fig. 3. Changes in the number of immunoreactive cells in cornea epithelium. After CAI induction, for each group of rats 5 μ l/rat of PEP-1-FK506BP or 0.1% sodium hyaluronate was topically applied twice per day for 14 days. At day 14, anti-inflammatory, anti-angiogenic, and anti-apoptotic effects of PEP-1-FK506BP in corneal epithelia were evaluated by IHC of corneal tissue. IHC images after CAI were digitized and each immune reactive cell was counted. (A) TNF- α , (B) IL-1 β , (C) COX-2, (D) VEGF, (E) iNOS, (F) Caspase-3, and (G) PARP immunoreactive cells were counted in cornea epithelium. Values are expressed as Mean \pm SD of ten rats. * $P < 0.01$ as compared with intact control by LSD test. # $P < 0.01$ as compared with CAI control by LSD test.

architectures including the pupil, iris vessels, or anterior chambers (36). In the present study, marked increases in corneal opacification grades (level 5: the highest level) were detected in the CAI control group after 1N NaOH exposure. PEP-1-FK506BP significantly protected against the effect on the cornea from alkali injury. Sodium hyaluronate had a statistically significant positive influence on epithelial re-surfacing, especially during the late healing phase (37, 38), and is used as a reference drug in CAI experiments (39) because of its favorable anti-inflammatory and anti-oxidative effects (40, 41). Corneal opacity scores were significantly increased in the CAI control group immediately after CAI induction and throughout the experimental period compared with the intact control group. However, these increases in corneal opacity scores were significantly inhibited by PEP-1-FK506BP treatment or 0.1% sodium hyaluronate from day 2 and 5 after initiation of topical application, respectively. The protective effects of PEP-1-FK506BP were greater than that of 0.1% sodium hyaluronate (Fig. 4A).

The protective effect of PEP-1-FK506BP on CNV has been studied in this report since neovascularization is directly related to vision loss (42-44). CNV was also evaluated using neovascularization scores for 2 weeks from the CAI induction (Fig. 4B). There were significant ($P < 0.01$) increases in corneal neovascularization scores in the CAI control group from day 1 after CAI induction and throughout the experimental period. These increases in corneal neovascularization scores were significantly ($P < 0.01$ or $P < 0.05$) inhibited by treatment with 0.1% sodium hyaluronate and PEP-1-FK506BP from day 6 and day 5, respectively. The cornea neovascularization scores at the end point were -10.22 and -21.78% in the 0.1% sodium hyaluronate and PEP-1-FK506BP treated groups, respectively. This indicates that PEP-1-FK506BP might be a more effective therapeutic agent for corneal alkali burn induced neovascularization and related vision losses than 0.1% sodium hyaluronate. From these results, we suggest PEP-1-FK506BP is a promising therapeutic lead molecule for corneal reepithelialization after alkali injury.

MATERIALS AND METHODS

Animals

All procedures used in this study were in accordance with the principles of the Association for Research in Vision and Ophthalmology (ARVO) Statement for the Use of Animals in Ophthalmic and Vision Research. All experimental procedures involving animals and their care were in accordance with the Guide for the Care and Use of Laboratory Animals of the National Veterinary Research and Quarantine Service of Korea, and were approved by the Hallym Medical Center Institutional Animal Care and Use Committee. 6-week-old male Sprague-Dawley rats (SLC, JAPAN) were used after acclimatization for 7 days.

Induction of CAI

The rats ($n = 10$ per group) were anesthetized by 25 mg/kg intraperitoneal injection of Zoletile 50 (Virbac Lab., France). To induce alkali injuries, 5 mm in diameter filter paper soaked with 1N NaOH was placed on the central cornea for 60 seconds. The eyes were then rinsed with sterile saline (10 ml) as previously described (33). For the intact control, saline soaked filter papers were placed on the cornea, in place of the alkali soaked paper. For each treated group, 5 μ l of PEP-1-FK506BP or 0.1% sodium hyaluronate (Samil Pharm. Co., Korea) was topically administered to eyes, twice a day for 14 days. In intact and CAI control groups, saline was applied instead of test materials. Changes in corneal opacity, neovascularization, and cornea epithelial wound healings were monitored via histopathological observation for 14 days.

Histomorphometry

The proportion of damaged corneal epithelium region, (%/5 mm of corneal epithelial lining), total thickness of cornea

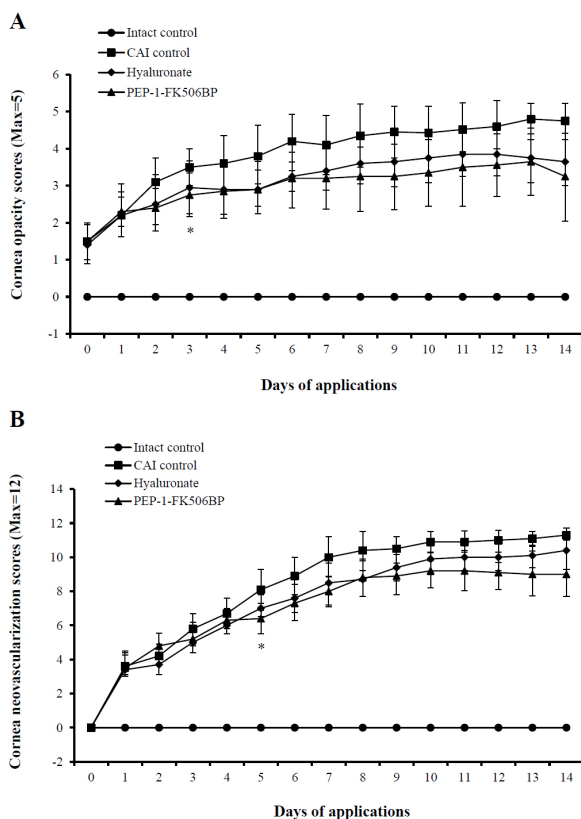


Fig. 4. Effect of PEP-1-FK506BP on corneal opacity and neovascularization after alkali injury. (A) Corneal opacity scores and (B) CNV scores were evaluated for 2 weeks following the CAI challenge. Values are expressed as Mean \pm SD for 10 rats in each group. * $P < 0.05$, between PEP-1-FK506BP treated rats and intact control rats by LSD test.

(μm /crossly trimmed corneal tissues), numbers of inflammatory cells infiltrated into the cornea (cells/ mm^2 of cornea stroma), and anterior chambers (cells/ mm^2 of anterior chambers, between cornea and lens), and numbers of neovasculatures in the cornea (vessels/ mm^2 of cornea stroma) were measured using a digital image analyzer (DMI-300, DMI, KOREA). The cells, which were stained by each antiserum including caspase-3, PARP, TNF- α , VEGF, COX-2, IL-1 β , and iNOS were regarded as immunoreactive (45). The percentages of caspase-3 and PARP-immunoreactive cells in cornea epithelium were measured by the digital image analyzer. The numbers of TNF- α , VEGF, COX-2, IL-1 β , and iNOS-positive cells per mm^2 of anterior chambers were measured, as well as caspase-3 and PARP.

Corneal opacity scoring

A previously described scoring system (36) was used to measure the degree of opacification (between 0-5); Briefly, 0 = clear and compact cornea, 1 = minimal superficial opacity, 2 = mild deep (stromal) opacity with pupil margin and iris vessels visible, 3 = moderate stromal opacity with only pupil margin visible, 4 = intense stromal opacity with anterior chamber visible, 5 = maximal corneal opacity with total obscuration of the anterior chamber.

Neovascularization scoring

Neovascularization was graded between 0 and 3 per corneal quadrant, with increments of 0.5, by a grid system based on the centripetal extent of neovascular branch outgrowth from the corneoscleral limbus (46). Neovascularization was generally graded by the extent of vessel invasion toward the central cornea regions, and was subdivided into 12 grades by the length of invaded vessels. Dilated limbal vessels not penetrating the corneal stroma were not considered to represent corneal neovascularization. All grading was done in a masked fashion. Scores for each quadrant were then summed to derive the cornea neovascularization index (range, 0-12) for each eye.

Statistical analysis

The obtained data were analyzed by one way ANOVA test followed by least-significant differences (LSD) multi comparison test. $P < 0.05$ was significantly different.

ACKNOWLEDGEMENTS

This work was supported by a Priority Research Centers Program grant (NRF-2009-0093812) and in part by a Mid-Career Researcher Program grant (2012R1A2A2A06043084) through the National Research Foundation of Korea funded by the Ministry of Science, ICT & Future Planning and by a grant of the Korean Health Technology R&D Project (A120960), Ministry of Health & Welfare, Republic of Korea and in part by a research grant from Hallym University (HRF-2015-01-014).

REFERENCES

1. Ormerod LD, Abelson MB and Kenyon KR (1989) Standard models of corneal injury using alkali-immersed filter discs. *Invest Ophthalmol Vis Sci* 30, 2148-2153
2. Wagoner MD (1997) Chemical injuries of the eye: current concepts in pathophysiology and therapy. *Surv Ophthalmol* 41, 275-313
3. Liu X, Lin Z, Zhou T et al (2011) Anti-angiogenic and anti-inflammatory effects of SERPINA3K on corneal injury. *PLoS One* 6, e16712
4. Kao WW, Ebert J, Kao CW, Covington H and Cintron C (1986) Development of monoclonal antibodies recognizing collagenase from rabbit PMN; the presence of this enzyme in ulcerating corneas. *Curr Eye Res* 5, 801-815
5. Phan TM, Foster CS, Shaw CD, Zagachin LM and Colvin RB (1991) Topical fibronectin in an alkali burn model of corneal ulceration in rabbits. *Arch Ophthalmol* 109, 414-419
6. Tseng SC (1985) Topical retinoid treatment for dry eye disorders. *Trans Ophthalmol Soc UK* 104, 489-495
7. Reim M (1990) A new treatment concept for severe caustic and thermal burns of the eyes. *Klin Monbl Augenheilkd* 196, 1-5
8. Thoft RA (1977) Conjunctival transplantation. *Arch Ophthalmol* 95, 1425-1427
9. Sekundo W, Augustin AJ and Stempel I (2002) Topical allopurinol or corticosteroids and acetylcysteine in the early treatment of experimental corneal alkali burns: a pilot study. *Eur J Ophthalmol* 12, 366-372
10. Dan L, Shi-long Y, Miao-li L et al (2008) Inhibitory effect of oral doxycycline on neovascularization in a rat corneal alkali burn model of angiogenesis. *Curr Eye Res* 33, 653-660
11. Guler M, Yilmaz T, Ozercan I and Elkiran T (2009) The inhibitory effects of trastuzumab on corneal neovascularization. *Am J Ophthalmol* 147, 703-708
12. Snyder SH and Sabatini DM (1995) Immunophilins and the nervous system. *Nat Med* 1, 32-37
13. Schiene-Fischer C and Yu C (2001) Receptor accessory folding helper enzymes: the functional role of peptidyl prolyl cis/trans isomerases. *FEBS Lett* 495, 1-6
14. Dietz GP (2010) Cell-penetrating peptide technology to deliver chaperones and associated factors in diseases and basic research. *Curr Pharm Biotechnol* 11, 167-174
15. Liu L, Yu R, Shi Y et al (2014) Transduced protein transduction domain linked HSP27 protected LECs against UVB radiation-induced damage. *Exp Eye Res* 120, 36-42
16. Kim SY, Jeong HJ, Kim DW et al (2011) Transduced PEP-1-FK506BP inhibits the inflammatory response in the Raw 264.7 cells and mouse models. *Immunobiol* 216, 771-781
17. Wadia JS and Dowdy SF (2002) Protein transduction technology. *Curr Opin Biotechnol* 13, 52-56
18. Youn JK, Kim DW, Kim ST et al (2014) PEP-1-HO-1 prevents MPTP-induced degeneration of dopaminergic neurons in a Parkinson's disease mouse model. *BMB Rep* 47, 569-574
19. Bertolini A, Ottani A and Sandrini M (2002) Selective

- COX-2 inhibitors and dual acting anti-inflammatory drugs: critical remarks. *Curr Med Chem* 9, 1033-1043
20. Firestein GS (2003) Evolving concepts of rheumatoid arthritis. *Nature* 423, 356-361
 21. Uto T, Fujii M and Hou DX (2007) Effects of 6-(methylsulfinyl)hexyl isothio cyanate on cyclooxygenase-2 expression induced by lipopolysaccharide, interferon-gamma and 12-O-tetradecanoylphorbol-13-acetate. *Oncol Rep* 17, 233-238
 22. Duan Y, Chen F, Zhang et al (2014) Aspirin inhibits lipopolysaccharide-induced COX-2 expression and PGE2 production in porcine alveolar macrophages by modulating protein kinase C and protein tyrosine phosphatase activity. *BMB Rep* 47, 45-50
 23. Kawamura A, Tatsuguchi A, Ishizaki M, Takahashi H and Fukuda Y (2008) Expression of microsomal prostaglandin synthase-1 in fibroblasts of rabbit alkali-burned corneas. *Cornea* 27, 1156-1163
 24. Cejkova J, Trosan P, Cejka C et al (2013) Suppression of alkali-induced oxidative injury in the cornea by mesenchymal stem cells growing on nanofiber scaffolds and transferred onto the damaged corneal surface. *Exp Eye Res* 116, 312-323
 25. Singh N, Jani PD, Suthar T, Amin S and Ambati BK (2006) Flt-1 intrareceptor induces the unfolded protein response, apoptotic factors, and regression of murine injury-induced corneal neovascularization. *Invest Ophthalmol Vis Sci* 47, 4787-4793
 26. Kim DW, Lee SH, Ku SK et al (2013) Transduced PEP-1-FK506BP ameliorates corneal injury in Botulinum toxin A-induced dry eye mouse model. *BMB Rep* 46, 124-129
 27. Kim SY, Sohn EJ, Kim DW et al (2011) Transduced PEP-1-FK506BP ameliorates atopic dermatitis in NC/Nga mice. *J Invest Dermatol* 131, 1477-1485
 28. Song HY, Lee JA, Ju SM et al (2008) Topical transduction of superoxide dismutase mediated by HIV-1 Tat protein transduction domain ameliorates 12-O-tetradecanoyl phorbol-13-acetate (TPA)-induced inflammation in mice. *Biochem Pharmacol* 75, 1348-1357
 29. He J, Bazan NG and Bazan HE (2006) Alkali-induced corneal stromal melting prevention by a novel platelet-activating factor receptor antagonist. *Arch Ophthalmol* 124, 70-78
 30. Ma Y, Xu Y, Xiao Z et al (2006) Reconstruction of chemically burned rat corneal surface by bone marrow-derived human mesenchymal stem cells. *Stem Cells* 24, 315-321
 31. Toshida H, Odaka A, Koike D and Murakami A (2008) Effect of retinol palmitate eye drops on experimental keratoconjunctival epithelial damage induced by n-heptanol in rabbit. *Curr Eye Res* 33, 13-18
 32. Lim S and Park S (2014) Role of vascular smooth muscle cell in the inflammation of atherosclerosis. *BMB Rep* 47, 1-7
 33. Yamada J, Dana MR, Sotozono C and Kinoshita S (2003) Local suppression of IL-1 by receptor antagonist in the rat model of corneal alkali injury. *Exp Eye Res* 76, 161-167
 34. Schrage NF, Kompa S, Haller W and Langefeld S (2002) Use of an amphoteric lavage solution for emergency treatment of eye burns. First animal type experimental clinical considerations. *Burns* 28, 782-786
 35. Epstein RJ, Stulting RD, Hendricks RL and Harris DM (1987) Corneal neovascularization: Pathogenesis and inhibition. *Cornea* 6, 250-257
 36. Sonoda Y and Streilein JW (1992) Orthotopic corneal transplantation in mice—evidence that the immunogenetic rules of rejection do not apply. *Transplantation* 54, 694-704
 37. Chung JH, Fagerholm P and Lindstrom B (1989) Hyaluronate in healing of corneal alkali wound in the rabbit. *Exp Eye Res* 48, 569-576
 38. Chung J, Park Y, Paek S, Chong Y and Kim W (1999) Effect of Na-hyaluronan on stromal and endothelial healing in experimental corneal alkali wounds. *Ophthalmic Res* 31, 432-439
 39. Bae SR, Park C, Choi JC, Poo H, Kim CJ and Sung MH (2010) Effects of ultra high molecular weight poly-gamma-glutamic acid from *Bacillus subtilis* (chungkookjang) on corneal wound healing. *J Microbiol Biotechnol* 20, 803-808
 40. Soltes L, Lath D, Mendichi R and Bystricky P (2001) Radical degradation of high molecular weight hyaluronan: inhibition of the reaction by ibuprofen enantiomers. *Methods Find Exp Clin Pharmacol* 23, 65-71
 41. Frankel A, Sohn A, Patel RV and Lebowitz M (2011) Bilateral comparison study of pimecrolimus cream 1% and a ceramide-hyaluronic acid emollient foam in the treatment of patients with atopic dermatitis. *J Drugs Dermatol* 10, 666-672
 42. Mochimaru H, Usui T, Yaguchi T et al (2008) Suppression of alkali burn-induced corneal neovascularization by dendritic cell vaccination targeting VEGF receptor 2. *Invest Ophthalmol Vis Sci* 49, 2172-2177
 43. Oh JY, Kim MK, Shin MS, Lee HJ, Lee JH and Wee WR (2009) The anti-inflammatory effect of subconjunctival bevacizumab on chemically burned rat corneas. *Curr Eye Res* 34, 85-91
 44. Jo H, Jung SH, Kang J, Yim HB and Kang KD (2014) Sulodexide inhibits retinal neovascularization in a mouse model of oxygen-induced retinopathy. *BMB Rep* 47, 637-642
 45. Lee SJ, Yoo JD, Choi SY and Kwon OS (2014) The expression and secretion of vimentin in the progression of non-alcoholic steatohepatitis. *BMB Rep* 47, 457-462
 46. Dana MR and Streilein JW (1996) Loss and restoration of immune privilege in eyes with corneal neovascularization. *Invest Ophthalmol Vis Sci* 37, 2485-2494