

Available online at www.sciencedirect.com

ScienceDirect

journal homepage: www.elsevier.com/locate/radcr

Case Report

Imaging findings of ovarian metastasis of primary renal cell carcinoma: A case report and literature review[☆]

Ayumi Takayanagi, MD^{a,b}, Fumi Kato, MD, PhD^{a,*}, Ayako Nozaki, MD^{c,d},
 Ryuji Matsumoto, MD, PhD^e, Takahiro Osawa, MD, PhD^e, Ken Kuwahara, MD^f,
 Yoshihiro Matsuno, MD, PhD^f, Hiroshi Asano, MD, PhD^c, Tatsuya Kato, MD^c,
 Hidemichi Watari, MD, PhD^g, Takashige Abe, MD, PhD^e, Nobuo Shinohara, MD, PhD^e,
 Kohsuke Kudo, MD, PhD^h

^a Department of Diagnostic and Interventional Radiology, Hokkaido University Hospital, Kita14, Nishi5, Kita-Ku, Sapporo, Hokkaido, 060-8648, Japan

^b Department of Diagnostic Radiology, Sapporo City General Hospital, Sapporo, Hokkaido, Japan

^c Department of Obstetrics and Gynecology, Hokkaido University Hospital, Sapporo, Hokkaido, Japan

^d Department of Obstetrics and Gynecology, Asahikawa-Kosei Hospital, Asahikawa, Hokkaido, Japan

^e Department of Urology, Faculty of Medicine and Graduate School of Medicine, Hokkaido University, Sapporo, Hokkaido, Japan

^f Department of Surgical Pathology, Hokkaido University Hospital, Sapporo, Hokkaido, Japan

^g Department of Obstetrics and Gynecology, Hokkaido University Graduate School of Medicine and Faculty of Medicine, Sapporo, Hokkaido, Japan

^h Department of Diagnostic Imaging, Graduate School of Medicine, Hokkaido University, Sapporo, Hokkaido, Japan

ARTICLE INFO

Article history:

Received 1 January 2022

Revised 28 March 2022

Accepted 30 March 2022

Keywords:

Renal cell carcinoma

Ovarian metastasis

Imaging findings

Retrograde pathway

Ovarian plexus

ABSTRACT

A 62-year-old woman presented with a tumor in the right kidney. A right partial nephrectomy was performed, and the tumor was diagnosed as clear cell renal cell carcinoma (RCC) on histopathological examination. A right ovarian tumor was detected on follow-up computed tomography (CT) 5 years after partial nephrectomy and pathology proved RCC metastasis. RCC rarely metastasizes to the ovaries. There is limited information on the radiological features of ovarian metastasis in RCC. In this case report, we presented the CT and magnetic resonance images of ovarian metastasis of RCC. In addition, we also presented a literature review with special emphasis on the imaging features of ovarian metastasis of RCC.

© 2022 The Authors. Published by Elsevier Inc. on behalf of University of Washington.

This is an open access article under the CC BY-NC-ND license (<http://creativecommons.org/licenses/by-nc-nd/4.0/>)

[☆] Competing Interest: The authors declare no conflicts of interest associated with this manuscript.

* Corresponding author.

E-mail address: fumikato@med.hokudai.ac.jp (F. Kato).

<https://doi.org/10.1016/j.radcr.2022.03.110>

1930-0433/© 2022 The Authors. Published by Elsevier Inc. on behalf of University of Washington. This is an open access article under the CC BY-NC-ND license (<http://creativecommons.org/licenses/by-nc-nd/4.0/>)

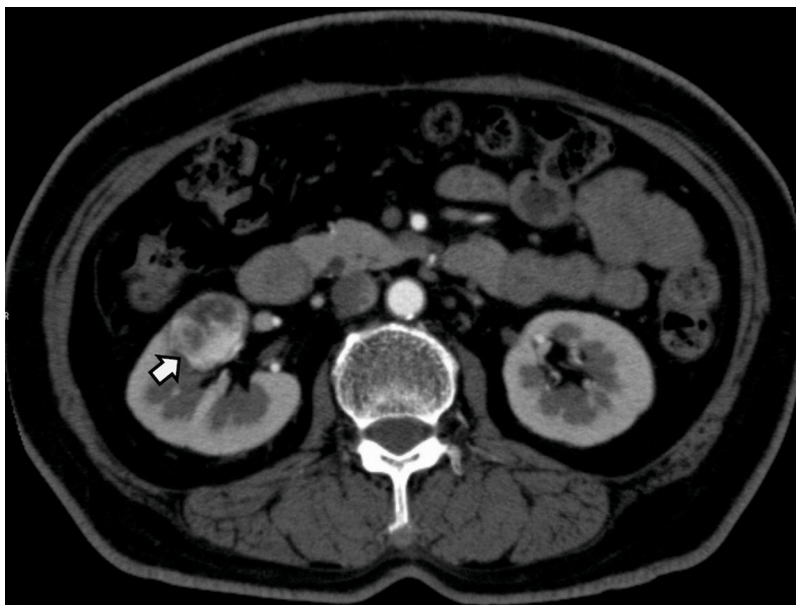


Fig. 1 – Primary clear cell renal cell carcinoma (RCC) in the right kidney. Dynamic contrast-enhanced computed tomography reveals a well-circumscribed mass in the right kidney. The mass demonstrates heterogeneous strong enhancement in the arterial phase.

Introduction

Ovarian metastasis from renal cell carcinoma (RCC) is rare. Bianchi et al. [1] reported that 0.2% of RCCs metastasized to the ovaries. Although there are 39 cases and some literature reviews about ovarian metastasis of RCC have been previously reported [2–29], to the best of our knowledge, no review has focused on the radiological features of ovarian metastasis of RCC. Herein, we reported a case of ovarian metastasis of RCC and a review of the literature demonstrating the radiological features of the tumor.

Case report

A 62-year-old female with poorly controlled diabetes underwent computed tomography (CT) to screen for malignant lesions (Fig. 1). A tumor was detected in the right kidney and was suspected to be RCC on dynamic contrast-enhanced CT. The tumor was treated with laparoscopic right partial nephrectomy. During histopathological examination, the tumor was diagnosed as clear cell RCC (pT1aNOM0, Union for International Cancer Control seventh edition) (Fig. 4A and C). Regular follow-up CTs were performed every year, and a well-enhanced 16 mm mass was detected in the right ovary 5 years after the surgery (Fig. 2B). The mass was retrospectively recognized as a 10 mm homogeneous enhanced nodule 1 year

earlier (Fig. 2A); however, the right ovarian vein thrombus and the dilated right ovarian vein made it difficult to note the mass at that time. Subsequent magnetic resonance imaging (MRI) was performed (Fig. 3). The mass showed heterogeneous signal intensity, mostly low and partially high signal on T2-weighted image (T2WI), which implied the existence of degeneration or necrosis, and showed high signal intensity on diffusion-weighted imaging and low apparent diffusion coefficient (ADC) (ADC value = $0.85 \times 10^{-3} \text{ mm}^2/\text{s}$). The tumor was generally well-enhanced and small degenerative areas were also observed. A malignant tumor, including metastasis from RCC and primary ovarian cancer, was suspected; thus, laparoscopic salpingo-oophorectomy of the right ovary was performed. Histology revealed the diagnosis of ovarian metastasis from clear cell RCC (Fig. 4B and D). Local recurrence was identified in the right kidney on a 4-year follow-up CT after salpingo-oophorectomy of the right ovary (Fig. 5) and the patient is under watchful waiting.

Discussion

Although the ovaries are common sites for intra-abdominal metastasis, ovarian metastasis from RCC is rare. RCCs generally metastasize to the lungs (45.2%), bones (29.5%), lymph nodes (21.8%), liver (20.3%), and brain (8.1%) [1]. Metastatic ovarian tumors are derived from the colon (32.2%), appendix (20.3%), breast (8.4%), small bowel (6.8%), stomach (6.8%),

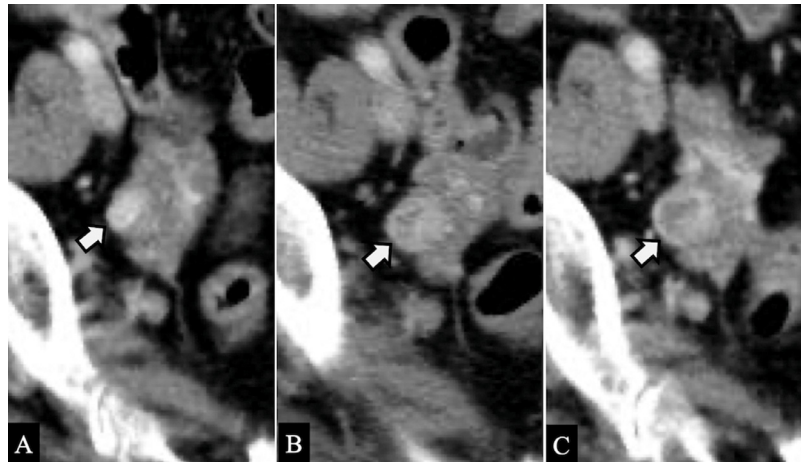


Fig. 2 – Change over time of the ovarian metastasis: (A) 1 year earlier from detection, (B) at the time of detection, and (C) 9 months after detection. Serial contrast-enhanced computed tomography is shown. (A) A homogeneous, well-enhanced 10 mm mass in the right ovary can be retrospectively recognized 1 year before detection. (B) The mass has increased slightly to 16 mm in size by the time of detection. (C) Tumor size has not changed significantly at 9 months; the necrotic part of the tumor has slightly enlarged.

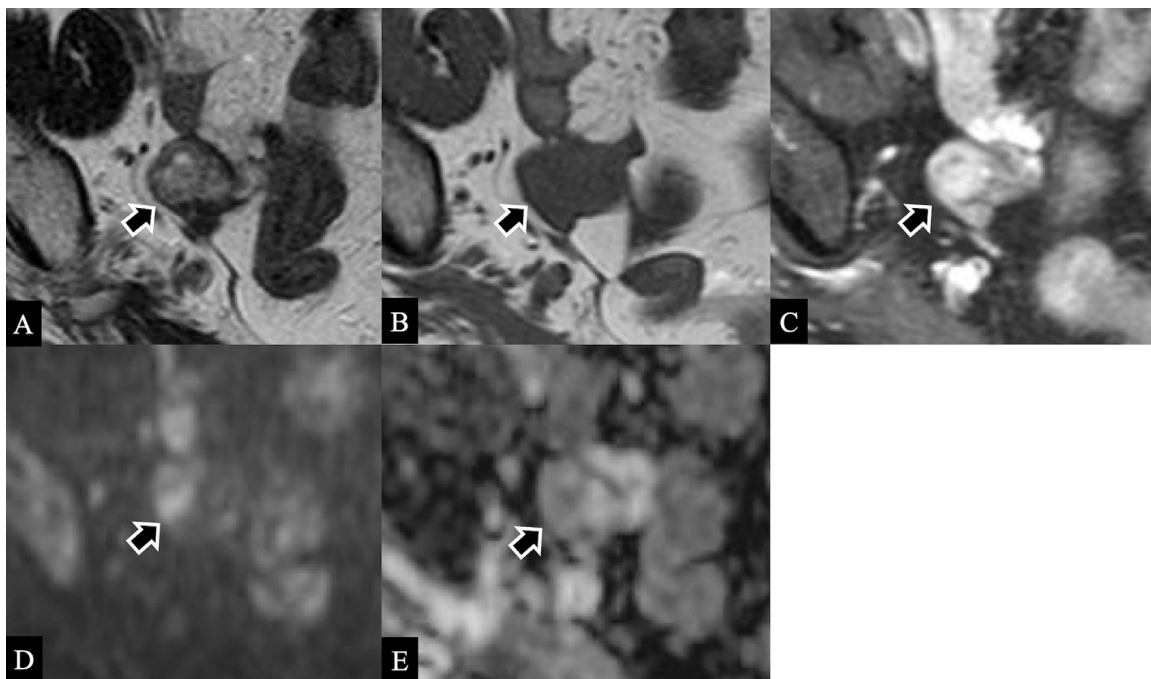


Fig. 3 – Magnetic resonance images of the ovarian metastasis were obtained 9 months after detection. The mass demonstrates heterogeneous signal intensity, mostly low and partially high signal intensity on T2-weighted image (A) implying the existence of degeneration or necrosis, low signal intensity on T1-weighted image (B), high signal intensity on diffusion-weighted image (D), and low apparent diffusion coefficient value ($0.85 \times 10^{-3} \text{ mm}^2/\text{s}$) (E). The tumor is generally well-enhanced and small degenerative areas are also observed on contrast enhanced fat-suppressed T1-weighted image (C)

pancreas (5.1%), gallbladder (1.7%), and urinary bladder (1.7%) [30]. Bianchi et al. [1] reported that 0.2% of RCCs metastasized to the ovaries. In one autopsy study, ovarian metastasis was found in 0.5% of RCC cases [4]. This rarity is considered to be a result of the following three factors: (1) RCC is twice as common in men as in women, (2) the reduction of blood flow

in postmenopausal ovaries in the age group in which RCC is common leading to fewer tumor cells being delivered to the ovaries, and (3) the difficulty in differentiating the diagnosis of metastatic ovarian tumors from RCC and primary ovarian tumor [15,31].

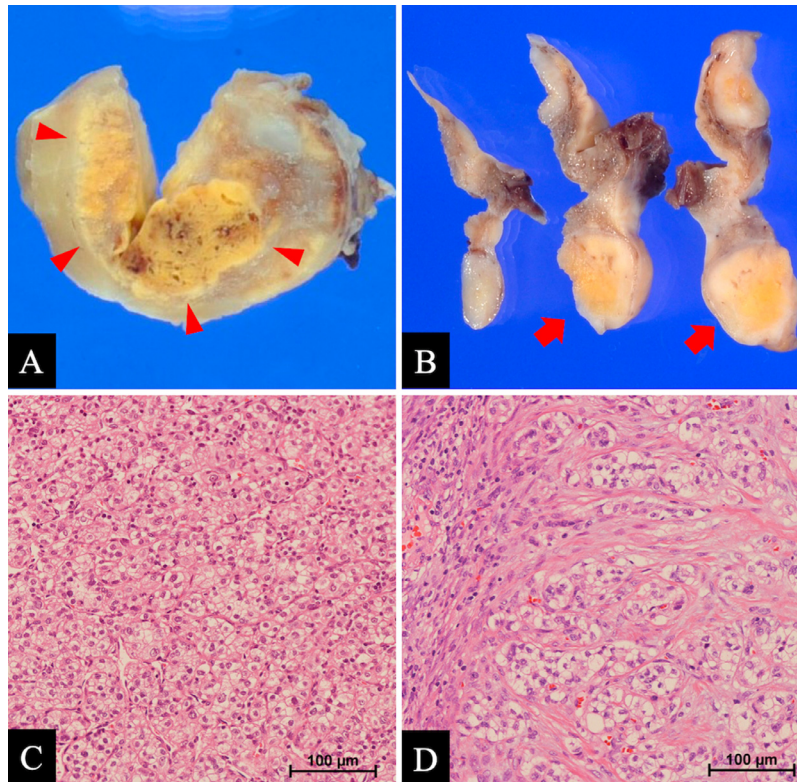


Fig. 4 – Pathological findings of the primary right renal lesion and the metastatic right ovarian lesion. The gross pathology of the renal tumor (A, arrowhead) demonstrates a well-defined, heterogeneous, yellowish, and solid appearance. The gross pathology of the ovarian tumor (B, arrow) is similar to that of the renal tumor. Hematoxylin and eosin staining (high-power field) sections of the renal tumor (C) and ovarian tumor (D) both demonstrate nests of epithelial cells with abundant clear cytoplasm separated by delicate vascular septa.

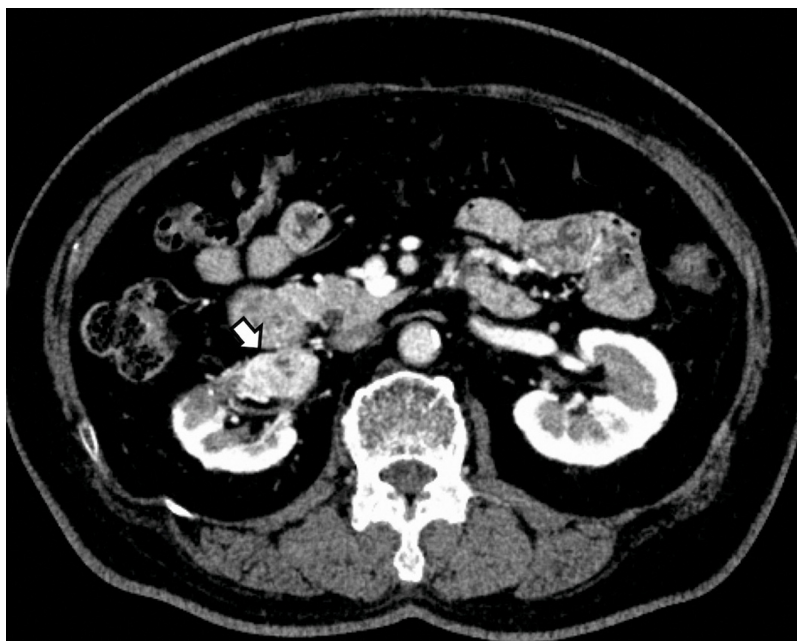

Fig. 5 – Computed tomography (CT) image of local recurrence in the right kidney. The 4-year follow-up CT after right salpingo-oophorectomy is shown. A mass with heterogeneous strong enhancement is seen in the right kidney in the cortico-medullary phase.

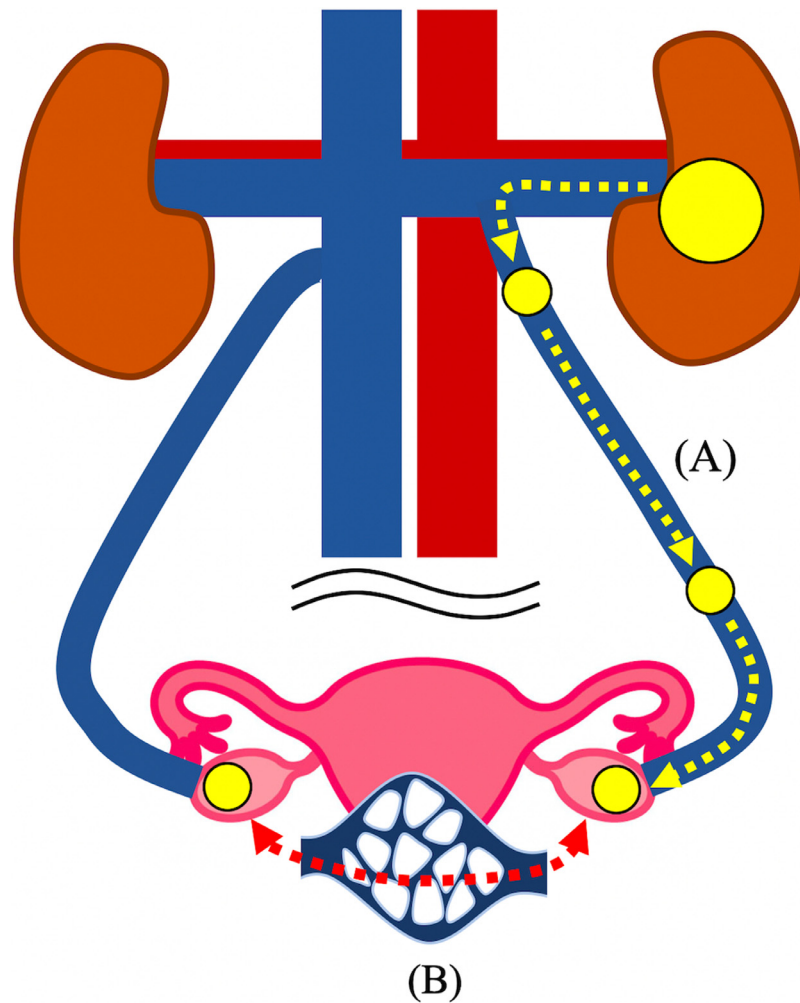


Fig. 6 – Possible metastatic pathways from the kidney to the ovary. The retrograde pathway from the left kidney to the left ovary via venous connection (A) partially explains the higher frequency of left ovarian metastasis of renal cell carcinoma (RCC). The existence of the ovarian plexus (B) possibly contributes to the bilateral ovarian metastasis of RCC.

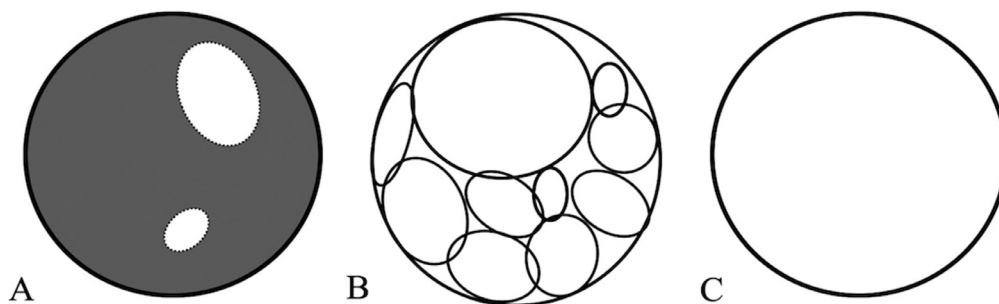


Fig. 7 – Patterns of radiological features. Ovarian tumors are categorized into three different radiological patterns: (A) solid with cyst/degeneration, (B) multilocular and solid, and (C) simple cyst.

To the best of our knowledge, there are 28 previous publications with 39 cases, and the present case was the 40th case reported [2–29]. A summary of the cases is presented in Table 1. Among these, 2 cases were from Japanese literature, and the remaining were in English. The age group of the pa-

tients ranged from 17 to 82 years (median, 50 years). The median age was younger than the predominant age of RCCs (sixth and seventh decades), which may be due to the ovaries showing an increasingly fibrotic and atrophic change at the peak age of RCC incidence. After menopause, the ovary is

Table 1 – The summary of the cases.

Year	Author [reference no.]	Age	RCC	Ovarian metastasis	First detected site	Duration between detections	Size (cm)	Imaging findings
1957	Vorder [2]	64	R	B	Kidney	11 y	R: 11 * 8 * 6 L: 17 * 10 * 8	NA
1981	Stefani [3]	68	R	L	Kidney	3 mo	NA	NA
1992	Young [4]	48	R	L	Ovary	8 y	18	NA
		62	L	R	Kidney	1 y	8 * 6 * 5.5	NA
		48	L	L	Sync		12	NA
1992	Liu [5]	28	R	L	Kidney	7 mo	12 * 10 * 8	NA
1993	Spencer [6]	40	L	B	Ovary	7 mo	NA	NA
1994	Adachi [7]	46	L	B	Kidney	3 y	NA	NA
1996	Fields [8]	54	R	L	Kidney	3 y	10	NA
1998	Vara [9]	66	R	B	Kidney	14 y	NA	Solid with degeneration
2001	Shinojima* [10]	47	L	L	Kidney	4 y	11 * 9 * 7	Multilocular
2003	Hammock [11]	48	L	R	Sync		NA	NA
2003	Insabato [12]	50	R	R	Kidney	1 y	NA	NA
		49	R	NA	Kidney	14 mo	NA	NA
		17	L	L	Kidney	2 y	NA	NA
2004	Valappil [13]	61	L	B	Kidney	7 y	R: 11.8 * 11.6 * 9.7 L: 7.4 * 7.3 * 6.7	NA
2006	Kato S* [14]	45	L	L	Kidney	11 mo	4	Solid with cyst
2006	Kato Y [15]	52	L	R	Sync		12*10	Solid with cyst
2007	Stolnicu [16]	73	NA	L	Kidney	NA	NA	NA
2009	Toquero [17]	54	L	L	Sync		4	Solid with degeneration
2009	Albrizio [18]	56	R	B	Kidney	10 y	NA	Solid with cyst
2011	Decoene [19]	47	R	L	Kidney	5 y	NA	Monolocular
2014	Bauerova [20]	61	R	B	Kidney	21 y	R: 12 * 10 * 8 L: 8 * 8 * 6	NA
2015	Bohara [21]	48	R	R	Kidney	3 y	5 * 4 * 3	NA
2015	Kostrzewa [22]	51	L	R	Kidney	4 y	1.5	NA
2016	Liang [23]	60	R	R	Sync		8	NA
		NA	NA	B	Sync		R: 15 L: 5.5	NA
		48	L	R	Kidney	14 mo	8	NA
		37	L	B	Kidney	8 mo	NA	NA
		45	R	L	Kidney	30 mo	7	NA
		43	R	R	Kidney	20 mo	7	NA
		52	L	R	Kidney	10 mo	9	NA
		52	R	L	Ovary	NA	NA	NA
2017	Uruc [24]	48	R	L	Kidney	22 mo	5.8 * 6.8	Multilocular with solid
2017	Bhaskar [25]	45	L	L	Sync		11.7 * 8.7 * 12.2	Solid with cyst
2018	Porfyrus [26]	82	R	L	Sync		16	Multilocular with solid
2019	Karaosmanoglu [27]	52	L	L	Kidney	4 y	NA	Multilocular with solid
2021	Fujii [28]	58	R	B	Kidney	8 y	NA	Solid with degeneration
2021	Snyder [29]	48	L	B	Sync		R: 8.7 L: 12.7	Solid with cyst
2019	Present case	66	R	R	Kidney	4 y	1.6	Solid with degeneration

Abbreviation: NA, not available; RCC, renal cell carcinoma; R, right; L, left; B, bilateral; sync, detected at the same time; y, year; mo, month
* Literature in Japanese.

Table 2 – Patterns of radiological features and the number of the cases.

	Solid with cyst/degeneration	Multilocular and solid	Simple cyst
The number of cases	8	5	1

reduced in weight, and its blood flow is decreased. Therefore, after menopause, fewer emboli are carried to the ovary than to the larger and more vascular organs. Furthermore, vascular sclerosis of the ovary reduces clumps of tumor cells passing through the arterioles into a more suitable environment of capillary beds or into thin-walled veins [15].

The size of the tumors ranged from 1.6 to 18 cm (median, 10 cm; the minimum was the present case). Ovarian tumor was first detected in 3 cases, RCC was first detected in 28 cases, and both ovarian tumor and RCC were simultaneously detected in 9 cases. The time interval between the appearance of ovarian metastasis varied from 3 months to 21 years. In 1 case reported by Bauerova et al. [20], ovarian tumor was detected 21 years after the treatment for renal primary. This long interval suggests the necessity of long-term follow-up after nephrectomy.

Among the 40 cases in which the laterality of the renal primaries and ovarian lesions was described, the laterality of ovarian metastasis was available in 37 cases: unilaterally in 27 cases (73%), ipsilateral in 12 cases (32%), contralateral in 15 cases (41%), and bilaterally in 10 cases (27%). This result showed that RCCs are likely to metastasize to unilateral ovaries, whereas approximately 66.1% of all secondary ovarian tumors occur bilaterally [30]. The high incidence of metastasis to the left ovary (45%) can possibly be explained by the retrograde pathway via a direct connection between the left ovarian vein and left renal vein, which does not seem sufficient considering the nearly equal occurrence in the left (49%) vs right (51%) renal origins of ovarian metastasis. Bilateral ovarian metastasis of RCCs occurred in 26% of the cases, which may suggest the contribution of the ovarian plexus (Fig. 6).

Although several cases of ovarian metastasis of RCCs have been reported with CT and/or MRI, to the best of our knowledge, no review has focused on the radiographic features. Among the 40 cases, 15 cases had CT or MR images but only 14 studies had contrast-enhanced CT or MR images; therefore, one case with (18)F-fluorodeoxyglucose-positron emission tomography/CT was excluded. The radiographic features were reviewed and categorized by 2 radiologists: one was a board-certified radiologist specializing in gynecological imaging and the other was a senior resident. Categorization was performed by consensus of the 2 radiologists and there was no discrepancy. The diagrams of the radiographic patterns and the number of cases of each pattern are shown in Figure 7 and Table 2, respectively. Seven of the cases represented heterogeneous tumors mixed with solid and cystic/degenerative components, 3 multilocular cystic tumors with solid components, and 1 unilocular cyst without intraluminal nodules. The solid components of the tumors were well-enhanced. Since these findings are not specific to ovarian metastasis of RCC, differential diagnosis from primary ovarian tumors remains difficult. It is important to consider the possibility of metastasis of RCC, even if the ovarian lesion is unilateral or if a long time has

passed since the preceding nephrectomy. In addition, it may be difficult to locate small lesions in the ovary when ovarian vein thrombosis is present as in this case, which may be a pitfall when interpreting the follow-up CT after RCC treatment.

Conclusion

We reported a case of unilateral ovarian metastasis of RCC and presented a review of the literature, including imaging features. Although differentiating from primary ovarian tumors remains a radiological challenge, it is important to consider the possibility of metastasis of RCC, even if the ovarian lesion is unilateral or a long time has passed since the preceding nephrectomy.

Patient consent

Informed consent was obtained from the patient.

REFERENCES

- [1] Bianchi M, Sun M, Jeldres C, Shariat SF, Trinh QD, Briganti A, et al. Distribution of metastatic sites in renal cell carcinoma: a population-based analysis. *Ann Oncol* 2012;23(4):973–80. doi:10.1093/annonc/mdr362.
- [2] Vorder Bruegge CF, Hobbs JH, Wegner CR, Wintemute RW. Wintemute bilateral ovarian metastasis from renal adenocarcinoma: report of a case and discussion of pathogenesis. *Obstet Gynecol* 1957;9(2):198–205.
- [3] Stefani P, Selli C, Nicita G, Turini D. Angiographic aspects of renal cell carcinoma metastatic to the female genitalia. *Cardiovasc Interv Radiol* 1981;4(3):183–6. doi:10.1007/BF02552421.
- [4] Young RH, Hart WR. Renal cell carcinoma metastatic to the ovary: a report of three cases emphasizing possible confusion with ovarian clear cell adenocarcinoma. *Int J Gynecol Pathol* 1992;11(2):96–104. doi:10.1097/00004347-199204000-00003.
- [5] Liu FS, Ho ES, Lu F, Chang CY. Solitary metastasis of renal cell carcinoma to the ovaries: a case report. *Zhonghua Yi Xue Za Zhi (Taipei)* 1992;50(2):165–8.
- [6] Spencer JR, Eriksen B, Garnett JE. Metastatic renal tumor presenting as ovarian clear cell carcinoma. *Urology* 1993;41(6):582–4. doi:10.1016/0090-4295(93)90111-m.
- [7] Adachi Y, Sasagawa I, Nakada T, Saitoh M, Mitobe K, Ohta T, et al. Bilateral ovarian metastasis from left renal cell carcinoma. *Urol Int* 1994;52(3):169–71. doi:10.1159/000282600.
- [8] Fields S, Libson E, Lavie O, Beller U. Renal cell carcinoma metastatic to the ovary. Ultrasound and CT appearance. *Clin Imaging* 1996;20(1):42–4. doi:10.1016/0899-7071(94)00075-1.

- [9] Vara A, Madrigal B, Veiga M, Diaz A, Garcia J, Calvo J. Bilateral ovarian metastases from renal clear cell carcinoma. *Acta Oncol* 1998;37(4):379–80. doi:10.1080/028418698430610.
- [10] Shinojima T, Nakajima Y, Kiguchi H. [Renal cell carcinoma metastatic to the ovary: a case report]. *Nihon Hinyokika Gakkai Zasshi* 2001;92(7):694–7. doi:10.5980/jpnjurol1989.92.694.
- [11] Hammock L, Ghorab Z, Gomez-Fernandez CR. Metastatic renal cell carcinoma to the ovary: a case report and discussion of differential diagnoses. *Arch Pathol Lab Med* 2003;127(3):e123–6. doi:10.5858/2003-127-e123-MRCCTT.
- [12] Insabato L, De Rosa G, Franco R, D'Onofrio V, Di Vizio D. Ovarian metastasis from renal cell carcinoma: a report of three cases. *Int J Surg Pathol* 2003;11(4):309–12. doi:10.1177/106689690301100408.
- [13] Valappil SV, Toon PG, Anandaram PS. Ovarian metastasis from primary renal cell carcinoma: report of a case and review of literature. *Gynecol Oncol* 2004;94(3):846–9. doi:10.1016/j.ygyno.2004.06.035.
- [14] Kato S, Nishino Y, Ito Y, Takeuchi T, Ban Y, Uno H. [Renal cell carcinoma metastatic to the ovary]. *Hinyokika Kiyo* 2006;52(11):859–62.
- [15] Kato Y, Numata A, Wada N, Iwata T, Saga Y, Hashimoto H, et al. A case of metastatic renal cell carcinoma to the ovary. *Hinyokika Kiyo* 2006;52(12):923–7.
- [16] Stolnicu S, Borda A, Radulescu D, Puscasiu L, Berger N, Nogales FF. Metastasis from papillary renal cell carcinoma masquerading as primary ovarian clear cell tumor. *Pathol Res Pract* 2007;203(11):819–22. doi:10.1016/j.prp.2007.07.007.
- [17] Toquero L, Aboumarzouk OM, Abbasi Z. Renal cell carcinoma metastasis to the ovary: a case report. *Cases J* 2009;2:7472. doi:10.4076/1757-1626-2-7472.
- [18] Albrizio M, La Fianza A, Gorone MS. Bilateral metachronous ovarian metastases from clear cell renal carcinoma: a case report. *Cases J* 2009;2:7083. doi:10.1186/1757-1626-2-7083.
- [19] Decoene J, Ameys F, Lerut E, Oyen R, Van Poppel H, Joniau S. Renal cell carcinoma with synchronous metastasis to the calcaneus and metachronous metastases to the ovary and gallbladder. *Case Rep Med* 2011;2011:671645. doi:10.1155/2011/671645.
- [20] Bauerová L, Dunder P, Fischerová D, Pesl M, Zikan M, Burgetová A. Ovarian metastasis of clear cell renal cell carcinoma: a case report. *Can Urol Assoc J* 2014;8(3–4):E188–92. doi:10.5489/auaj.1456.
- [21] Bohara S, Dey B, Agarwal S, Bharti JN, Khurana N, Sachdeva P. Metastatic renal cell carcinoma masquerading as a primary ovarian mass in a post-operative case of meningioma and renal cell carcinoma. *Rare Tumors* 2015;7(3):5824. doi:10.4081/rt.2015.5824.
- [22] Kostrzewa M, Zyla M, Władziński J, Stetkiewicz T, Stachowiak G, Wilczyński JR. Metastases of renal clear cell carcinoma to ovary—case report and review of the literature. *Eur J Gynaecol Oncol* 2015;36(2):219–22.
- [23] Liang L, Huang H, Dadhania V, Zhang J, Zhang M, Liu J. Renal cell carcinoma metastatic to the ovary or fallopian tube: a clinicopathological study of 9 cases. *Hum Pathol* 2016;51:96–102. doi:10.1016/j.humpath.2015.12.017.
- [24] Uruc F, Akan S, Sahin A, Yildirim C, Urkmez A. Contralateral ovarian metastasis of Clear-cell renal carcinoma: a rare case report and review of the literature. *Case. Rep Surg* 2017;2017:9849205. doi:10.1155/2017/9849205.
- [25] Bhaskar V, Kumar M, Goel S, Sankhwar S. Papillary renal cell carcinoma with synchronous ovarian metastasis: a rare entity. *BMJ Case Rep* 2017;2017. doi:10.1136/bcr-2017-220764.
- [26] Porfyrus O, Alexandrou P, Masaoutis C, Nikolakakos F. Ovarian metastasis of renal cell carcinoma: clinical and pathological presentation of a case. *Turk J Urol* 2019;45(2):150–3. doi:10.5152/tud.2018.96237.
- [27] Karaosmanoglu AD, Onur MR, Salman MC, Usubutun A, Karcaaltincaba M, Ozmen MN, et al. Imaging in secondary tumors of the ovary. *Abdom Radiol (NY)* 2019;44(4):1493–505. doi:10.1007/s00261-018-1809-4.
- [28] Fujii S, Mukuda N, Murakami A, Yunaga H, Kitao S, Miyoshi H, et al. CT and MR imaging findings of bilateral ovarian metastasis from renal cell carcinoma: a case report. *Acta Radiol Open* 2021;10(2):2058460121990293.
- [29] Snyder E, Tafti D, Zhao JM, Walker K, Schwope RB. Bilateral ovarian metastasis of clear-cell renal cell carcinoma: A case report. *Clin Imaging* 2021;69:91–3. doi:10.1016/j.clinimag.2020.06.042.
- [30] Moore RG, Chung M, Granai CO, Gajewski W, Steinhoff MM. Incidence of metastasis to the ovaries from nongenital tract primary tumors. *Gynecol Oncol* 2004;93(1):87–91. doi:10.1016/j.ygyno.2003.12.039.
- [31] Levi F, Ferlay J, Galeone C, Lucchini F, Negri E, Boyle P, et al. The changing pattern of kidney cancer incidence and mortality in Europe. *BJU Int* 2008;101(8):949–58. doi:10.1111/j.1464-410X.2008.07451.x.