

# Descending Colon Perforation as a Complication of Inferior Mesenteric Artery Thrombosis—COVID-19–Associated Coagulopathy

Alamelu Alagappan<sup>1</sup> Biswajit Sahoo<sup>1</sup>

<sup>1</sup>Department of Radiodiagnosis, All India Institute of Medical Sciences, Bhubaneswar, Orissa, India

Indian J Radiol Imaging 2023;33:136–137.

Address for correspondence Alamelu Alagappan, Department of Radiodiagnosis, All India Institute of Medical Sciences, Bhubaneswar 751019, Orissa, India (e-mail: sornavallialagappan@gmail.com).

Biswajit Sahoo, MD, Department of Radiodiagnosis, All India Institute of Medical Sciences, Bhubaneswar 751019, Orissa, India (e-mail: Radiol\_biswajit@aiimsbhubaneswar.edu.in).

We present a 50-year-old female patient with acute onset fever, shortness of breath, and abdominal distension. Saturation at admission was 82%. Clinical examination revealed abdominal distension, guarding, and rigidity. Patient responded to oxygen therapy with a face mask. Coronavirus disease 2019 (COVID-19) rapid antigen test and reverse transcription polymerase chain reaction done subsequently were positive. Biochemical investigations showed leukocytosis (total leucocyte count: 24200/mm<sup>3</sup>). Erythrocyte sedimentation rate, C-reactive protein, ferritin, interleukin-6, and lactate dehydrogenase levels were elevated (39 mm/h, 107.6 mg/dL, 593.2 ng/mL, 19 pg/mL and 444 U/L, respectively). D-Dimer level (8.6 µg) was elevated.

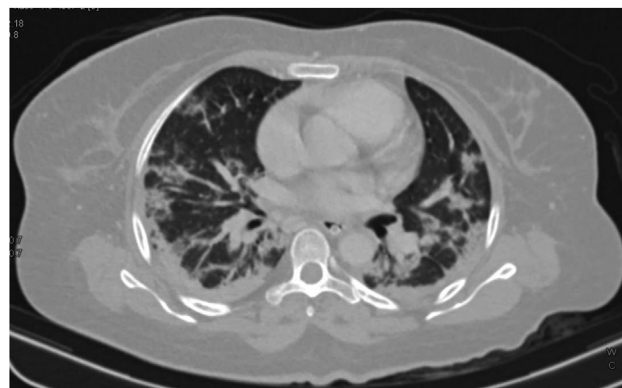
Contrast-enhanced computed tomography (CT) scan showed peripheral ground-glass opacities in both the lungs consistent with COVID-19 (CT severity score of 19/25) (→Fig. 1). Abdominal images showed hypoenhancing wall of descending colon with collection with air foci surrounding the bowel in left iliac fossa. Mural defect was noted in the descending colon with extravasation of rectal contrast from the defect into the collection (→Fig. 2). There was partial eccentric thrombosis of the infrarenal aorta extending into the inferior mesenteric artery (IMA), causing occlusion of IMA (→Fig. 3).

Patient was treated according to our hospital COVID-19 protocol. Emergency explorative laparotomy was performed that revealed descending colon gangrene with necrosis of 60% of the bowel circumference. Patient underwent resection of around 15 cm of necrotic large bowel and loop colostomy. Laboratory workup done to look for hypercoagulable status was negative. Patient's recovery was uneventful.

COVID-19 is caused by the severe acute respiratory syndrome coronavirus 2 (SARS-CoV2). Recent studies have shown

several coagulation abnormalities in patients with COVID-19.<sup>1</sup> Pulmonary embolism is the most frequently diagnosed thromboembolic complication. Others include deep vein thrombosis, ischemic stroke, and systemic arterial/venous embolism.<sup>2</sup> Acute mesenteric artery thrombosis is increasingly recognized as a cause of acute mesenteric ischemia. In a study published on January 2021, 13 cases of acute mesenteric ischemia in COVID-19 were reported, the most common etiology being superior mesenteric artery thrombosis.<sup>3,4</sup>

But our patient had IMA thrombosis. Since extensive hypercoagulable workup was negative, thrombotic complications of SARS-CoV2 were attributed as the potential cause. Gupta et al, in their study, said that thrombus formation is regulated by hypoxia-inducible transcription factors.<sup>5</sup> Our patient had shortness of breath and low saturation. This

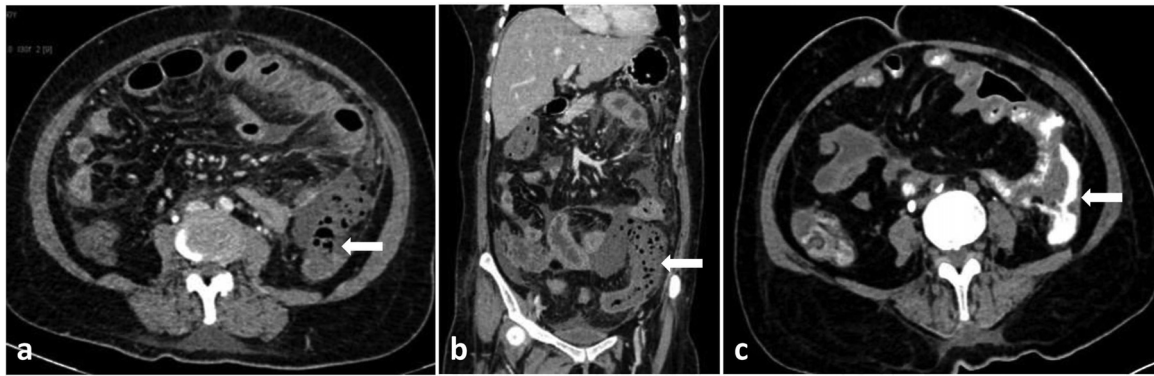


**Fig. 1** Axial lung window of the chest showing coronavirus disease 2019 changes in bilateral lungs.

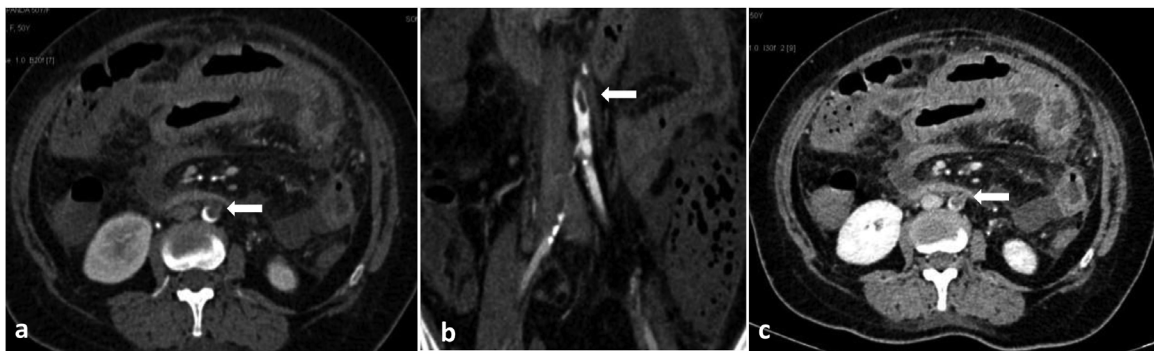
article published online  
November 24, 2022

DOI <https://doi.org/10.1055/s-0042-1758199>.  
ISSN 0971-3026.

© 2022. Indian Radiological Association. All rights reserved.  
This is an open access article published by Thieme under the terms of the Creative Commons Attribution-NonDerivative-NonCommercial-License, permitting copying and reproduction so long as the original work is given appropriate credit. Contents may not be used for commercial purposes, or adapted, remixed, transformed or built upon. (<https://creativecommons.org/licenses/by-nc-nd/4.0/>)  
Thieme Medical and Scientific Publishers Pvt. Ltd., A-12, 2nd Floor, Sector 2, Noida-201301 UP, India



**Fig. 2** Axial (a) and coronal (b) venous phase images showing mural defect (white arrow) in descending colon with adjacent air containing collection. There is extravasation of rectal contrast from the defect (c).



**Fig. 3** Contrast-enhanced computed tomography: Axial (a) and coronal (b) arterial phase images showing thrombus in descending aorta extending into the inferior mesenteric artery (white arrow). Axial venous (c) phase image showing the same.

probable state of prolonged hypoxia may represent the stimulus for hypercoagulation in our patient.

Sun et al described that D-dimer could be a potential biomarker for diagnosing mesenteric ischemia.<sup>6</sup> Markedly elevated D-dimer levels are also associated with poor prognosis in COVID-19 patients.<sup>7</sup> Our patient presented with elevated D-dimer level, with a maximum of threefold rise noted in subsequent days.

In an extensive literature search, till now, only one case of IMA thrombosis has been reported,<sup>8</sup> where it was associated with sigmoid colon perforation. In our case, descending colon perforation was the complication. For these cases, early diagnosis and timely treatment are indispensable in reducing patients' morbidity and mortality.

#### Informed Consent

Informed consent has been obtained from the patient and will be produced to the editor whenever required.

#### Note

Since this article is a case report, ethical committee clearance is not required.

#### Authors' Contributions

A.A. contributed to data collection, manuscript drafting, and editing. B.S. was involved in protocol management, reporting, manuscript proofing, and review.

#### Conflict of Interest

None declared.

#### Reference

- COVID-19 and coagulopathy: frequently asked questions. Accessed August 8, 2022, at: <https://www.hematology.org/covid-19/covid-19-and-coagulopathy>
- Klok FA, Kruip MJHA, van der Meer NJM, et al. Incidence of thrombotic complications in critically ill ICU patients with COVID-19. *Thromb Res* 2020;191:145–147
- Singh B, Kaur P. COVID-19 and acute mesenteric ischemia: a review of literature. *Hematol Transfus Cell Ther* 2021;43(01):112–116
- Cheruiyot I, Kipkorir V, Ngure B, Misiani M, Munguti J, Ogeng'o J. Arterial thrombosis in coronavirus disease 2019 patients: a rapid systematic review. *Ann Vasc Surg* 2021;70:273–281
- Gupta N, Zhao YY, Evans CE. The stimulation of thrombosis by hypoxia. *Thromb Res* 2019;181:77–83
- Sun DL, Li SM, Cen YY, et al. Accuracy of using serum D-dimer for diagnosis of acute intestinal ischemia: a meta-analysis. *Medicine (Baltimore)* 2017;96(13):e6380
- Tang N, Li D, Wang X, Sun Z. Abnormal coagulation parameters are associated with poor prognosis in patients with novel coronavirus pneumonia. *J Thromb Haemost* 2020;18(04):844–847
- Almeida A, Baixauli J, Cienfuegos JA, Valentí V, Rotellar F. Concomitant aortic, inferior mesenteric artery thrombosis and sigmoid colon perforation in severe COVID-19 disease. *Cir Esp* 2022;100(11):736–738