

Pediatrics

Do Not Judge a Kidney by Its Pelvis: A Rare Case of an Unobstructed Dilated Renal Pelvis

Aaron D. Martin, Craig A. Peters*

Children's National Health System and The George Washington University, Washington, DC

ARTICLE INFO

Article history:

Received 23 December 2013

Accepted 14 January 2014

Keywords:

Kidney pelvis

Ureteral obstruction

Infant

Congenital abnormalities

Hydronephrosis

Ultrasonography

ABSTRACT

We present a rare case of an unobstructed dilated renal pelvis in a newborn female. Prenatal imaging documented a large abdominal cyst in a stable fetus. Postnatal imaging confirmed persistence of this large cyst but with an unclear etiology. The child was taken to surgery by the pediatric surgeons with concern for a possible harmful nonurologic diagnosis. Intraoperative findings were that of a severely dilated renal pelvis; however, in the absence of an expected ureteropelvic junction obstruction. Reduction pyeloplasty without interference of the ureteropelvic junction proved successful.

© 2014 The Authors. Published by Elsevier Inc. Open access under [CC BY-NC-ND license](https://creativecommons.org/licenses/by-nc-nd/4.0/).

Introduction

Large cystic abdominal masses in a newborn infant can be confusing to diagnose even with the current sophisticated imaging modalities and concerning for the physician and parents alike. Although typically the diagnosis is clear before surgery, the surgeon must be prepared for occasional surprises and consult with appropriate specialists as needed. We present one example of this occurrence and its uncharacteristic features.

Case presentation

A term newborn female was transferred immediately after birth from an outside facility under care of general surgery because of prenatal imaging documenting a large abdominal cyst (>7 cm in largest dimension). The child was stable clinically with good urine output and stooling. She had no issues with feeding or respiratory effort in the first days of life. Physical examination revealed an easily palpable abdominal mass on the left side from the costal margin to the pelvic brim that did not cross midline. A

complete abdominal ultrasound was performed on day of life 2 (Fig. 1), and the findings were interpreted as a cystic mass with no solid areas or septations but with a slightly thickened wall. It was medial to the left kidney but without identifiable communication to the kidney or bladder and measuring 10.4 × 4.1 cm. The left kidney had moderate hydronephrosis without hydroureter. The differential diagnoses were a gastrointestinal duplication cyst, an ovarian cyst, or a mesenteric lymphatic malformation. With these considerations, the general surgery team took the child to the operating room for exploration. The cyst was easily identified and discovered to be intimately associated with a healthy appearing left kidney (Figs. 2 and 3). The urology team was called for consultation, and the cyst was confirmed to be a severely dilated left renal pelvis. The renal pelvis was opened revealing mild calyceal dilation, and the ureter was easily cannulated with a 5F catheter with no evidence of intrinsic obstruction or presence of obstructive crossing vessels. Owing to lack of evidence of obstruction, a renal pelvis reduction was performed without intervention at the ureteropelvic junction (UPJ) and no stenting or renal drainage. At 1 month postoperatively, a renal ultrasound revealed mild left hydronephrosis improved from the preoperative study without evidence of a dilated renal pelvis. Voiding cysto-urethrogram did not show vesicoureteral reflux. A MAG-3 renal scan showed no evidence of obstruction (T1/2 of 4 minutes; 93% emptying) with 51.4% differential uptake of the left kidney.

* Corresponding author. Tel.: +202-476-4859; Fax: +202-476-1280.

E-mail address: crpeters@childrensnational.org (C.A. Peters).

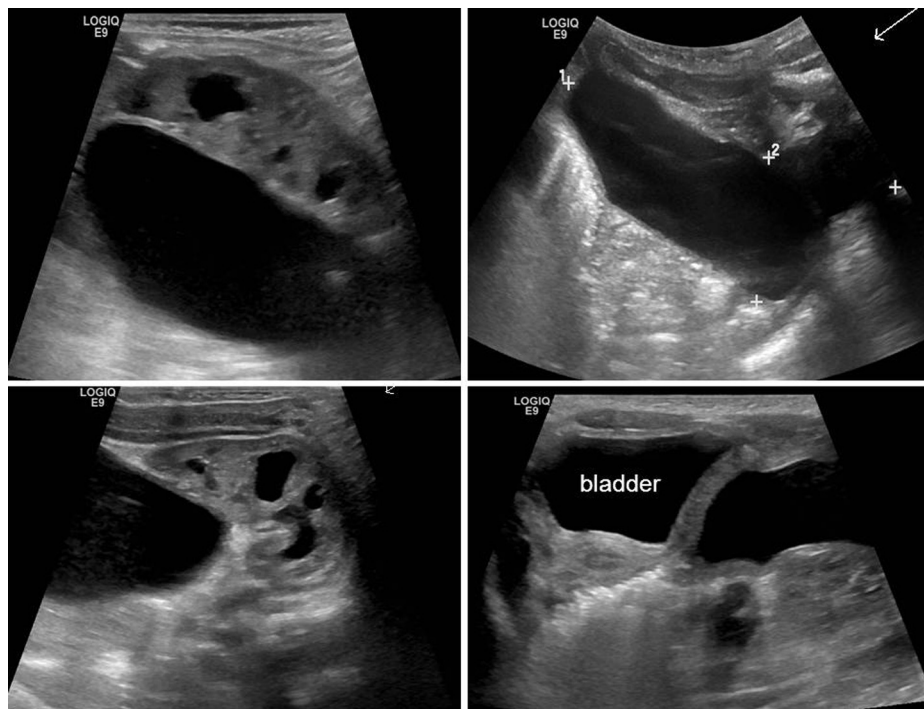


Figure 1. Selected images from abdominal ultrasound showing the cyst and its proximity to the left kidney (left side) and bladder (bottom right).

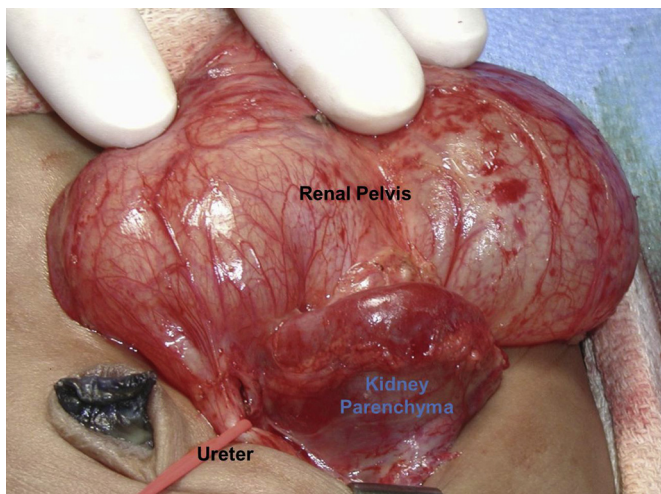


Figure 2. Severely dilated renal pelvis with left renal parenchyma preserved.

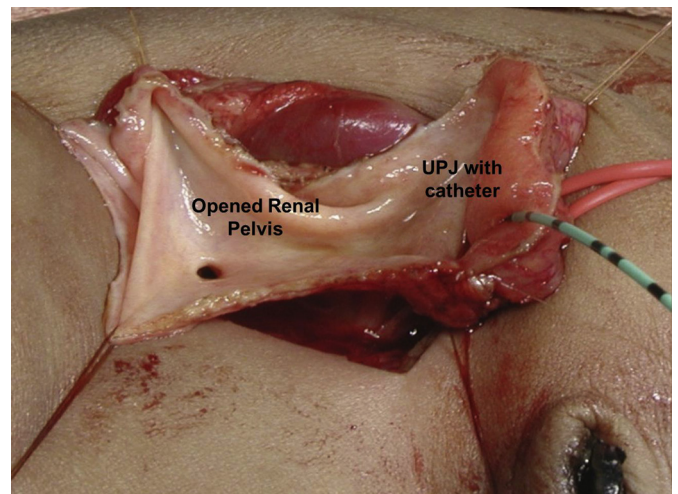


Figure 3. Renal pelvis opened with catheter in ureter and view of mildly dilated calyx.

Discussion

An extrarenal collecting system presenting as a cystic abdominal mass has been reported although infrequently in the published literature.^{1–3} All previous reports have assumed or demonstrated UPJ obstruction in association with the dilated renal pelvis as would seem logical. These patients underwent a pyeloplasty with reconstruction of the UPJ. This case is unique in that no UPJ obstruction was observed or demonstrated during or after surgery without reconstruction of the UPJ. The etiology for this massively dilated extrarenal pelvis is, therefore, unclear but would suggest a developmental malformation. The child will continue to have monitoring with periodic renal ultrasound to assure stability of this left system.

Conclusion

Typically, dilatation of the collecting system is found to be in association with obstruction; however, this case demonstrates an exception to the rule. An extrarenal pelvis should be in a surgeon's differential for abdominal masses when imaging is not conclusive in the contrary.

References

1. Pontes JE, Rattner WH. Extrarenal collecting system presenting as an abdominal mass in a child. *J Urol.* 1973;110:585–587.
2. Johnson 3rd JF. Ureteropelvic junction obstruction associated with extrarenal pelvis: a potential cause of cystic abdominal mass anterior to a normal-appearing kidney in the newborn. *J Clin Ultrasound.* 1999;27:474–477.
3. Felman AH, Walker RD. Extrarenal pelvic hydronephrosis: report of five cases. *Rev Interam Radiol.* 1977;2:101–104.