



Since January 2020 Elsevier has created a COVID-19 resource centre with free information in English and Mandarin on the novel coronavirus COVID-19. The COVID-19 resource centre is hosted on Elsevier Connect, the company's public news and information website.

Elsevier hereby grants permission to make all its COVID-19-related research that is available on the COVID-19 resource centre - including this research content - immediately available in PubMed Central and other publicly funded repositories, such as the WHO COVID database with rights for unrestricted research re-use and analyses in any form or by any means with acknowledgement of the original source. These permissions are granted for free by Elsevier for as long as the COVID-19 resource centre remains active.

COVID-19 in a patient with chronic lymphocytic leukaemia

Xiang-Hong Jin*, Kenneth I Zheng*, Ke-Hua Pan, Yu-Peng Xie, Ming-Hua Zheng



Since the outbreak of coronavirus disease 2019 (COVID-19) first began in Wuhan, China, in December, 2019, the viral epidemic has quickly engulfed China. Here we describe a case of a patient with chronic lymphocytic leukaemia with COVID-19.

On Feb 16, 2020, a 39-year-old man with a medical history of non-Hodgkin lymphoma and chronic lymphocytic leukaemia attended our clinic in Wenzhou, China, after 4 days of fever, sore throat, productive cough, and dyspnoea. Previous history of treatment for non-Hodgkin lymphoma consisted of six courses of 21 days of R-CHOP chemotherapy in 2007. His previous treatment for chronic lymphocytic leukaemia started in November, 2018, with oral chlorambucil (10 mg/m²) per day. He became non-compliant in December, 2019, stating that improvements derived from treatment did not outweigh the cost and follow-up time required. At admission (Feb 16, 2020), the most relevant clinical findings included body temperature of 38.5°C, white blood cell counts of 91.85×10⁹ cells per L, lymphocyte percentage of 96%, haemoglobin of 85 g/L, platelet count of 79×10⁹ cells per L, high-sensitive C-reactive protein 21.5 mg/L, β₂-microglobulin of 4.76 µg/mL, and lactic acid dehydrogenase of 429 U/L. Plasma concentrations of IgG, IgM, and IgA were markedly reduced (3.18 g/L for IgG, 0.45 g/L for IgM, and <0.17 g/L for IgA). The concentration of plasma brain natriuretic peptide, estimated glomerular filtration rate, concentration of liver enzymes, and echocardiogram results were unremarkable. Bone marrow aspiration was not done at the time of assessment. Other haematological investigations included a Binet stage C, Rai stage IV, and European Cooperative Oncology Group performance score of 1. A CT scan of the chest showed bilateral ground-glass opacities and a small amount of fluid in the left pleural cavity (figure). The attending physician suspected COVID-19 and ordered testing. The real-time RT-PCR assay result was positive and the patient was immediately transferred to the isolation ward for management. He started treatment with a reduced dose of oral chlorambucil (2 mg) twice per day to treat his frail condition due to his chronic lymphocytic leukaemia. He also received nebulised α-interferon (5 000 000 international units) twice per day, intravenous human immunoglobulin (20 g) once per day, and intravenous methylprednisolone (40 mg) every 12 h for the treatment of COVID-19, as recommended by the Chinese COVID-19 Interim Management Guidance (sixth edition). During the first 9 days, the patient had relapsing fever with temperature ranging from 36.6°C to 39.6°C, PaO₂/FiO₂ less than 300 mm Hg, and with a Sequential Organ Failure Assessment score of 4. The patient was given non-invasive ventilation therapy until dyspnoea subsided on day 8. The treatment plan

changed to low-dose intravenous methylprednisolone (40 mg) every 12 h with oral chlorambucil (2 mg) twice per day for the next 4 days. A follow-up chest CT on March 1, 2020 (figure), showed a substantial improvement with a marked reduction of pulmonary exudative lesions. The patient's temperature also returned to normal with improvement in symptoms. However, repeated real-time RT-PCR test remained positive for COVID-19 infection. He was scheduled for an additional 7 days of observation until all clinical criteria for hospital discharge were met (more than 3 days of normal body temperature, resolved respiratory symptoms, substantially improved acute exudative lesions on chest CT, and two consecutive negative COVID-19 infection tests), at which time he was transferred to the inpatient haematology department for further management.

After the first positive test for COVID-19 infection, the attending physician must, by protocol, verify the source and possible transmission of COVID-19. Initially, the patient denied any recent travel to Wuhan or having had any close contact with others who had visited endemic outbreak areas. However, after being informed of the serious risk of disease transmission to others, he provided a detailed history of his travel activities before admission. He admitted having travelled to Wuhan between Jan 12–18, 2020. He travelled back to Wenzhou, which became the second epicenter of the outbreak in

Lancet Haematol 2020;
7: e351–52

*These authors contributed equally

Department of Hematology (X-H Jin MD), Department of Hepatology (K I Zheng MD, M-H Zheng MD), Department of Radiology (K-H Pan MD), and Department of Respiratory and Critical Care Medicine (Y-P Xie MD), The First Affiliated Hospital of Wenzhou Medical University, Wenzhou, China

Correspondence to: Dr Ming-Hua Zheng, Department of Hepatology, The First Affiliated Hospital of Wenzhou Medical University, Wenzhou 325000, China zhengmh@wmu.edu.cn

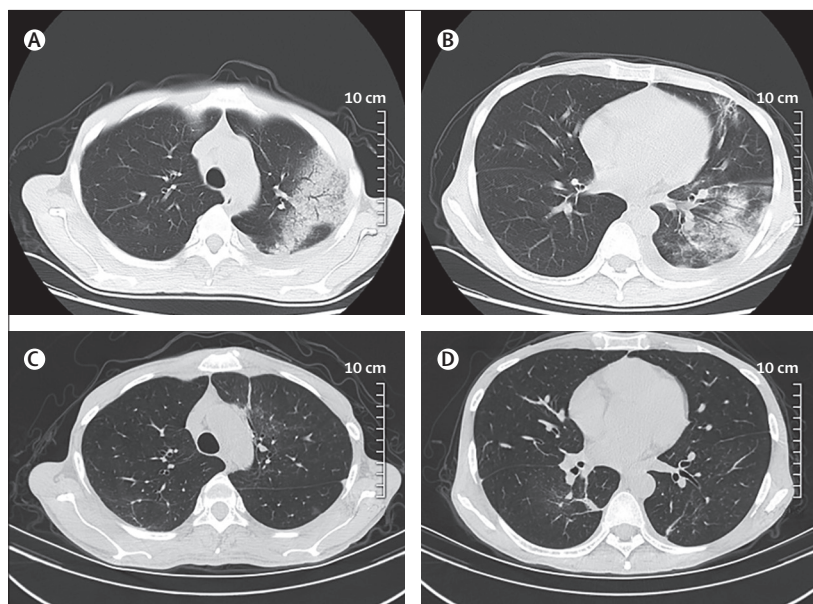


Figure: CT scan of the chest on day of admission and 2 weeks later. Upper lobe (A) and lower lobe (B), showing bilateral ground-glass opacities, mass-like high-density shadow in left lung with partial consolidation, patchy high-density shadow in the right lung, and a small amount of fluid in the left pleural cavity; upper lobe (C) and lower lobe (D), showing a substantial improvement with a marked reduction of pulmonary exudative lesions.

early February. Those who travelled from Wuhan were advised by local government to conduct self-isolation at home for 14 days. He stated he had been in home isolation after returning from Wuhan, and subsequently developed fever and acute respiratory symptoms by Feb 12, 2020. The patient also explained he assumed he had a recurrent flu, common given his frail condition, rather than COVID-19.

Without the complete travel history, COVID-19 infection was not initially suspected, because his whole blood cell and lymphocyte counts were high because of his chronic lymphocytic leukaemia masking a potential infection. However, the attending physician noticed that although symptoms could be the result of a recurrent infection, his chest CT scan resembled that of a patient with COVID-19. This case is interesting because the estimated incubation period for COVID-19 infection is thought to be no more than 14 days, according to the Chinese interim guidance. However, a retrospective review of the patient's condition suggested an incubation period of about 25 days.

In conclusion, clinical and biochemical data of COVID-19 might be partly masked by coexisting chronic lymphocytic leukaemia; better diagnostic strategies

(ie, superior CT differential techniques such as radiomics) could be used for diagnosis; individuals with compromised immune status might be subjected to a longer incubation period (although the underlying mechanisms are not known); and it remains uncertain whether the combination of chemotherapy, corticosteroids, α -interferon, and immunoglobulins could work synergistically in patients with chronic lymphocytic leukaemia and COVID-19.

Contributors

Written consent for publication was obtained from the patient. M-HZ, J-XH, KIZ, H-KH, and Y-PX were involved in data collection, analysis, and interpretation. J-XH and KIZ wrote the manuscript. M-HZ critically revised the manuscript.

Declaration of interests

We declare no competing interests.

Acknowledgments

The authors thank Prof Christopher D Byrne (Faculty of Medicine, University of Southampton and Southampton NIHR Biomedical Research Centre, University Hospital Southampton, UK) and Prof Giovanni Targher (Department of Medicine, Azienda Ospedaliera Universitaria Integrata Verona, Verona, Italy) for proof reading and comments on the manuscript.

© 2020 Elsevier Ltd. All rights reserved.