

Association of Appendicitis, *Helicobacter Pylori* Positive Gastritis and Thrombotic Thrombocytopenic Purpura in an Adolescent

Authors' Contribution:
Study Design A
Data Collection B
Statistical Analysis C
Data Interpretation D
Manuscript Preparation E
Literature Search F
Funds Collection G

ABCDEF 1 **Adela Arapović**
ABDF 1 **Sandra Prgomet**
ABDEF 1,2 **Marijan Saraga**
ABCD 1 **Tanja Kovačević**
ABDE 3 **Zoltán Prohászka**
ABCD 1 **Ranka Despot**
ABCD 1 **Eugenija Marušić**
ABCDE 4 **Josipa Radić**

1 Department of Pediatric, University Hospital in Split, Split, Croatia
2 School of Medicine, University of Split, Split, Croatia
3 3rd Department of Medicine, Research Laboratory, and HAS-SU Research Group of Immunology and Hematology, Semmelweis University, Budapest, Hungary
4 Department of Nephrology, University Hospital in Split, Split, Croatia

Corresponding Author: Marijan Saraga, e-mail: msaraga@kbsplit.hr
Conflict of interest: None declared

Patient: Male, 16
Final Diagnosis: Thrombotic thrombocytopenic purpura
Symptoms: Anemia
Medication: —
Clinical Procedure: —
Specialty: Pediatrics and Neonatology





Objective: Unusual clinical course
Background: Thrombotic thrombocytopenic purpura (TTP) in children is a rare life-threatening syndrome, characterized by microangiopathic hemolytic anemia, thrombocytopenia with renal dysfunction, neurologic symptoms, and fever. TTP is usually caused by deficient activity of von Willebrand factor cleaving protease (ADAMTS13), due to either gene mutations or acquired via anti-ADAMTS13 autoantibodies. It can be triggered by bone marrow or solid organ transplantation, cardiothoracic-, abdominal-, and orthopedic surgeries, infections including very rarely *Helicobacter pylori* infection.

Case Report: Here we report a case of a 16-year-old male with TTP, who presented with thrombocytopenia before an appendectomy. Seven days after surgery, our patient started to vomit, developed melena, and was admitted to our pediatric intensive care unit (PICU) with clinical presentation of shock. Gastroscopy revealed *H. pylori* positive hemorrhagic gastritis. The patient was treated by erythrocyte transfusions, fresh frozen plasma, human albumin, glucose-electrolyte solutions, vitamin K, platelet transfusion before implantation of central venous catheter, and antibiotics. After 36 hours, we started plasma exchange (PEX). Blood tests showed deficiency of ADAMTS13. Due to the presence of anti-ADAMTS13 autoantibodies, rituximab was administered. Due to generalized tonic-clonic seizures, he was artificially ventilated. Brain MR angiography showed small ischemic cerebro-vascular insult in the arteria cerebri media region. Despite immunosuppressive therapy and PEX, the patient did not improve completely until the *H. pylori* infection was eradicated. After which, he recovered completely.

Conclusions: We present a rare case of TTP accompanied with appendicitis and gastritis caused by *H. pylori*, where TTP improvement was dependent on *H. pylori* infection eradication.

MeSH Keywords: Adolescent • *Helicobacter Pylori* • Purpura, Thrombotic Thrombocytopenic

Full-text PDF: <https://www.amjcaserep.com/abstract/index/idArt/913129>

 1070   1  13



Background

Thrombotic thrombocytopenic purpura (TTP) is a rare but a life-threatening clinical syndrome in children, characterized by microangiopathic hemolytic anemia, thrombocytopenia with renal dysfunction, neurologic symptoms, and fever. TTP is usually caused by deficient activity of von Willebrand factor cleaving protease (ADAMTS13), due to either gene mutations or acquired via anti-ADAMTS13 autoantibodies. Therefore, TTP is characterized by increased platelet aggregation throughout the body and thrombotic microangiopathy [1–6]. It can be triggered by bone marrow or solid organ transplantation, cardiothoracic, abdominal and orthopedic surgeries, and infections including very rarely *Helicobacter pylori* infection [7–11]. The treatment and therapeutic approach is still being developed: plasma exchange, corticosteroids, rituximab, cyclosporine A, bortezomib, Na-acetylcysteine, eculizumab, cyclophosphamide, vincristine, caplacizumab, and splenectomy [12,13]. Here we describe a case report of a 16-year-old male patient presenting to the Emergency Medicine Department with signs of acute appendicitis, thrombocytopenia, and *H. pylori* positive hemorrhagic gastritis infection.

Case Report

A 16-year old male presented at the Emergency Medicine Department with progressive pain in the lower right abdomen, fever, nausea, and vomiting. After clinical examination, appendicitis was suspected, and the patient underwent urgent appendectomy on the day of admission; after 7 days he was discharged. Subsequent surgical exploration and histological examination revealed a final diagnosis of phlegmonous appendicitis. A slight increase in white blood cell count to $10.9 \times 10^9/L$ and decrease in platelet count ($10^6 \times 10^9/L$) was observed before surgery. On postoperative day 8, the patient was admitted to the Pediatric Intensive Care Unit (PICU) because of clinical suspicion of hemorrhagic shock. After admission to the PICU, the patient was afebrile and his blood pressure was 95/60 mm Hg, although he was somnolent, pale and tachycardic, without evidence of jaundice or petechiae. Laboratory examination revealed anemia with a hemoglobin level of 41 g/L, erythrocyte count of $1.5 \times 10^{12}/L$, hematocrit of 0.128, and platelet count of $9 \times 10^9/L$. The peripheral blood smear revealed schistocytes. Serum lactate dehydrogenase was elevated 2101 U/L, urea 8.4 mmol/L, creatinine 75 $\mu\text{mol}/L$, total bilirubin 59 $\mu\text{mol}/L$, aspartate aminotransferase 56 U/L, total serum protein level 56 g/L, albumin 34 g/L, and haptoglobin was undetectable. Direct and indirect Coombs test were negative. Urine-analysis revealed mild proteinuria and erythrocyturia. Computed tomography scan of abdomen demonstrated no blood in the abdominal cavity or retroperitoneal space. Gastroscopy revealed hemorrhagic gastritis with positive *H. pylori*. He was treated

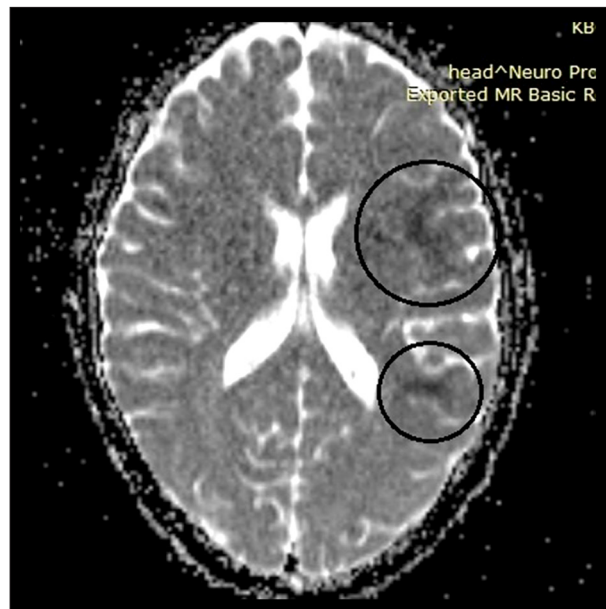


Figure 1. Patient's brain magnetic resonance scan on the second day after his admission in pediatric intensive care unit showed areas of restricted diffusion in the area of arteria cerebri media (encircled).

by erythrocyte transfusion, human albumin, plasma exchange (PEX), infusions of fresh frozen plasma (FFP), vitamin K, methylprednisolone, esomeprazole, folic acid, and parenteral antibiotics (meropenem and vancomycin). On the first day of his admission into the PICU, he received 1 platelet transfusion due to deep thrombocytopenia and the need for central venous catheter placement. According to the clinical presentation and characteristic laboratory findings in our patient, we suspected that he might have thrombotic microangiopathy. Therefore, we started with therapeutic PEX on postoperative day 10, or day 2 of his admission to the PICU. Before that, we took the samples for ADAMTS13 metalloprotease. Six hours after PEX was started, the patient became confused and experienced generalized tonic-clonic seizures. The patient was intubated and temporarily mechanically ventilated. Brain MRI showed small cerebro-vascular insult in the arteria cerebri media region (Figure 1) but he recovered. On postictal day 4, his brain MRI was normal. The patient underwent daily PEX, using 1.5 estimated plasma volumes for 14 consecutive days. After 10 doses of PEX, his platelet count was $24 \times 10^9/L$. In the meantime, laboratory workup for TTP showed deficiency (0%) of ADAMTS13 metalloprotease, with the presence of anti-ADAMTS13 inhibitory autoantibodies. As his thrombocytopenia did not improve, despite PEX, we continued PEX for another 4 days, and we started with rituximab on day 14 after admission to the PICU. Rituximab was administered weekly, for 4 weeks. In another 5-day period, he received 3 PEXs. The last PEX he received was on day 20 after his admission to the PICU. After that period, he received 16 infusions of FFP during the

period of 20 days. After rituximab treatment, his CD20 positive B lymphocyte count was zero in his peripheral blood. His platelet count normalized to $230 \times 10^9/L$ by day 17 after readmission to the hospital but 2 weeks after his platelet count decreased again to $95 \times 10^9/L$. Then *H. pylori* treatment was initiated, with included amoxicillin, metronidazole, and esomeprazole for 8 days. After the eradication of his *H. pylori* infection, his platelet counts normalized and the patient showed complete remission. Our patient received a total of 18 PEXs, 4 doses of rituximab, 16 infusions of FFP, treatment for *H. pylori* infection, and was sent home after 60 days in the hospital in very good clinical condition. During this whole period, he received corticosteroids. During his 1 year of follow-up, there was no TTP recurrence.

Discussion

Immune mediated ADAMTS13 deficient TTP is a very rare condition in childhood and it has to be differentiated from other forms of thrombotic microangiopathy because of specific therapeutic approaches [12,13]. Aside from the demonstration of ADAMTS13 deficiency to support the diagnosis of TTP, it is essential to fully characterize the molecular etiology, including inhibitory anti-ADAMTS13 autoantibodies, to treat the disease effectively. In our case we could not achieve long lasting complete remission before we eradicated the gastritis caused by *H. pylori* infection [7,11]. It is generally recognized that TTP is hard to treat if active infection is ongoing, and our case demonstrated that besides common locations and pathogens, rarely occurring or exceptional microbes should also be considered for treatment. Although our patient was

diagnosed in time and received appropriate treatment, he was resistant to medical therapy with delayed improvement and early exacerbation. Unusually severe and complicated disease courses should be considered as warning signs for underlying TTP precipitating factors, including infections. Our patient underwent complete resolution of his TTP following *H. pylori* eradication.

Conclusions

We conclude that acquired TTP may be triggered by various of factors, including surgery accompanied with different infections (acute appendicitis and *H. pylori* positive hemorrhagic gastritis) in the same patient and that treating the underlying triggering infection may play a significant role in improving TTP outcomes in some patients, especially when the disease is not responding to conventional medical therapy. To our knowledge, this is the first case report of TTP in an adolescent, who had 2 possible triggers for TTP and who partly improved after standard therapy, but completely improved after eradication of *H. pylori* infection.

Name of Department and Institution where work was done:

Department of Pediatric, University Hospital in Split, Split, Croatia

Conflict of interest

None.

References:

1. Arapović A, Prgomet S, Kovačević T et al: Acute appendicitis and thrombocytopenia-first signs of thrombotic thrombocytopenic purpura (Case report). *Pediatr Nephrol*, 2016; 31: 1876
2. Moschowitz E: Hyaline thrombosis of the terminal arterioles and capillaries: A hitherto undescribed disease. *Proc NY Pathol Soc*, 1924; 24: 21–24
3. Moake JL, Rudy CK, Troll JH et al: Unusually large plasma factor VIII: von Willebrand factor multimers in chronic relapsing thrombotic thrombocytopenic purpura. *N Engl J Med*, 1982; 307: 1432–35
4. Furlan M, Robles R, Galbusera M et al: von Willebrand factor-cleaving protease in thrombotic thrombocytopenic purpura and the hemolytic-uremic syndrome. *N Engl J Med*, 1998; 339: 1578–84
5. Tsai HM, Lian EC: Antibodies to von Willebrand factor-cleaving protease in acute thrombotic thrombocytopenic purpura. *N Engl J Med*, 1998; 339: 1585–94
6. Levy GG, Nichols WC, Lian EC et al: Mutations in a member of the ADAMTS gene family cause thrombotic thrombocytopenic purpura. *Nature*, 2001; 413: 488–94
7. Taktsuka H, Wakae T, Toda A et al: Association of *Helicobacter pylori* with thrombotic thrombocytopenic purpura and hemolytic uremic syndrome after bone marrow transplantation. *Clin Transplant*, 2004; 18(5): 547–51
8. Robertson MD, Zumberg M: Post appendectomy thrombotic thrombocytopenic purpura: A case report and review of the literature. *Am J Hematol*, 2007; 82(3): 224–28
9. Eskazan AE, Buyuktas D, Soysal T: Postoperative thrombotic thrombocytopenic purpura. *Surg Today*, 2015; 45(1): 8–16
10. Schiller O, Ash S, Schonfeld T et al: Postoperative thrombotic thrombocytopenic purpura in an infant: Case report and literature review. *J Pediatr Surg*, 2011; 46(4): 764–66
11. Franchini M: Thrombotic thrombocytopenic purpura: Proposal of a new pathogenic mechanism involving *Helicobacter pylori* infection. *Med Hypotheses*, 2005; 65: 1128–31
12. Sayani FA, Abrams CS: How I treat refractory thrombotic thrombocytopenic purpura. *Blood*, 2015; 3830–37
13. Peyvandi F, Scully M, Kremer Hovinga JA: Caplacizumab for acquired thrombotic thrombocytopenic purpura. *N Engl J Med*, 2016; 374: 511–22