



## ■ ONCOLOGY

# How 3D patient-specific instruments improve accuracy of pelvic bone tumour resection in a cadaveric study

**A. Sallent,  
M. Vicente,  
M. M. Reverté,  
A. Lopez,  
A. Rodríguez-Baeza,  
M. Pérez-Domínguez,  
R. Velez**

*Universitat Autònoma de Barcelona,  
Barcelona, Spain*

- A. Sallent, MD, Orthopaedic Surgeon, Department of Orthopaedic Surgery, Hospital Vall d'Hebron, Barcelona, Spain and Vall d'Hebron Research Institute (VHIR), Universitat Autònoma de Barcelona, Barcelona, Spain.
- M. Vicente, MD, Orthopaedic Surgeon,
- M. M. Reverté, MD, PhD, Orthopaedic Surgeon,
- M. Pérez-Domínguez, MD, PhD, Orthopaedic Surgeon, Department of Orthopaedic Surgery, Hospital Vall d'Hebron, Barcelona, Spain.
- A. Lopez, Researcher, Musculoskeletal Tissue Engineering Department, Vall d'Hebron Research Institute (VHIR), Barcelona, Spain.
- A. Rodríguez-Baeza, MD, PhD, Professor of Anatomy, Department of Morphological Science, Universitat Autònoma de Barcelona, Barcelona, Spain.
- R. Velez, MD, PhD, Orthopaedic Surgeon, Department of Orthopaedic Surgery, Hospital Vall d'Hebron, Barcelona, Spain and Vall d'Hebron Research Institute (VHIR), Universitat Autònoma de Barcelona, Spain.

Correspondence should be sent to A. Sallent;  
email: andreasallent@gmail.com

doi: 10.1302/2046-3758.610.  
BJR-2017-0094.R1

*Bone Joint Res* 2017;6:577–583.  
Received: 5 April 2017;  
Accepted: 31 July 2017

## Objectives

To assess the accuracy of patient-specific instruments (PSIs) *versus* standard manual technique and the precision of computer-assisted planning and PSI-guided osteotomies in pelvic tumour resection.

## Methods

CT scans were obtained from five female cadaveric pelvises. Five osteotomies were designed using Mimics software: sacroiliac, biplanar supra-acetabular, two parallel iliopubic and ischial. For cases of the left hemipelvis, PSIs were designed to guide standard oscillating saw osteotomies and later manufactured using 3D printing. Osteotomies were performed using the standard manual technique in cases of the right hemipelvis. Post-resection CT scans were quantitatively analysed. Student's *t*-test and Mann–Whitney U test were used.

## Results

Compared with the manual technique, PSI-guided osteotomies improved accuracy by a mean 9.6 mm ( $p < 0.008$ ) in the sacroiliac osteotomies, 6.2 mm ( $p < 0.008$ ) and 5.8 mm ( $p < 0.032$ ) in the biplanar supra-acetabular, 3 mm ( $p < 0.016$ ) in the ischial and 2.2 mm ( $p < 0.032$ ) and 2.6 mm ( $p < 0.008$ ) in the parallel iliopubic osteotomies, with a mean linear deviation of 4.9 mm ( $p < 0.001$ ) for all osteotomies. Of the manual osteotomies, 53% ( $n = 16$ ) had a linear deviation  $> 5$  mm and 27% ( $n = 8$ ) were  $> 10$  mm. In the PSI cases, deviations were 10% ( $n = 3$ ) and 0% ( $n = 0$ ), respectively. For angular deviation from pre-operative plans, we observed a mean improvement of  $7.06^\circ$  ( $p < 0.001$ ) in pitch and  $2.94^\circ$  ( $p < 0.001$ ) in roll, comparing PSI and the standard manual technique.

## Conclusion

In an experimental study, computer-assisted planning and PSIs improved accuracy in pelvic tumour resections, bringing osteotomy results closer to the parameters set in pre-operative planning, as compared with standard manual techniques.

**Cite this article:** *Bone Joint Res* 2017;6:577–583.

**Keywords:** Pelvic tumour, Patient-specific instruments, 3D printing, Computer-assisted planning, Cadaveric study

## Article focus

- Assess the accuracy of 3D PSI in pelvic tumour resection in a cadaveric model.
- Use of PSIs yields more accurate results than standard manual technique in pelvic tumour resection.
- Computer-assisted planning and PSI-guided osteotomies result in more precise pelvic tumour resections.

## Key messages

- PSIs could benefit clinical practices performing pelvic bone tumour resections

- PSIs would be especially useful in centres with limited financial resources, by improving execution of pre-operatively planned osteotomies.
- In an experimental study, computer-assisted planning and PSIs improved accuracy of pelvic osteotomies in common bone tumour resections, when compared with freehand techniques.

## Strengths and limitations

- Strength: The literature includes no previous reports evaluating the precision of PSIs in pelvic tumour surgery.

- Strength: The previous studies are made with saw-bones or comparing with navigated surgery.
- Limitation: this was an experimental cadaveric study with few cases; more extensive clinical studies involving multiple surgeons should be performed to validate these results.

## Introduction

Surgical treatment of malignant bone tumours within the pelvis is challenging due to the complex 3D bone structure geometry, as well as the proximity of vital structures such as blood vessels, sciatic and femoral nerves and the bladder and/or rectum. Furthermore, a wide resection with safe tumour margins is the most important prognostic factor. Local recurrence rate can be as high as 70% after a marginal resection and 92% in cases of intralesional resection, as compared with a 5% to 17% recurrence rate with negative surgical margins.<sup>1-5</sup> However, excessive resection may alter or reduce reconstructive options and may lead to negative functional outcomes,<sup>6</sup> taking into account that limb salvage surgery is the preferred procedure for most patients with malignant tumours of the pelvis and lower limb.<sup>7</sup>

Cartiaux et al<sup>8</sup> performed an experimental study to analyse the surgical accuracy of pelvic tumour resection by four experienced surgeons. The study clearly demonstrated that freehand osteotomy of pelvic tumours is not an accurate technique: 11 of the 24 cutting planes studied did not meet the accepted 5 mm tolerance above or below the targeted 10 mm surgical margin; two cutting planes were intralesional. In a study in which 24 patients underwent wide resection of malignant pelvic tumours, the surgical resections, classified according to the system described by Enneking et al,<sup>9</sup> were found to be wide in 19 cases, marginal in six and intralesional in one.<sup>10</sup>

Several procedures for improving surgical accuracy have been described, such as computer-assisted surgical navigation, robot-assisted surgery and use of patient-specific instruments.<sup>3,11-14</sup>

The patient-specific instrument (PSI) is a personalised tool that guides the saw, chisel or drill in a specific, pre-designed cutting path. A short clinical series and a cadaveric study comparing PSIs with navigation have shown that PSIs perform well in a clinical setting and are as precise as navigation-assisted resection.<sup>7,12</sup> Currently, there are no cadaveric studies comparing standard freehand technique with PSI-guided resections. The aims of this experimental study were to assess the accuracy of PSIs versus standard freehand technique and the precision of computer-assisted planning and PSI-guided osteotomies in pelvic tumour resection. For the purposes of this study, accuracy is defined as the distance of a cut from its pre-operatively planned target and precision is defined as the degree of variability of cuts among the study cases in relation to their surgical targets.

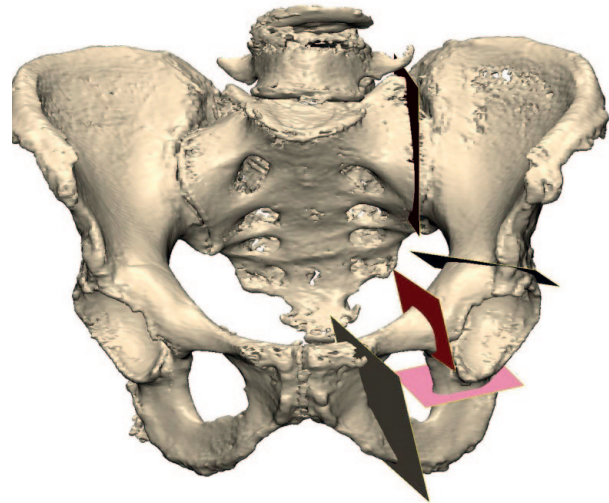


Fig. 1

Design of the five osteotomies using Materialise 3-matic. From left to right, top to bottom: single-plane sacroiliac; biplanar supra-acetabular; single-plane ischial; and parallel iliopubic osteotomies.

## Materials and Methods

An experimental study was performed using five female cadaveric pelvises from the Anatomy Laboratory (Universitat Autònoma de Barcelona, Barcelona, Spain). The pelvises were scanned (Aquilion Vision; Toshiba, Irvine, California) in 0.5 mm slices. Digital Imaging and Communications in Medicine (DICOM) files were then exported to the Mimics (Materialise, Leuven, Belgium) software. Semi-automatic segmentation was then performed for each pelvis, and a 3D pelvic bone model was created (1:1). Next, using Materialise 3-matic software, five pelvic osteotomies commonly performed in pelvic bone tumour resections were designed (Fig. 1). The first osteotomy was a single-plane sacroiliac osteotomy, parallel and medial to the joint. Also designed was a biplanar supra-acetabular osteotomy, a single-plane ischial osteotomy and two parallel iliopubic osteotomies. According to the Enneking classification,<sup>15</sup> these osteotomies would serve for T1, T2 and iliopubic bone resections. Sacroiliac and supra-acetabular osteotomies are commonly used for tumours in pelvic area type I of the Enneking classification (confined to the ilium). The supra-acetabular osteotomy, also commonly used for both type I or II resections, was biplanar, to test the supposed advantage of PSI in custom resections for custom implants. Two parallel iliopubic osteotomies were designed to evaluate accomplishment of parallel cuts. The ischial osteotomy is also commonly employed in type II resections. We did not design a pubic symphysis osteotomy as these are not difficult to perform freehand.

For the right hemipelvis, resection plans were designed using measurements of the dimensions and angles of the designed planes. Plane endpoints were referenced with key anatomic landmarks to aid freehand

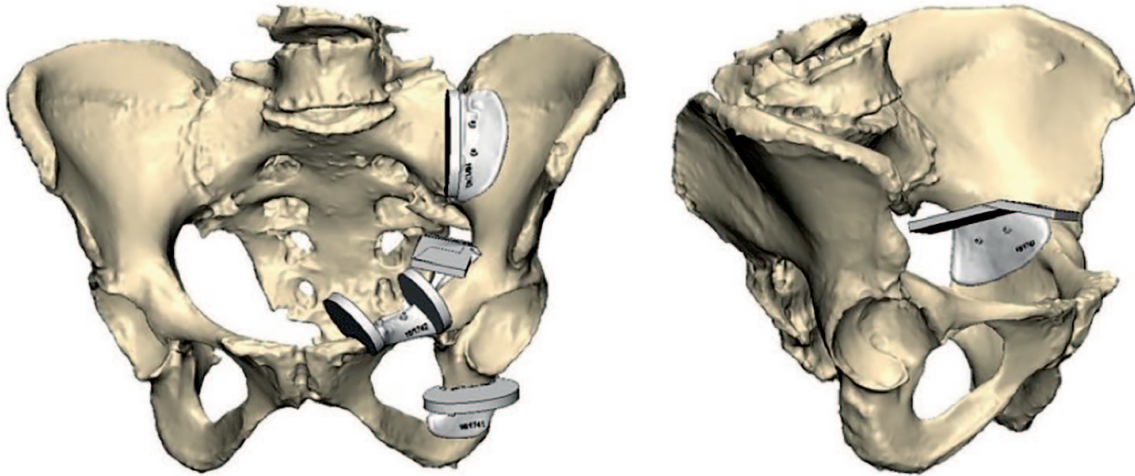


Fig. 2

Design of the patient-specific instruments using Materialise 3-matic software for each individual osteotomy.

resection technique. For the left hemipelvis, PSIs were designed using Materialise 3-matic software to guide each individual osteotomy (Fig. 2). These guides were designed to adapt to the cortical surfaces; each included three orifices for stabilisation with a 1.5 mm Kirschner-wire (K-wire). Each guide had a 2 cm wide planar surface over which the oscillating saw would pass. The guides were manufactured in polyamide using a Formiga P110 3D printer (EOS GmbH Electro Optical Systems, Krailling, Germany) with Avinent Implant System, S.L. (Barcelona, Spain). Each PSI was then packaged with an identification number that correlated with the specific pelvis for which it had been designed.

All pelvic resections were carried out in the cadaver lab. For each osteotomy, the pelvic specimen was secured to a table with external support pads. Pre-operative plans, which included all dimensions, were printed out and made available for each hemipelvic manual resection on the right-hand side. All hemipelvic resections on the right-hand side followed the standard technique, interpreting the visual, printed pre-operative plans and using key anatomic landmarks to measure and mark the desired osteotomies.

The osteotomies were performed using an oscillating saw. Resected bone specimens were marked, identified and packaged in transparent plastic transport bags. For hemipelvic resections on the left-hand side, each pelvis had its own set of PSIs (Fig. 3). Local bone exposure was performed and then the PSIs were placed according to plan and each fixed with three K-wires. After confirming good cortical anatomic match between the specimen and the guide, with a visible gap of  $< 1$  mm between the bone surface and the PSI, the osteotomy was performed using an oscillating saw, sliding above the guide. Resected bone specimens were marked, identified and packaged in transparent transport plastic bags. Aquilion Vision was used to

scan the specimens with 0.5 mm slices. DICOM files were then exported to the Mimics software. Next, semi-automatic segmentation was performed on each specimen and 3D models were created (1:1).

The sacroiliac and ischial osteotomies were performed with their corresponding monoplanar PSIs. The biplanar supra-acetabular and parallel iliopubic osteotomies were performed with biplanar PSIs. Each surgical cut was compared with its pre-operative target plane and maximum absolute deviation was obtained. Mean improvement, as we use it here, refers to the difference between the mean of the maximum distances between the actual and planned cuts.

We used the Mimics software to analyse the pre- and post-resection 3D reconstructed specimens. For each specimen, the software superimposed the pre-operative and post-operative images, placing both in common coordinates. Linear deviation was then measured, in millimetres, as the perpendicular distance from the target plane osteotomy to the point on the cut specimen farthest from the planned target plane. Angular roll and pitch deviations were measured, in degrees, as rotation about the bone's anteroposterior axis and mediolateral axis, respectively, between the target plane osteotomy and the cut specimen.

**Statistical analysis.** This was performed using SPSS Statistics (SPSS 20.0 for Windows; IBM Corp., Armonk, New York). Descriptive statistics were used to present the results. Quantitative variables were compared using the parametric Student's *t*-test and the non-parametric Mann–Whitney U test, considering a *p*-value of  $< 0.05$ .

## Results

**Accuracy of PSI versus standard freehand technique: distance improvement.** Compared with the standard manual technique, the PSI-guided osteotomies resulted in

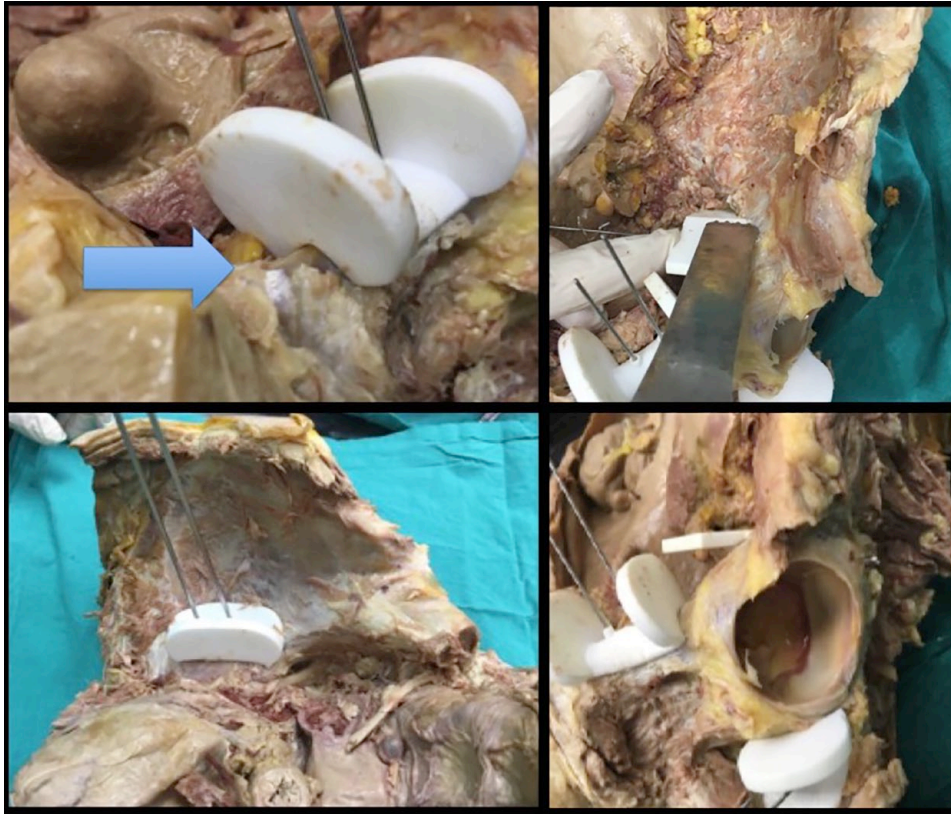


Fig. 3

For hemipelvic resections on the left-hand side, each osteotomy had its own pair of patient-specific instruments (PSIs). PSIs were placed according to anatomical landmarks and fixed with Kirschner-wires. A correct match between anatomical cortical bone and the guide can be observed (arrow).

a significant mean improvement of 9.6 mm ( $p < 0.008$ ) in the sacroiliac osteotomies, 6.2 mm ( $p < 0.008$ ) and 5.8 mm ( $p < 0.032$ ) in the biplanar supra-acetabular osteotomies, 3 mm ( $p < 0.016$ ) in the ischial osteotomies and 2.2 mm ( $p < 0.032$ ) and 2.6 mm ( $p < 0.008$ ) in the parallel iliopubic osteotomies. Mean maximum linear deviation was 4.9 mm ( $p < 0.001$ ) for all osteotomies (Table I). A total of 53% of the standard technique osteotomies ( $n = 16$ ) had a linear deviation  $> 5$  mm and 27% ( $n = 8$ ) were  $> 10$  mm. In the PSI osteotomies, the percentages were 10% ( $n = 3$ ) and 0% ( $n = 0$ ), respectively.

**Accuracy of PSIs versus standard freehand technique: angular improvement.** For angular deviation from pre-operatively planned planes, we observed a mean  $7.06^\circ$  improvement ( $p < 0.001$ ) in pitch and a mean  $2.94^\circ$  ( $p < 0.001$ ) improvement in roll. Comparing the standard manual technique with PSI-guided osteotomies, we found that PSIs produced a significant mean pitch-angle improvement of  $9.34^\circ$  ( $p < 0.008$ ) in the sacroiliac osteotomies,  $6.76^\circ$  ( $p < 0.016$ ) and  $9.7^\circ$  ( $p < 0.008$ ) in the biplanar supra-acetabular osteotomies,  $5.42^\circ$  ( $p < 0.008$ ) in the ischial osteotomies and  $5.84^\circ$  ( $p < 0.008$ ) and  $5.28^\circ$  ( $p < 0.008$ ) in the parallel iliopubic osteotomies. Compared with the standard manual technique, PSI-guided osteotomies resulted in significant mean roll-angle improvements of  $4.08^\circ$  ( $p < 0.008$ ) in the sacroiliac

osteotomies,  $2.98^\circ$  ( $p < 0.008$ ) and  $3.28^\circ$  ( $p < 0.016$ ) in the biplanar supra-acetabular osteotomies and  $3.94^\circ$  ( $p < 0.008$ ) and  $3.42^\circ$  ( $p < 0.008$ ) in the parallel iliopubic osteotomies. The ischial osteotomy mean roll angle was  $2.76^\circ$  for the standard manual technique; in the PSI group, the angle was  $2.8^\circ$  ( $p > 0.05$ ). Descriptive data collected are shown in Table II.

### Discussion

In this cadaveric study, we demonstrate that 3D patient-specific instruments could improve bone resection accuracy during surgery, especially compared with the standard manual technique.

Reproducing the pre-operative plan as accurately as possible is crucial in pelvic tumour surgery, in order to achieve negative surgical margins and thus decrease the likelihood of local recurrence, a critical factor for patient survival.<sup>5,14,16,17</sup> However, resecting significantly more tissue than planned, out of concern for leaving a positive margin, can compromise patient function and/or successful reconstruction.<sup>14</sup> Thus, accuracy in executing the pre-operative plan is crucial for safe surgical margins and for preserving maximum bone stock.

In 2004, Hüfner et al<sup>18</sup> first described the use of navigation-assisted surgery for improving bone resection technique in the treatment of pelvic tumours. The use of

**Table I.** Mean and standard deviation (SD) distances (mm) in osteotomies, comparing freehand versus patient-specific instruments

Osteotomy	Distance			p-value*
	Freehand	PSI	Mean improvement†	
SI	14.60 (3.85)	5 (1.73)	9.6	0.008
SA1	10.20 (2.68)	4 (1.41)	6.2	0.008
SA2	9.40 (2.51)	3.60 (2.70)	5.8	0.032
ISCH	5.20 (2.28)	2.20 (1.10)	3	0.016
PI1	3.00 (1.58)	0.80 (0.84)	2.2	0.032
PI2	3.60 (1.14)	1 (0.71)	2.6	0.008

\*Student's t-test and Mann-Whitney U test

†Mean improvement refers to the mean of the maximum distances between actual and planned cuts

PSI, patient-specific instruments; SI, sacroiliac; SA1, supra-acetabular 1; SA2, supra-acetabular 2; ISCH, ischial; PI1, parallel iliopubic 1; PI2, parallel iliopubic 2

computer navigation assistance in pelvic tumour surgery has been shown to decrease the intralesional resection rate from 29% to 8.7%.<sup>11</sup> Where navigation is used, both the intralesional resection rate and the local recurrence rate compare favourably with traditional techniques due to their improved accuracy.<sup>3,11</sup> Sternheim et al<sup>19</sup> studied pelvic bone cut accuracy using a navigated system (navigated osteotome and oscillating saw). According to the authors, navigation can improve accuracy in pelvic bone tumour resections and pelvic osteotomies to within 5 mm of the planned cut, resulting in > 95% of cuts with a safe margin of 5 mm between the target tumour volume and the planned cut.

However, pre-operative and intra-operative errors can occur with navigation-assisted surgery, especially in relation to surface registration (where the surgeon must re-interpret the correct localisation).<sup>20</sup> Image-to-patient registration must be checked before resection. This step can be avoided where PSI is used, although PSI does require careful bone-surface preparation. Furthermore, navigational instruments can be costly, navigated surgeries can be lengthy and becoming proficient with the technique involves a steep learning curve.<sup>11</sup>

It has also been shown that cutting accuracy can be improved using robot-assisted surgery.<sup>13,14</sup> According to the studies cited, the robot-assisted technique provided a mean locational accuracy of 1.7 mm, as compared with 2.8 mm for the navigated freehand process ( $p < 0.0001$ ). However, the saws currently available may not be entirely suitable for robot-assisted surgery due to their limited ability to produce gap-free surfaces.<sup>13</sup> As demonstrated by Fadda et al,<sup>21</sup> current saws, when held by a robot manipulator, can produce gaps of a maximum of 0.2 mm. Khan et al<sup>14</sup> designed a novel passive (haptic) robot-assisted resection that leaves cut control in the surgeon's hands. Compared with the manual group, the haptic-robotic group improved mean maximum deviation from the pre-operative plan by 7.8 mm (statistically significant).

**Table II.** Descriptive details of the values observed in pitch (°), roll (°) and distance (mm) of the different osteotomies

	SI	SA1	SA2	ISCH	PI1	PI2
Right pitch						
1	10.1	9.1	20.2	7.1	8.3	5.1
2	17.2	12.3	14.1	10.1	9.3	8.6
3	10.2	15.3	11.6	6.8	5.4	5.4
4	9.4	19.1	14.3	7.4	6.8	7.8
5	22.1	10.2	10.1	3.2	3.7	3.2
Right roll						
1	5.1	7.3	7.2	2.1	5.5	4.5
2	5.2	6.1	6.5	3.1	4.5	4.3
3	4.9	5.3	4.3	4.1	4.3	3.4
4	8.9	8.1	7.6	3.2	4.5	4.9
5	7.3	4.3	3.4	1.3	2.1	1.2
Right distance						
1	15	8	7	5	4	2
2	19	8	12	5	1	4
3	13	12	9	4	2	5
4	9	14	7	3	5	4
5	17	9	12	9	3	3
Left pitch						
1	3.1	9.1	3.1	2.1	1.1	1
2	4.5	5.7	3.2	2.2	1.2	0.9
3	5.1	9.1	9.2	2	1.3	1.1
4	3.2	3.1	3.2	0.1	0.5	0.5
5	6.4	5.2	3.1	1.1	0.2	0.2
Left roll						
1	2.2	3.1	1.7	3.4	0.4	0.4
2	2.1	4.3	2.1	4.5	0.5	0.5
3	1.1	1.8	3.7	2.8	0	0
4	2.1	3.4	2.6	2.2	0.2	0.2
5	3.5	3.6	2.5	1.1	0.1	0.1
Left distance						
1	4	5	1	1	0	0
2	4	3	2	4	1	1
3	5	6	8	2	0	1
4	4	3	4	2	2	2
5	8	3	3	2	1	1

SI, sacroiliac; SA1, supra-acetabular 1; SA2, supra-acetabular 2; ISCH, ischial; PI1, parallel iliopubic 1; PI2, parallel iliopubic 2

Previous studies have shown that using PSIs in bone tumour resection within the pelvis provides good cutting accuracy, simplifying tumour resection and later prosthetic reconstruction.<sup>7,22</sup> Cartiaux et al<sup>23</sup> performed an experimental study similar to the current study; however, rather than operating on cadaveric bones (which differ anatomically between individual human specimens), they used identical synthetic bones and addressed only one periacetabular tumour. The authors observed that the use of PSI and navigation produced results significantly better than those obtained with the unassisted technique. Surgical times were also reduced in such cases. The same study compared the use of PSI technology by senior and junior surgeons. No significant difference in results was observed between the two groups in terms of location accuracy and surgical margins obtained.<sup>23</sup> The authors concluded that PSI could be an easily managed technology for experienced and newer surgeons alike. Synthetic cadavers were used in the study, with no intrinsic anatomical differences from one case to the next. This could have facilitated planning and execution, favourably affecting results.

The use of PSIs does not offer the same intra-operative feedback as is available in navigation-guided systems, feedback that can reveal errors in the pre-operative planning and allow for procedural adjustments.<sup>12,24</sup> Another limitation of PSI surgery may be the incorrect placement of the PSI on the bone surface. A recent review stated that a footprint with more contoured bone surfaces may be less prone to errors since the PSI would fit better.<sup>25</sup> Navigation systems also offer the advantage of being available upon request for scheduling a surgery, whereas PSI use requires four to five days for instrument design and manufacture.

An experimental study comparing PSI and navigation in treating periacetabular tumours showed that both could achieve clinically acceptable accuracy, with a mean deviation of < 2 mm from planned parameters.<sup>12</sup> The mean time required for resection was significantly reduced in the PSI group as compared with the navigation group, and surgeons described intra-operative use of PSI as simpler. On the other hand, a PSI can only be assessed subjectively with respect to its being correctly fitted to the bone surface, whereas navigation calibration systems objectively evaluate image-to-patient registration.<sup>12</sup> While both techniques can achieve similar outcomes, PSIs offer lower associated costs than navigated surgery.

One clinical study used computer-aided design and PSIs in treating osteosarcoma of the knee in eight male patients.<sup>26</sup> The authors observed shorter surgical durations, reduced radiation exposure and blood loss and greater ease of execution.

Several limitations must be considered when reviewing the present study. First, only five cadaveric specimens were available, with significant differences observed. Second, because PSIs can only guide bone osteotomies, a soft-tissue mass associated with the tumour must sometimes be resected using the standard technique, so that the overall impact of PSI use on achieving negative oncologic margins may be less than expected. This is a factor that has also previously been noted regarding navigation-assisted surgery.<sup>11</sup> Although the standard technique requires exposure of the bone surface through healthy, uncontaminated tissue, large soft-tissue masses may impede or limit application of PSIs, since these require more soft-tissue exposure to achieve correct placement. Nerves and vessels are also present in the surgical field which can affect results due to incorrect placement or iatrogenic damage. Moreover, all manual osteotomies in this study were performed on the right hemipelvis, whereas PSIs were only used on the left. Thus, the right- or left-handedness of the participating surgeons could have affected accuracy. Ideally, steps would have been taken to eliminate this variable. Additionally, there are the effects of user variability in accurate placement of the PSI in areas of differing anatomic contours and with restricted exposure and visibility. Cadaveric studies

are carried out in a much more controlled environment than in live surgeries, without the need to manage real-time surgical situations such as excessive bleeding, which could affect correct PSI placement.

PSIs offer the advantage of being case-specific, i.e., they are custom-manufactured for the individual patient, with no need to invest in an expensive navigation system. It is an accessible technology with a minimal learning curve;<sup>27</sup>

3D PSI is an effective method for high-accuracy reproduction of pre-operative planning. In clinical practice, PSIs could be helpful for pelvic bone tumour resection in centres with limited financial resources by improving the execution of pre-operatively planned osteotomies. There are no previous reports in the literature evaluating the precision of PSIs in pelvic tumour surgery. Computer-assisted planning and patient-specific instruments improve the accuracy of pelvic osteotomies in common bone tumour resections when compared with standard manual techniques in an experimental study.

## References

- Ozaki T, Flege S, Kevric M, et al.** Osteosarcoma of the pelvis: experience of the Cooperative Osteosarcoma Study Group. *J Clin Oncol* 2003;21:334-341.
- Fuchs B, Hoekzema N, Larson DR, Inwards CY, Sim FH.** Osteosarcoma of the pelvis: outcome analysis of surgical treatment. *Clin Orthop Relat Res* 2009;467:510-518.
- Wong KC, Kumta SM.** Computer-assisted tumor surgery in malignant bone tumors. *Clin Orthop Relat Res* 2013;471:750-761.
- Parry MC, Laitinen M, Albergo J, et al.** Osteosarcoma of the pelvis. *Bone Joint J* 2016;98-B:555-563.
- Wirbel RJ, Schulte M, Mutschler WE.** Surgical treatment of pelvic sarcomas: oncologic and functional outcome. *Clin Orthop Relat Res* 2001;390:190-205.
- Han I, Lee YM, Cho HS, et al.** Outcome after surgical treatment of pelvic sarcomas. *Clin Orthop Surg* 2010;2:160-166.
- Gouin F, Paul L, Odri GA, Cartiaux O.** Computer-assisted planning and patient-specific instruments for bone tumor resection within the pelvis: a series of 11 patients. *Sarcoma* 2014;2014:842709.
- Cartiaux O, Docquier PL, Paul L, et al.** Surgical inaccuracy of tumor resection and reconstruction within the pelvis: an experimental study. *Acta Orthop* 2008;79:695-702.
- Enneking WF, Spanier SS, Goodman MA.** Current concepts review. The surgical staging of musculoskeletal sarcoma. *J Bone Joint Surg [Am]* 1980;62-A:1027-1030.
- Delloye C, Banse X, Brichard B, Docquier PL, Cornu O.** Pelvic reconstruction with a structural pelvic allograft after resection of a malignant bone tumor. *J Bone Joint Surg [Am]* 2007;89-A:579-587.
- Jeys L, Matharu GS, Nandra RS, Grimer RJ.** Can computer navigation-assisted surgery reduce the risk of an intralesional margin and reduce the rate of local recurrence in patients with a tumour of the pelvis or sacrum? *Bone Joint J* 2013;95-B:1417-1424.
- Wong KC, Sze KY, Wong IO, Wong CM, Kumta SM.** Patient-specific instrument can achieve same accuracy with less resection time than navigation assistance in periacetabular pelvic tumor surgery: a cadaveric study. *Int J Comput Assist Radiol Surg* 2016;11:307-316.
- Cartiaux O, Paul L, Docquier PL, et al.** Computer-assisted and robot-assisted technologies to improve bone-cutting accuracy when integrated with a freehand process using an oscillating saw. *J Bone Joint Surg [Am]* 2010;92-A:2076-2082.
- Khan F, Pearle A, Lightcap C, Boland PJ, Healey JH.** Haptic robot-assisted surgery improves accuracy of wide resection of bone tumors: a pilot study. *Clin Orthop Relat Res* 2013;471:851-859.
- Enneking WF, Dunham WK.** Resection and reconstruction for primary neoplasms involving the innominate bone. *J Bone Joint Surg [Am]* 1978;60-A:731-746.
- Bacci G, Forni C, Longhi A, et al.** Local recurrence and local control of non-metastatic osteosarcoma of the extremities: a 27-year experience in a single institution. *J Surg Oncol* 2007;96:118-123.

17. **Nagarajan R, Neglia JP, Clohisy DR, Robison LL.** Limb salvage and amputation in survivors of pediatric lower-extremity bone tumors: what are the long-term implications? *J Clin Oncol* 2002;20:4493-4501.
18. **Hüfner T, Kfuri M, Jr, Galanski M, et al.** New indications for computer-assisted surgery: tumor resection in the pelvis. *Clin Orthop Relat Res* 2004;426:219-225.
19. **Sternheim A, Daly M, Qiu J, et al.** Navigated pelvic osteotomy and tumor resection: a study assessing the accuracy and reproducibility of resection planes in Sawbones and cadavers. *J Bone Joint Surg [Am]* 2015;97-A:40-46.
20. **Wong KC, Kumta SM.** Joint-preserving tumor resection and reconstruction using image-guided computer navigation. *Clin Orthop Relat Res* 2013;471:762-773.
21. **Fadda M, Marcacci M, Toksvig-Larsen S, Wang T, Meneghello R.** Improving accuracy of bone resections using robotics tool holder and a high speed milling cutting tool. *J Med Eng Technol* 1998;22:280-284.
22. **Holzapfel BM, Pilge H, Prodinger PM, et al.** Customised osteotomy guides and endoprosthesis reconstruction for periacetabular tumours. *Int Orthop* 2014;38:1435-1442.
23. **Cartiaux O, Paul L, Francq BG, Banse X, Docquier PL.** Improved accuracy with 3D planning and patient-specific instruments during simulated pelvic bone tumor surgery. *Ann Biomed Eng* 2014;42:205-213.
24. **Leeuwen JA, Grøgaard B, Nordsletten L, Röhrli SM.** Comparison of planned and achieved implant position in total knee arthroplasty with patient-specific positioning guides. *Acta Orthop* 2015;86:201-207.
25. **Wong KC.** 3D-printed patient-specific applications in orthopedics. *Orthop Res Rev* 2016;8:57-66.
26. **Ma L, Zhou Y, Zhu Y, et al.** 3D-printed guiding templates for improved osteosarcoma resection. *Sci Rep* 2016;6:23335.
27. **Chinnappa J, Chen DB, Harris IA, MacDessi SJ.** Total knee arthroplasty using patient-specific guides: is there a learning curve? *Knee* 2015;22:613-617.

**Funding Statement**

- None declared

**Author Contribution**

- A. Sallent: Surgery, Writing the paper, Final revision.
- M. Vicente: Surgery, Statistical analysis.
- M. M. Reverté: Statistical analysis, Final revision.
- A. Lopez: Writing the paper, Final revision.
- A. Rodríguez-Baeza: Surgery, Statistical analysis.
- M. Pérez-Domínguez: Final revision.
- R. Velez: Surgery, Writing the paper.

**Conflicts of Interest Statement**

- None declared

© 2017 Sallent et al. This is an open-access article distributed under the terms of the Creative Commons Attribution licence (CC-BY-NC), which permits unrestricted use, distribution, and reproduction in any medium, but not for commercial gain, provided the original author and source are credited.