

Clinical Features of Primary Familial Brain Calcification in 17 Families

Yuan-Tao Huang¹, Li-Hua Zhang¹, Mei-Fang Li², Lin Cheng³, Jian Qu⁴, Yu Cheng¹, Xi Li¹, Guo-Ying Zou⁵, Hong-Hao Zhou¹

¹Department of Clinical Pharmacology, Xiangya Hospital Central South University, Changsha, Hunan 410008, China

²Department of Otorhinolaryngology, The Brain Hospital of Hunan Province, Changsha, Hunan 410007, China

³Key Laboratory of Ophthalmology, Zhongshan Ophthalmic Center, Sun Yat-sen University, Guangzhou, Guangdong 510060, China

⁴Department of Pharmacy, The Second Xiangya Hospital, Central South University, Institute of Clinical Pharmacy, Central South University, Changsha, Hunan 410011, China

⁵Department of Clinical Laboratory, The Brain Hospital of Hunan Province, Changsha, Hunan 410007, China

To the Editor: Primary familial brain calcification (PFBC) is a rare genetically degenerative disease that is generally characterized by symmetrical, bilateral calcinosis in the basal ganglia, thalamus, dentate nuclei, and other brain regions and mainly manifests with neurological and psychiatric symptoms. A growing number of studies have reported associations between this condition and pathogenic mutations, such as those in the *SLC20A2*, *PDGFRB*, *PDGFB*, *XPRI*, and *MYORG* genes.^[1-5] Few studies have evaluated familial clinical characteristics, such as the volume of basal ganglia calcification (VBGC), and the results of clinical tests to determine serum levels of calcium (Ca), magnesium (Mg), phosphorus (P), iron (Fe), aluminum (Al), arsenic (As), cobalt (Co), parathyroid hormone (PTH), and calcitonin (Ct), or the relationship between patient age and the VBGC in PFBC. In an effort to investigate this subject, we collected and analyzed clinical data for 17 PFBC families. This study was approved by the Independent Ethics Committee, Institute of Clinical Pharmacology, Central South University (No: CTXY-140010-3). The protocol was registered at the Chinese Clinical Trial Registry (No. ChiCTR-COC-15006713). All participants signed informed consent forms before enrollment.

We performed a retrospective review to identify suspected patients who were observed in the inpatient or outpatient departments of the Brain Hospital of Hunan Province within the last four years. We also continuously collected data for suspected patients who were registered during the period from July 10, 2015, to October 10, 2016. After a suspected patient was confirmed as a proband, we contacted and recruited all of his or her family members. PFBC diagnostic procedures and exclusion criteria were based on 2015 Nicolas.^[6] Finally, 17 PFBC families including 70 patients and 60 healthy individuals with Han Chinese ethnicity were enrolled and analyzed. The family pedigrees are shown in Figure 1.

All the family members completed a medical history and physical examinations performed by a trained neurologist. Blood samples

were obtained from all patients and some of the healthy people in the 17 families. The samples were subjected to clinical tests, such as routine blood, blood sedimentation, liver and renal function, electrolyte and syphilis tests, in addition for tests for trace elements (spectrophotometric method) and immunoreactivity for anti-Sm and anti-nuclear antibodies and chemiluminescence detection (Abbott reagent) of PTH and Ct. All family members older than 14 years underwent a routine brain computed tomography (CT) examination. Layered computing was first used to measure the VBGC and was followed by a summation of the combined volume exhibiting calculation. Calculations based on CT automated software were performed to determine the surface area of each layer. The final volume was multiplied by the slice thickness. Physiological calcification, including that observed at the age over 60 years and on head CT showing punctate calcification in the basal ganglia, was not calculated.

Family members were divided into a patient group and a normal group. Patients were classified into a symptomatic group and an asymptomatic group, according to clinical symptoms and when subdivided into families with movement disorder and psychiatric signs according to the patients' specific clinical manifestations. The independent sample *t*-test was used to analyze numerical variables such as onset age, VBGC, serum levels of Ca²⁺, and other parameters. The Chi-square test was used to analyze categorical variables, such as the rate of calcification of the choroid plexus, thalamus, and cerebellum. The independent sample *t*-test was applied to analyze all available data. First, the normal distribution test was conducted to analyze variables related to the VBGC. The movement disorder and psychiatric family samples were analyzed for data frequency distribution and found to be normally distributed.

Address for correspondence: Dr. Hong-Hao Zhou,
Department of Clinical Pharmacology, Xiangya Hospital Central
South University, Changsha, Hunan 410008, China
E-Mail: hhzhou2003@163.com

This is an open access journal, and articles are distributed under the terms of the Creative Commons Attribution-NonCommercial-ShareAlike 4.0 License, which allows others to remix, tweak, and build upon the work non-commercially, as long as appropriate credit is given and the new creations are licensed under the identical terms.

© 2018 Chinese Medical Journal | Produced by Wolters Kluwer - Medknow

Received: 28-05-2018 **Edited by:** Ning-Ning Wang
How to cite this article: Huang YT, Zhang LH, Li MF, Cheng L, Qu J, Cheng Y, Li X, Zou GY, Zhou HH. Clinical Features of Primary Familial Brain Calcification in 17 Families. *Chin Med J* 2018;131:2997-3000.

Access this article online

Quick Response Code:



Website:
www.cmj.org

DOI:
10.4103/0366-6999.247218

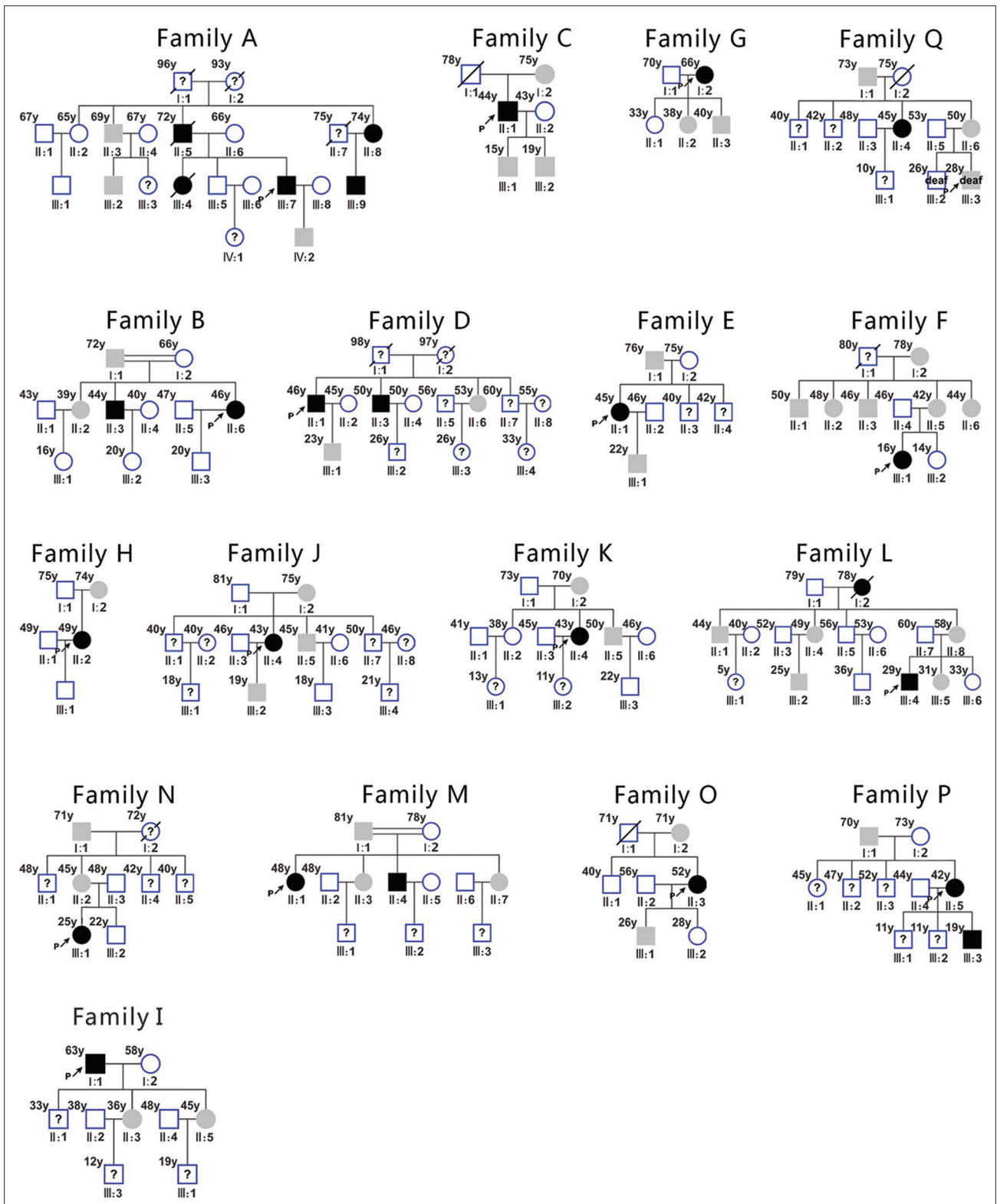


Figure 1: The pedigrees of the 17 PFBC families. Squares indicate male family members, circles indicate female family members, solid black symbols indicate symptomatic affected members, solid gray symbols indicate asymptomatic affected members, slashes indicate deceased family members, and the double lines indicate a consanguineous marriage in families B and Q. The arrow indicates the proband. The ages of the family members are shown on the upper-left side. The “?” indicates family members who participated in the survey but for whom no CT image and blood sample were available. PFBC: Primary familial brain calcification; CT: Computed tomography.

Then, the relationship between patient age and VBGC was analyzed using a linear regression analysis. A $P < 0.05$ was considered statistically significant. All numerical variables in this article are

presented as the mean \pm standard deviation (SD). Demographic and baseline characteristics were analyzed using SPSS 20.0 software (SPSS Inc., Chicago, IL, USA).

A total of 70 patients in 17 families were enrolled in this study, including two families with consanguineous marriages. All showed an autosomal dominant pattern of inheritance [Figure 1]. In all, 37.14% (26/70) of the patients were symptomatic and 62.86% (44/70) were asymptomatic. The clinical manifestations associated with PFBC included movement disorder (42.31%, 11/26), psychiatric signs (46.15%, 12/26), and epilepsy (11.54%, 3/26). The clinical manifestations in symptomatic patients were similar within the same family and presented family consistencies. Brain CT and magnetic resonance (MR) in the patients showed that only patient II: 2 in Family B had a lesion in the parietal lobe, while the rest of the patients displayed bilateral symmetry in lesions located in the basal ganglia, cerebellum, and other areas. The three epileptic patients had relatively larger lesions in basal ganglia calcifications and also had other cortical calcifications. Brain CT showed intracranial calcification lesions with high-density changes. Brain MR displayed equally short T_1 and short, slightly longer T_2 signals [Supplementary Figure 1]. The rate of calcification of the choroid plexus was 97.14% (68/70) in PFBC patients and was statistically significant higher than the rates of thalamic (4.29%, 30/70) and cerebellar (25.71%, 18/70) calcification ($\chi^2 = 120.739, 75.366, P < 0.05$) in PFBC patients.

There was no statistically significant difference in the serum levels of Ca^{2+} , Mg^{2+} , P, Fe, Al, As, Co, PTH, and Ct between the normal and patient groups or the symptomatic and asymptomatic groups [Supplementary Table 1 and 2]. There were statistically significant differences in patient age of onset (44 ± 3 vs. 27 ± 6 years, $t = 7.543, P < 0.05$) between the movement disorder and psychiatric groups. There were also statistically significant differences in the VBGC (9.48 ± 8.15 cm³ vs. 2.26 ± 2.60 cm³, $t = 4.389, P < 0.05$) between the symptomatic and asymptomatic groups, the movement disorder and psychiatric groups (15.86 ± 4.71 cm³ vs. 1.66 ± 1.09 cm³, $t = 9.764, P < 0.05$), and the symptomatic and asymptomatic groups in movement disorder families (15.86 ± 4.71 vs. 4.26 ± 3.96 cm³, $t = 6.359; P < 0.05$). However, there was no statistically significant difference in the VBGC between the symptomatic and asymptomatic groups in the psychogenic families (1.66 ± 1.09 vs. 1.41 ± 1.11 cm³, $t = 0.657; P > 0.05$). In movement disorder families, the patient age was unrelated to the VBGC [$r = 0.124, P > 0.05$, Supplementary Figure 2]. The same result was found in psychogenic families [$r = 0.027, P > 0.05$, Supplementary Figure 3].

Movement disorders, psychiatric signs, and cognitive impairments are the most common clinical manifestations of PFBC patients.^[7] They are usually related to basic pathological changes in parameters such as infiltration by Ca and other minerals into the basal ganglia, dentate nuclei, and subcortical white matter or even their peripheral vessels. Our results, which demonstrate that the percentage of patients who exhibited movement disorder and psychotic manifestations, are inconsistent with the previous reports.^[7] The percentage of asymptomatic patients was significantly higher in our study than in previous studies. In our opinion, the symptoms of some of the patients with headache, dizziness, and deafness were not largely associated with the calcified lesions. Therefore, these patients were included in the group of asymptomatic patients, directly leading to an increase in the number of patients in this group. The results of our study show that the symptoms were similar across all the symptomatic patients in the PFBC families, in agreement with previous reports saying that the clinical features of this condition are similar regardless of the type of inheritance. Our results show that the

symptoms observed in the symptomatic patients manifested as the same unique system of damage-related symptoms. This differs from previous reports in which PFBC patients have often been reported to present two to three overlapping symptoms, indicating a distinct clinical syndrome.^[8] Our results are also different from those described in reports by Bowirrat *et al.*,^[9] who showed that brothers in the same family exhibited completely different symptoms. The reason for these differences remains unclear. We speculate that patients from the same family tend to have the same causative gene and the living environment (epigenetic environment), and these factors may determine the location, size, and number of and changes in calcified lesions and the type of clinical phenotype observed.

Previous studies have reported that symptomatic patients have more calcification than found in asymptomatic patients.^[7] However, we found that the symptoms of movement disorder but not the appearance of psychiatric signs were related to the VBGC after we regrouped the patients according to specific clinical symptoms. There was no significant difference in the VBGC between the symptomatic and asymptomatic groups of patients in the families with psychiatric signs. We think that the accuracy and reliability of these results would be improved by making comparisons between different groups, according to their specific manifestations. The causes of the movement disorder observed in the patients in this study were mainly related to the infiltration of minerals, such as Ca, into the basal ganglia and cerebellar dentate nuclei, in accordance with classical views of the relationships among neural structures and their functions. However, the causes and consequences of these movement disorders do not exactly match. For example, the clinical characteristics were relatively mild in some patients with serious structural changes on imaging. The following findings are related to the pathological changes observed in PFBC patients: although serious gliosis and neuronal loss were observed in areas with severe Ca infiltration, some of the neurons in these regions remained well preserved. In addition, the VBGC was relatively smaller in the patients in psychiatric families. Younger patients were more likely to exhibit clinical symptoms such as hallucinations and delusions, and older patients in the same family reported no discomfort related to the calcified lesions if they exhibited no clinical symptoms when they were young. This might indicate that whether or not they became symptomatic was independent of the VBGC. Under those circumstances, a new issue arose: while there were only one or two symptomatic patients in each psychiatric family, other patients within each family were asymptomatic despite having lesions in the same region and a similar VBGC. These results suggest that whether the patients within the family exhibit clinical symptoms or not is likely to depend on factors other than genetic inheritance alone.

Previous studies have reported that the clinical heterogeneity of PFBC is associated with the onset age.^[7,10] We have obtained more detailed data related to the onset age of patients with different symptoms. In patients with movement disorder, the age of onset was approximately 40 years, which was generally 10 years older than that observed in patients with psychiatric signs. These results are consistent with the conclusion that patients who become symptomatic early in adulthood are more prone to psychosis.^[8] We hypothesized that movement disorder developed as a direct result of the destruction of nerve nuclei, which requires a certain level of deposition of calcium and other elements. This process of deposition is gradual and requires a long time. Hence, the clinical symptoms of movement disorder would appear later. Conversely, damage to the chemical pathways related to psychiatric signs can

occur earlier than damage, resulting in structural changes to nerve nuclei.

Previous studies have reported that differences in the amount of calcification are not significantly associated with age^[8] and the degree of calcification was not always the most marked in the oldest affected members. In our study, a linear regression analysis showed that patient age was not related to the VBGC. We also found that older patients within the same family were less likely to have a significantly larger VBGC. This finding challenges the general understanding that elderly patients have bigger calcified lesions, while younger patients have smaller calcified lesions. We did not perform a dynamic study of how the sizes of the calcified lesions changed within the same patient. However, based on the changes observed in the patients' clinical symptoms and levels of severity, we conclude that the sizes of calcified lesions may vary across a certain range within different age groups. A study had shown that most common locations for calcification occur in PFBC patients are the basal ganglia, cerebellum, and thalamus.^[8] Although our data were limited to head imaging data obtained from 70 patients, we found that the most frequently observed site of calcification in PFBC patients were the basal ganglia, choroid plexus, cerebellum, and thalamus. Although the causes of choroid plexus calcification are multifactorial, choroid plexus calcification is more frequently regarded as related to physiology and age.^[8] In a previous study, the rate of calcification of the choroid plexus has been reported to be as high as 12% in children^[11] and 70.2% in adults.^[11] However, our data indicate that the rate of calcification of the choroid plexus is as high as 97.14%, and this led us to the conclusion that the calcification of the choroid plexus might be one of the most important imaging characteristics of PFBC.

In PFBC patients, the main components of intracranial calcified lesions are Ca, polysaccharide, and a small amount of trace elements. In this study, we examined the serum concentrations of Ca, Al, As, Co, Mg, P, and Fe in PFBC family members and found that neither their serum concentrations nor those of the major hormones PTH and Ct, which regulate the metabolism of Ca, P, and other trace elements, were different when groups of family members were analyzed using a number of methods. It has previously been presumed that the VBGC deposition in the brain of Ca or other mineral substances is not caused by abnormal serum concentrations of Ca, Al, As, Co, Mg, P, and Fe or abnormal blood levels of PTH and Ct. Therefore, methods that test these factors may not be useful in diagnosing PFBC patients. The question then becomes one of how to explain the depositions of Ca and other substances that are observed in the brain tissues of patients with PFBC. Currently, the consensus is that changes in genes might directly or indirectly affect the formation of calcified lesions.

In summary, 17 PFBC families that exhibit dramatic clinical heterogeneity were reported. Affected patients with movement disorder had a larger VBGC and were characterized by relatively later-onset ages, while affected patients with psychiatric signs had a smaller VBGC and were characterized by relatively earlier-onset ages. Movement disorder but not psychiatric signs were related to the VBGC. We also found that neither serum concentrations of Ca, Al, As, Co, Mg, P, and Fe nor the levels of the major hormones PTH and Ct, which regulate the metabolism of Ca, P, and other trace elements, were associated with clinical symptoms. The choroid plexus followed by the basal ganglia were the most frequent sites of PFBC. Our study has some limitations, such as sample representativeness, which may have led to bias. A further

clinical study that includes a larger sample size to validate these results is therefore warranted.

Supplementary information is linked to the online version of the paper on the Chinese Medical Journal website.

Acknowledgment

We thank all the families that participated in this study. We are grateful for the generous help provided by Dr. Jing Dong and Xue Zhang during manuscript revisions.

Financial support and sponsorship

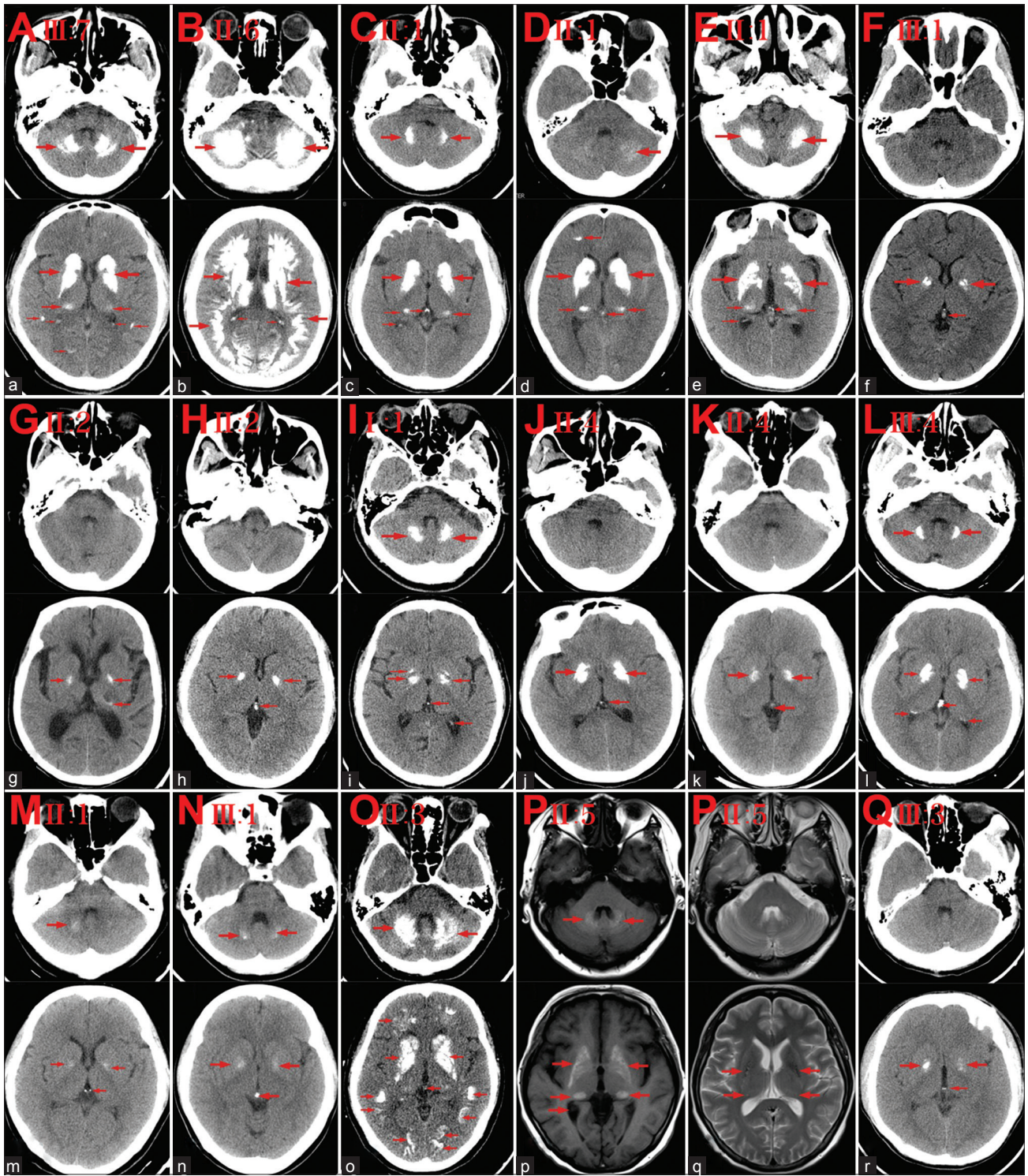
This study is supported by the grants from the Health and Family Planning Commission of Hunan Province (No. B2015-106) and the Natural Science Foundation of Hunan Province of China (No. 2018JJ6012).

Conflicts of interest

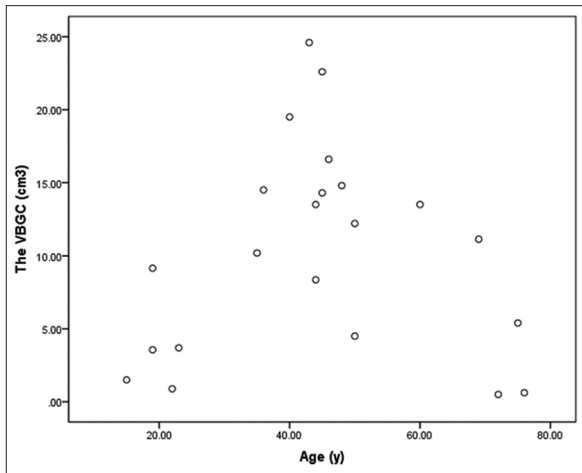
There are no conflicts of interest.

REFERENCES

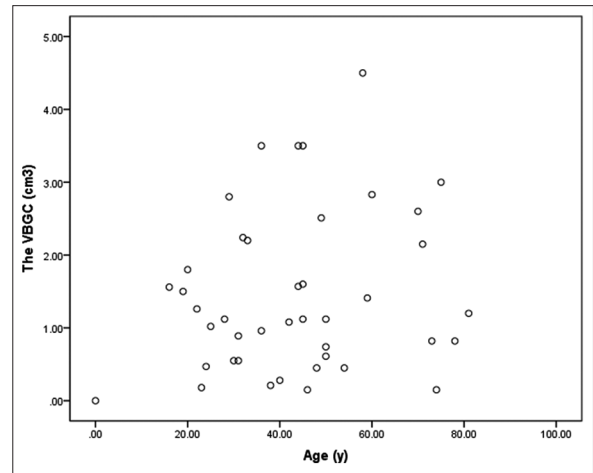
1. Wang C, Li Y, Shi L, Ren J, Patti M, Wang T, *et al.* Mutations in SLC20A2 link familial idiopathic basal ganglia calcification with phosphate homeostasis. *Nat Genet* 2012;44:254-6. doi: 10.1038/ng.1077.
2. Nicolas G, Pottier C, Maltête D, Coutant S, Rovelet-Lecrux A, Legalic S, *et al.* Mutation of the PDGFRB gene as a cause of idiopathic basal ganglia calcification. *Neurology* 2013;80:181-7. doi: 10.1212/WNL.0b013e31827ccf34.
3. Sanchez-Contreras M, Baker MC, Finch NA, Nicholson A, Wojtas A, Wszolek ZK, *et al.* Genetic screening and functional characterization of PDGFRB mutations associated with basal ganglia calcification of unknown etiology. *Hum Mutat* 2014;35:964-71. doi: 10.1002/humu.22582.
4. Legati A, Giovannini D, Nicolas G, López-Sánchez U, Quintáns B, Oliveira JR, *et al.* Mutations in XPR1 cause primary familial brain calcification associated with altered phosphate export. *Nat Genet* 2015;47:579-81. doi: 10.1038/ng.3289.
5. Yao XP, Cheng X, Wang C, Zhao M, Guo XX, Su HZ, *et al.* Biallelic mutations in MYORG cause autosomal recessive primary familial brain calcification. *Neuron* 2018;98:1116-23.e5. doi: 10.1016/j.neuron.2018.05.037.
6. Freire MA, Faber J, Lemos NA, Santos JR, Cavalcanti PF, Lima RH, *et al.* Distribution and morphology of calcium-binding proteins immunoreactive neurons following chronic tungsten multielectrode implants. *PLoS One* 2015;10:e0130354. doi: 10.1371/journal.pone.0130354.
7. Nicolas G, Pottier C, Charbonnier C, Guyant-Maréchal L, Le Ber I, Pariente J, *et al.* Phenotypic spectrum of probable and genetically-confirmed idiopathic basal ganglia calcification. *Brain* 2013;136:3395-407. doi: 10.1093/brain/awt255.
8. Bonazza S, La Morgia C, Martinelli P, Capellari S. Strio-pallido-dentate calcinosis: A diagnostic approach in adult patients. *Neurol Sci* 2011;32:537-45. doi: 10.1007/s10072-011-0514-7.
9. Bowirrat A, Yassin M, Artoul F, Artul S. Fahr's disease: Bilateral symmetrical striopallidodentate calcification in two brothers with two distinct presentations. *BMJ Case Rep* 2013;2013. pii: bcr2013200462. doi: 10.1136/bcr-2013-200462.
10. Whitehead MT, Oh C, Raju A, Choudhri AF. Physiologic pineal region, choroid plexus, and dural calcifications in the first decade of life. *AJNR Am J Neuroradiol* 2015;36:575-80. doi: 10.3174/ajnr.A4153.
11. Yalcin A, Ceylan M, Bayraktutan OF, Sonkaya AR, Yuca I. Age and gender related prevalence of intracranial calcifications in CT imaging: data from 12,000 healthy subjects. *J Chem Neuroanat* 2016;78:20-4. doi: 10.1016/j.jchemneu.2016.07.008.



Supplementary Figure 1: Diagram of the 17 probands' head CT (a-o and r) or MR (p and q). The number of the proband in the pedigree and the serial number of the pedigree are shown on the upper-left side. A set of images showing the cerebellum (upper part) and basal ganglia (lower part) of the proband. The arrow points to a calcified lesion. It is clear that the probands with movement disorder (a-e) had a larger VBGC than was observed in those with psychogenic disorders (f-n). The two probands with epilepsy (o-q) had relatively larger calcification lesions in the basal ganglia in addition to other areas of calcification. CT presents calcified lesions more intuitive than does MR. VBGC: Volume of basal ganglia calcification; CT: Computed tomography; MR: Magnetic resonance.



Supplementary Figure 2: Scatter plot of PFBC patient age and VBGC in movement disorder families ($n = 22$) showing that patient age was not related to the VBGC ($r = 0.124$, $P = 0.904$). PFBC: Primary familial brain calcification; VBGC: Volume of basal ganglia calcification.



Supplementary Figure 3: Scatter plot of PFBC patient age and VBGC in psychiatric signs families showing that patient age was not related to the VBGC ($r = 0.027$, $P = 0.232$). PFBC: Primary familial brain calcification; VBGC: Volume of basal ganglia calcification.

Supplementary Table 1: Comparison of the serum Ca, Mg, P, Fe, Al, As, Co, PTH and Ct concentration between the health and PFBC group

Items	Health group ($n = 10$)	PFBC group ($n = 67$)	t	P
Calcium (mmol/L)	2.21 ± 0.05	2.18 ± 0.10	0.932	0.354
Magnesium (mmol/L)	1.23 ± 0.07	1.22 ± 0.11	0.463	0.654
Phosphorous (mmol/L)	1.15 ± 0.09	1.15 ± 0.11	-0.055	0.956
Iron (μmol/ml)	7.44 ± 0.27	7.42 ± 0.81	0.079	0.937
Aluminum (nmol/l)	59.45 ± 1.47	58.03 ± 3.38	0.868	0.388
Arsenic (μmol/L)	2.14 ± 0.09	2.15 ± 0.19	-0.175	0.861
Cobalt (nmol/L)	11.95 ± 0.69	11.55 ± 1.02	1.185	0.240
PTH (pg/ml)	57.69 ± 2.78	58.21 ± 4.50	-0.969	0.336
Calcitonin (ng/L)	5.28 ± 0.17	5.17 ± 0.23	1.445	0.153

Data was presented with mean ± standard deviation. PTH: parathyroid hormone; PFBC: Primary familial brain calcification.

Supplementary Table 2: Serum Ca, Mg, P, Fe, Al, As, Co, PTH and Ct concentration in PFBC patients

Items	Symptomatic group ($n = 23$)	Asymptomatic group ($n = 43$)	t	P
Calcium (mmol/L)	2.17 ± 0.09	2.18 ± 0.10	-0.361	0.719
Magnesium (mmol/L)	1.20 ± 0.12	1.22 ± 0.10	-0.716	0.476
Phosphorous (mmol/L)	1.11 ± 0.12	1.16 ± 0.11	-1.962	0.054
Iron (μmol/ml)	7.48 ± 0.89	7.40 ± 0.78	0.370	0.712
Aluminum (nmol/l)	58.59 ± 3.60	57.66 ± 4.32	0.868	0.388
Arsenic (μmol/L)	2.21 ± 0.13	2.12 ± 0.21	1.758	0.084
Cobalt (nmol/L)	11.45 ± 0.96	11.63 ± 1.06	-0.680	0.499
PTH (pg/ml)	59.31 ± 4.81	57.67 ± 4.32	1.418	0.161
Calcitonin (ng/L)	5.14 ± 0.24	5.19 ± 0.22	-0.988	0.327

Data was presented with mean ± standard deviation. PTH: parathyroid hormone; PFBC: Primary familial brain calcification.