

Case Report

Endovascular Treatment for Pseudoaneurysms after Surgical Correction of Aortic Coarctation

M. Rabellino,^{1,2} T. Zander,¹ G. González,¹ S. Baldi,¹ H. Cheves,³ A. Estigarribia,³ R. Llorens,³ J. M. Carreira,¹ and M. Maynar¹

¹Department of Interventional Radiology, Hospital Hospiten Rambla, General Franco 115, 38001 Santa Cruz de Tenerife, Spain

²Department of Endovascular Therapy, Hospital Hospiten Rambla, General Franco 115, 38001 Santa Cruz de Tenerife, Spain

³Department of Cardiovascular Surgery, Hospital Hospiten Rambla, General Franco 115, 38001 Santa Cruz de Tenerife, Spain

Correspondence should be addressed to M. Rabellino, jmrabellino@hotmail.com

Received 17 November 2010; Accepted 9 February 2011

Academic Editor: Christian W. Hamm

Copyright © 2011 M. Rabellino et al. This is an open access article distributed under the Creative Commons Attribution License, which permits unrestricted use, distribution, and reproduction in any medium, provided the original work is properly cited.

Late complications after surgical repair of aortic coarctation are not uncommon. Among these complications pseudoaneurysms are the most frequent complications, occurring between 3 and 38%. Reoperation in these patients is associated with high morbidity and mortality. In the last decade, endovascular techniques emerged as an alternative to conventional surgery with excellent results. We report the case of two patients who presented with pseudoaneurysms after surgical correction for aortic coarctation, which were treated by endovascular means.

1. Introduction

Open surgery remains the gold standard for the treatment of aortic coarctation. Surgical treatment includes resection of the narrow segment with end-to-end anastomosis of the aorta and aortoplasty using a subclavian flap or synthetic material. These techniques show initially excellent results; however, late anastomotic pseudoaneurysms develop in 3 to 38% of all cases [1, 2]. Reoperation in these patients is complex and associated with high morbidity and mortality [2–5]. Therefore, in the last decade endovascular techniques emerged to treat these complications [5–9], based on the experience of endovascular treatment in atherosclerotic aneurysms in this location. We report the case of two patients with pseudoaneurysms after previous surgical repair which were treated by endovascular means.

2. Case 1

A 31-year-old female patient underwent surgical correction of aortic coarctation at the age of 4 years using a Gore-tex patch. During a routine angio-CT 17 years after the initial surgery, a recoarctation and a pseudoaneurysm were diagnosed, and a balloon-expandable stent was placed at

the recoarctation site. A control angio-CT showed stent migration and growth of the pseudoaneurysm measuring 53×40 mm in diameter. In contrast to the previous angio-CT, the pseudoaneurysm was multilobulated with irregular walls, and the origin of the left subclavian artery was dilated with 25 mm in diameter. Due to the morphologic changes and the size of the pseudoaneurysm, this patient was referred to our institution for endovascular treatment. Before treatment, a diagnostic angiography was performed using a 5F pigtail catheter with markers. The angiography showed a small caliber aortic arch with severe angulation and a pseudoaneurysm, that extended proximally to the origin of the left subclavian artery. The balloon-expandable stent was in contact with the aortic wall only at its distal end (Figure 1(a)). Treatment was performed in two times. Under general anesthesia a left carotid-subclavian bypass was performed using prosthetic Gore-tex of 8 mm, and the left subclavian artery was ligated. Two days after the surgery, the endovascular treatment was performed under general anesthesia and systemic heparinization. A right femoral access was used to introduce a Captivia (Medtronic Vascular, Santa Rosa, CA) thoracic endoprosthesis, 22×150 mm. The device was released covering the origin of the left subclavian artery (Figure 1(b)). Seventy-two hours after the

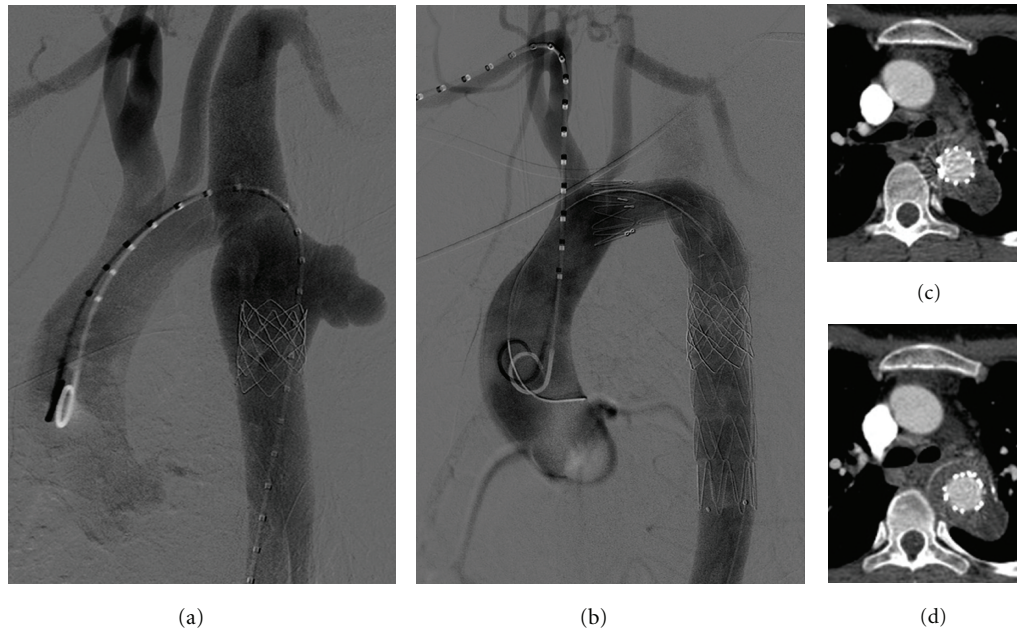


FIGURE 1: (a) Aortic angiography showing an angulated aortic arch and a small caliber thoracic aorta. A lobulated aortic pseudoaneurysm extends proximally to the left subclavian artery, and a large caliber balloon-expandable stent is adhered to the aortic wall at its distal end. (b) Final result after completion of the carotid subclavian bypass and exclusion of the pseudoaneurysm. A heparin-related leak can be found which extends to the left subclavian artery. (c) and (d) Angio-CT images showing exclusion of the pseudoaneurysm without evidence of leakage.

endovascular treatment, the patient was discharged. No complication was found in the angio-CT (Figures 1(c) and 1(d)). After 3 months the patient was asymptomatic without evidence of pathologic images in the control angio-CT.

3. Case 2

A 46-years-old male patient, who presented with mild hemoptysis at our institution, was operated at the age of 17 years for aortic coarctation using a prosthetic patch. In the angio-CT a pseudoaneurysm was diagnosed as a late complication of surgery of aortic coarctation measuring 64×68 mm in diameter. The diagnostic angiogram showed a sacular and irregular shaped pseudoaneurysm (Figure 2(a)). The right vertebral artery was found to be patent without atherosclerotic lesions and of preserved diameter. An aortobronchial fistula could be identified neither in the angio-CT nor in the diagnostic angiogram. Under general anesthesia and systemic heparinization the right common femoral artery was dissected, and a first endoprosthesis body Zenith TX2 (Cook Inc, Bloomington, IN) 22×115 mm was introduced and released, covering the left subclavian artery. After that, a second endoprosthesis body Captivia (Medtronic Vascular, Santa Rosa, CA) 26-26-150 mm was used to exclude the pseudoaneurysm. Due to the risk of death caused by severe hemoptysis, an emergency treatment was considered, consisting in endovascular bridging with stent grafts and proximal occlusion of the left subclavian artery. For this reason, two different endoprosthesis were used, since no other stent grafts, available in our stock, met the required characteristics. After liberating both devices a

latex balloon was introduced over a stiff wire for sealing. Through a left brachial access the left subclavian artery was then embolized using a 16-mm Amplatzer device. The final angiogram showed no leaks with present collateral flow in the left subclavian artery (Figures 2(b) and 2(c)) via right vertebral artery. The control angio-CT 3 days after the surgery showed a leak. There was an uncertainty, whether there was a leak type I or II, additionally a pseudoaneurysm in the right subclavian artery was found which was considered iatrogenic after placement of a jugular central line.

Through a right brachial access the pseudoaneurysm was embolized with 3 microcoils (Trufill, Cordis, Miami Lakes, FL.) (Figures 3(b) and 3(c)). The same access was used to clearly demonstrate a leak type I of the first endoprosthesis body (Figure 3(d)). Under general anesthesia a 23-mm angioplasty balloon catheter was delivered through a left femoral artery access to successfully seal the leak.

Before discharging the patient, a control angio-CT was performed, and no leak could be identified. At the 6-month follow-up the patient remained asymptomatic without hemoptysis and without other evidence of leakage or pathologic images in the angio-CT.

4. Discussion

Among the surgical techniques for the treatment of aortic coarctation, the surgical resection and end-to-end anastomosis has demonstrated low complication rates; however, late complications are still common [1, 2]. Late pseudoaneurysms should not be left untreated, as rupture has been

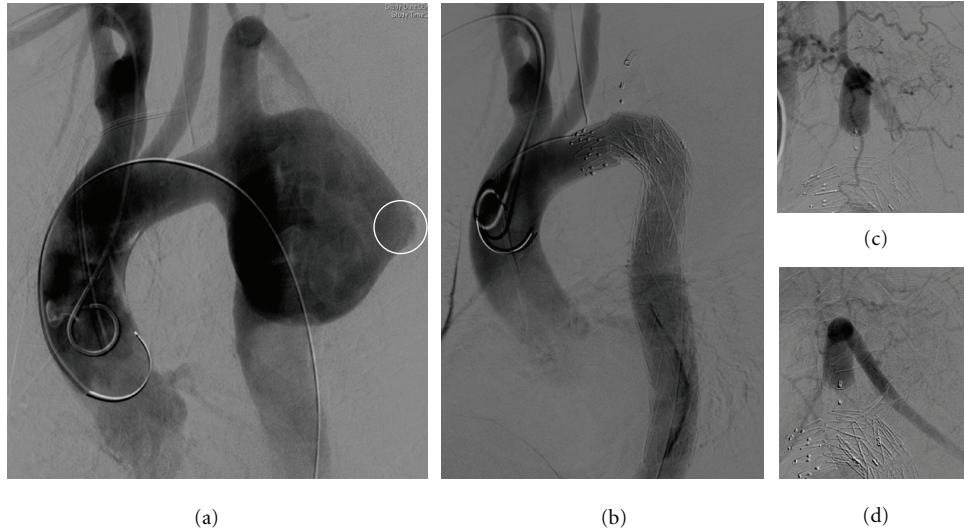


FIGURE 2: (a) Angiography shows a large aortic pseudoaneurysm extending to the origin of the left subclavian artery with an irregular wall (white circle). (b) Final angiography after stent placement and embolization of the left subclavian artery demonstrates complete exclusion of the pseudoaneurysm with no evidence of leakage. (c) and (d) Late angiographic image shows left subclavian artery perfusion due to subclavian steal.

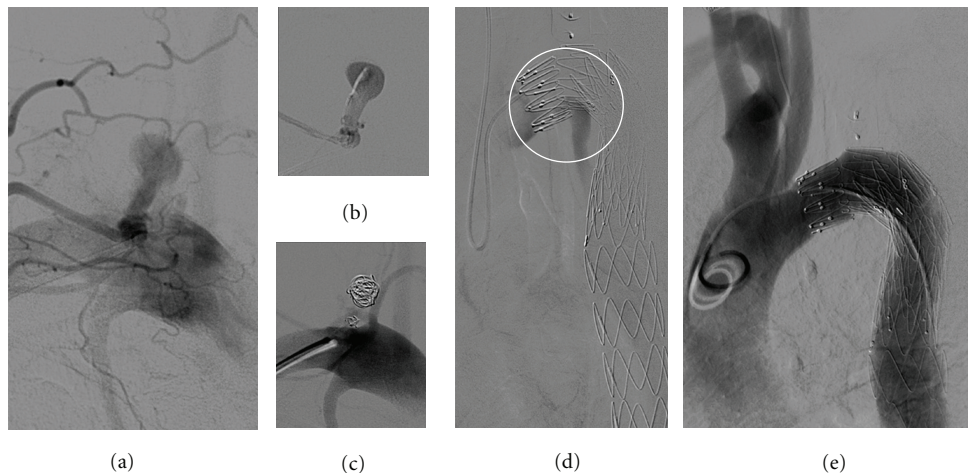


FIGURE 3: (a) Selective angiography of the left subclavian artery showing iatrogenic pseudoaneurysm after central line placement. (b) Selective intraaneurysmal angiography was performed with a 1.9 Fr microcatheter showing a long neck. (c) Result after embolization with microcoils demonstrating complete occlusion of the sack. (d) Selective angiography using a 5 Fr Sidewinder catheter shows a type I leak which can also be found on the angio-CT. (e) After angioplasty of the proximal endoprosthesis body the type I endoleak could be sealed completely.

described even in small pseudoaneurysms [7]. Knyshev et al. reported a rupture rate at 15 years of 100% of these pseudoaneurysms [2]. Reoperation in these patients is complex and is associated with high mortality and morbidity such as paraplegia, recurrent nerve paralysis, and bleeding [2]. In the last decade, endovascular techniques were introduced for the treatment of late complications after coarctation surgery in order to reduce complications related to open surgery. Even if the reported series are small, they show very encouraging results [5–9]. The technical difficulty of treating these patients includes hypoplastic aortic arch, proximal fixation zone in relation to the extension of the

pseudoaneurysm and the dimension of the access arteries. None of our patients had aortic arch hyperplasia; however one case presented with a severe angulated arch and a small diameter aorta. Additionally, the procedure was complicated by an aortic stent which was attached to the arterial wall only by the distal end. In this kind of patient and in patients with small caliber accessing arteries, friction and resistance can complicate the procedure, not permitting the device to be delivered to the proximal anchoring zone. The use of new devices with hydrophilic coating could help to overcome problems with angled arches, intravascular devices, and small accessing arteries.

In both cases the left subclavian artery had to be covered. In the first case, the left subclavian artery was revascularized through a carotid-subclavian bypass, and in the second case the subclavian artery was embolized using an Amplatzer device. Left subclavian artery occlusion is generally well tolerated; however there are several studies reporting the risk of complications such as superior extremity claudication or associated neurological symptoms [10–13]. Preinterventional angiography of the supraaortic vessels should be performed in order to demonstrate collateralization blood flow from the right to the left vertebral artery. These studies have been conducted on a patient population with atherosclerotic disease in which the collateral pathway, like vertebral arteries or the thyrocervical trunk, may be affected by the arteriosclerotic angiopathy. However, young patients usually do not have atherosclerotic disease, therefore occlusion of the left subclavian artery might be better tolerated. In a previous publication we reported the case of a young patient with traumatic aortic rupture in whom the left vertebral artery originated directly from the aortic arch [14]. In this case, despite independent embolization of left vertebral artery and left subclavian artery due to a type II leak, no neurological symptoms or signs of claudication in the left upper limb could be found, and the ipsilateral brachial and radial pulse was palpable in the following controls [14].

Although there are reports of endovascular treatment in late complications after surgical repair of aortic coarctation, these reports include a small number of patients. The published results are very encouraging, and with new devices more patients with complex anatomy can be treated safely with a high technical success. The endovascular treatment is an important alternative to surgical reoperation due to its lower morbidity and mortality. However, more data from long-term monitoring are needed to determine their effectiveness and to detect late complications.

Conflict of Interests

The authors declare that they have no conflict of interests.

References

- [1] Y. von Kodolitsch, M. A. Aydin, D. H. Koschyk et al., "Predictors of aneurysmal formation after surgical correction of aortic coarctation," *Journal of the American College of Cardiology*, vol. 39, no. 4, pp. 617–624, 2002.
- [2] G. V. Knyshov, L. L. Sitar, M. D. Glagola, and M. Y. Atamanyuk, "Aortic aneurysms at the site of the repair of coarctation of the aorta: a review of 48 patients," *Annals of Thoracic Surgery*, vol. 61, no. 3, pp. 935–939, 1996.
- [3] M. Cohen, V. Fuster, P. M. Steele, D. Driscoll, and D. C. McGoon, "Coarctation of the aorta: long-term follow-up and prediction of outcome after surgical correction," *Circulation*, vol. 80, no. 4, pp. 840–845, 1989.
- [4] K. Ala-Kulju and L. Heikkinen, "Aneurysms after patch graft aortoplasty for coarctation of the aorta: long-term results of surgical management," *Annals of Thoracic Surgery*, vol. 47, no. 6, pp. 853–856, 1989.
- [5] H. Ince, M. Petzsch, T. Rehders et al., "Percutaneous endovascular repair of aneurysm after previous coarctation surgery," *Circulation*, vol. 108, no. 24, pp. 2967–2970, 2003.
- [6] B. Marcheix, Y. Lamarche, P. Perrault et al., "Endovascular management of pseudo-aneurysms after previous surgical repair of congenital aortic coarctation," *European Journal of Cardio-Thoracic Surgery*, vol. 31, no. 6, pp. 1004–1007, 2007.
- [7] S. Kutty, R. K. Greenberg, S. Fletcher, L. G. Svensson, and L. A. Latson, "Endovascular stent grafts for large thoracic aneurysms after coarctation repair," *Annals of Thoracic Surgery*, vol. 85, no. 4, pp. 1332–1338, 2008.
- [8] L. Botta, V. Russo, G. Oppido et al., "Role of endovascular repair in the management of late pseudo-aneurysms following open surgery for aortic coarctation," *European Journal of Cardio-Thoracic Surgery*, vol. 36, no. 4, pp. 670–674, 2009.
- [9] M. Midulla, A. Dehaene, F. Godart et al., "TEVAR in patients with late complications of aortic coarctation repair," *Journal of Endovascular Therapy*, vol. 15, no. 5, pp. 552–557, 2008.
- [10] O. Galili, S. Fajer, A. Eyal, and R. Karmeli, "Left subclavian artery occlusion by thoracic aortic stent graft: long-term clinical and duplex follow-up," *Israel Medical Association Journal*, vol. 9, no. 9, pp. 668–670, 2007.
- [11] T. C. Rehders, M. Petzsch, H. Ince et al., "Intentional occlusion of the left subclavian artery during stent-graft implantation in the thoracic aorta: risk and relevance," *Journal of Endovascular Therapy*, vol. 11, no. 6, pp. 659–666, 2004.
- [12] P. J. Riesenman, M. A. Farber, R. R. Mendes, W. A. Marston, J. J. Fulton, and B. A. Keagy, "Coverage of the left subclavian artery during thoracic endovascular aortic repair," *Journal of Vascular Surgery*, vol. 45, no. 1, pp. 90–95, 2007.
- [13] J. Görich, Y. Asquan, H. Seifarth et al., "Initial experience with intentional stent-graft coverage of the subclavian artery during endovascular thoracic aortic repairs," *Journal of Endovascular Therapy*, vol. 9, no. 2, pp. I139–I143, 2002.
- [14] M. Rabellino, L. García Nielsen, S. Baldi et al., "Retrograde embolization of the left vertebral artery in a type II endoleak after endovascular treatment of aortic thoracic rupture: technical note," *CardioVascular and Interventional Radiology*, vol. 32, no. 1, pp. 169–173, 2009.