

Isolated Spontaneous Midbrain Hemorrhage in a 14-Year-Old Boy

Kim-Long R. Nguyen^{1,2} Hyunyoung Kim^{1,2} Laszlo Nagy^{1,2}

¹Covenant Children's Hospital, Lubbock, Texas, United States

²Texas Tech University Health Sciences Center, Lubbock, Texas, United States

Address for correspondence Kim-Long R. Nguyen, MSI, Texas Tech University Health Sciences Center, 3601 4th St., Lubbock, TX 79430, United States (e-mail: kim-long.r.nguyen@ttuhsc.edu).

J Neurol Surg Rep 2017;78:e5–e8.

Abstract

Isolated spontaneous midbrain hemorrhages are rare because they are usually secondary to hemorrhages from inferior structures such as the pons and cerebellum, or superior structures such as the thalamus and putamen. While the etiologies are largely unidentified, the most common ones are vascular malformations and bleeding diathesis with hypertension being relatively uncommon. We report midbrain hemorrhage in a 14-year-old boy with a long-standing history of frequent migraine headaches and attention deficit/hyperactivity disorder (ADHD). Neurologic examinations, noncontrast computed tomography (CT) scans, and magnetic resonance imaging (MRI) suggested that the lesion likely affected the dorsal part of the midbrain. The neurologic symptoms improved following endoscopic third ventriculostomy (ETV) with the placement of external ventricular drains (EVDs). In this report, anatomical correlations to the case are discussed and previous reports of midbrain hemorrhages are reviewed.

Keywords

- ▶ isolated hemorrhage
- ▶ midbrain hemorrhage
- ▶ pediatric
- ▶ spontaneous midbrain hemorrhage

Introduction

Spontaneous vascular lesions restricted to the midbrain are relatively rare compared with other brain lesions because of the small size of the structure and common vascular supply of the brain. Mesencephalic hemorrhages often secondarily result from a superior extension of pontine or cerebellar hemorrhage or an inferior extension of thalamic or putamen bleeding.^{1–3} While the etiologies of nontraumatic primary midbrain hemorrhages are largely unidentified, the most frequent ones are vascular malformations and bleeding diathesis with hypertension occasionally.⁴

Because of the complex anatomy of the midbrain, lesions in this structure result in a broad spectrum of clinical signs and symptoms, including ataxia, vertigo, ocular motility disorders, parkinsonian signs, and hydrocephalus.^{5–12} Among all, eye movement disorders are the most prominent manifestation because the vertical gaze centers and two nuclei of the extraocular muscles are located in the midbrain.^{13–16} Nevertheless, the prognosis is known to be generally favor-

able, as minute and benign cases have been increasingly recognized with the widespread use of imaging techniques.³

We report clinical symptoms and computed tomography (CT) and magnetic resonance imaging (MRI) findings of an isolated and spontaneous midbrain hemorrhage in a pediatric patient, not previously described in the literature.

Case Report

A 14-year-old boy with a long-standing history of frequent migraine headaches and attention deficit/hyperactivity disorder (ADHD) was transferred to our hospital from another institution with the diagnosis of possible midbrain tumor versus hemorrhage.

For the past 4 months prior to admission, the patient had experienced more frequent headaches, which attributed to poor vision, and a severe headache without vomiting 1 day before arrival. He is also reported to have experienced a bouncing movement going over a speed bump while traveling in a car. He initially developed symptoms of urinary

received
May 12, 2016
accepted
November 7, 2016

DOI <http://dx.doi.org/10.1055/s-0036-1597616>.
ISSN 2193-6358.

© 2017 Georg Thieme Verlag KG
Stuttgart · New York

License terms



incontinence and right-sided hemiparesis. Upon examination at the outside hospital (OSH), he presented with hypertension, altered mental status, and was difficult to arouse. He also had limited supraversion in both eyes, loss of vision in the right eye with diplopia, and nonreactive pupils, but no abnormalities of eyelids.

The noncontrast CT scan of the head done at OSH revealed a heterogeneous 2-cm hyperdense mass in the pineal region on the left, compressing the aqueduct of Sylvius, resulting in moderate obstructive hydrocephalus. Differential diagnosis included a recently thrombosed vein of Galen aneurysm versus hemorrhagic primary pineal tumor per report.

The MRI of the brain showed a 1.5-cm lesion within the posterior midbrain with some associated local edema with limited contrast enhancement. The ventricular system was enlarged and with moderate hydrocephalus. However, the angiogram was normal. **Fig. 1** shows the sagittal, axial, and coronal T₂-weighted images and axial fluid-attenuated inversion recovery (FLAIR) images.

Endoscopic third ventriculostomy (ETV) was performed to alleviate obstructive hydrocephalus, and an external ventricular drain (EVD) was placed to measure intracranial pressure, which never increased beyond 12 mm Hg. Although endoscopic biopsy was attempted, the location of mass in the

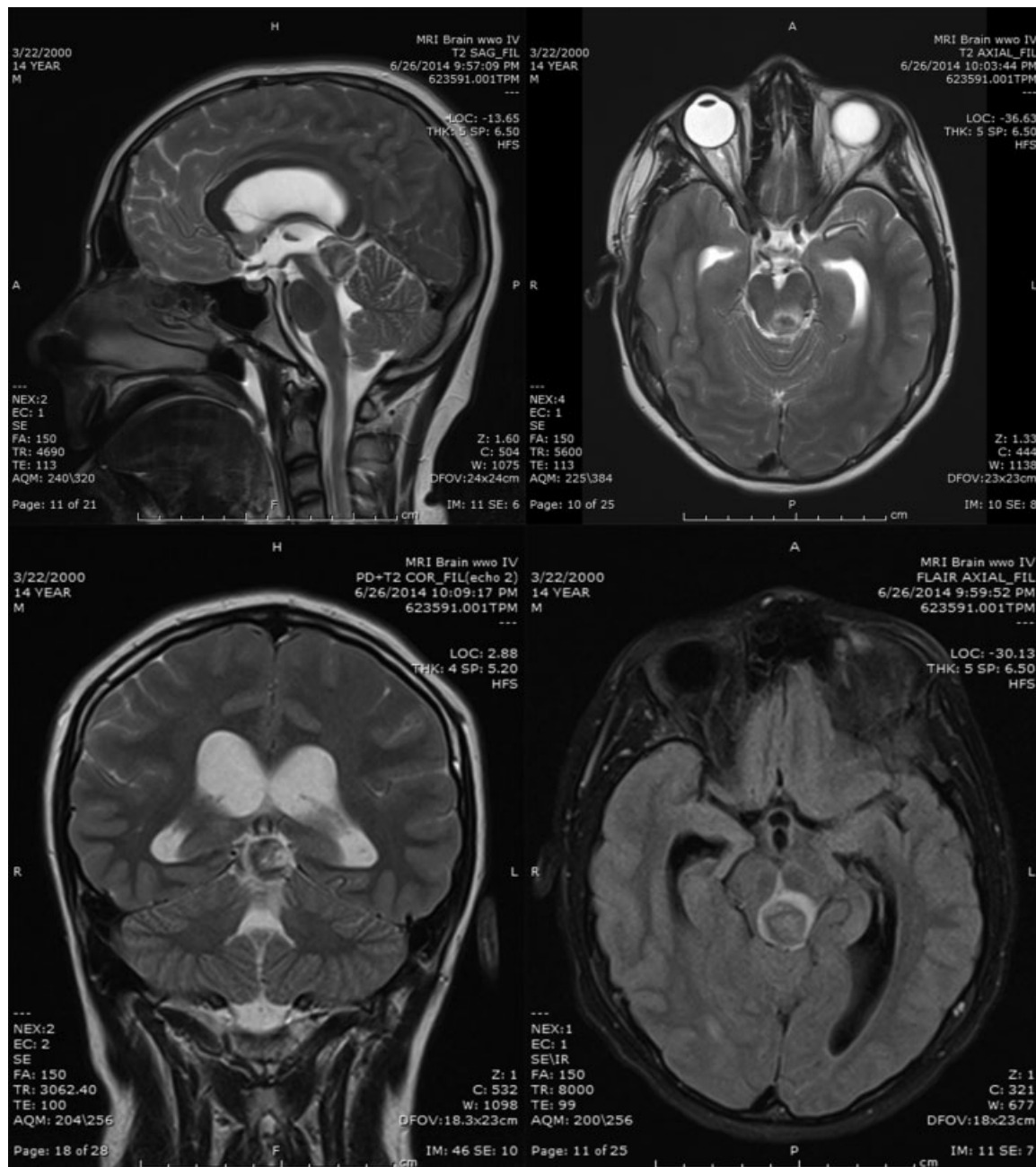


Fig. 1 Sagittal (upper left), axial (upper right), and coronal (lower left) T₂-weighted images and axial FLAIR images (lower right) on initial examination show a 1.5-cm lesion within the posterior midbrain with local edema.

midbrain made the risk of resection or embolization greater than endoscopic biopsy provided benefit.

One week after the operation, the MRI of the brain showed improvement in ventriculomegaly but remaining brainstem edema. The patient's mental status improved, and he denied any headache but continued to have a blurry and double vision, difficulty with upward gaze, and ataxia upon standing.

Four months after the acute event, a small area (~8 mm) of the abnormal signal related to the remote hemorrhage in the left tectum was again identified in MRI of the brain (→ Fig. 2). However, there was no evidence of an acute large territorial infarct, hydrocephalus, midline shift, or abnormal extra-axial fluid collections. The patient eventually improved and exhibited no neurologic deficits.

Discussion

Reports of patients suffering isolated midbrain hemorrhages have been relatively infrequent due to small size of the structure itself and the complex vasculature surrounding the whole brainstem. Vascular lesions in the midbrain are usually ischemic and often affect tegmentum, because major arteries are located at the ventral side of the brainstem and only the ends of their branches supply the dorsolateral midbrain.

The blood supply of the midbrain includes penetrating paramedian mesocephalic branches of the basilar artery, perforating branches of the posterior cerebral arteries (PCAs) and the superior cerebellar arteries (SCAs), and, possibly, the posterior medial choroidal arteries. The paramedian perforators of basilar bifurcation and thalamic-subthalamic perforating branches from the PCAs (P1 segment) supply the medial structures, including posterior commissure, the rostral nucleus of longitudinal fasciculus (riMLF), and the nucleus of the third cranial nerve.

While clear causes of the spontaneous midbrain hemorrhages remain to be identified, the most frequently cited ones are arteriovenous malformations and bleeding diathesis with arterial hypertension being relatively uncommon. Also, the previous reports of isolated spontaneous midbrain hemorrhages involved only adult patients. This case is unique in a sense that our patient was an adolescent and had normal vasculature with hypertension, which may have contributed to the hemorrhage, and the lesion was located majorly at the tectum.

The patient mainly exhibited right-sided hemiparesis and upward gaze palsy with mild obstructive hydrocephalus. Additional clinical presentations included bilateral nonreactive pupils, lagged extraocular motion, and double vision. Neurologic examination and imaging suggested that the lesion likely affected the superior colliculus and nearby structures, such as the riMLF, the nucleus of the third cranial nerve, the cerebral aqueduct, and the nucleus of the posterior commissure (NPC).

The ocular disorders manifest in our patient correlate to the damages to various structures at the level of the superior colliculus. While the slowed eye movements and nonreactive pupils could have resulted from a partial injury to the nucleus of the third nerve, the limitation on supraversion of the eyes could be related to the interruption of riMLF and NPC. Unilateral lesion of the riMLF has been related to bilateral upward gaze palsy, and the unilateral lesion of the NPC has been associated with unilateral upward eye movement. Moreover, the obstructive hydrocephalus occurs probably due to the damage to the cerebral aqueduct.

The clinical manifestations of the midbrain infarcts and hemorrhages are diverse mainly due to the complex anatomy of the structure. The increasing use of diagnostic imaging techniques has helped expand the clinical description of the isolated mesencephalon lesions. To our knowledge, this is the first case of a pediatric patient to be reported with an isolated

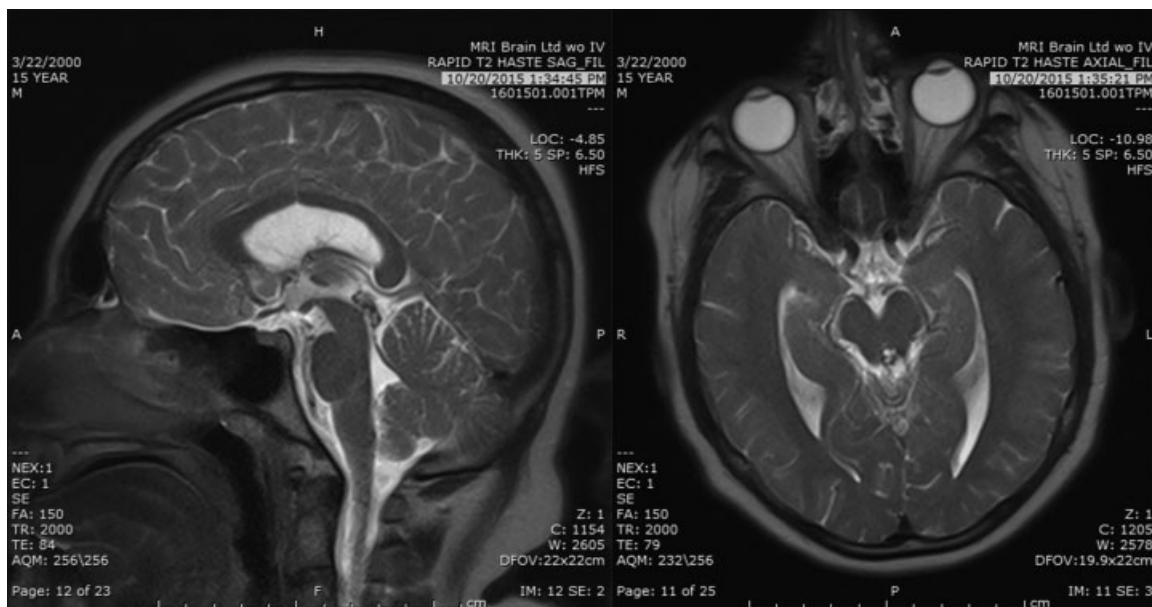


Fig. 2 Sagittal (left) and axial (right) T₂-weighted images after 4 months show an 8-mm lesion within the posterior midbrain.

and spontaneous mesencephalic hemorrhage. The clinical profile of this unusual disorder is therefore enhanced.

Acknowledgments

We would like to recognize Covenant Children's Hospital for allowing the use of patient history in this case report and Texas Tech University Health Sciences Center for their assistance in this report.

References

- 1 Han SH, Roh JK, Myung HJ. Mesencephalic hemorrhage—a report of 3 cases. *J Korean Med Sci* 1989;4(1):1–5
- 2 Tuttle PV, Reinmuth OM. Midbrain hemorrhage producing pure sensory stroke. *Arch Neurol* 1984;41(7):794–795
- 3 Perez FJ, Nuñez CT. Scanning dysarthria secondary to spontaneous midbrain hemorrhage: case report and review of literature. *Eur Neurol* 2008;60(2):89–91
- 4 Link MJ, Bartleson JD, Forbes G, Meyer FB. Spontaneous midbrain hemorrhage: report of seven new cases. *Surg Neurol* 1993;39(1):58–65
- 5 Bhole R, Olson RJ. Dorsal midbrain syndrome with bilateral superior oblique palsy following brainstem hemorrhage. *Arch Ophthalmol* 2006;124(12):1786–1788
- 6 Britt CW Jr, Raso E, Gerson LP. Spindle coma, secondary to primary traumatic midbrain hemorrhage. *Electroencephalogr Clin Neurophysiol* 1980;49(3–4):406–408
- 7 Esteban Muñoz J, Tolosa E, Saiz A, Vila N, Martí MJ, Blesa R. Upper-limb dystonia secondary to a midbrain hemorrhage. *Mov Disord* 1996;11(1):96–99
- 8 Galetta SL, Balcer LJ. Isolated fourth nerve palsy from midbrain hemorrhage: case report. *J Neuroophthalmol* 1998;18(3):204–205
- 9 Kremer M, Russell WR, Smyth GE. A mid-brain syndrome following head injury. *J Neurol Neurosurg Psychiatry* 1947;10(2):49–60
- 10 Ogane K, Suzuki S, Sobata E, Iwabuchi T. [Two cases of well-known syndrome due to midbrain-brain stem hemorrhage—Weber's syndrome and one and a half syndrome] [in Japanese]. *No To Shinkei* 1993;45(2):163–168
- 11 Shuaib A, Israelian G, Lee MA. Mesencephalic hemorrhage and unilateral pupillary deficit. *J Clin Neuroophthalmol* 1989;9(1):47–49
- 12 Shuaib A, Murphy W. Mesencephalic hemorrhage and third nerve palsy. *J Comput Tomogr* 1987;11(4):385–388
- 13 Lee AG, Brown DG, Diaz PJ. Dorsal midbrain syndrome due to mesencephalic hemorrhage. Case report with serial imaging. *J Neuroophthalmol* 1996;16(4):281–285
- 14 Rodríguez-Gómez J, Colás J, Aragón A, Albo MI, Casado F. [Upward and downward gaze palsy with a unilateral mesencephalic hemorrhage] [in Spanish]. *Rev Neurol* 2000;30(4):324–326
- 15 Shintani S, Tsuruoka S, Minato Y, Shiigai T. Radiologic-clinical correlation. Isolated third nerve palsy caused by midbrain hemorrhage. *AJNR Am J Neuroradiol* 1994;15(8):1508–1511
- 16 Tomecek FJ, Morgan JK. Ophthalmoplegia with bilateral ptosis secondary to midbrain hemorrhage. A case with clinical and radiologic correlation. *Surg Neurol* 1994;41(2):131–136