



Contents lists available at ScienceDirect

International Journal of Surgery Case Reports

journal homepage: www.casereports.com

Ileo-ileal intussusception of a sutured enterotomy site, 6 days after laparotomy due to fetobezoar: A case report



Moran Slavin*, Patricia Malinger, Yaron Rudnicki, Roye Inbar, Shmuel Avital

Department of General Surgery B, Meir Medical Center, Kfar Saba, Israel

ARTICLE INFO

Article history:

Received 4 March 2017

Received in revised form 3 May 2017

Accepted 6 May 2017

Available online 15 May 2017

Keywords:

Postoperative

Intussusception

Small bowel obstruction

Enterotomy

Case report

ABSTRACT

INTRODUCTION: Postoperative small bowel obstruction due to intussusception is a rare entity but can lead to severe morbidity and even mortality. We present a case of this rare complication produced by an unusual cause.

CASE REPORT: A 22 year old male, who is a fruitarian, presented to the E.R on day 6 after laparotomy due to obstructing fetobezoars that were removed via gastrotomy and enterotomy. In his readmission, he had severe, diffuse abdominal pain, distended abdomen and diffuse peritonitis. Abdominal computed tomography (CT) showed a large amount of fluid in the abdomen, distended small bowel loops, a small amount of free air around the stomach and a suspected ileo-ileal intussusception. The patient underwent emergent laparotomy which revealed an ileo-ileal intussusception with the sutured enterotomy site from the previous operation as the lead point. In addition, a minor dehiscence of the gastrotomy site was identified. A reduction of the intussusception was performed with resection of the enterotomy site and side to side anastomosis. The gastrotomy site was debrided and re-sutured. Recovery was uneventful.

CONCLUSION: Postoperative intussusception, although rare, is potentially a dangerous complication, often not involving the site of the primary operation. To our knowledge this is the first report of an intussusception with a sutured enterotomy site as the lead point. Clinicians should be aware of this entity when assessing a patient with abdominal pain and distention after surgery with enterotomy or resection of bowel.

© 2017 The Authors. Published by Elsevier Ltd on behalf of IJS Publishing Group Ltd. This is an open access article under the CC BY-NC-ND license (<http://creativecommons.org/licenses/by-nc-nd/4.0/>).

1. Introduction

Intussusception is a rare cause of bowel obstruction in adults accounting for 1%–5% of bowel obstructions [1]. It is commonly associated with an organic cause, however up to 20% may be idiopathic. Postoperative intussusceptions are a very rare entity and described mostly after manipulation of the stomach and proximal jejunum [2,3].

We present a case of an antegrade intussusception with a sutured enterotomy site as a lead point at POD 6.

This case was managed at Meir Medical Center, a public academic institute.

2. Case report

A 22 year old male presented to the E.R with a three day history of vomiting and abdominal pain. The patient is a fruitarian (a person whose diet consists chiefly of fruit [4]) and reported eating 20

persimmons the day before onset of symptoms. He had no surgical history.

Abdominal X-rays and CT showed small bowel obstruction with suspected bezoars in both ileum and stomach. An attempt to extract the stomach bezoars via endoscopy failed and the patient underwent a laparotomy. Three large fetobezoars were extracted from the stomach through a gastrotomy in the anterior stomach wall. Another fetobezoar was extracted from the ileum through a longitudinal enterotomy which was then sutured horizontally. Both the gastrotomy and enterotomy were sutured in double layers. A thorough scan of the small bowel was performed and no additional fetobezoars were found.

Recovery from the operation was uneventful; however the patient continued to consume only fruit, and since he was advised against a high fiber diet, restricted himself to filtered juice. Psychiatric evaluation did not reveal any major pathology. The patient was discharged on postoperative day 5.

24h later the patient returned to the E.R with vomiting, severe abdominal pain, hypothermia and a distended and tender abdomen. Abdominal X-rays demonstrated small bowel obstruction. CT revealed a large amount of fluid in the abdomen, a small amount of free air around the stomach and distended small bowel loops with a transition zone near the ileocecal valve (Fig. 1). Sus-

* Corresponding author.

E-mail address: moran.salomon@gmail.com (M. Slavin).

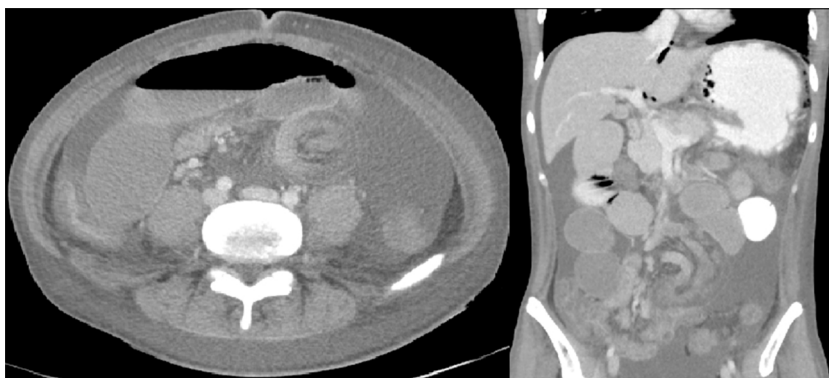

Fig. 1. Abdominal CT showing intussusception.

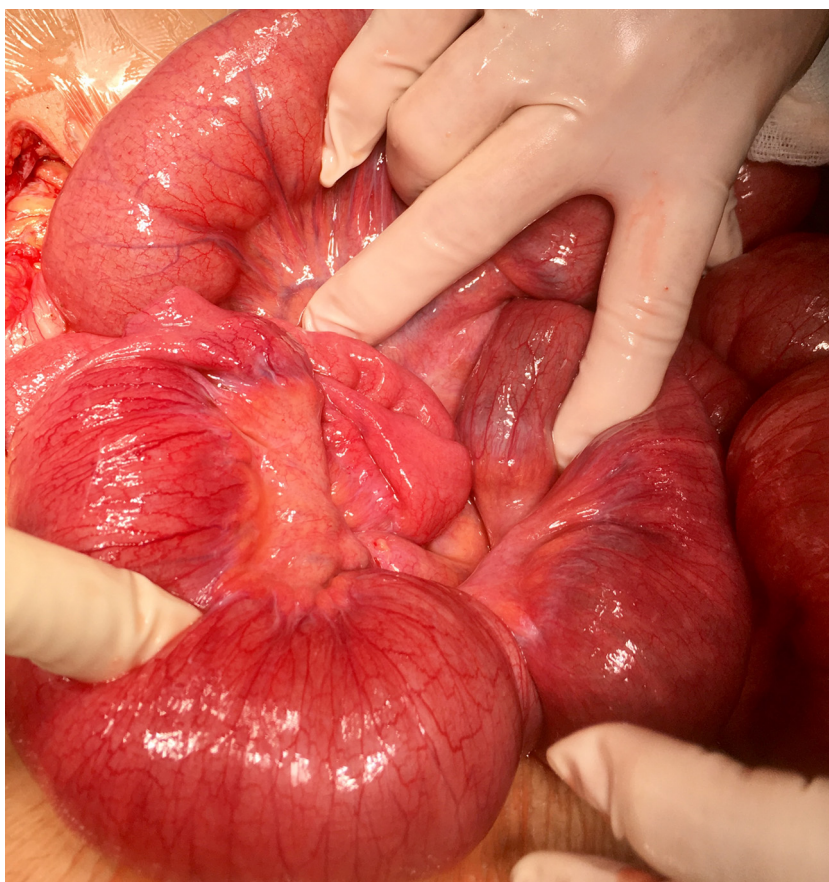


Fig. 2. Antegrade intussusception of ileum.

suspicion of an intussusception was raised however the presence of another fetobezoar could not be ruled out.

An emergent exploratory laparotomy was performed. An antegrade intussusception of the ileum (Fig. 2) and a two millimeter dehiscence of the gastrotomy site were found. A decompression of the intussusception was carefully performed. The length of the intussusceptum was roughly 50 cm with the lead point being the enterotomy site from the previous laparotomy. There was no leak from the enterotomy suture line; however the enterotomy site seemed to be mildly edematous (Fig. 3). Examination of the formerly invaginated bowel loop showed moderate hyperemia with good peristalsis and pulse. It was restored into the abdomen and care was then taken to repair of the gastrotomy site, which

was debrided and resutured in two layers. Re-examination of the previously invaginated segment of small bowel showed it had recovered well after decompression, and so only 10 cm of small bowel, enterotomy site included, were resected. Side to side hand sawn anastomosis was performed.

The patient's postoperative course was characterized by a slow recovery, requiring parenteral nutrition which was complicated by re-feeding syndrome and the need for intravenous replacement therapy. After initiating a vegan diet the patient was discharged on the seventh day following his second operation.

Pathology report of the resected small bowel loop showed inflammatory changes with no other pathologic findings.

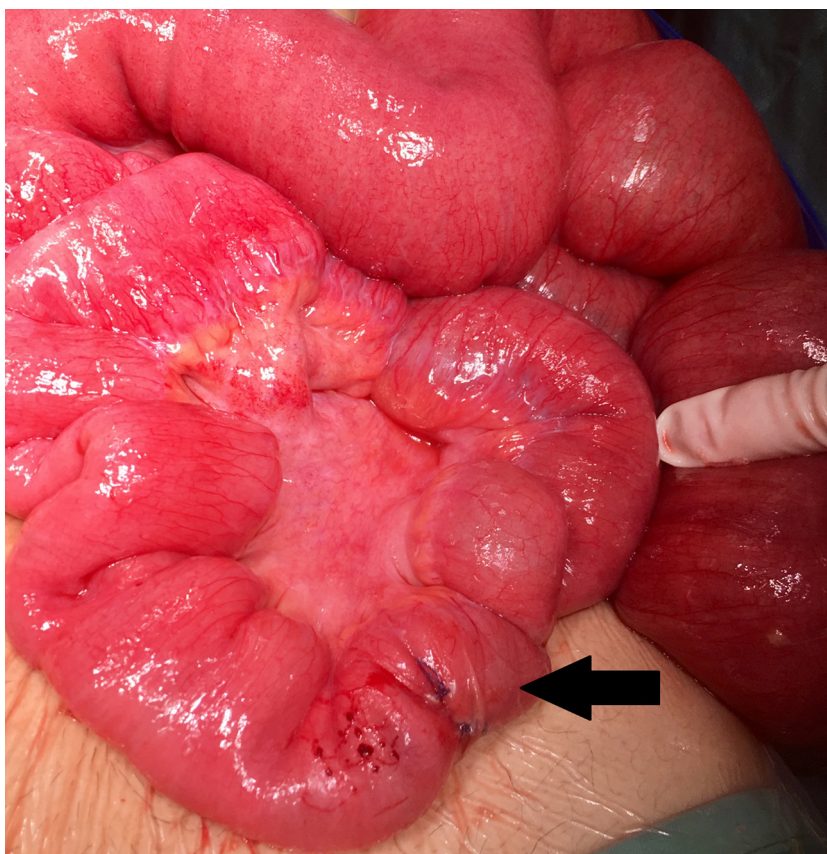

Fig 3. Enterotomy site revealed as lead point after reduction (arrow).

3. Discussion

In the adult population, unlike the pediatric population [5], postoperative intussusception causing bowel obstruction is considered to be a rare entity, although some authors report an incidence of 2.5% [6].

The pathogenesis of all forms of intussusception is both children and adults remains unknown. What was first considered to be the result of abnormal peristalsis is now thought to be caused by focal abnormality of the bowel wall. Theory suggests these two possible causes; a functionally noncontractile segment of bowel wall such as an indurated lesion, flaccid segment or sudden change in caliber, or a process leading to mechanical linkage of two nonadjacent segments of bowel, intraluminal (eg, pedunculated polyps) or extraluminal (eg, adhesions). Under these circumstances during peristalsis a kink in the bowel wall is formed at the abnormal site and contraction of the bowel around it causes intussusception led by the abnormal segment [7].

As opposed to sporadic adult intussusception in which an anatomical lesion has been reported in 70–90% of cases, more commonly in the small intestine [8], in postoperative cases usually no lead point is found; Sarr et al. [7] reported that out of 73 cases of adult intussusception in a 25-year period, 34% occurred postoperatively, most in the early postoperative period (median at 5th post-operative day). The jejunum was the most common site, with suture lines and postoperative adhesions being the most common etiology. Of the five post-operative intussusceptions in their series which were directly related to suture lines, two followed jejunostomy closure and three followed exclusion bypass of the right colon with blind ileal stumps. No intussusception occurred after an end to end enteric anastomosis. More recent reports describe postopera-

tive intussusception with suture lines as the clear lead point mainly after gastrojejunostomy or roux and y gastric bypass [2,3].

Diagnosis of postoperative intussusception in adults is elusive. The triad of colicky abdominal pain, currant jelly stool and palpable abdominal mass is rarely present and symptoms of mechanical obstruction can be delayed for up to two weeks [7,9]. Presentation may change from acute surgical emergency to chronic post prandial pain. Abdominal CT is considered to be the most useful radiologic method in the diagnosis of intussusception in adults [1,10], classically featuring a “target” or “sausage” sign. While some reports suggest a preoperative diagnosis of intestinal intussusception by CT to be as low as 40–50% [11], other state that it can be helpful in determining the etiology of the intussusception, the presence of a mass, its relation with other structures, staging in case of malignancy and even the necessity for emergent surgery versus conservative treatment in case no lead point is found [12].

Management of this postoperative complication usually requires resection of the intussuscepted bowel in adults; however the extent of resection is debatable. Reduction and limited resection is considered safe for benign lesions [8]. The goal of this approach is to limit the extent of resection and to avoid a risk of short bowel syndrome. In addition, for enteric intussusception with a benign cause this approach resulted in virtually no recurrence [13]. If the cause for intussusception is suspicious for malignancy or unknown, resection of the entire intussuscepted bowel should be considered. Malignancy is present in up to 30% of cases of small bowel intussusception in adults and can be as high as 66% in the large bowel. Therefore, in case of ileocecal, ileocolic and colo-colic intussusception, especially in adults over 60 years of age, formal oncologic resection is advised [10,14].

In our patient, there was no concern for malignancy and the intussusceptum was 50 cm long. Since the patient was already mal-

nourished, there was great concern about the outcome of resecting such a long segment of small bowel and so a limited resection of the lead point only was performed.

We cannot fully determine what incited this rare phenomena in our patient as opposed to others undergoing similar procedures. Previous theories regarding “abnormal motility” of the small bowel as a cause of intussusception remain a subject for debate. Our patient indeed had a unique postoperative diet of juice alone after his first surgery, but we did not find any evidence supporting this as a cause of intussusception.

Lastly, at the time of the 2nd operation, the patient was in a catabolic state with a serum albumin level of 2 mg/dL. Interestingly, the enterotomy site was intact but the stomach, with its rich blood supply and good healing abilities, was the source of the leak. Hence, we can only assume that the gastrotomy site leak was a result of the high pressure in the obstructed small bowel and the vomiting that followed.

4. Conclusion

Postoperative intussusception with suture lines as a lead point is a rare but potentially dangerous complication, especially in the presence of a synchronous recent manipulation of GI tract lumen. Diagnosis requires a high index of suspicion since presentation in the adult may be variable and imaging studies are not always helpful. Since this entity has the potential of causing significant morbidity, a surgeon should be aware of this option when treating a patient postoperatively.

This work has been reported in line with the SCARE criteria [15].

Conflicts of interest

There is no conflict of interest.

Funding

Publication is funded by the department itself.

Ethical approval

As this is a case report, no ethical approval was needed in our institution.

Consent

Informed consent was obtained from the patient.

Author contribution

study concept and design - Moran Slavin.

data collection - Moran Slavin, Yaron Rudnicki, Roye Inbar, Patricia Malinge.

data analysis and interpretation - Moran Slavin, Shmuel Avital.

writing - Moran Slavin.

Registration of research studies

researchregistry2213.

Guarantor

Dr. Moran Slavin.

Prof. Shmuel Avital.

References

- [1] T. Azar, D.L. Berger, Adult intussusception, *Ann. Surg.* 226 (1997) 134–138.
- [2] M. Ishii, S. Teramoto, M. Yakabe, H. Yamamoto, Y. Yamaguchi, Y. Hanaoka, Y. Ouchi, Small intestinal intussusceptions caused by percutaneous endoscopic jejunostomy tube placement, *J. Am. Geriatr. Soc.* 55 (2007) 2093–2094.
- [3] L. Daellenbach, M. Suter, Jejunojunal intussusception after Roux-en-Y gastric bypass: a review, *Obes. Surg.* 21 (2) (2010) 253–263.
- [4] www.dictionary.com.
- [5] Y.Z. Bai, H. Chen, W.L. Wang, A special type of postoperative intussusception: ileoileal intussusception after surgical reduction of ileocolic intussusception in infants and children, *J. Pediatr. Surg.* 44 (4) (2009) 755–758.
- [6] J.C. Quatromoni, L.R. Rosoff, J.M. Halls, A.E. Yellin, Early postoperative small bowel obstruction, *Ann. Surg.* 191 (1980) 72–74.
- [7] M.G. Sarr, D.M. Nagorney, D.C. McIlrath, Postoperative intussusception in the adult: a previously unrecognized entity? *Arch. Surg.* 116 (1981) 144–148.
- [8] A. Marinis, A. Yiallourou, L. Samanides, N. Dafnios, G. Anastasopoulos, I. Vassiliou, T. Theodosopoulos, Intussusception in adults – a review, *World J. Gastroenterol.* 28 (4) (2009) 407–411 (15).
- [9] B.T. Kjellstom, C. Gortz, S. Nilsson, Adult idiopathic enteric intussusception in the postoperative period, *Eur. J. Surg.* 157 (1991) 359–360.
- [10] K. Takeuchi, Y. Tsuzuki, T. Ando, M. Sekihara, T. Hara, T. Kori, H. Kuwano, The diagnosis and treatment of adult intussusception, *J. Clin. Gastroenterol.* 36 (2003) 18–21.
- [11] L.K. Eisen, J.D. Cunningham, A.H. Aufses Jr., Intussusception in adults: institutional review, *J. Am. Coll. Surg.* 188 (1999) 390–395.
- [12] Y.H. Kim, M.A. Blake, M.G. Harisinghani, K. Archer-Arroyo, P.F. Hahn, M.B. Pitman, P.R. Mueller, Adult intestinal intussusception: CT appearances and identification of a causative lead point, *Radiographics* 26 (2006) 733–744.
- [13] L.T. Wang, C.C. Wu, J.C. Yu, C.W. Hsiao, C.C. Hsu, S.W. Jao, Clinical entity and treatment strategies for adult intussusceptions: 20 years' experience, *Dis. Colon Rectum* 50 (2007) 1941–1949.
- [14] D.G. Begos, A. Sandor, I.M. Modlin, The diagnosis and management of adult intussusception, *Am. J. Surg.* 173 (1997) 88–94.
- [15] R.A. Agha, A.J. Fowler, A. Saetta, I. Barai, S. Rajmohan, Orgill DP and the SCARE group: the SCARE statement: consensus-based surgical case report guidelines, *Int. J. Surg.* 34 (2016) 180–186.

Open Access

This article is published Open Access at sciedirect.com. It is distributed under the [IJSCR Supplemental terms and conditions](#), which permits unrestricted non commercial use, distribution, and reproduction in any medium, provided the original authors and source are credited.