

Case Report

Isolated ureteral injury following a stab wound: A case report

Sang Hyun Park^a, Ki Hoon Kim^{b,*}^a Department of Urology, Haeundae Paik Hospital, University of Inje College of Medicine, Busan, Republic of Korea^b Department of Surgery, Haeundae Paik Hospital, University of Inje College of Medicine, Busan, Republic of Korea

ARTICLE INFO

Keywords:

Ureteral injuries

Stab wounds

Uretero-ureterostomy

ABSTRACT

Ureteral injuries reportedly occur in 2–5% of gunshot wounds to the abdomen, and are even rarer in abdominal stab wounds. Ureteral injuries are usually silent and produce no early signs or symptoms. An unrecognized or mismanaged ureteral injury can lead to significant morbidity and mortality. A 34-year-old woman was transferred to our emergency department from another hospital after removal of a knife on her abdomen. She was diagnosed with isolated ureter injury. An uretero-ureterostomy was performed after stenting of the ureteral catheter. The postoperative course was uneventful, and the patient was discharged on postoperative day 12.

Introduction

Ureteral injuries represent 2.5% of genitourinary (GU) trauma; they are rare because of the ureter's small diameter and its protected retroperitoneal location [1]. The most common cause is iatrogenic trauma during open surgery, laparoscopy, or endoscopy. Ureteral injuries reportedly occur in 2–5% of gunshot wounds to the abdomen, and are even rarer in abdominal stab wounds [2,3]. Ureteral injuries are usually silent and produce no early signs or symptoms. Penetrating ureteral injuries are almost always associated with injuries to multiple organs such as the bowel and blood vessels or other GU injuries [4]. Few physicians have experience with ureteral trauma, as it is more difficult to diagnose isolated ureteral injury. An unrecognized or mismanaged ureteral injury can lead to significant complications including urinoma, abscess, ureteral stricture, and potential loss of the ipsilateral kidney or even death. Hereby, We report a case of isolated ureteral injury following a stab wound.

Case report

A 34-year-old woman was transferred to our emergency department from another hospital after removal of a knife from the right upper quadrant (RUQ) of her abdomen. She complained of tenderness in the entire abdomen. Her initial vital signs were stable, and we noticed a 5-cm laceration in her abdominal RUQ. She had been taking anti-insomnia drugs. Laboratory examination results were normal, except for an increased white blood count of 20,890/mm³. An abdominal computed tomography (CT) scan was performed and showed a hematoma around the site of the stab wound and right psoas muscle (Fig. 1). A simple abdominal radiograph at the bed-side was performed 15 min after the CT scan, which showed leakage of contrast material around the right ureter (Fig. 2). An emergency laparotomy was performed. There was a tear in the right rectus muscle, with active bleeding. Moreover, a ureter injury of nearly 50% of the ureter circumference was detected around the right psoas muscle, causing a hematoma that led me to suspect a stab wound (Fig. 3); however, no other organ injury was found. An uretero-ureterostomy was performed using a fine chromic catgut after

* Corresponding author at: Department of Surgery, Inje University Haeundae Paik hospital, 612-030, 1435, Jwa-dong, Haeundae-gu, Busan, Republic of Korea.

E-mail address: medhun@hanmail.net (K.H. Kim).

<https://doi.org/10.1016/j.tcr.2019.100197>

Accepted 7 April 2019

Available online 12 April 2019

2352-6440/ © 2019 The Authors. Published by Elsevier Ltd. This is an open access article under the CC BY-NC-ND license (<http://creativecommons.org/licenses/by-nc-nd/4.0/>).

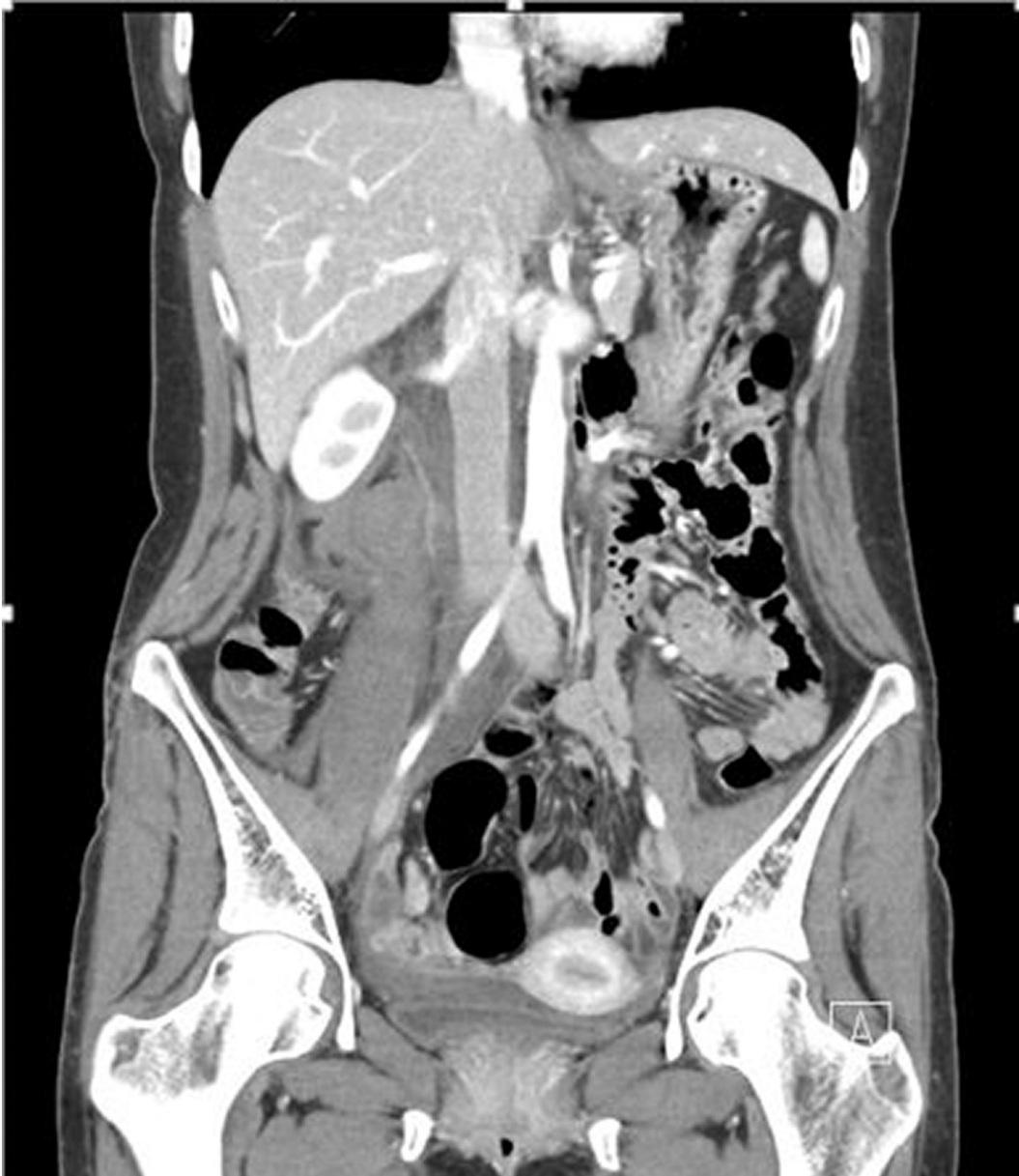

Fig. 1. Coronary CT finding. Showing hematoma around the site of the stab wound and right psoas muscle.

stenting of the ureteral catheter. The postoperative course was uneventful except for focal flank pain, and the patient was discharged on postoperative day 12. Two weeks after discharge, the patient visited the outpatient clinic due to right flank pain. Abdominal CT scan was performed, and massive liquefaction of the hematoma was observed in the injured area of the right psoas muscle. The flank area pain subsided after drainage was performed using a percutaneous catheter. At two months post-surgery, intravenous pyelography was performed, and the double-J stent was removed.

Discussion

In the diagnosis of ureteral injury, there are no classic signs and symptoms; moreover, hematuria, which is the hallmark of any GU trauma, is not a reliable finding in ureteral injuries [5,6] Imaging studies are the most important diagnostic tools available to evaluate for ureteral injury. A retrograde pyelography (RGP) is the most accurate imaging test to evaluate the location and extent of the ureteral injury; however, RGP is time consuming and cumbersome [7]. Thus, it is difficult to perform in the acute trauma setting [4]. RGP is most commonly used to diagnose missed ureteral injuries, because it allows the simultaneous placement of a ureteral stent if possible. Recently, the use of ultrasound has gained widespread use in trauma situations. However, it has proven unreliable in

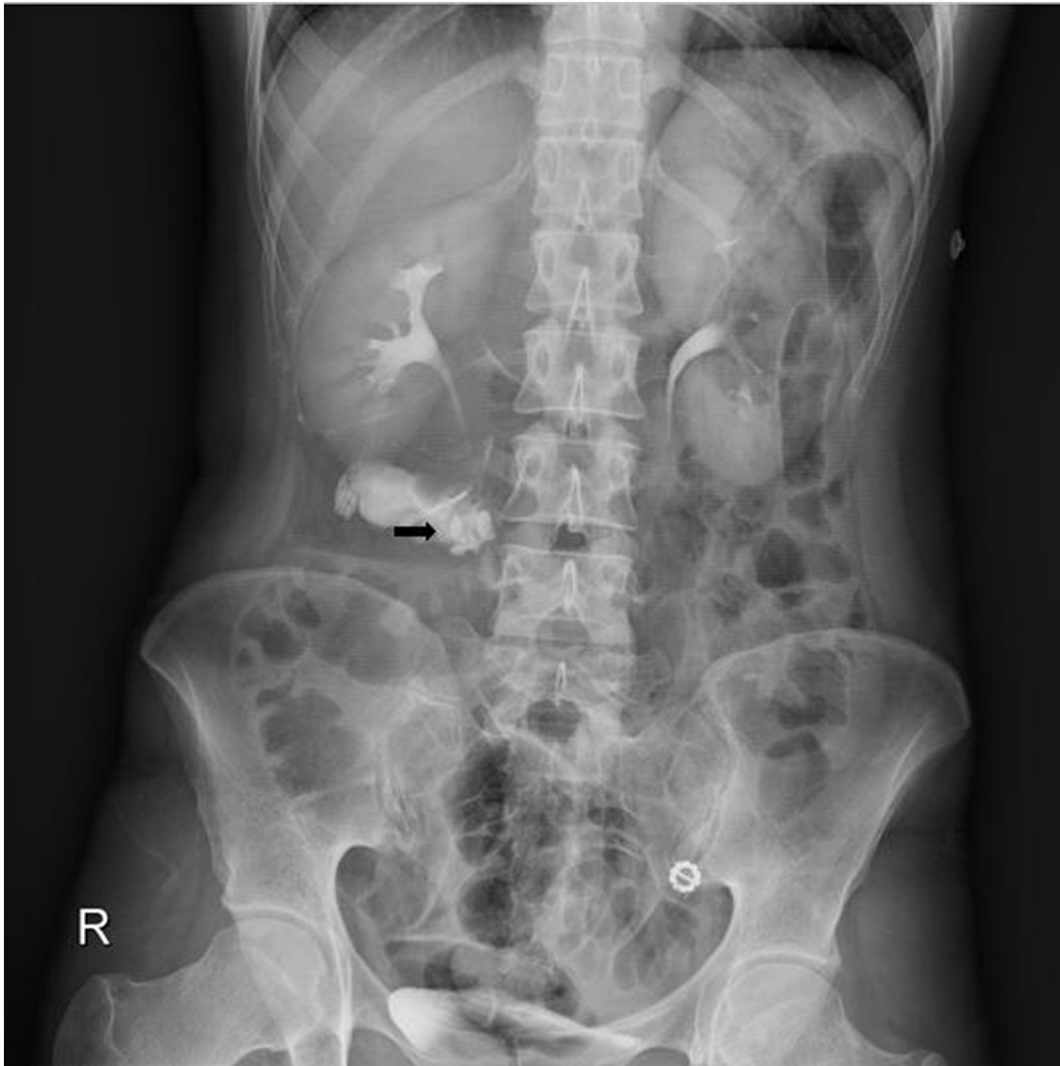


Fig. 2. Simple abdominal X-ray after computed tomography. Showing leakage of contrast around the right ureter (black arrow).

evaluating ureteral injuries, particularly because of the small caliber and retroperitoneal location of the ureters. With the availability of CT scanning and its sensitivity, contrast-enhanced CT has been the recent diagnostic modality of choice [8,9]. Identification of ureteral injuries require a delay of 5–10 min after the administration of intravenous contrast to allow the contrast to reach the ureter [10,11]. Approximately 80% of injuries can be missed on initial CT and are detected only on delayed CT imaging. Ureteral injury can be visualized on CT, including the presence of contrast extravasation from the ureter, non-visualization of the ureter, ipsilateral hydronephrosis, and poor renal excretion localized to one side [12,13]. Therefore, in case of a hemodynamically stable patient, CT can be useful to diagnose the ureteral injury. The AUA trauma guidelines recommend performing abdominopelvic CT with intravenous contrast and delayed scans for all stable patients with suspected ureteral trauma [14]. If there is poor renal excretion of intravenous contrast at 10 min, repeated scans at a later interval may be necessary although it may cause more radiation exposure. However, in an acute trauma state, especially in a patient who is hemodynamically unstable or whose condition is variable, the timing of early resuscitation is very important. Therefore, it may be dangerous to keep the patient for 5–10 min in the CT room for gaining the delayed CT image. My hospital has a protocol wherein CT scan takes only up to 70 s in a trauma case and a simple abdomen radiograph can be checked at the bed-side approximately 10–15 min later. In this case, the initial CT scan showed no evidence of ureteral injury, but a subsequent simple abdominal radiograph showed contrast leakage at the right side.

The primary goal for repair is to maintain renal drainage. Management options depend on the site of injury, extent of the devitalized ureter, and concomitant injuries. The basic surgical principals include a tension-free anastomosis, debridement of devitalized tissues, spatulation of each end, and water-tight anastomosis. We use absorbable sutures (5–0 PDS) with the use of ureteral stent.

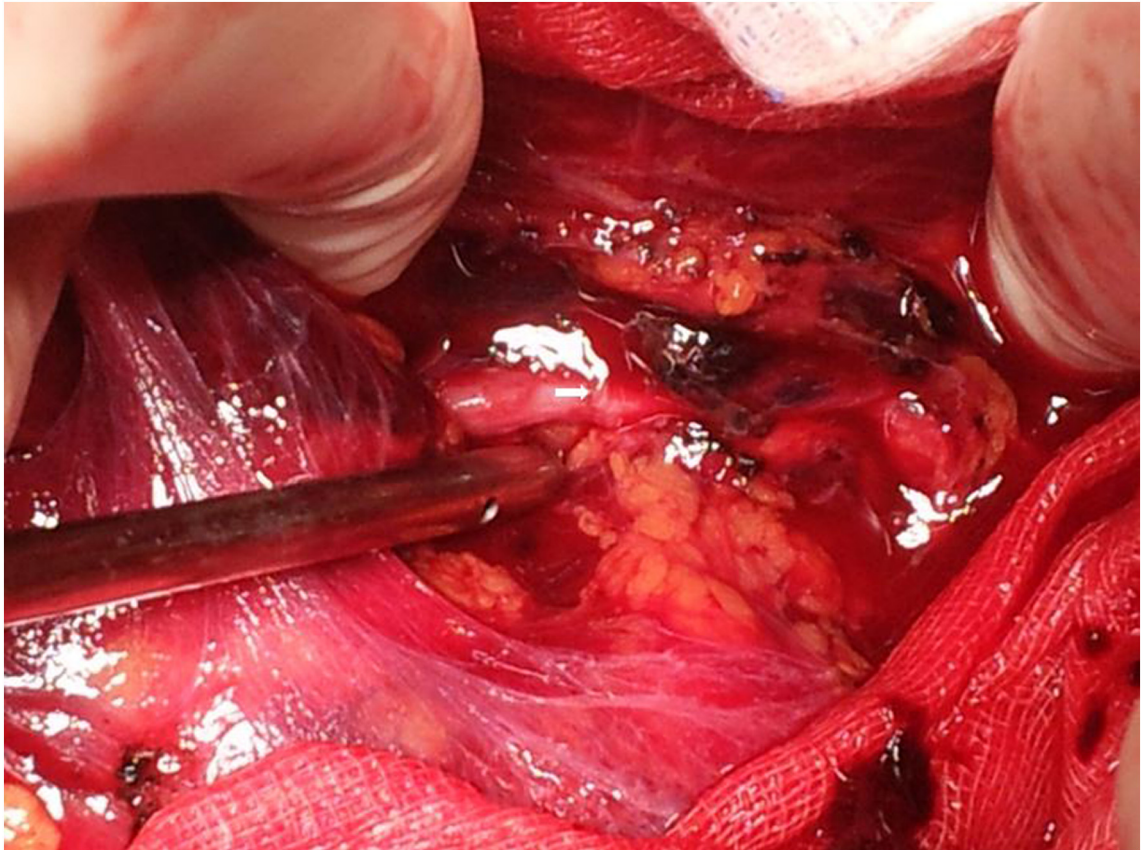


Fig. 3. Intraoperative finding. A ureter injury was identified (white arrow).

Conclusion

The incidence of ureter injury is rare because of the ureter's small diameter and its protected retroperitoneal location; however, a delayed diagnosis or misdiagnosis can be associated with a high level of morbidity or mortality. Although abdominal organ injuries may not occur in a stab wound, isolated ureter injury might occur. Subsequent abdominal radiographs after computed tomography might be useful for detection of ureteral injury. If there is a structural injury around the ureter, the suspicion of ureteral injury is necessary. The course of action should be determined keeping in mind the best interest of the patient.

Consent

Written informed consent was obtained from the patient and his wife for publication of this case report and accompanying images.

Conflict of interest

The authors declare no conflict of interest.

Funding

This research did not receive any specific grant from funding agencies in the public, commercial, or not-for-profit sectors.

Authors' contributions

KKH has made substantial contributions to conception and design. KKH and PSH wrote the paper. PSH checked bibliographic reference. KKH had primary responsibility for the content. Both authors read and approved the final manuscript.

References

- [1] S.M. Siram, S.Z. Gerald, E.R. Greene, K. Hughes, T.A. Oyetunji, K. Chrouser, et al., Ureteral trauma: patterns and mechanisms of injury of an uncommon condition, *Am. J. Surg.* 199 (4) (2010) 566–570.
- [2] C. Bent, T. Iyngkaran, N. Power, M. Matson, T. Hajdinjak, N. Buchholz, et al., Urological injuries following trauma, *Clin. Radiol.* 63 (12) (2008) 1361–1371.
- [3] K. Al-Awadi, E.O. Kehinde, A. Al-Hunayan, A. Al-Khayat, Iatrogenic ureteric injuries: incidence, aetiological factors and the effect of early management on subsequent outcome, *Int. Urol. Nephrol.* 37 (2) (2005) 235–241.
- [4] S. Brandes, M. Coburn, N. Armenakas, J. McAninch, Diagnosis and management of ureteric injury: an evidence-based analysis, *BJU Int.* 94 (3) (2004) 277–289.
- [5] T.H. Lynch, L. Martinez-Pineiro, E. Plas, E. Serafetinides, L. Turkeri, R.A. Santucci, et al., EAU guidelines on urological trauma, *Eur. Urol.* 47 (1) (2005) 1–15.
- [6] L.S. Palmer, R.R. Rosenbaum, M.D. Gershbaum, E.R. Kreutzer, Penetrating ureteral trauma at an urban trauma center: 10-year experience, *Urology* 54 (1) (1999) 34–36.
- [7] E.W. Campbell Jr., P.S. Filderman, S.C. Jacobs, Ureteral injury due to blunt and penetrating trauma, *Urology* 40 (3) (1992) 216–220.
- [8] P.J. Kenney, D.M. Panicek, L.S. Witanowski, Computed tomography of ureteral disruption, *J. Comput. Assist. Tomogr.* 11 (3) (1987) 480–484.
- [9] M. Townsend, A.J. DeFalco, Absence of ureteral opacification below ureteral disruption: a sentinel CT finding, *AJR Am. J. Roentgenol.* 164 (1) (1995) 253–254.
- [10] S.L. Brown, D.M. Hoffman, J.P. Spirnak, Limitations of routine spiral computerized tomography in the evaluation of blunt renal trauma, *J. Urol.* 160 (1998) 1979–1981.
- [11] J.M. Mulligan, I. Cagiannos, J.P. Collins, S.F. Millward, Ureteropelvic junction disruption secondary to blunt trauma: excretory phase imaging (delayed films) should help prevent a missed diagnosis, *J. Urol.* 159 (1) (1998) 67–70.
- [12] B.S. Carver, C.B. Bozeman, D.D. Venable, Ureteral injury due to penetrating trauma, *South. Med. J.* 97 (5) (2004) 462–464.
- [13] S.J. Ortega, F.S. Netto, P. Hamilton, P. Chu, H.C. Tien, CT scanning for diagnosing blunt ureteral and ureteropelvic junction injuries, *BMC Urol.* 8 (2008) 3.
- [14] A.F. Morey, S. Brandes, D.D. Dugi 3rd, J.H. Armstrong, B.N. Breyer, J.A. Broghanner, et al., Urotrauma: AUA guideline, *J. Urol.* 192 (2) (2014) 327–335.