

Application of a Customized Total Talar Prosthesis for Revision Total Ankle Arthroplasty

Shigeki Morita, MD, Akira Taniguchi, MD, PhD, Takuma Miyamoto, MD, Hiroaki Kurokawa, MD, PhD, and Yasuhito Tanaka, MD, PhD

Investigation performed at the Department of Orthopedic Surgery, Nara Medical University, Nara, Japan

Background: The rate of revision surgery for total ankle arthroplasty (TAA) is higher than for hip and knee arthroplasties. Tibiotalocalcaneal arthrodesis is widely used; however, it requires a large allograft. Thus, the use of a customized total talar prosthesis in combination with the tibial component of TAA (combined TAA) may be an effective strategy for talar component subsidence. This study aimed to evaluate the clinical and radiographic effectiveness of the combined TAA in such revision cases.

Methods: Between 2000 and 2015, 10 patients (10 women; 10 ankles) were treated using the combined TAA for revision after standard TAA or combined procedures that included the use of a talar body prosthesis. In 6 patients, the tibial component was concurrently replaced. The median follow-up period was 49 months (interquartile range [IQR], 24.5 to 90 months). The Japanese Society for Surgery of the Foot (JSSF) ankle-hindfoot scale score, a numerical rating scale (NRS) pain score, passive range of motion of the ankle, and the presence of osteophytes and degenerative changes in the adjacent joints were assessed preoperatively and at final postoperative follow-up.

Results: The median NRS pain score improved significantly, from 7 (IQR, 6.25 to 8.75) to 2 (IQR, 1 to 3). The median JSSF ankle-hindfoot scale total score improved significantly, from 64 (IQR, 56.25 to 71.5) to 88.5 (IQR, 79.75 to 96). In the subcategories of this scale, the median pain score improved from 20 (IQR, 20 to 27.5) to 35 (IQR, 30 to 40), and the median function score improved from 34 (IQR, 26.5 to 37) to 43.5 (IQR, 39.75 to 46). The median range of motion improved from 29° (IQR, 25.5° to 35°) to 35° (IQR, 31.25° to 43.75°). No significant difference in osteophyte formation was found. Degenerative changes in the adjacent joint were found only in the talonavicular joint.

Conclusions: The combined TAA, used in revision for postoperative complications after standard TAA or combined procedures including the use of a talar body prosthesis, was associated with improved objective JSSF ankle-hindfoot scale scores, subjective pain assessment, and range of motion in the ankle.

Level of Evidence: Therapeutic Level IV. See Instructions for Authors for a complete description of levels of evidence.

Surface replacement models are commonly used for total ankle implants. However, the blood supply to the talus is fundamentally poor because a large portion of its surface is covered with articular cartilage, predisposing the structure to fragility and subsidence under the talar component after total ankle arthroplasty (TAA)¹⁻³. Furthermore, the ankle is located in the lower position of the load axis and is often affected by trauma and sprains. In cases of severe collapse under the talar component, tibiotalocalcaneal (TTC) arthrodesis is often performed as a salvage procedure. However, a large amount of bone is required for harvest to refill the bone defects, and long-

term immobilization with a cast is usually necessary⁴⁻⁸. Pseudoarthrosis may eventually occur⁴. To treat these formidable complications, an unconventional approach is required that does not compromise ankle function.

In 1999, an alumina ceramic talar prosthesis was developed for patients with a collapsed talus due to osteonecrosis^{9,10}. The first-generation implant was designed as a talar body prosthesis with a peg for cement fixation to the talar neck; however, loosening was identified around the fixation site in some cases. Therefore, the peg was removed to avoid loosening around the fixation site in the second-generation implant. Often, the

Disclosure: The authors indicated that no external funding was received for any aspect of this work. The **Disclosure of Potential Conflicts of Interest** forms are provided with the online version of the article (<http://links.lww.com/JBJSOA/A213>).

Copyright © 2020 The Authors. Published by The Journal of Bone and Joint Surgery, Incorporated. All rights reserved. This is an open-access article distributed under the terms of the [Creative Commons Attribution-Non Commercial-No Derivatives License 4.0](https://creativecommons.org/licenses/by-nc-nd/4.0/) (CCBY-NC-ND), where it is permissible to download and share the work provided it is properly cited. The work cannot be changed in any way or used commercially without permission from the journal.

remaining talar head would burst, depending on the compression force from the talar body prosthesis. Subsequent to these complications, the total talar prosthesis was developed in 2005, and satisfactory results have been reported since then^{9,11}. This implant replaces the whole talus.

We hypothesized that the use of a total talar prosthesis in combination with the tibial component used in TAA (combined TAA) would be an effective strategy for subsidence under the talar component after TAA (Fig. 1). However, the efficacy of the combined TAA is unknown. Therefore, the purpose of this case series was to validate the clinical and radiographic effectiveness of the combined TAA in such revision cases.

Materials and Methods

This study was approved by the institutional review board of our hospital, and written informed consent was obtained from all study participants. Between 2000 and 2015, 254 patients who had ankle osteoarthritis were treated with TAA using the TNK ankle system (Kyocera), and 29 patients were treated with an artificial talar body prosthesis (Kyocera) at our institution. Of these, 9 patients required revision surgery because of notable collapse of the talus. Of the 9 patients, 5 had been treated using

TAA and 4 had been treated using the combination of a talar body prosthesis and the tibial component of the TNK ankle implant. There was an additional patient with subsidence under the talar component after TAA, which had been performed at another hospital. In total, 10 patients (10 women; 10 ankles) were enrolled in this case series (6 who had undergone TAA and 4 who had replacement using a talar body prosthesis).

Of the 6 cases that underwent revision following TAA, the reason for revision was loosening and subsidence around both the tibial and talar components in 4 cases and subsidence around the talar component only in 2 cases. Of the 4 cases that underwent revision after replacement using a talar body prosthesis, the reason for revision was loosening and subsidence around both the tibial and talar components in 2 cases and subsidence around the talar component only in 2 cases. In 4 of the 10 cases, only the talar component was replaced at the time of revision with a total talar implant, whereas in the remaining 6 cases, both the talar and tibial components were replaced (Figs. 2 and 3).

For the production of the artificial talus, the relevant dimensions were measured on radiographs and computed tomography (CT) scans of the contralateral, normal talus. The CT images were made at 2-mm intervals in the axial and sagittal planes, and a 3-dimensional wire model and implant were assembled. Then, a stereolithographic model was cast, and from that, an alumina ceramic prosthesis was produced¹¹. The anterior approach was used for the combined TAA. The articular surface of the tibia was osteotomized, and then the talus was cut in its neck. The body of the talus was cut in the coronal plane along with dissection of the attaching ligament or joint capsule. After the insertion of the artificial talar prosthesis, the peg hole was made in the distal part of the tibia, and then the tibial component was placed¹². Polyethylene was set to the tibial component in the TNK ankle system such that it could not be replaced anteriorly; in the case of catastrophic damage, it would be necessary to revise the whole tibial component. A remarkable lucent zone around the tibial component or inclination medially or laterally were indications for revision of the tibial component.

One patient had rheumatoid arthritis. The median age of the patients was 67 years (interquartile range [IQR], 61.5 to 78.8 years), and the median follow-up period was 49 months (IQR, 24.5 to 90 months). The Japanese Society for Surgery of the Foot (JSSF) ankle-hindfoot scale^{13,14}, consisting of subcategories for pain, function, and alignment, was used for the objective evaluation pre- and postoperatively. Pain was also subjectively assessed using a numerical rating scale (NRS). Pain severity was graded from 0 (no pain) to 10 (the worst pain ever). Passive range of motion of the ankle in dorsiflexion and plantar flexion was measured using a goniometer (FRIGZ Medico Japan), and we compared these preoperative and postoperative values. Range of motion of the ankle was measured by a blinded orthopaedic foot surgeon who was not involved in the surgery.

To evaluate how degenerative changes occurred in the affected joints after combined TAA, we investigated changes in the osteophyte formation as well as degenerative changes in the adjacent joints. The presence of osteophytes and degenerative

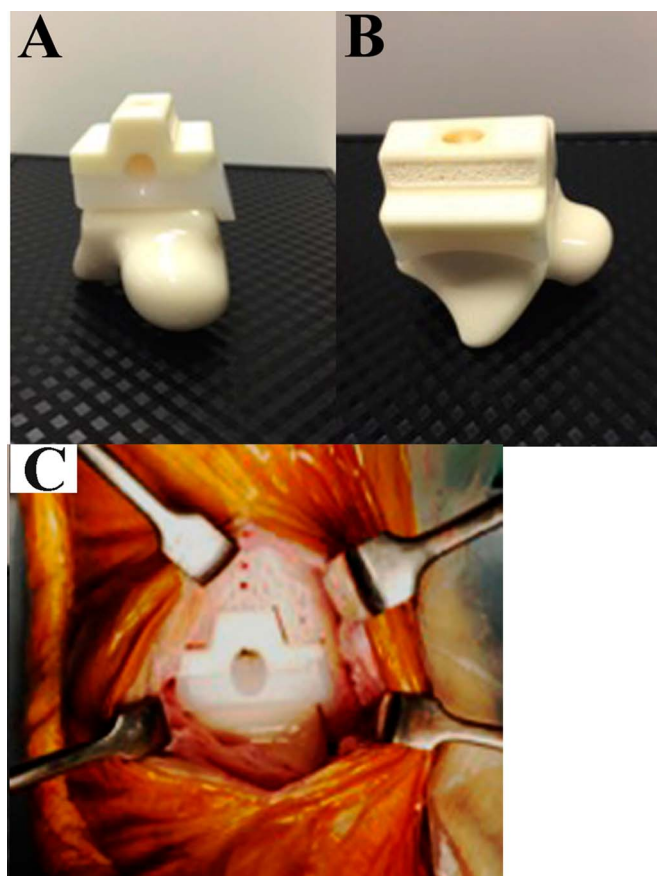


Fig. 1
Example of a custom-made total talar prosthesis with the tibial component of the TNK ankle implant, viewed from the front (Fig. 1-A), from the side (Fig. 1-B), and in position when placed in the ankle (Fig. 1-C).

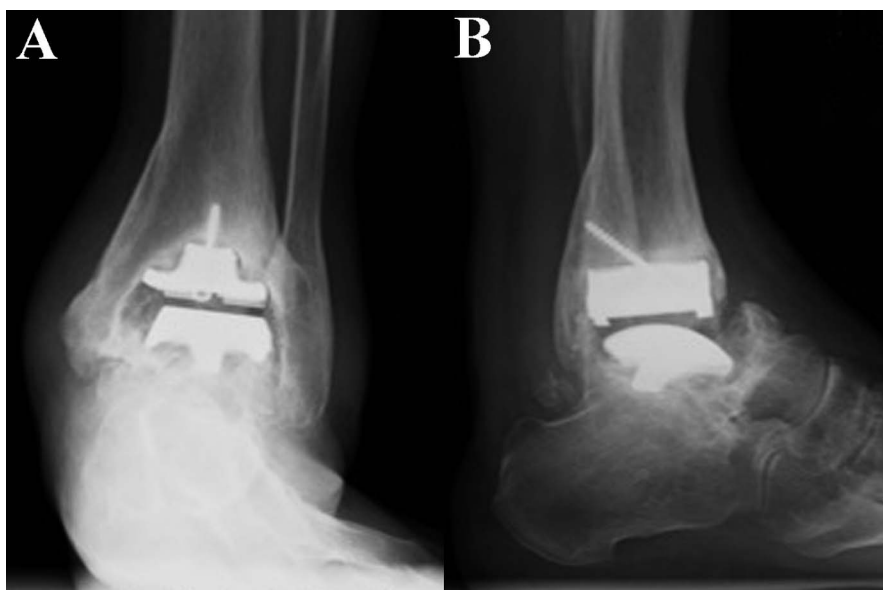


Fig. 2
Radiographs made prior to revision, 5 years after implantation of a TNK ankle prosthesis. Note the subsidence of the talar component and loosening around the tibial component. **Fig. 2-A** Anteroposterior view. **Fig. 2-B** Lateral view.

changes in the talonavicular and subtalar joints were assessed using weight-bearing lateral radiographs preoperatively and at the final postoperative follow-up. No evidence of osteophytes was scored as 0, and the proliferation of osteophytes was scored as 1. No evidence of degenerative change was scored as 0, osteosclerotic change in the subchondral bone was scored as 1, joint-space narrowing or partial disappearance of the joint space was scored as 2, and disappearance of the entire joint space was scored as 3 (Table I). All radiographic evaluations

were performed by a blinded orthopaedic foot surgeon who was not involved in the surgery.

Statistical Analysis

The JSSF ankle-hindfoot scale scores, NRS scores, osteophyte formation, and degenerative changes in the talonavicular and subtalar joints were compared between the preoperative and final follow-up time points; for the comparisons at these 2 time points, a Wilcoxon signed-rank test was used for the JSSF

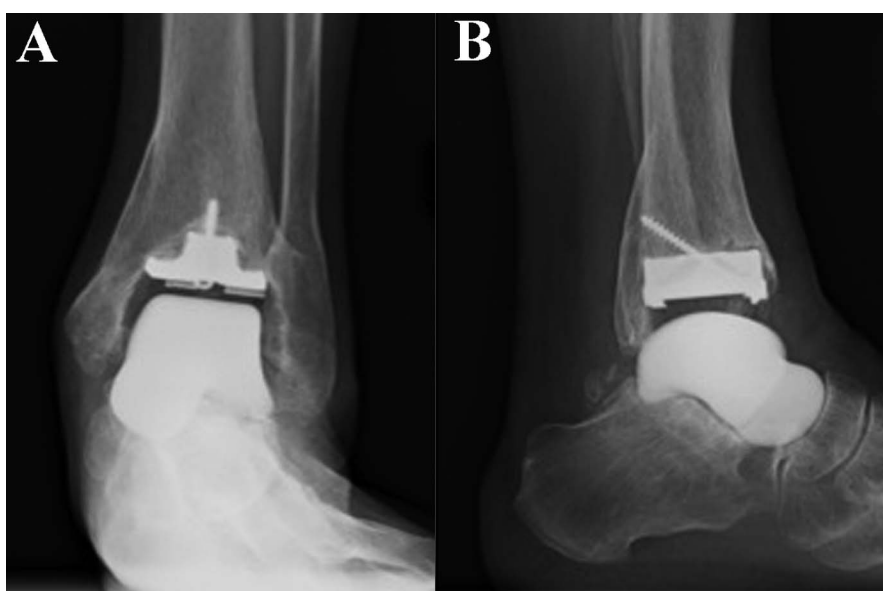


Fig. 3
Postoperative radiographs 3 years after the combined TAA. **Fig. 3-A** Anteroposterior view. **Fig. 3-B** Lateral view.

TABLE I Scoring of the Radiographic Findings

Radiographic Assessment	Points
Osteophyte formation	
No osteophyte	0
Proliferation of osteophytes	1
Degenerative change	
No degenerative change	0
Osteosclerotic change	1
Joint-space narrowing or partial disappearance of the joint space	2
Disappearance of the entire joint space	3

TABLE II Comparison of NRS Scores for Pain and the JSSF Ankle-Hindfoot Scale Scores Preoperatively and at Final Follow-up*

	Median (IQR)	P Value
NRS for pain		0.011†
Preop.	7 (6.25-8.75)	
Final follow-up	2 (1-3)	
JSSF ankle-hindfoot scale		0.0059†
Pain		
Preop.	20 (20-27.5)	
Final follow-up	35 (30-40)	
Function		0.0076†
Preop.	34 (26.5-37)	
Final follow-up	43.5 (39.75-46)	
Alignment		‡
Preop.	10 (10-10)	
Final follow-up	10 (10-10)	
Total score		0.0076†
Preop.	64 (56.25-71.5)	
Final follow-up	88.5 (79.75-96)	
Range of motion (°)		0.018†
Preop.	29 (25.5-35)	
Final follow-up	35 (31.25-43.75)	

*NRS = numerical rating scale, JSSF = Japanese Society for Surgery of the Foot, and IQR = interquartile range. †The scores improved significantly ($p < 0.05$). ‡Statistical analysis could not be performed because the results were the same preoperatively and at final follow-up.

ankle-hindfoot scale scores and the NRS scores, a Fisher exact probability test was used to compare the data regarding osteophytes in the adjacent joints, and a Mann-Whitney U test was used to compare the data regarding degenerative changes in the adjacent joints. A p value of < 0.05 was considered significant. All statistical analyses were carried out using Statcel 4 (version 4; OMS Publishing).

Results

The median NRS score for pain improved significantly, from 7 (IQR, 6.25 to 8.75) preoperatively to 2 (IQR, 1 to 3) postoperatively ($p = 0.011$). The median total score for the JSSF ankle-hindfoot scale also improved significantly, from 64 (IQR, 56.25 to 71.5) preoperatively to 88.5 (IQR, 79.75 to 96) postoperatively ($p = 0.0076$). In the subcategories of this scale, the median pain score improved significantly from 20 (IQR, 20 to 27.5) preoperatively to 35 (IQR, 30 to 40) postoperatively ($p = 0.0059$), and the median function score also improved significantly, from 34 (IQR, 26.5 to 37) preoperatively to 43.5 (IQR, 39.75 to 46) postoperatively ($p = 0.0076$). Median range of motion improved significantly from 29° (IQR, 25.5° to 35°) preoperatively to 35° (IQR, 31.25° to 43.75°) postoperatively ($p = 0.018$) (Table II). The median score for osteophyte formation in the subtalar joint, both preoperatively and at final follow-up, was 1 (IQR, 0 to 1). Regarding osteophyte formation in the talonavicular joint, the median score, both preoperatively and at final follow-up, was 0 (IQR, 0 to 0) (Table III). Regarding degenerative changes in the talonavicular joint, the preoperative median score was 0 (IQR, 0 to 0.75), and the postoperative median score was 1 (IQR, 1 to 1). These results revealed the progression of degenerative changes in the talonavicular joint

TABLE III Comparison of Osteophyte Formation Preoperatively and at Final Follow-up

	Median (IQR)*	P Value
Osteophyte formation		
Subtalar joint		0.675
Preop.	1 (0-1)	
Final follow-up	1 (0-1)	
Talonavicular joint		0.576
Preop.	0 (0-0)	
Final follow-up	0 (0-0)	

*IQR = interquartile range.

TABLE IV Comparison of Degenerative Changes Preoperatively and at Final Follow-up

	Median (IQR)*	P Value
Degenerative changes		
Subtalar joint		‡
Preop.	1 (1-1)	
Final follow-up	1 (1-1)	
Talonavicular joint		0.0012‡
Preop.	0 (0-0.75)	
Final follow-up	1 (1-1)	

*IQR = interquartile range. †Statistical analysis could not be performed because the results were the same preoperatively and at the final follow-up. ‡The scores improved significantly ($p < 0.05$).

($p = 0.0012$), whereas the preoperative and postoperative median scores for degenerative changes in the subtalar joint were both 1 (IQR, 1 to 1) (Table IV). In terms of postoperative complications, 1 patient had gastroparesis; no other complications were observed.

Discussion

Our findings suggest that revision TAA using the described combined TAA is an effective technique that can contribute to the improvement of clinical outcomes, with excellent pain relief and regained range of ankle motion. To our knowledge, there have been no reports on this novel treatment approach thus far, making this study of clinical importance despite the small sample size.

The TNK ankle is a 2-component semiconstrained type of total ankle implant, developed in 1975. The first-generation model was designed to include a polyethylene tibial implant and a stainless steel talar implant. In 1980, the second-generation model was produced to improve implant survival; alumina ceramic implants and polyethylene inserts were utilized¹⁵. Bone cement was used to fix both implants to the bone. Clinical results improved; however, in approximately half of the cases, the outcomes were unsatisfactory. The third-generation implant was produced in 1991, featuring screw holes in the tibial component and cement beads mounted on the surface facing the osteotomy site for the initial stability and bone bonding. These improvements in the implant and surgical techniques gave rise to markedly improved clinical results; nevertheless, approximately 7.5% of the patients still required revision surgery¹⁶. After TAA, revision surgery is always challenging because of poor bone stock in the talus; nevertheless, the revision rate of TAA is relatively high compared with that of hip or knee arthroplasties because the ankle joint is located in the lower part of the extremity and is frequently exposed to trauma¹⁷. Several complications, including infection, pain, instability, dislocation, and fracture, as well as component loosening, have been reported¹⁸. In a series reported on by Gross et al.¹⁸, 92% of the patients had loosening under the talar component. In patients with severe collapse under the talar component, it is difficult to revise the joint using ready-made implants.

TTC arthrodesis⁴, with a large allograft, has been used in these cases. Thomason and Eyres⁵ reported having salvaged 3 failed cases after TAA using TTC arthrodesis with allografts from the femoral head, with bone union attained in all cases. Ali et al.⁶ reported an 87% union rate after salvage TTC arthrodesis for failed TAA. The most formidable complication is restricted range of motion in the ankle and hindfoot. Kamrad et al. evaluated the clinical results of 118 cases treated with hindfoot arthrodesis compared with 70 cases that had been treated with revision TAA following failure of primary TAA (from among a total of 1,110 primary TAA cases). A low postoperative functional score and a <50% rate of satisfaction were reported for arthrodesis¹⁹. Rahm et al. reported a low score of 40 points for the function subscale of the Short Form (SF)-36 in 23 cases of hindfoot arthrodesis as salvage surgery following primary TAA⁷.

Artificial talar prostheses were developed to treat large osseous defects of the talus caused by idiopathic talar necrosis^{9,11}. Indications for the use of the total talar prosthesis, in

combination with the tibial component, have been extended to TAA^{12,20}. This combination has the potential to address unfavorable complications after TAA. Ketz et al.²¹ reported on a customized total ankle implant with a long stem that was inserted into the talus. Although favorable results were reported, motion in the subtalar joint was diminished. Wagener et al.²² performed a salvage procedure on patients with subsidence under the talar component with the HINTEGRA ankle system (Newdeal) using customized talar implants. Nevertheless, their implant was designed as a talar body prosthesis and was made of stainless steel, with a relatively high risk of loosening at the fixation site and degenerative changes in the adjacent joint. According to Yoshinaga²³, alumina ceramic has a higher affinity for articular cartilage than 316L stainless steel, which was confirmed using customized hip implants in dogs. Alumina ceramic is an ideal material for artificial talar implants because it is surrounded by adjacent bones on all sides⁹, and it prevents leg-length discrepancy when combined with the total ankle implant even in patients with severe collapse of the talus after primary total ankle replacement²⁰. Our findings suggest that the combined TAA may decrease pain and restore the ability to perform activities of daily living by preserving hindfoot range of motion and stability. In a case with a catastrophic complication, tibiocalcaneal fusion with allograft would be indicated. In our case series, such a case with a severe complication requiring revision after this procedure was not seen.

This study had several limitations. The first is the small number of subjects. Nevertheless, investigations into any rare complications are of relevance, despite a small sample size. Second is the short-term follow-up. In particular, adjacent-joint involvement should be evaluated for longer periods. TAA is performed less frequently than total hip or knee arthroplasties, and postoperative complications can be devastating for some patients. The versatility of the combined TAA for revision surgery after TAA was indicated by our findings.

In conclusion, the combined TAA used in revision for postoperative complications after standard TAA or combination procedures using the talar body prosthesis improved objective JSSF ankle-hindfoot scale scores, subjective pain assessments, and range of motion in the ankle. ■

Shigeki Morita, MD¹
Akira Taniguchi, MD, PhD¹
Takuma Miyamoto, MD¹
Hiroaki Kurokawa, MD, PhD¹
Yasuhito Tanaka, MD, PhD¹

¹Department of Orthopedic Surgery, Nara Medical University, Nara, Japan

ORCID iD for S. Morita: [0000-0003-4452-0481](https://orcid.org/0000-0003-4452-0481)
ORCID iD for A. Taniguchi: [0000-0002-3507-0426](https://orcid.org/0000-0002-3507-0426)
ORCID iD for T. Miyamoto: [0000-0002-8504-2706](https://orcid.org/0000-0002-8504-2706)
ORCID iD for H. Kurokawa: [0000-0003-1208-8508](https://orcid.org/0000-0003-1208-8508)
ORCID iD for Y. Tanaka: [0000-0002-2300-611X](https://orcid.org/0000-0002-2300-611X)

References

1. Li SY, Myerson MS. Management of talar component subsidence. *Foot Ankle Clin.* 2017 Jun;22(2):361-89. Epub 2017 Mar 31.
2. Mulfinger GL, Trueta J. The blood supply of the talus. *J Bone Joint Surg Br.* 1970 Feb;52(1):160-7.
3. Oppermann J, Franzen J, Spies C, Faymonville C, Knifka J, Stein G, Bredow J. The microvascular anatomy of the talus: a platination study on the influence of total ankle replacement. *Surg Radiol Anat.* 2014 Jul;36(5):487-94. Epub 2013 Oct 27.
4. Urquhart MW, Mont MA, Michelson JD, Krackow KA, Hungerford DS. Osteonecrosis of the talus: treatment by hindfoot fusion. *Foot Ankle Int.* 1996 May;17(5):275-82.
5. Thomason K, Eyres KS. A technique of fusion for failed total replacement of the ankle: tibio-allograft-calcanal fusion with a locked retrograde intramedullary nail. *J Bone Joint Surg Br.* 2008 Jul;90(7):885-8.
6. Ali AA, Forrester RA, O'Connor P, Harris NJ. Revision of failed total ankle arthroplasty to a hindfoot fusion: 23 consecutive cases using the Phoenix nail. *Bone Joint J.* 2018 Apr 1;100-B(4):475-9.
7. Rahm S, Klammer G, Benninger E, Gerber F, Farshad M, Espinosa N. Inferior results of salvage arthrodesis after failed ankle replacement compared to primary arthrodesis. *Foot Ankle Int.* 2015 Apr;36(4):349-59. Epub 2014 Nov 6.
8. Halverson AL, Goss DA Jr, Berlet GC. Ankle arthrodesis with structural grafts can work for the salvage of failed total ankle arthroplasty. *Foot Ankle Spec.* 2020 Apr;13(2):132-7. Epub 2019 Apr 22.
9. Taniguchi A, Takakura Y, Sugimoto K, Hayashi K, Ouchi K, Kumai T, Tanaka Y. The use of a ceramic talar body prosthesis in patients with aseptic necrosis of the talus. *J Bone Joint Surg Br.* 2012 Nov;94(11):1529-33.
10. Tanaka Y, Takakura Y, Kadono K, Taniguchi A, Hayashi K, Iida Z, Sugimoto K, Tohma Y, Ohgushi H. Alumina ceramic talar body prosthesis for idiopathic aseptic necrosis of the talus. *Key Eng Mater.* 2003 May;240-242:805-8.
11. Taniguchi A, Takakura Y, Tanaka Y, Kurokawa H, Tomiwa K, Matsuda T, Kumai T, Sugimoto K. An alumina ceramic total talar prosthesis for osteonecrosis of the talus. *J Bone Joint Surg Am.* 2015 Aug 19;97(16):1348-53.
12. Kurokawa H, Taniguchi A, Morita S, Takakura Y, Tanaka Y. Total ankle arthroplasty incorporating a total talar prosthesis: a comparative study against the standard total ankle arthroplasty. *Bone Joint J.* 2019 Apr;101-B(4):443-6.
13. Niki H, Aoki H, Inokuchi S, Ozeki S, Kinoshita M, Kura H, Tanaka Y, Noguchi M, Nomura S, Hatori M, Tatsunami S. Development and reliability of a standard rating system for outcome measurement of foot and ankle disorders I: development of standard rating system. *J Orthop Sci.* 2005 Sep;10(5):457-65.
14. Niki H, Aoki H, Inokuchi S, Ozeki S, Kinoshita M, Kura H, Tanaka Y, Noguchi M, Nomura S, Hatori M, Tatsunami S. Development and reliability of a standard rating system for outcome measurement of foot and ankle disorders II: interclinician and intraclinician reliability and validity of the newly established standard rating scales and Japanese Orthopaedic Association rating scale. *J Orthop Sci.* 2005 Sep;10(5):466-74.
15. Takakura Y, Tanaka Y, Kumai T, Sugimoto K, Ohgushi H. Ankle arthroplasty using three generations of metal and ceramic prostheses. *Clin Orthop Relat Res.* 2004 Jul;(424):130-6.
16. Tanaka Y, Takakura Y. [The TNK ankle: short- and mid-term results]. *Orthopade.* 2006 May;35(5):546-51. German.
17. Labek G, Thaler M, Janda W, Agreiter M, Stöckl B. Revision rates after total joint replacement: cumulative results from worldwide joint register datasets. *J Bone Joint Surg Br.* 2011 Mar;93(3):293-7.
18. Gross C, Erickson BJ, Adams SB, Parekh SG. Ankle arthrodesis after failed total ankle replacement: a systematic review of the literature. *Foot Ankle Spec.* 2015 Apr;8(2):143-51. Epub 2015 Jan 5.
19. Kamrad I, Henricson A, Magnusson H, Carlsson Å, Rosengren BE. Outcome after salvage arthrodesis for failed total ankle replacement. *Foot Ankle Int.* 2016 Mar;37(3):255-61. Epub 2015 Nov 18.
20. Tsukamoto S, Tanaka Y, Maegawa N, Shinohara Y, Taniguchi A, Kumai T, Takakura Y. Total talar replacement following collapse of the talar body as a complication of total ankle arthroplasty: a case report. *J Bone Joint Surg Am.* 2010 Sep 1;92(11):2115-20.
21. Ketz J, Myerson M, Sanders R. The salvage of complex hindfoot problems with use of a custom talar total ankle prosthesis. *J Bone Joint Surg Am.* 2012 Jul 3;94(13):1194-200.
22. Wagener J, Gross CE, Schweizer C, Lang TH, Hintermann B. Custom-made total ankle arthroplasty for the salvage of major talar bone loss. *Bone Joint J.* 2017 Feb;99-B(2):231-6.
23. Yoshinaga K. Replacement of femoral head using endoprosthesis (alumina ceramics vs metal)—an experimental study of canine articular cartilage. *Nihon Seikeigeka Gakkai Zasshi.* 1987 May;61(5):521-30.