

Staple Line Coverage with a Polyglycolic Acid Patch and Fibrin Glue without Pleural Abrasion after Thoracoscopic Bullectomy for Primary Spontaneous Pneumothorax

Ki Pyo Hong, M.D., Ph.D., Do Kyun Kim, M.D., Kyung Hoon Kang, M.D.

Background: This study was conducted to determine the efficacy of staple line coverage using a polyglycolic acid patch and fibrin glue without pleural abrasion to prevent recurrent postoperative pneumothorax. **Methods:** A retrospective analysis was carried out of 116 operations performed between January 2011 and April 2013. During this period, staple lines were covered with a polyglycolic acid patch and fibrin glue in 58 cases (group A), while 58 cases underwent thoracoscopic bullectomy only (group B). **Results:** The median follow-up period was 33 months (range, 22 to 55 months). The duration of chest tube drainage was shorter in group A (group A 2.7 ± 1.2 day vs. group B 3.9 ± 2.3 day, $p=0.001$). Prolonged postoperative air leakage occurred more frequently in group B than in group A (43% vs. 19%, $p=0.005$). The postoperative recurrence rate of pneumothorax was significantly lower in group A (8.6%) than in group B (24.1%) ($p=0.043$). The total cost of treatment during the follow-up period, including the cost for the treatment of postoperative recurrent pneumothorax, was not significantly different between the two groups ($p=0.43$). **Conclusion:** Without pleural abrasion, staple line coverage with a medium-sized polyglycolic acid patch and fibrin glue after thoracoscopic bullectomy for primary spontaneous pneumothorax is a useful technique that can reduce the duration of postoperative pleural drainage and the postoperative recurrence rate of pneumothorax.

Key words: 1. Pneumothorax
2. Thoracoscopy
3. Polyglycolic acid
4. Fibrin tissue adhesive

INTRODUCTION

The surgical treatment of primary spontaneous pneumothorax (PSP) is conducted to close air leakage and prevent recurrence. Thoracoscopic bullectomy is generally considered the standard treatment of PSP, and is advantageous because it has been associated with decreased postoperative pain and improved cosmetic outcomes in comparison to open thoracotomy; however, the postoperative recurrence rate after

thoracoscopic bullectomy has been found to be much higher than the rate of recurrence observed after open thoracotomy procedures [1-5].

Several additional procedures, such as pleural abrasion, partial pleurectomy, and chemical pleurodesis, have been performed after thoracoscopic bullectomy to reduce the recurrence rate of postoperative pneumothorax and prolonged air leakage. Although these procedures have yielded good results for preventing postoperative recurrence, they can induce

Department of Thoracic and Cardiovascular Surgery, National Health Insurance Service Ilsan Hospital

Received: February 12, 2016, Revised: February 23, 2016, Accepted: March 8, 2016, Published online: April 5, 2016

Corresponding author: Ki Pyo Hong, Department of Thoracic and Cardiovascular Surgery, National Health Insurance Service Ilsan Hospital, 100 Ilsan-ro, Ilsandong-gu, Goyang 10444, Korea
(Tel) 82-31-900-0632 (Fax) 82-31-900-0343 (E-mail) kipyoh@yahoo.co.kr

© The Korean Society for Thoracic and Cardiovascular Surgery. 2016. All right reserved.

© This is an open access article distributed under the terms of the Creative Commons Attribution Non-Commercial License (<http://creativecommons.org/licenses/by-nc/4.0>) which permits unrestricted non-commercial use, distribution, and reproduction in any medium, provided the original work is properly cited.

Table 1. Patient characteristics

Variable	Group A (n=58)	Group B (n=58)	p-value
Sex			0.569
Male	52 (89.7)	50 (86.2)	
Female	6 (10.3)	8 (13.8)	
Age (yr)	22.2±8.3 (range, 15-48)	20.5±6.7 (range, 13-41)	0.221
Body mass index (kg/m ²)	18.9±2.1	19.6±2.5	0.103
Pneumothorax site			0.192
Left	30 (49.1)	23 (35.6)	
Right	28 (50.9)	35 (64.4)	

Values are presented as number (%) or mean±standard deviation.

additional postoperative chest pain and increase the risk of morbidity, including hematoma, hemothorax, or tight pleural adhesion that can cause difficulties for subsequent thoracic surgery [6-11]. Moreover, pleural abrasion shows a wide range of recurrence rates because the procedure is not standardized [6-10].

Therefore, researchers have sought to develop an effective post-thoracoscopic bullectomy procedure that is nonaggressive and is not associated with morbidity. Recently, staple line coverage with absorbable mesh has been found to be useful for preventing the postoperative recurrence of pneumothorax and prolonged air leakage around the staple line after thoracoscopic bullectomy. Although various absorbable materials, such as fleece-coated fibrin glue, Vicryl mesh, and polyglycolic acid (PGA) patches, have been used to cover staple lines and have been associated with good results [12-16], the reports published so far in the literature have not discussed covering staple lines with a medium-sized PGA patch and fibrin glue without pleural abrasion.

In this study, we retrospectively investigated the effectiveness of staple line coverage with a medium-sized PGA patch and fibrin glue without pleural abrasion in preventing postoperative recurrent pneumothorax after thoracoscopic bullectomy.

METHODS

This study was approved by the institutional review board of the National Health Insurance Service Ilsan Hospital (2012-17).

1) Patients

From January 2011 to April 2013, 174 cases of thoraco-

scopic bullectomy for spontaneous pneumothorax were performed in our hospital. Fifty-eight cases from the initial study population were excluded. The following criteria were used to exclude patients from this study: (1) prior ipsilateral thoracoscopic bullectomy; (2) a history of pulmonary tuberculosis; (3) underlying chronic underlying pulmonary disease, such as emphysema; and (4) prior chemical pleurodesis. A single operation on one side was counted as one case, and the patients were divided into two groups based the procedures that they underwent. The 56 patients in group A underwent 58 thoracoscopic bullectomies in which the staple line was covered with an absorbable medium-sized PGA patch (Neoveil, 10×5 cm; Gunze, Kyoto, Japan) and fibrin glue (Beriplast-P combiset 1 mL; CSL Behring GmbH, Marburg, Germany). In group B, 56 patients underwent 58 bullectomies without any additional procedures. The patient characteristics are presented in Table 1.

2) Surgical indications

Surgical treatment of primary spontaneous pneumothorax was offered when patients exhibited: (1) ipsilateral or contralateral recurrent pneumothorax, (2) persistent air leakage (lasting for more than five days), (3) definite bullae that were detected on a chest X-ray or multiple bullae on a computed tomography scan, (4) simultaneous bilateral spontaneous pneumothorax, or (5) spontaneous hemopneumothorax (Table 2).

Each patient referred to the corresponding author with a diagnosis of primary spontaneous pneumothorax underwent thoracoscopic bullectomy and the staple line was covered with an absorbable medium-sized PGA patch (Neoveil, 10×5 cm; Gunze) and fibrin glue (Beriplast-P Combiset 1 mL, CSL Behring GmbH) if they satisfied the operation criteria. The

Table 2. Operative indications

Indication	Group A (n=58)	Group B (n=58)	p-value
Recurrent pneumothorax			0.12
Ipsilateral	24 (41.4)	29 (50.0)	
Contralateral	6 (10.3)	2 (3.4)	
Persistent air leak	28 (48.3)	24 (41.4)	
Simultaneous bilateral pneumothorax	0	3 (5.2)	

Values are presented as number (%).

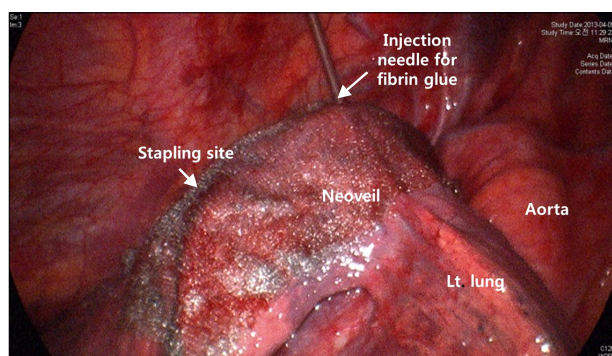


Fig. 1. Intraoperative findings. The staple line was covered with a medium-sized polyglycolic acid patch after application of the thrombin solution, followed by a fibrin solution that was dripped along the staple line.

other consecutive patients referred to the other two surgeons with a diagnosis of primary spontaneous pneumothorax underwent thoracoscopic bullectomy without any additional procedures if they satisfied the operation criteria.

3) Operative procedures

The operative procedures for thoracoscopic surgery were as follows. All patients received general anesthesia and were intubated with a double-lumen endotracheal tube to allow selective contralateral ventilation. The patients were placed in the lateral decubitus position. Three trocars (5 mm or 10 mm, and 12 mm) were inserted into the affected side of the thoracic wall. All detectable bullae were resected with endoscopic staplers under thoracoscopy. A sealing test was not performed after bullectomy. After gently scrubbing the visceral pleura around the staple line with a sponge on a stick, a thrombin solution (Beriplast-P Combiset 1 mL, CSL Behring GmbH) was dripped along the staple line. Next, a medium-sized PGA patch (Neoveil, 10×5 cm; Gunze) was inserted into the pleu-

ral cavity via an access port and placed on the staple line. Then, fibrin solution (Beriplast-P Combiset 1 mL, CSL Behring GmbH) was dripped onto the PGA patch along the staple line to fix it onto the visceral pleura (Fig. 1). No additional chemical or mechanical pleurodesis was performed. After coagulation of the bleeding from the trocar insertion holes, a 28-Fr chest tube was inserted through a trocar insertion hole and the other trocar insertion holes were closed with sutures.

4) Postoperative chest tube management

Negative suction was applied immediately after the operation and maintained until chest tube removal. The chest tube was removed after cessation of air leakage, with drainage of less than 100 mL over the course of 24 hours, minimal fluctuations of the fluid level (≤ 10 cm) in the chest tube on coughing or deep breathing, and complete resolution of the pneumothorax.

5) Statistical analysis

All values in the text and tables are presented as means±standard deviation. The data were analyzed using IBM SPSS ver. 21.0 (IBM Co., Armonk, NY, USA). The unpaired t-test, chi-square test, and Fisher's exact test were used to evaluate between-group differences. All p-values <0.05 were considered to indicate statistical significance.

RESULTS

The preoperative characteristics of groups A and B are presented in Table 1. No significant differences were found in sex, age, body mass index, and pneumothorax site.

No instances of operative mortality occurred in either

Table 3. Treatments for postoperative recurrent pneumothorax

Treatment	Group A (n=58)	Group B (n=58)
Observation	0	7
High-concentration oxygen treatment	4	1
Closed thoracostomy	1	3
Wedge resection	-	3
Total	5	14

group. The median follow-up was 33 months (range, 22 to 55 months). In group A, the number of wedge resections was significantly larger than in group B (1.7±0.8 vs. 1.3±0.5, p=0.002).

The median duration of chest tube drainage was three days. Therefore, we defined postoperative prolonged air leakage as four or more days in this study. Prolonged postoperative air leakage occurred more frequently in group B (43% vs. 19%, p=0.005). The duration of chest tube drainage was shorter in group A (2.7±1.2 vs. 3.9±2.3, p=0.001).

The postoperative recurrence rate of pneumothorax was significantly lower in group A than in group B (8.6% vs. 24.1%, p=0.043). None of the patients in group A required another operation. In group B, a secondary operation was performed in three cases of postoperative recurrence (Table 3).

The cost of treatment for the first operation was higher in group A than group B (4,872,783±907,221 Korean won [KRW] vs. 4,340,798±1,227,584 KRW, p=0.01). However, the total cost of the treatment of pneumothorax in the follow-up period, including the cost of treating postoperative recurrent pneumothorax, was not significantly different between the two groups (5,122,839±1,559,805 KRW vs. 4,872,328±1,797,685 KRW, p=0.43).

DISCUSSION

Several procedures have been performed after thoracoscopic bullectomy to prevent the postoperative recurrence of pneumothorax. These procedures include pleural abrasion, apical pleurectomy, chemical pleurodesis, and staple line coverage with an absorbable patch. All of those procedures are intended to eventually accomplish pleural symphysis.

Pleural abrasion techniques show significant variability de-

pending on the operating surgeon. The scrubbing material, scrubbing intensity, and range of abrasion have not yet been standardized. As a result, in the literature, the recurrence rate after thoracoscopic bullectomy with pleural abrasion has been reported to range from 2.8% to 12.8% [6-10]. The guidelines published by the British Thoracic Society suggest that pleurectomy is slightly more advantageous than pleural abrasion, with recurrence rates of 0.4% after pleurectomy (n=752) and 2.3% after pleural abrasion (n=301) [17]. In addition, pleural abrasion may cause additional chest pain and a possible risk of hematoma or hemothorax.

Apical pleurectomy is an effective method of treating pleurodesis using a thoracoscopic approach [17]. However, pleurectomy requires a lengthy operation and is technically problematic [18,19]. In addition, it is associated with a higher risk of intraoperative bleeding and longer postoperative chest drainage [8].

Colt et al. [11] reported that talc poudrage for chemical pleurodesis was significantly superior to pleural abrasion. However, talc pleurodesis can induce severe postoperative chest pain and can cause tight pleural adhesions, even in lower portions of the lung, which can be difficult to dissect during future thoracic operations. In addition, talc pleurodesis may cause granuloma formation and decreased pulmonary function over the course of long-term follow-up [18]. Minocycline pleurodesis, another chemical pleurodesis option, was also found to induce severe postoperative pain despite a large dose of intrapleural lidocaine (400 mg) [8].

Recent attention has focused on synthetic bioresorbable systems. Staple line coverage with an absorbable patch has been reported to be an effective method for reducing the postoperative recurrence rate after thoracoscopic stapled bullectomy [12-16]. The high recurrence rate after thoracoscopic stapled bullectomy has been attributed to causal factors such as collapsed emphysematous bullae during unilateral ventilation and the insufficient observation of rarely diseased areas, inappropriate visualization of the diseased areas on the mediastinal side, and new bulla formation near the staple lines [13,15,20]. In contrast, postoperative air leakage occurs mainly along the staple lines, as a result of stapling difficulties, incomplete bullae resection, emphysematous changes in the resected area, or staple line crossing [21]. Therefore,

reinforcement of the visceral pleura around the staple line and a surgical focus on the site of bullectomy can prevent the postoperative recurrence of pneumothorax and air leakage. However, no evidence suggests that absorbable mesh and fibrin glue thicken and reinforce the normal pleura. According to Nakanishi [13], in a reoperation two years after placing mesh on the pleura, a proliferation of fibrous connective tissue between the pleurae, rather than a thickening of the pleura itself, was seen at the site where the absorbable mesh was patched with fibrin glue. The proliferation of fibrous connective tissue between the pleurae was proposed to have occurred as a result of foreign body-induced inflammatory reactions over several weeks, until the absorbable mesh melted and disappeared. Although the visceral pleura over the stapling site was not thickened after application of a PGA patch with fibrin glue, the proliferation of fibrous connective tissue between pleurae induced by a PGA patch reinforced the stapling site. Fibrin glue promotes the coagulation cascade and healing reaction at the staple line [22]. Fibrin glue has anti-adhesive activity but disappears between five and seven days after placement [22]. Therefore, fibrin glue may influence staple line healing and fix absorbable mesh to the visceral pleura during the early postoperative phase [13,22,23].

According to Haraguchi et al. [15] and Lee et al. [24], staple line coverage with a PGA patch in addition to pleural abrasion was found to be a useful method for preventing the postoperative recurrence of pneumothorax. However, the combination of these two procedures made it difficult to evaluate the effect of each procedure (PGA patch coverage vs. pleural abrasion), because each procedure can induce pleural symphysis. In addition, as mentioned previously, pleural abrasion is not a standardized procedure and can increase the risk of postoperative morbidity, such as hematoma, hemothorax, and additional postoperative chest pain. Therefore, we aimed to evaluate the effectiveness of staple line coverage using a PGA patch without pleural abrasion.

Sakamoto et al. [25] reported that wide coverage of the staple line with Vicryl mesh (15×15 cm) was effective in decreasing the incidence of recurrent postoperative pneumothorax and in preventing postoperative air leakage. Their study used a wide mesh that could be attached to the entire apex to further reduce postoperative recurrence. However,

new bullae were often found after bullectomy at the apical pleura near previous surgical margins that were stapled with automatic instruments [12]. Therefore, we hypothesized that a medium-sized PGA patch (Neoveil, 10×5 cm; Gunze) would be sufficient for staple line coverage to prevent the postoperative recurrence of pneumothorax and would be more manageable during thoracoscopic surgery than a wide mesh. Finally, fibrin glue (Berioplast-P combiset 1 mL, CSL Behring GmbH) was used to fix the PGA patch onto the visceral pleura.

In this study, the number of wedge resections in group A was significantly larger than in group B. The rate of postoperative air leakage may increase in proportion to the number of wedge resections. However, the duration of postoperative chest tube drainage was significantly shorter in group A than group B. The rate of prolonged air leakage (for at least four days) was also significantly lower in group A than group B. These results show the effectiveness of staple line coverage with a PGA patch and fibrin glue after thoracoscopic bullectomy.

The postoperative recurrence rate of pneumothorax was significantly lower in the group that underwent staple line coverage with a PGA patch and fibrin glue than in the group that underwent thoracoscopic bullectomy without any additional procedures. This indicates that, without pleural abrasion or chemical pleurodesis, staple line coverage with a PGA patch and fibrin glue is a useful method for reducing the postoperative recurrence of pneumothorax without any additional postoperative morbidity.

Despite the shorter duration of chest tube drainage and the lower incidence of prolonged postoperative air leakage in group A, the cost of the first operation was higher in group A, because the PGA patch and fibrin glue are relatively expensive materials. However, the total cost for the treatment of pneumothorax in the follow-up period, including the cost for the treatment of postoperative recurrent pneumothorax, was not significantly different between the two groups due to a higher recurrence rate in group B. Considering the time cost and physical strain associated with readmission, staple line coverage with a PGA patch and fibrin glue can be considered a cost-effective and time-saving procedure.

In conclusion, staple line coverage with a medium-sized

PGA patch and fibrin glue after thoracoscopic bullectomy for PSP without pleural abrasion is a useful method for reducing the duration of postoperative pleural drainage and the postoperative recurrence rate of pneumothorax. However, this study was a non-randomized retrospective study and the number of cases was relatively small. Therefore, a large, prospective, randomized clinical study with a long-term follow-up period is required to confirm the clinical effectiveness of this technique in decreasing postoperative pneumothorax recurrence.

CONFLICT OF INTEREST

No potential conflict of interest relevant to this article was reported.

ACKNOWLEDGMENTS

This work was supported by the National Health Insurance Service Ilsan Hospital Research Grant (2012-17).

REFERENCES

1. Horio H, Nomori H, Fuyuno G, Kobayashi R, Suemasu K. *Limited axillary thoracotomy vs video-assisted thoracoscopic surgery for spontaneous pneumothorax*. *Surg Endosc* 1998; 12:1155-8.
2. Sawada S, Watanabe Y, Moriyama S. *Video-assisted thoracoscopic surgery for primary spontaneous pneumothorax: evaluation of indications and long-term outcome compared with conservative treatment and open thoracotomy*. *Chest* 2005;127:2226-30.
3. Kim KH, Kim HK, Han JY, Kim JT, Won YS, Choi SS. *Transaxillary minithoracotomy versus video-assisted thoracic surgery for spontaneous pneumothorax*. *Ann Thorac Surg* 1996;61:1510-2.
4. Sahn SA, Heffner JE. *Spontaneous pneumothorax*. *N Engl J Med* 2000;342:868-74.
5. Haraguchi S, Koizumi K, Hioki M, et al. *Postoperative recurrences of pneumothorax in video-assisted thoracoscopic surgery for primary spontaneous pneumothorax in young patients*. *J Nippon Med Sch* 2008;75:91-5.
6. Gossot D, Galetta D, Stern JB, et al. *Results of thoracoscopic pleural abrasion for primary spontaneous pneumothorax*. *Surg Endosc* 2004;18:466-71.
7. Huh U, Kim YD, Cho JS, I H, Lee JG, Lee JH. *The effect of thoracoscopic pleurodesis in primary spontaneous pneumothorax: apical parietal pleurectomy versus pleural abrasion*. *Korean J Thorac Cardiovasc Surg* 2012;45:316-9.
8. Chen JS, Hsu HH, Huang PM, et al. *Thoracoscopic pleurodesis for primary spontaneous pneumothorax with high recurrence risk: a prospective randomized trial*. *Ann Surg* 2012;255:440-5.
9. Park JS, Han WS, Kim HK, Choi YS. *Pleural abrasion for mechanical pleurodesis in surgery for primary spontaneous pneumothorax: is it effective?* *Surg Laparosc Endosc Percutan Tech* 2012;22:62-4.
10. Moreno-Merino S, Congregado M, Gallardo G, et al. *Comparative study of talc poudrage versus pleural abrasion for the treatment of primary spontaneous pneumothorax*. *Interact Cardiovasc Thorac Surg* 2012;15:81-5.
11. Colt HG, Russack V, Chiu Y, et al. *A comparison of thoracoscopic talc insufflation, slurry, and mechanical abrasion pleurodesis*. *Chest* 1997;111:442-8.
12. Muramatsu T, Ohmori K, Shimamura M, Furuichi M, Takeshita S, Negishi N. *Staple line reinforcement with fleece-coated fibrin glue (TachoComb) after thoracoscopic bullectomy for the treatment of spontaneous pneumothorax*. *Surg Today* 2007;37:745-9.
13. Nakanishi K. *An apical symphyseal technique using a wide absorbable mesh placed on the apex for primary spontaneous pneumothorax*. *Surg Endosc* 2009;23:2515-21.
14. Saito T, Kaneda H, Konobu T, Saito Y. *The covering with forceps-assisted polymeric biodegradable sheet and endostapling method: a simplified technique for wide coverage and reinforcement of staple-line in video-assisted thoracoscopic bullectomy for spontaneous pneumothorax*. *Interact Cardiovasc Thorac Surg* 2011;12:103-5.
15. Haraguchi S, Koizumi K, Mikami I, et al. *Staple line coverage with a polyglycolic acid sheet plus pleural abrasion by thoracoscopic surgery for primary spontaneous pneumothorax in young patients*. *J Nippon Med Sch* 2012;79:139-42.
16. Lin XM, Liu Y, Chi C, Lin CX, Yang Y. *Efficacy of an absorbable polyglycolic acid patch in surgery for pneumothorax due to silicosis*. *J Cardiothorac Surg* 2012;7:18.
17. Henry M, Arnold T, Harvey J; *Pleural Diseases Group, Standards of Care Committee, British Thoracic Society*. *BTS guidelines for the management of spontaneous pneumothorax*. *Thorax* 2003;58 Suppl 2:ii39-52.
18. Chang YC, Chen CW, Huang SH, Chen JS. *Modified needlescopic video-assisted thoracic surgery for primary spontaneous pneumothorax: the long-term effects of apical pleurectomy versus pleural abrasion*. *Surg Endosc* 2006;20: 757-62.
19. Rena O, Massera F, Papalia E, Della Pona C, Robustellini M, Casadio C. *Surgical pleurodesis for Vanderschueren's stage III primary spontaneous pneumothorax*. *Eur Respir J* 2008;31:837-41.
20. Hatz RA, Kaps MF, Meimarakis G, Loehe F, Muller C,

Staple Line Coverage with Polyglycolic Acid Patch and Fibrin Glue after Thoracoscopic Bullectomy

- Furst H. *Long-term results after video-assisted thoracoscopic surgery for first-time and recurrent spontaneous pneumothorax.* Ann Thorac Surg 2000;70:253-7.
21. Busetto A, Moretti R, Barbaresco S, Fontana P, Pagan V. *Extrapleural bullectomy or lung volume reduction: air tight surgery for emphysema without strip-patch.* Acta Chir Hung 1999;38:15-7.
22. Toosie K, Gallego K, Stabile BE, Schaber B, French S, de Virgilio C. *Fibrin glue reduces intra-abdominal adhesions to synthetic mesh in a rat ventral hernia model.* Am Surg 2000;66:41-5.
23. Eriksen JR, Bech JJ, Linnemann D, Rosenberg J. *Laparoscopic intraperitoneal mesh fixation with fibrin sealant (Tisseel) vs. titanium tacks: a randomized controlled experimental study in pigs.* Hernia 2008;12:483-91.
24. Lee S, Park SY, Bae MK, et al. *Efficacy of polyglycolic acid sheet after thoracoscopic bullectomy for spontaneous pneumothorax.* Ann Thorac Surg 2013;95:1919-23.
25. Sakamoto K, Takei H, Nishii T, et al. *Staple line coverage with absorbable mesh after thoracoscopic bullectomy for spontaneous pneumothorax.* Surg Endosc 2004;18:478-81.