

Received: 2018.03.25  
Accepted: 2018.08.14  
Published: 2018.11.29

e-ISSN 1941-5923  
© Am J Case Rep, 2018; 19: 1422-1424  
DOI: 10.12659/AJCR.910196

## Rare Co-Existence of Amyand's and Littre's Hernia Treated with Appendectomy and Bowel Resection Followed by Polypropylene Mesh Application

Authors' Contribution:  
Study Design A  
Data Collection B  
Statistical Analysis C  
Data Interpretation D  
Manuscript Preparation E  
Literature Search F  
Funds Collection G

ABCDEF **Christoforos Kosmidis**  
DEF **Stylianos Mantalovas**  
E **Konstantinos Sapalidis**  
E **Charilaos Koulouris**  
EF **Georgios Koimtzis**  
E **Efstathios T. Pavlidis**  
E **Stefanos Atmatzidis**  
E **Nikolaos Michalopoulos**  
ABE **Isaac I. Kesisoglou**

3<sup>rd</sup> Department of Surgery, AHEPA University Hospital, Aristotle University of Thessaloniki, Medical School, Thessaloniki, Greece

**Corresponding Author:** Stylianos Mantalovas, e-mail: [steliosmantalobas@yahoo.gr](mailto:steliosmantalobas@yahoo.gr)

**Conflict of interest:** None declared

**Patient:** Male, 65  
**Final Diagnosis:** Rare co-existence of Amyand's and Littre's hernia  
**Symptoms:** Swelling  
**Medication:** —  
**Clinical Procedure:** Lichtenstein hernia repair  
**Specialty:** Surgery

**Objective:** Rare co-existence of disease or pathology

**Background:** Amyand's and Littre's hernias are 2 rare types of inguinal hernias, which constitute less than 1% of all types of hernias. Amyand's hernia is characterized mainly by the presence of a vermiform appendix in an inguinal hernia sac, whereas Littre's hernia includes a protrusion of a Meckel's diverticulum into the hernial sac.

**Case Report:** In this article, we report a case of co-existence of Amyand's and Littre's hernia in the same sac of a groin hernia. To the best of our knowledge, this is the first case report of a patient with the appendix and Meckel's diverticulum inside the hernia sac. Although there was no sign of inflammation, we performed an incidental appendectomy and partial enterectomy. We continued with the repair process with polypropylene mesh using Lichtenstein technique. The patients showed no signs of complication or recurrence of the hernia within 1 year from the day of the surgery.

**Conclusions:** The aim of this article is to present for the first time the occurrence and the repair of a combined Amyand's and Littre's hernia. Additionally, in this study, we were the first to use polypropylene mesh to repair both hernias in an elderly patient after performing appendectomy and enterectomy, avoiding any complications or recurrence of the hernia 12 months following the surgery.

**MeSH Keywords:** Appendicitis • Hernia, Inguinal • Polypropylenes

**Abbreviations:** Surg Endosc – surgical endoscopy; WSES – World Society of Emergency Surgery

**Full-text PDF:** <https://www.amjcaserep.com/abstract/index/idArt/910196>




1016



3



15



15

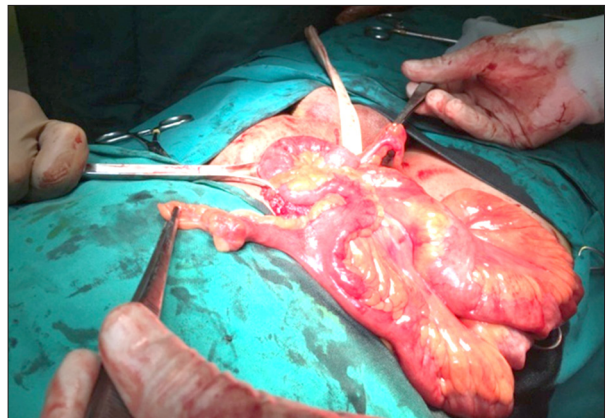


## Background

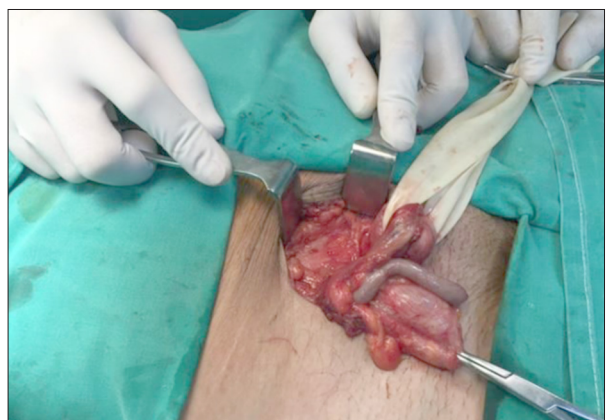
Amyand's hernia and Littre's hernia are 2 rare types of hernia. Amyand's hernia is a type of inguinal hernia, representing <1% of all inguinal hernias [1 2], it was first reported by British surgeon Claudius Amyand. He performed the first reported successful appendectomy on an 11-year-old boy by removing the perforated appendix from the right inguinal hernia sac [3–5]. Littre's hernia is another rare hernia, which contains Meckel's diverticulum, the most common congenital abnormality of the gastrointestinal tract [6]. Alexis Littre was the first to describe hernias containing intestinal diverticula, such as Meckel's diverticulum [7]. Both of these rare types of hernias – Amyand's and Littre's – constitute less than 1% of all types of hernias. The diagnosis is often difficult to confirm preoperatively; therefore, it is almost always found intraoperatively. The difficulties that a surgeon confronts during the treatment of these inguinal hernias include: 1) the performance of appendectomy (in the case of Amyand's) or an enterectomy (in the case of Littre's), and 2) the need to use tension-free mesh for the hernia repair. Therefore, the surgeon has to quickly decide which type of operation to perform.

## Case Report

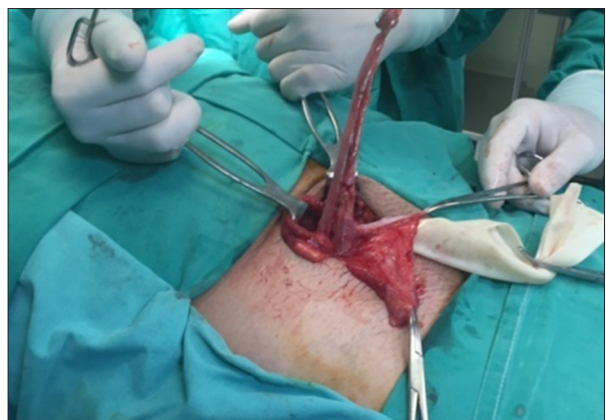The presented case was a 65-year-old patient who was diagnosed with a right-side inguinal hernia 10 years ago, without complaining about any inconvenience or pathological symptoms. He was a heavy smoker (1 pack/day) and occasionally social drinker, and he received medication for arterial hypertension (ramipril 5 mg 1×1) without experiencing any additional health problems. Based on Surgical Endoscopy guidelines (Surg Endosc 2015), the surgical team opted for an open approach because there was no recurrent inguinal hernia and the abdomen was 'hostile' because the patient had been submitted to laparoscopic cholecystectomy in the past [8]. During the operation, the content of the hernia sac was identified and the most intriguing finding was that it consisted of the appendix and Meckel's diverticulum. This indicates that the type of hernia was a combination of Amyand and Littre's hernia (Figure 1). After evaluating the macroscopic pathology of the appendix intraoperatively and taking into consideration the World Society of Emergency Surgery (WSES) Grading System [9], we came to the conclusion that there was no sign of inflammation in the appendix and the Meckel's diverticulum (Figures 2, 3). According to Losanoff and Basson guidelines [10,11], in the case of Amyand's hernias, the appendix must be removed in young patients regardless of the state of inflammation. Therefore, we decided to proceed with an appendectomy (Figure 3) and a partial enterectomy of the diverticulum with fully controlled conditions in order to avoid contamination that could spread the infection. After the appendectomy and the enterectomy



**Figure 1.** The appendix and the Meckel's diverticulum as contents of the hernia sac, a rare co-existence of Amyand's and Littre's hernia.



**Figure 2.** The appendix as a content of the hernia sac.



**Figure 3.** Surgical preparation for appendectomy by an inguinal incision.

were completed, the surgical field swab was conducted and the operation restored the hernia. In the above case, a polypropylene mesh was used according to Lichtenstein hernioplasty.

The patient was intraoperatively administered a single dose of the prophylactic antibiotic cefoxitin. He patient was discharged on the second postoperative day. At 12 months after the surgery, he shows no sign of complication or recurrence of the hernia.

## Discussion

Amyand's hernia and Littre's hernia are rare hernias accounting for <1% of all types of hernias [1,2,7]. D'Alia et al. reported that an inflamed appendix is even rarer than a normal appendix in a sac and determined that this proportion is about 0.08% [1]. Due to their rarity, only a few cases of these hernias have been described in the literature. The diagnosis based on the contents of the sac is almost always confirmed intraoperatively. In 1999 Weber et al. [10] confirmed the results of a previous report by Thomas [12] that only 1 of 60 patients is preoperatively diagnosed based on the contents of the sac. A difficulty arises when the surgeon must quickly decide whether to perform an appendectomy or a partial enterectomy and what technique to use for the hernia repair. According to recent international research papers, the decision depends upon the inflammation signs of the appendix or the Meckel's diverticulum and the macroscopic pathology of each of the specimens. In this respect, the decision is often individualized. According to Losanoff and Basson's guidelines modified by Signal and Gupta [13], in a case where there was an acute appendicitis, appendectomy must be performed without use of a mesh for repair of the hernia. If there is no inflammation, the decision is often difficult. Ofili et al. believed that in young patients, the appendix must be removed regardless of the sign of inflammation and thus insisted on incidental appendectomy. The probability of a patient with Amyand's hernia displaying acute appendicitis during the following years is higher than

in the general population. This is due to the pathophysiology of an Amyand's hernia, because the appendix in a sac is vulnerable to adhesions, microtraumas, and tissue ischemia [13]. On the other hand, the decision to use mesh after an appendectomy of a normal appendiceal specimen is up to the surgeon. Sharma et al. [15] argue that it is safe to repair a hernia after an appendectomy of a normal appendix with the use of a mesh. Our data are consistent with the above findings, since our cases were the first to use polypropylene mesh in elderly patients in absence of postoperative complications or recurrence [14,15]. The present case of hernia is of great scientific interest due to its rarity. Actually, the hernia sac contained both the appendix and Meckel's diverticulum. We performed an appendectomy and partial enterectomy with fully controlled conditions and we restored both of the hernias with the use of a polypropylene mesh and our patient had no complication or recurrence of the hernia at 1 year after the operation. Therefore, the present report is the first to describe a successful repair in a patient with combined Amyand's hernia and Littre's hernia.

## Conclusions

The data from our study present for the first time a case of a typical Amyand's hernia combined with Littre's hernia. Both the appendix and Meckel's diverticulum were resected despite the absence of any signs of inflammation or ischemia. The procedure continued with the placement of a mesh according to Lichtenstein's technique.

## Conflict of interest

None.

## References:

- D'Alia C, Lo Schiavo MG, Tonante A et al: Amyand's hernia: Case report and review of the literature. *Hernia*, 2003; 7: 89–91
- Kwok CM, Su CH, Kwang WK, YC: Amyand's hernia – case report and review of the literature. *Case Rep Gastroenterol*, 2007; 1: 65–70
- Komorowski AL, Moran Rodriguez J: Amyand's hernia. Historical perspective and current considerations. *Acta Chir Belg*, 2009; 109: 563–64
- Lauschke H, Kaminski M, Stratmann H, Hirner A: [Littre's hernia – clinical aspects and review of the history]. *Chirurg*, 1999; 70: 953–56 [in German]
- Milanchi S, Allins AD: Amyand's hernia: history, imaging, and management. *Hernia*, 2008; 12: 321–22
- Citgez B, Yetkin G, Uludag M et al: Littre's hernia, an incarcerated ventral incisional hernia containing a strangulated meckel diverticulum: Report of a case. *Surg Today*, 2011; 41: 576–78
- Mirza MS: Incarcerated Littre's femoral hernia: Case report and review of the literature. *J Ayub Med Coll Abbottabad*, 2007; 19: 60–61
- Bittner R, Montgomery MA, Arregu E et al: Update of guidelines on laparoscopic (TAPP) and endoscopic (TEP) treatment of inguinal hernia (International Endohernia Society). *Surg Endosc*, 2015; 29: 289–321
- Gomes CA, Sartelli M, Di Saverio S et al: Acute appendicitis: proposal of a new comprehensive grading system based on clinical, imaging and laparoscopic findings. *World J Emerg Surg*, 2015; 10: 60
- Losanoff JE, Basson MD: Amyand hernia: A classification to improve management. *Hernia*, 2008; 12: 325–26
- Weber G, Kassai M, Csontos Z et al: First Hungarian, internet-based prospective, multicenter study: The hernia-project. *Acta Chir Hung*, 1999; 38: 219–20
- Thomas WE, Vowles KD, Williamson RC: Appendicitis in external herniae. *Ann R Coll Surg Engl*, 1982; 64: 121–22
- Singal R, Gupta S: "Amyand's hernia" – pathophysiology, role of investigations and treatment. *Maedica (Buchar)*, 2011; 6: 321–27
- Ofili OP: Simultaneous appendectomy and inguinal herniorrhaphy could be beneficial. *Ethiop Med J*, 1991; 29: 37–38
- Sharma H, Gupta A, Shekhawat NS et al: Amyand's hernia: A report of 18 consecutive patients over a 15-year period. *Hernia*, 2007; 11: 31–35