



Since January 2020 Elsevier has created a COVID-19 resource centre with free information in English and Mandarin on the novel coronavirus COVID-19. The COVID-19 resource centre is hosted on Elsevier Connect, the company's public news and information website.

Elsevier hereby grants permission to make all its COVID-19-related research that is available on the COVID-19 resource centre - including this research content - immediately available in PubMed Central and other publicly funded repositories, such as the WHO COVID database with rights for unrestricted research re-use and analyses in any form or by any means with acknowledgement of the original source. These permissions are granted for free by Elsevier for as long as the COVID-19 resource centre remains active.

- Cosentini R, Brambilla AM, Aliberti S, Bignamini A, Nava S, Maffei A, et al. Helmet continuous positive airway pressure vs oxygen therapy to improve oxygenation in community-acquired pneumonia: a randomized, controlled trial. *Chest*. 2010;138:114–20. <http://dx.doi.org/10.1378/chest.09-2290>.
- Brambilla AM, Aliberti S, Prina E, Nicoli F, Del Forno M, Nava S, et al. Helmet CPAP vs. oxygen therapy in severe hypoxemic respiratory failure due to pneumonia [published correction appears in *Intensive Care Med*. 2014 Aug;40(8):1187]. *Intensive Care Med*. 2014;40:942–9. <http://dx.doi.org/10.1007/s00134-014-3325-5>.
- Paolini V, Faverio P, Aliberti S, Messinesi G, Foti G, Sibilo O, et al. Positive end expiratory pressure in acute hypoxemic respiratory failure due to community acquired pneumonia: do we need a personalized approach? *PeerJ*. 2018;6:e4211. <http://dx.doi.org/10.7717/peerj.4211>. Published 2018 Jan 30.

Francesco Amati<sup>a,b</sup>, Stefano Aliberti<sup>a,b,\*</sup>,  
Sofia Misuraca<sup>a,b</sup>, Edoardo Simonetta<sup>a,b</sup>,  
Francesco Bindo<sup>a,b</sup>, Annalisa Vigni<sup>a,b</sup>, Linda Bassi<sup>a,b</sup>,  
Alessandra Mazzucco<sup>b,c</sup>, Andrea Cara<sup>b,c</sup>, Francesco Blasi<sup>a,b</sup>

<sup>a</sup> *Fondazione IRCCS Ca' Granda Ospedale Maggiore Policlinico, Respiratory Unit and Cystic Fibrosis Adult Center, Milan, Italy*  
<sup>b</sup> *Università degli Studi di Milano, Department of Pathophysiology and Transplantation, Milan, Italy*  
<sup>c</sup> *Thoracic Surgery and Lung Transplant Unit, Fondazione Irccs Ca' Granda Ospedale Maggiore Policlinico, Milan, Italy*

\* Corresponding author.

E-mail address: [stefano.aliberti@unimi.it](mailto:stefano.aliberti@unimi.it) (S. Aliberti).

<https://doi.org/10.1016/j.arbres.2020.09.017>

0300-2896/ © 2020 SEPAR. Published by Elsevier España, S.L.U. All rights reserved.

## Lung Ultrasound for Evaluation of COVID-19 in Children



### Ecografía torácica para evaluar la COVID-19 en niños

Dear Editor,

Although the evidence is still limited, studies describing the course of SARS-CoV-2 infection suggest that the disease is mild in children. Most frequent complication is pneumonia, which occurs between 30 and 80% of cases, eventually requiring hospitalization.<sup>1–3</sup> Pulmonary involvement has been described in children and adults in pauci or even asymptomatic patients, especially when computerized tomography (CT) is used. In fact, the sensitivity of CT has been suggested to be even higher than PCR for COVID-19 diagnosis, but is not justified in children.<sup>4</sup>

In recent years, point-of-care ultrasound (POCUS) is being increasingly used in pediatrics, as it is rapid, portable, repeatable, and non-ionizing. Specific patterns of lung ultrasound (LU) have shown to be useful in the differential diagnosis of pneumonia or acute bronchiolitis, with potential for prognosis.<sup>5–7</sup> First case series describing main ultrasound findings in children with confirmed COVID-19 pneumonia have been published recently, suggesting a pulmonary involvement similar to the one described in other viral infections.<sup>8</sup>

The aim of this study was to address the usefulness of point-of-care LU, performed by pediatricians, to address pulmonary involvement in children with symptoms considered possibly attributable to SARS-CoV-2, during the first pandemic wave in Madrid.

We performed a prospective observational cohort study, including patients that consulted with symptoms attributable to SARS-CoV-2 infection, from April to June 2020 at the Paediatrics Department of a tertiary hospital in Madrid. The study protocol was reviewed and accepted by the local Ethics Committee.

Patients below 18 years of age evaluated for fever and/or respiratory symptoms were eligible for inclusion in the study. Exclusion criteria were: chronic lung disease, congenital heart disease, immunodeficiency, and congenital or anatomical defects of the airway.

A LU was performed at the Emergency Room or within the first 24 h of admission, using an E-Cube I7 (Alpinion Medical Equipment) equipped with a 3–12 Hz lineal probe. Scans were performed by 4 pediatricians with ultrasonography experience, following a common systematic methodology including longitudinal and transversal sections collected on the anterior, lateral, and posterior chest wall, as previously described by Copetti et al.<sup>9</sup> Ultrasound findings included: lung sliding, more than 3 B-lines per intercostal space, confluent B-lines and subpleural consolidations.

The presence of A lines and fewer than 3 B lines per intercostal space defined normality.

All patients were managed according to the current treatment protocol. Data were collected from the patients' medical records including all microbiological results, treatment and clinical outcome.

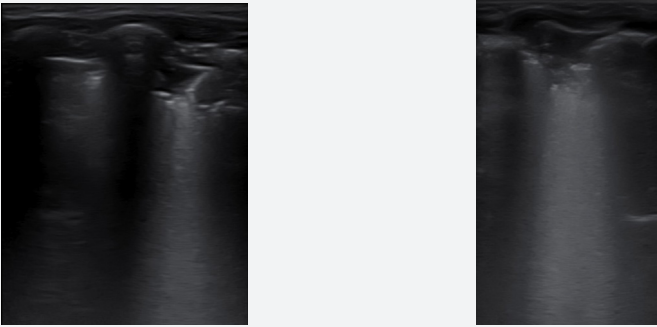
A total of 20 patients were included in this pilot study, with a median age of 5.2 years [IQR: 2.9–11.4], 65% were male. All patients were symptomatic, presenting with fever (80%), cough (55%), short of breathing (40%) and 45% were admitted for a median of 4.5 days [IQR:4–10]. Median duration of symptoms was 5 days [IQR: 2.5–8.5] and 25% of all patients needed oxygen support. SARS-CoV-2 infection was confirmed in 50% of patients either by PCR (42%) or by a positive serology (8%). In two cases, an alternate etiology was found (one mycoplasma, one metapneumovirus). No differences were found in epidemiological and clinical variables between COVID-19 confirmed and unconfirmed cases. Three cases (15%) were transferred to PICU without fatalities.

All but one patient had abnormalities on the chest X-ray, mostly ground glass opacities (35%), perihilar infiltrates (30%) and consolidations (30%), with no differences between the groups (Table 1). Three COVID-19 patients displayed a completely normal LU, vs. one in the comparison group. In all cases presenting with respiratory symptoms, LU revealed signs of lung involvement during COVID-19 infection. Ultrasound abnormalities were bilateral in 75% of cases in both groups. Pleural irregularities (50% anterior, 70% posterior), more than 3 B lines per intercostal space (uni or bilaterally) were present in 70% of cases, and consolidations in 30%, with no differences between groups. In total, six patients presented with consolidation bigger than 2 cm (three in each group). There was no pleural effusion in any. The presence of ultrasound abnormalities did not predict the need of supportive oxygen. Isolated, none of the ultrasound findings showed high sensitivity for COVID-19, and no particular ultrasound pattern characterized the infection.

In this pilot study in children screened with COVID-19 suspicion, ultrasound findings on admission did not show predictive ability for the identification of SARS-CoV-2 infection. The accuracy of point-of-care thorax ultrasound was comparable to chest X-ray in order to detect lung abnormalities in the context of SARS-CoV infection, but findings were indistinguishable from other respiratory infections.

The accuracy of PCR for the diagnosis of SARS-CoV infection seems to be lower in children compared to adult patients.<sup>10</sup> Chest X-ray is unspecific in most cases, and point of care ultrasound has been suggested as a promising tool by some pediatric studies.<sup>8</sup> The accuracy of LU in detecting pediatric pneumonia of any etiology has been extensively proven,<sup>5,9,11</sup> and the scarce data in the literature suggest that the accuracy in the context of

**Table 1**  
Clinical characteristics and lung ultrasound results in children with COVID-19 vs other respiratory infections.

	COVID-19 (n=10)	Others (n=10)
<i>Male sex</i>	9/10	4/10
<i>Median age in years<sup>a</sup></i>	4.8 [2.4–10.6]	5.7 [3.5–7.2]
<i>Confirmed SARS-CoV-2 household contact</i>	3/10	4/10
<i>Underlying conditions</i>	2/10	1/10
<i>Hospitalization</i>	6/10	3/10
<i>Signs and symptoms</i>		
<i>Temperature &gt; 37.9 °C</i>	9/10	7/10
Cough	4/10	7/10
Rhinorrhoea	1/10	5/10
Odynophagia	2/10	2/10
Breathing difficulty	4/10	4/10
Vomiting	4/10	1/10
Diarrhea	1/10	–
Rash	2/10	1/10
Hypoxia	3/10	2/10
<i>Chest X-ray</i>		
Normal	1/10	0/10
Perihilar infiltrates	6/9	–
Ground glass interstitial pattern	2/9	5/10
Lobar condensation	1/9	5/10
Pleural effusion	–	1/10
Bilateral involvement	8/9	4/10
<i>Ultrasound findings</i>		
Normal	3/10	1/10
Pleural irregularities	5/7	7/9
More than 3 B lines per intercostal space	5/7	7/9
Consolidations > 1 cm	3/7	3/9
Bilateral involvement	5/7	7/9
		
Representative image		
<i>Blood tests</i>		
Leucocytes/mm <sup>3</sup> <sup>a</sup>	9350 [8000–1517]	8474 [4775–11987]
Lymphocytes/mm <sup>3</sup> minimum <sup>a</sup>	1400 [720–2620]	2190 [577–3792]
C reactive protein; mg/L maximum <sup>a</sup>	70 [8–215]	33 [1–44.5]
<i>Outcome</i>		
Days of admission <sup>a</sup>	5 [3–10.5]	4
PICU admission	3	–

Abbreviations: IQR, interquartile range; PICU, pediatric intensive care unit.

<sup>a</sup> Expressed as median and IQR.

COVID-19 is comparable.<sup>8</sup> Main COVID-19 findings include pleural irregularities, vertical artifacts, areas of white lung and subpleural consolidations; all characteristic findings in the context of other viral respiratory infections such as acute bronchiolitis.<sup>6,12</sup> Results of our study support these findings, with no abnormalities characterizing COVID-19. Although previous studies including infants admitted with acute bronchiolitis suggest that LU might help predicting clinical outcome, larger studies including severe cases of COVID-19 will be needed in order to test its role in patient stratification. In this context, the use of POCUS has aroused great interest among clinicians managing infected adults. In view of the recommendation of pronal position to optimize ventilation of adults suffering from COVID-19, one could expect to find greater involvement when scanning the posterior wall, as described in acute bronchiolitis, where both B-lines and confluent B-lines are seen more often in the posterior area, but no differences were found in our series.

This is the first study that explores the usefulness of LU as a tool for identification of COVID-19 among children presenting with respiratory symptoms. Our study has several limitations, including the small sample size and the impossibility to completely exclude SARS-CoV-2 infection and scans were not performed by a single

person. Recruitment is ongoing to validate the usefulness of point of care ultrasound in children suffering from COVID-19.

## Bibliografía

- de Ceano-Vivas M, Martín-Espín I, del Rosal T, Bueno-Barricón M, Plata-Gallardo M, Ruiz-Dominguez JA, et al. SARS-CoV-2 infection in ambulatory and hospitalized Spanish children. Arch Dis Child. 2020; <http://dx.doi.org/10.1136/archdischild-2020-319366>, archdischild-2020-319366.
- Escosa-García L, Aguilera-Alonso D, Calvo C, Mellado MJ, Baquero-Artigao F. Ten key points about COVID-19 in children: the shadows on the wall [published online ahead of print, 2020 Aug 13]. Pediatr Pulmonol. 2020;10; <http://dx.doi.org/10.1002/ppul.25025>.
- Parri N, Magistà AM, Marchetti F, Cantoni B, Arrighini A, Romanengo M, et al. Characteristic of COVID-19 infection in pediatric patients: early findings from two Italian Pediatric Research Networks. Eur J Pediatr. 2020;179:1315–23; <http://dx.doi.org/10.1007/s00431-020-03683-8>.
- Caro-Dominguez P, Shelmerdine SC, Toso S, Secinaro A, Toma P, Damasio MB, et al. Thoracic imaging of coronavirus disease 2019 (COVID-19) in children: a series of 91 cases. Pediatr Radiol. 2020; <http://dx.doi.org/10.1007/s00247-020-04747-5>.
- Shah VP, Tunik MC, Tsung JW. Prospective evaluation of point-of-care ultrasonography for the diagnosis of pneumonia in children and young adults. JAMA Pediatr. 2013;167:119–25.

6. Caiulo VA, Gargani L, Caiulo S, Fiscicaro A, Moramarco F, Latini G, et al. Lung ultrasound in bronchiolitis: comparison with chest X-ray. *Eur J Pediatr*. 2011;170:1427–33.
7. Varshney T, Mok E, Shapiro AJ, Li P, Dubrovsky AS. Point-of-care lung ultrasound in young children with respiratory tract infections and wheeze. *Emerg Med J*. 2016;33:603–10. <http://dx.doi.org/10.1136/emered-2015-205302> [accessed 24.06.18].
8. Musolino AM, Supino MC, Buonsenso D, Ferro V, Valentini P, Magistrelli A, et al. Lung ultrasound in children with COVID-19: preliminary findings. *Ultrasound Med Biol*. 2020;46:2094–8. <http://dx.doi.org/10.1016/j.ultrasmedbio.2020.04.026>.
9. Copetti R, Cattarossi L. Ultrasound diagnosis of pneumonia in children. *Radiol Med*. 2008;113:190–8. <http://dx.doi.org/10.1007/s11547-008-0247-8> <https://www.ncbi.nlm.nih.gov/pubmed/18386121>
10. Woloshin S, Patel N, Kesselheim AS. False negative tests for SARS-CoV-2 infection – challenges and implications [published online ahead of print, 2020 Jun 5]. *N Engl J Med*. 2020;10. <http://dx.doi.org/10.1056/NEJMp2015897>, 1056/NEJMp2015897.
11. Ambroggio L, Sucharew H, Rattan MS, O'Hara SM, Babcock DS, Clohessy C, et al. Lung ultrasonography: a viable alternative to chest radiography in children with suspected pneumonia? *J Pediatr*. 2016;176:98, e7.
12. Bueno-Campaña M, Sainz T, Alba M, Del Rosal T, Mendez-Echevarría A, Echevarría R, et al. Lung ultrasound for prediction of respiratory support in infants with acute bronchiolitis: a cohort study. *Pediatr Pulmonol*. 2019. <http://dx.doi.org/10.1002/ppul.24287>.

Talía Sainz<sup>a,b,c,\*</sup>, Clara Udaondo<sup>a,b</sup>, Ana Méndez-Echevarría<sup>a,b,c</sup>, Cristina Calvo<sup>a,b,c</sup>

<sup>a</sup> *Pediatrics and Infectious Disease Unit, Hospital Universitario La Paz, Madrid, Spain*

<sup>b</sup> *Fundación IdiPaz, Madrid, Spain*

<sup>c</sup> *Traslational Research Network of Pediatric Infectious Diseases (RITIP), Madrid, Spain*

\* Corresponding author.

E-mail address: [tsainzcosta@gmail.com](mailto:tsainzcosta@gmail.com) (T. Sainz).

<https://doi.org/10.1016/j.arbres.2020.10.013>

0300-2896/ © 2020 SEPAR. Published by Elsevier España, S.L.U. All rights reserved.