

Thoracic EndoVascular Stent Graft Repair for Aortic Aneurysm

Joung Taek Kim, M.D.*, Yong Han Yoon, M.D.*, Hyun Kyung Lim, M.D.**,
Ki Hwan Yang, M.D.**, Wan Ki Baek, M.D.*, Kwang Ho Kim, M.D.*

Background: The number of cases employing thoracic endovascular aortic repair (TEVAR) has been increasing due to lower morbidity and mortality compared to open repair technique. The aim of this study is to evaluate the outcome of TEVAR for thoracic aortic diseases. **Materials and Methods:** Sixteen patients underwent TEVAR from October 2003 to April 2010. Mean age at operation was 59 years (20~78 years), and 11 were male. Indications for TEVAR were large aortic diameter (>5.5 cm) upon presentation in 6 patients, increasing aortic diameter during the follow-up period in 4, traumatic aortic rupture in 3, persistent chest pain in 2, and ruptured aortic aneurysm in one. The mean diameter, length and the number of the stents were 33 mm (26~40 mm), 12 cm (9.5~16.0 cm), and 1.25 (1~2), respectively. Aortography employing Multi-detector computerized tomography (MDCT) technique was performed at one week, and patients were followed up in the out-patient department at one month, 6 months, and one year postoperatively. **Results:** Primary technical success showing complete exclusion of the aneurysm was achieved in 15 patients. One patient showed a small endo-leak (type 1). Four patients developed perioperative stroke: Three recovered without sequelae, and one showed mild right-side weakness. There was no operative mortality. Diameter of the thoracic aorta covered by stent graft changed within 10% range in 12 patients, decreased by more than 10% in 3, and increased by more than 10% in one during mean follow-up duration of 18 months (1~73 months). There was no recurrence-related death during this period. **Conclusion:** Intermediate-term outcome after TEVAR was encouraging. Indications for TEVAR could be extended for other thoracic aortic diseases.

Key words: 1. Aorta
2. Aneurysm
3. Stents

INTRODUCTION

After stent graft implantation became a standard procedure for infra-renal abdominal aortic aneurysm, the number of cases of thoracic endovascular aortic repair (TEVAR) in Korea has been rapidly increasing [1-3], substantiated by the reports from Korean Health Insurance Review & Assessment Service

(Fig. 1). Stent graft, which consists of prosthetic material, such as Dacron or Gore-Tex patches, embedded in the cylindrical metallic frame, is devised to separate aortic aneurysm from true aortic lumen, and thus interrupt the blood flow into the aneurysm. Because TEVAR eliminates the basic elements of surgical intervention (i.e. thoracotomy, left heart bypass, aortic cross-clamping and deep hypothermic circulatory ar-

*Department of Thoracic and Cardiovascular Surgery, Inha University Hospital

**Department of Anesthesiology and Pain Medicine, Inha University Hospital

†This work was supported by research grant from Inha University.

Received: July 13, 2010, Revised: March 15, 2011, Accepted: March 17, 2011

Corresponding author: Joung Taek Kim, Department of Thoracic and Cardiovascular Surgery, Inha University Hospital, 7-206, Sinheung-dong 3-ga, Jung-gu, Incheon 400-711, Korea
(Tel) 82-32-890-2280 (Fax) 82-32-890-3099 (E-mail) jtkim@inha.ac.kr

© The Korean Society for Thoracic and Cardiovascular Surgery. 2011. All right reserved.

© This is an open access article distributed under the terms of the Creative Commons Attribution Non-Commercial License (<http://creativecommons.org/licenses/by-nc/3.0>) which permits unrestricted non-commercial use, distribution, and reproduction in any medium, provided the original work is properly cited.

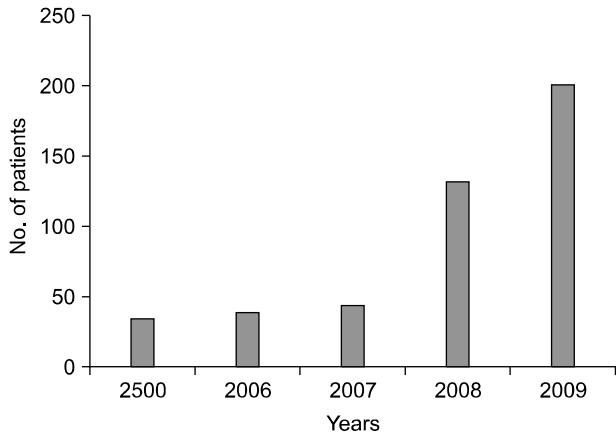


Fig. 1. Number of patients treated with TEVAR in Korea*. *=Data was provided by Korean Health Insurance review & assessment service. TEVAR=Thoracic endovascular aortic repair.

Table 1. Aortic diseases of the patients treated with TEVAR* (N=16)

	No. of patients
Descending thoracic aortic aneurysm	4
Chronic aortic dissection	4
Type A aortic dissection	2
Type B aortic dissection	2
Traumatic aortic rupture	3
Aortic arch aneurysm	2
Acute type B aortic dissection	2
Descending thoracic aortic pseudo-aneurysm	1

*=Thoracic endovascular aortic repair.

rest), this new therapeutic modality is believed to lower the risks of morbidity and mortality in descending thoracic aortic aneurysm, traumatic aortic rupture and type B aortic dissection [2]. Furthermore, when the application of TEVAR for aortic arch aneurysm is difficult because proximal landing zone (PLZ) for stent graft overrides the origin of the arch vessels, hybrid procedure (i.e. surgical debranching of the arch vessels plus TEVAR) has been recently developed [3]. In this study, we sought to determine the intermediate-term results of TEVAR for thoracic aortic aneurysm.

MATERIALS AND METHODS

The study cohort comprises 16 patients who underwent TEVAR between October 2003 and April 2010. Median age

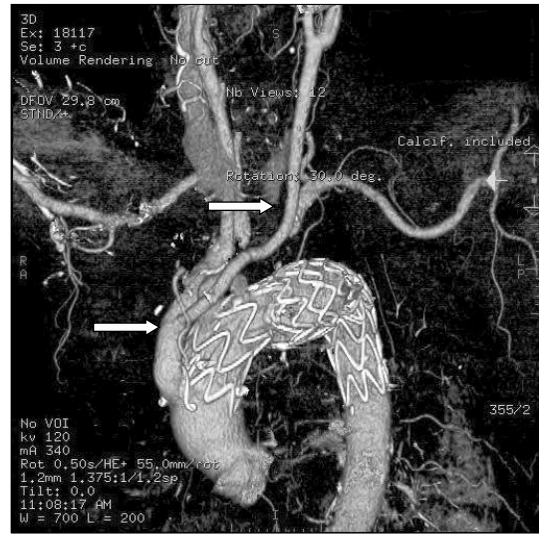


Fig. 2. Three-Dimensional reconstruction of MDCT image after hybrid TEVAR. The arrows indicate de-branched innominate artery and left common carotid artery. MDCT=Multi-detector computed tomography; TEVAR=Thoracic endovascular aortic repair.

Table 2. Indications for TEVAR*

	No. of patients
Aortic diameter ≥ 5.5 cm	6
False lumen enlargement	4
Traumatic rupture	3
Persistent back/chest pain	2
Aortic aneurysm rupture	1

*=Thoracic endovascular aortic repair.

at TEVAR was 59 years (20~78 years), and 11 were males. Types of aortic lesion were descending thoracic aortic aneurysm in 4, chronic aortic dissection in 4, traumatic aortic rupture in 3, aortic arch aneurysm in 2, acute type B aortic dissection in 2, and descending thoracic aorta pseudoaneurysm in 1 (Table 1). Associated morbidities were systemic hypertension in 7, multiple trauma in 3, a history of ascending aortic replacement for previous type A aortic dissection in 2, diabetes mellitus in 2, and aortic rupture in 1. Indications for TAVAR were dilated aortic diameter equal to or greater than 5.5 cm (n=6), increase in aortic size during the follow-up (n=4), traumatic aortic rupture (n=3), persistent chest pain (n=2), and ruptured aortic aneurysm (n=1) (Table 2). Mean diameter of the stent used for TEVAR was 33 mm (26~40 mm), and mean number of the stent per a patient was 1.25 (1

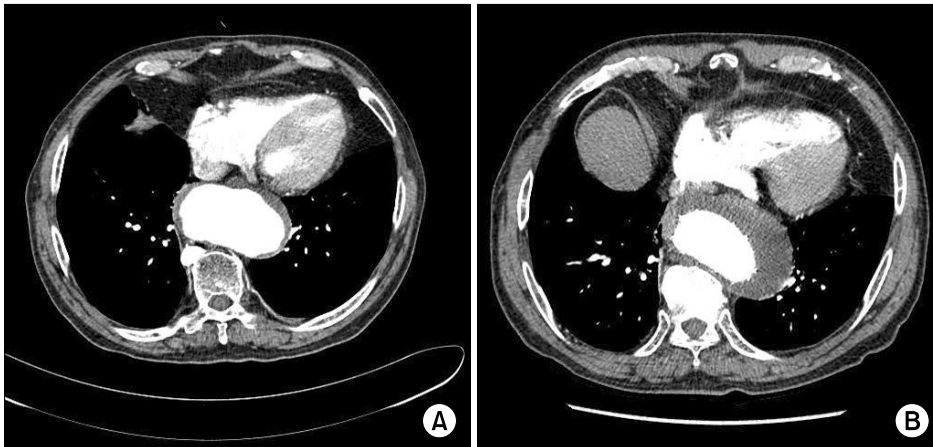


Fig. 3. Follow-up MDCT aortography shows the increased aortic diameter after TEVAR (B) compared with preoperative image (A).

~2). All patients underwent multi-detector computed tomography (MDCT) for the assessment of thoraco-abdominal aorta, and sufficient PLZ was defined by aortic diameter (≤ 40 mm) and length (≥ 2 cm) on MDCT. If the length of normal aorta is insufficient for PLZ, TEVAR was preceded by debranching surgery of the arch vessels (Fig. 2). With respect to the intra-operative safety measures, cerebrospinal fluid drainage was done in a patient whose distal landing zone was to be below the level of 8th thoracic vertebra, and intra-operative electroencephalography (EEG) monitoring was done for patients with debranching surgery. Under general or epidural anesthesia, right femoral artery was exposed for the catheter sheath insertion, and left femoral artery or left radial artery was punctured to introduce a reference catheter, 5 French in size, which was used to determine the exact location of DLZ. After 5,000 IU of heparin was administered, a stent graft (Seal flex, S & G Co, Korea) was introduced through the sheath in the right femoral artery up to the level of pre-determined PLZ and DLZ. During the procedure, calcium channel blockers and remifentanyl were used to lower the systolic systemic blood pressure down to 80 mmHg. Rapid right ventricular pacing to prevent windsock phenomenon, which is recommended by several programs, was not performed. After the stent graft was deployed, aortography was performed to ascertain the absence of endo-leak. If endo-leak was suspected, balloon dilatation of the stent graft or additional stent graft implantation was performed. Follow-up MDCT was done at one week after the procedure, and patients were follow-up in the out-patient department at post-

operative 1, 6 and 12 months.

RESULTS

Endovascular aneurismal exclusion was confirmed in 15 patients (15/16, 94%). One patient showed minimal Type 1 endoleak, and has been closely followed up ever since the procedure without further deterioration. Cerebral embolism occurred in four patients: Three recovered completely, and one developed mild right side motor weakness. Two patients developed left-sided pleural effusion, which was drained using a catheter in one. There was no surgical mortality. During a mean follow-up duration of 18 months (1~73 months), the diameter of the thoracic aorta covered by the stent graft changed within 10% range in 12 patients, decreased by more than 10% in 3, and increased by more than 10% in one (Fig. 3). There was no late death related to the recurrence of the original aortic disease.

DISCUSSION

Stent graft TEVAR for various thoracic aortic diseases reportedly shows low morbidity and mortality compared to conventional surgical approach [1-4]. Technical success rate of TEVAR (i.e. complete isolation of the aneurysmal cavity from the aortic circulation) has reached up to 98%, while early mortality (1.9~2.9%) is extremely lower than that (5.7~11.7%) of surgical series [2-4]. As for the morbidity, a recent report claimed that TEVAR resulted in lower incidence

(9.4%) of morbidities, including myocardial infarction, respiratory complications and cerebrospinal injury compared to the outcome of surgical intervention (33%) [4]. Indications for TAVAR are almost the same as those for surgical intervention, that are dilated aortic diameter equal to or greater than 5.5 cm, increase in aortic size by greater than 1 cm per year during the follow-up, traumatic aortic rupture, persistent chest pain, peripheral perfusion failure from type B aortic dissection, and penetrating aortic ulcer larger than 2 cm in diameter [2].

Traumatic aortic rupture is caused by an acute deceleration injury on the insertion site of ligamentum arteriosum, and frequently associated with multiple trauma, which may render the surgical outcome even worse. In this setting, TEVAR is a formidable alternative to a surgical intervention by minimizing the invasiveness of the repair [5]. Small sized stent grafts tend to be used for TEVAR for patients with traumatic aortic rupture because this condition frequently occurs in younger population whose pre-trauma aortic size could well be normal.

With respect to the outcome after TEVAR for uncomplicated type B dissection, INSTEAD (Investigation of stent graft in patients with type B aortic dissection) study conducted in Europe showed that there was no difference in 1 year survival between TEVAR group and medical treatment group [6]. However, given that the size of the aorta increases as time passes, the longer term outcome may turn out to be in favor of TEVAR strategy [7]. To the contrary, Iris et al observed that there was no difference in the size of the false aortic lumen between TEVAR and medical treatment groups, and they asserted that TEVAR procedure never abolishes, albeit may delay, the manifestation of the adverse outcome from the natural progression of the aortic disease [8]. In our series, there was one patient whose aortic diameter increased as time passed.

As for chronic aortic dissection, partial thrombus formation in the false lumen is believed to increase the risk of rupture and death [9]. Thus, the benefits from TEVAR in comparison to surgical approach is still controversial, because stent graft only obliterates the opening of the entry site while leaving reentry site uncovered, which may end up with partial thrombus formation, progressive aortic dilation and rupture of the thoracic aorta.

Surgical correction of acute type B dissection involving the origin of arch vessels is associated with significant morbidity and high mortality rate [10]. Arch vessels obstruction is caused by intimal flap occluding the origins of the vessels, and obstruction can be either static (i.e. fixed obstruction) or dynamic (i.e. intermittent obstruction according to the cardiac cycle) [11]. Arch dissection with static obstruction of the arch vessels necessitate self-expandable stent insertion into the arch vessels, and communication between the true lumen and arch vessel origins is established either by fenestration of the stent graft or by the use of separate bare stent at the arch level. On the contrary, arch dissection with dynamic obstruction of the arch vessels only requires obliteration of the entry site by stent graft so that intermittent expansion of the intimal flap during the systolic phase is prevented [11]. Early and late mortality after surgery for patients who had undergone TEVAR for arch dissection with arch vessel obstruction are reported to be 17% and 36%, respectively, which appears to be much better than the mortality after conventional surgical repair for acute arch dissection (40%) [11]. This finding signifies that the application of TEVAR to arch dissection is designed to convert a complicated type B dissection involving arch vessels into an uncomplicated chronic type B dissection, which is much more amenable to a surgical intervention. In this regards, Szeto et al asserted that TEVAR should be considered as the first-line treatment for complicated type B acute dissection (i.e. rupture or arch obstruction), evidenced by the low procedure-related mortality (3%) in 35 patients with complicated arch dissection [12]. However, some argue that the risk of false lumen rupture in type-B dissection with arch vessel obstruction remains significant even after TEVAR is performed [13]. As for uncomplicated type B dissection, ADSORB (Acute Uncomplicated Aortic Dissection Type B: Evaluating Stent-Graft Placement or Best Medical Treatment Alone) study has investigated on the benefits of stent graft over medical treatment, which has not reached a conclusion yet. Timing of TEVAR for type B acute dissection is also controversial. Some prefer to delay the procedure to 2~4 weeks after the onset, based on the findings that intimal flap is fragile and easily breakable during early period [14,15], while others believe that early intervention may promote the complete restoration of the aortic integrity, and thus could

improve the long-term outcome [16,17]. In a study which compared the outcomes after TEVAR and medical treatment for acute type B dissection [10], the authors insisted that there was no difference in the development of complication or mortality, and therefore TEVAR should be reserved only for complicated type B dissection. Akira et al stratified the patients according to the diameter of the aorta, and they concluded that TEVAR should be indicated for patients whose maximal aortic diameter is greater than 40 mm, based on their observations that 60% of the patients with large aorta (≥ 40 mm in diameter) showed enlargement of the false lumen and underwent a surgical intervention while 94% of the patients with small aorta (≤ 40 mm in diameter) showed spontaneous obliteration of the false lumen [18].

Preoperative computed tomographic angiography can be utilized for the evaluation of the arch vessels, and, if basilar artery mal-perfusion after TEVAR is anticipated due to poor collateral circulation to the left subclavian artery or left dominance of vertebral artery circulation, graft interposition between the left subclavian artery and left common carotid artery should be performed beforehand. If the stent graft is to cover the left common carotid artery too, graft interposition between both common carotid arteries should also be performed before TEVAR procedure. If the innominate artery is to be covered, all three arch vessels should be debranched and reimplanted into the proximal ascending aorta through median sternotomy [3]. Special care should be taken to prevent cerebrospinal injury upon TEVAR procedure. Cerebral embolism of atheromatous plaques may take place during the catheter work or graft stenting, and left vertebral artery mal-perfusion may lead to posterior cerebral infarction when PLZ violates the origin of the left subclavian artery. Furthermore, spinal cord injury is likely to occur when more than 15 cm of the descending thoracic aorta is covered by the stent graft or DLZ is less than 5 cm away from the origin of the celiac trunk [2].

As to the complications after TEVAR, post-implantation syndrome refers to inflammatory responses after TEVAR characterized by leukocytosis, mild fever and the elevation of the inflammatory markers, and is attributed to the activation of the intimal cells of the aorta. Reactive pleural effusion may also occur in 37~73% of the patients. Distal migration

of the stent graft more than 10 mm off the original site is observed in 1~2.8% of the patients, and too large stent graft or variability of the luminal curvature in the proximity of PLZ are thought to be the risk factors for stent graft migration [2].

Postoperative evaluation is based on the findings of MDCT, which is to be performed at postoperative 1,6 and 12 months, and annually from that on. If type 1 endo-leak is detected on MDCT, immediate intervention is recommended, and, if type 2 endo-leak is suspected, close follow-up focusing on the size change of the aneurysm is suggested.

The application of TEVAR using stent graft has not been fully established yet. Traumatic aortic rupture and descending thoracic aneurysm seem to be best benefitted from this new therapeutic modality, and TEVAR is expected to rapidly replace the conventional surgical approach. As for aortic arch dissection involving arch vessels, employment of hybrid procedure (i.e. TEVAR with surgical interventions for arch vessels) will increase [3]. The efficacy of TEVAR for acute type B dissection is still under debate: Some are insisting that TEVAR does not change the natural course of the false lumen while others claim that TEVAR may contribute to the regression of the false lumen by thrombus formation and absorption [8,19]. Thus, further study with longer-term follow-up is necessary to delineate the benefits from TEVAR for this subset.

CONCLUSION

Intermediate-term outcome after TEVAR was encouraging. Indications for TEVAR could be extended for other thoracic aortic diseases.

REFERENCES

1. Kim JT, Geon YS, Baek WK, Yoon YH, Kim YS, Kim KH. *Use of percutaneous endovascular stent graft in patients with thoracic aneurysm*. Korean J Thorac Cardiovasc Surg 2006;39:157-61.
2. Wang GJ, Fairman RM. *Endovascular repair of the thoracic aorta*. Semin Intervent Radiol 2009;26:17-21.
3. Antoniou GA, Sakka KE, Hamady M, Wolfe JHN. *Hybrid treatment of complex aortic arch disease with supra-aortic debranching and endovascular stent graft repair*. Eur J Vasc

- Endovasc Surg 2010;39:683-90.
4. Matsumura JS, Cambria RP, Dake MD, Moore RD, Svensson LG, Snyder S. *International controlled clinical trial of thoracic endovascular repair with Zeith TX2 endovascular graft: 1-year results.* J Vasc Surg 2008;47:247-57.
 5. Neschis DG, Scalea TM, Flinn WR, Griffith BP. *Blunt aortic injury.* N Engl J Med 2008;359:1708-16.
 6. Nienaber CA, Zannetti S, Kische S, Schareck W, Rehders TC. *Investigation of stent graft in patients with type B aortic dissection: design of the INSTEAD trial-prospective, multi-center, European randomized trial.* Am Heart J 2005;149:592-9.
 7. Song JM, Kim SD, Kim JH, et al. *Long-term predictors of descending aorta aneurismal change in patients with aortic dissection.* JACC 2007;50:799-804.
 8. Chemelli-Steingruber IE, Chemelli A, Strasak A, Hugel B, Hiemetzberger R, Czermak BV. *Evaluation of volumetric measurements in patients with acute type B aortic dissection-TEVAR vs conservative.* J Vasc Surg 2009;49:20-8.
 9. Tsai TT, Evangelista A, Nienaber CA, et al. *Partial thrombolysis of false lumen in patients with acute type B aortic dissection.* N Engl J Med 2007;357:349-59.
 10. Chemelli-Steingruber IE, Chemelli A, Strasak A, et al. *Endovascular repair or medical treatment of acute type B aortic dissection? A comparison.* Eur J Radiol 2008;73:175-80.
 11. Patel HJ, William DM. *Endovascular therapy for malperfusion in acute type B aortic dissection.* Oper Tech Thorac Cardiovasc Surg 2009;14:2-11.
 12. Szeto WY, Mearvey M, Pochettino A, et al. *Results of a new surgical paradigm: endovascular repair for acute complicated type B aortic dissection.* Ann Thorac Surg 2008;86:87-94.
 13. Patel HJ, William DM, Meekov M, Dasika NL, Upchurch GR, Deeb GM. *Long-term results of percutaneous management of malperfusion in acute type B aortic dissection: implications for thoracic aortic endovascular repair.* J Thorac Cardiovasc Surg 2009;138:300-8.
 14. Tang DG, Dake MD. *TEVAR for acute uncomplicated aortic dissection: immediate repair versus medical therapy.* Semin Vasc Surg 2009;22:145-51.
 15. Kato N, Hirano T, Ishida M, et al. *Acute and contained rupture of the descending thoracic aorta: treatment with endovascular stent-grafts.* J Vasc Surg 2003;37:100-5.
 16. Shimono T, Kato N, Yasuda F, et al. *Transluminal stent-graft placements for the treatments of acute onset and chronic aortic dissection.* Circulation 2002;106:1241-7.
 17. Conrad MF, Crawford RS, Kwolek CJ, Brewster DC, Brady TJ, Cambria RP. *Aortic remodeling after endovascular repair of acute complicated type B aortic dissection.* J Vasc Surg 2009;50:510-7.
 18. Marui A, Mochizuki T, Mitsui N, Koyama T, Kimura F, Horibe M. *Toward the best treatment for uncomplicated patients with type B acute aortic dissection.* Circulation 1999; 100(19 suppl):275-80.
 19. Song TK, Donayre CE, Walot I, et al. *Endograft exclusion of acute and chronic descending thoracic aortic dissections.* J Vasc Surg 2006;43:247-58.