



Corneal warpage caused by cosmetic contact lenses: a case description

Ying Xu^{1^}, Shuangqing Wu², Fei Shen¹, Xiaoqian Wang¹, Qianfeng Xiao¹

¹Center of Refractive Surgery, Hangzhou Aier Eye Hospital, Hangzhou, China; ²National Clinical Research Center for Ocular Diseases, Eye Hospital of Wenzhou Medical University, Wenzhou, China

Correspondence to: Ying Xu, MD. Center of Refractive Surgery, Hangzhou Aier Eye Hospital, 180 Boxue Rd., Hangzhou 310000, China. Email: xuying11@aierhhr.com.

Submitted May 10, 2023. Accepted for publication Sep 27, 2023. Published online Oct 30, 2023.

doi: 10.21037/qims-23-641

View this article at: <https://dx.doi.org/10.21037/qims-23-641>

Introduction

As a method of vision correction, contact lenses, especially cosmetic contact lenses, are convenient and esthetic. However, long-term use can cause complications such as ocular dryness, discomfort, conjunctivitis, and infectious keratitis (1). Symptomatic contact lens wearers often undergo refractive surgery to reduce their dependence on lenses. Patients must stop wearing soft contact lenses for 1 week and hard contact lenses for 3 weeks before surgery for a reliable measurement during preoperative evaluation (2). However, serious complications such as corneal warpage may require more time to resolve. Corneal warpage, first reported by Hartstein in 1965 (3), exhibits reversible distortion of the corneal surface and clinically manifests as irregular corneal astigmatism. Studies have shown that some corneal warpage occurs in soft contact lens wearers; however, most studies have not described whether the warpage is induced by nonpigmented or pigmented soft contact lenses (4). Here, we present a case of corneal warpage caused by pigmented cosmetic lenses.

Case presentation

All procedures performed in this study were in accordance with the ethical standards of the institutional and/or the relevant national research committee(s) and with the Helsinki Declaration (as revised in 2013). Written informed consent was obtained from the patient for publication of

this case report and accompanying images. A copy of the written consent is available for review by the editorial office of this journal.

A 25-year-old woman seeking refractive surgery attended our clinic after discontinuing cosmetic lens use for 4 days. The patient had worn cosmetic lenses for more than 8 hours per day for 7 years. A patient history of myopia was noted, and a preoperative assessment was conducted. Corneal tomography, aberration evaluation, and densitometry were performed using Scheimpflug imaging (Pentacam; Oculus Inc., Wetzlar, Germany). The manifest refractions and best-corrected visual acuities (BCVAs) were respectively $-3.25 -3.00 \times 85$ and 20/25 oculus dexter (OD) and $-4.75 -1.75 \times 75$ and 20/20 oculus sinister (OS). The maximum keratometry front (Kmax-front) values were 45.40 diopter (D) OD and 46.60 D OS, and the astigmatism front values were 1.60 D OD and 1.00 D OS (*Figure 1A,1B*). The average values of anterior corneal densitometry in the 0 to 2, 2 to 6, 6 to 10, and 10 to 12 mm groups were respectively 26.9, 24.0, 29.0, and 42.9 OD; and 27.8, 24.9, 27.6, and 40.3 OS. The surgery was delayed, as the duration of ceasing contact lens use was insufficient.

The patient returned 4 days after. The manifest refractions and BCVAs were respectively $-3.75 -2.25 \times 80$ and 20/20 OD and $-4.75 -1.50 \times 75$ and 20/20 OS. The Kmax-front values were 44.10 D OD and 45.80 D OS, and the astigmatism front values were 0.70 D OD and 1.40 D OS (*Figure 1C,1D*). The average values of anterior corneal

[^] ORCID: 0009-0002-4367-9060.

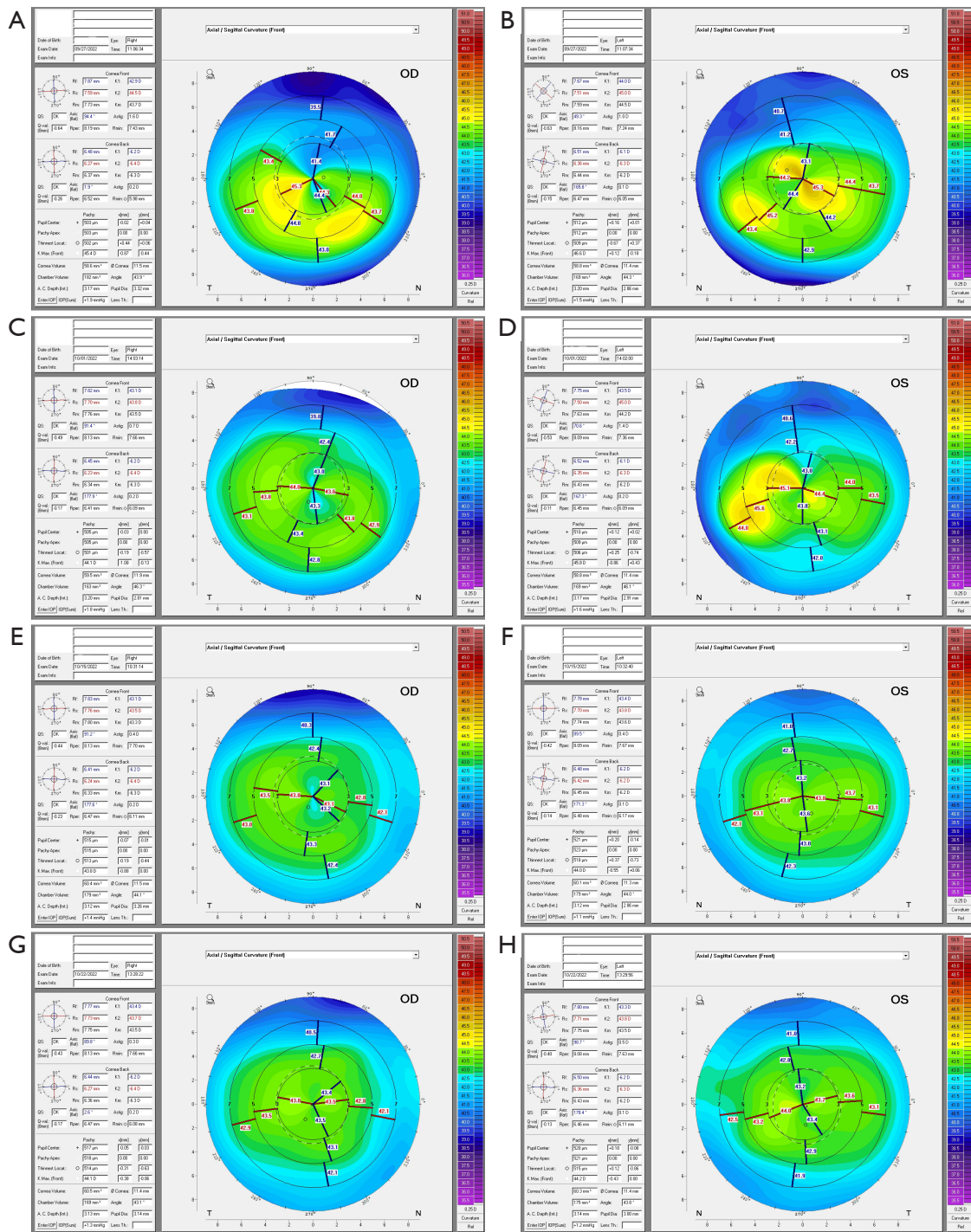


Figure 1 Corneal tomography of the patient from the first to the fourth visit. (A) Tomography revealed irregular astigmatism in the right cornea after lens discontinuation for 4 days. (B) Tomography revealed irregular astigmatism in the left cornea after lens discontinuation for 4 days. (C) Irregular astigmatism disappeared in the right cornea after lens discontinuation for 8 days. (D) Irregular astigmatism was still present in the left cornea after lens discontinuation for 8 days. (E) Normal tomography in the right cornea after lens discontinuation for 22 days. (F) Irregular astigmatism disappeared in the left cornea after lens discontinuation for 22 days. (G) Stable normal tomography in the right cornea after lens discontinuation for 29 days. (H) Normal tomography in the left cornea after lens discontinuation for 29 days. OD, oculus dexter; N, nasal; T, temporal; D, diopter; OS, oculus sinister.

Table 1 Changes in manifest refraction, Kmax, and astigmatism in the front cornea

Visit	Manifest refraction		Kmax-front		Astigmatism front	
	OD	OS	OD	OS	OD	OS
First	-3.25 -3.00 × 85	-4.75 -1.75 × 75	45.40 D	46.60 D	1.60 D	1.00 D
Second	-3.75 -2.25 × 80	-4.75 -1.50 × 75	44.10 D	45.80 D	0.70 D	1.40 D
Third	-4.25 -1.75 × 85	-4.75 -1.25 × 75	43.80 D	44.00 D	0.40 D	0.40 D
Fourth	-4.25 -1.25 × 90	-4.75 -1.00 × 90	44.10 D	44.20 D	0.30 D	0.50 D

Kmax, maximum keratometry; Kmax-front, maximum keratometry front; OD, oculus dexter; OS, oculus sinister; D, diopter.

Table 2 HOA changes in the horizontal coma, vertical coma, and PSA

Visit	OD			OS		
	Horizontal coma (μm)	Vertical coma (μm)	PSA (μm)	Horizontal coma (μm)	Vertical coma (μm)	PSA (μm)
First	-0.182	-0.953	0.323	0.070	-0.884	0.015
Second	-0.123	-0.355	0.262	-0.179	-0.410	0.090
Third	-0.149	-0.175	0.229	0.110	-0.108	0.146
Fourth	-0.112	-0.028	0.112	0.088	-0.050	0.145

Aberration values are presented as Zernike coefficients. HOA, higher-order aberration; PSA, primary spherical aberration; OD, oculus dexter; OS, oculus sinister.

densitometry in the 0 to 2, 2 to 6, 6 to 10, and 10 to 12 mm groups were respectively 27.3, 24.2, 22.4, and 33.0 OD; and 26.6, 23.8, 25.6, and 30.0 OS. Owing to these inconsistent results, the surgery was once again postponed.

The patient returned again after 14 days. The manifest refractions and BCVAs were respectively -4.25 -1.75 × 85 and 20/20 OD and -4.75 -1.25 × 75 and 20/20 OS. The Kmax-front values were 43.80 D OD and 44.00 D OS, and the astigmatism front values were 0.40 D OD and 0.40 D OS (*Figure 1E,1F*). The surgery was postponed to the following week to meet the stabilization criteria.

When the patient returned a week later, the manifest refractions and BCVAs were respectively -4.25 -1.25 × 90 and 20/20 OD and -4.75 -1.00 × 90 and 20/20 OS. The Kmax-front values were 44.10 D OD and 44.20 D OS, and the astigmatism front values were 0.30 D OD and 0.50 D OS (*Figure 1G,1H*). The critical results are summarized in *Table 1*. The higher-order aberrations (HOAs) changes in horizontal coma, vertical coma, and primary spherical aberration (PSA) are listed in *Table 2*. During the visits, the central steepened cornea became flat as the Kmax-front and astigmatism front values decreased, the vertical comas were the most significantly lowered among the HOAs from the first to the fourth visit (*Table 2*), and the anterior corneal

densitometry values in the approximate 10 to 12 mm range were obviously reduced (*Figure 2*). Finally, the patient successfully underwent small incision lenticule extraction (SMILE) based on the manifest refraction results of the fourth visit and achieved satisfactory visual rehabilitation. Her refractions and visual acuities after surgery were respectively +0.25 -0.50 × 89 and 20/20 OD and +0.25 -0.25 × 81 and 20/20 OS.

Discussion

In the present case, the patient—a long-term wearer of cosmetic lenses—recalled the presence of myopia at the onset of vision loss, and obvious astigmatism was observed during her initial visit. Rayess *et al.* (5) reported that corneal warpage resolves within 7–21 days. Similarly, in the present case, corneal warpage resolved within 22 days. One study (6) reported that spherical and cylindrical refractions fluctuate with the duration of warpage resolution, which is consistent with our observations in the present case. The clinical picture of corneal warpage often mimics a keratoconus-like topographic pattern characterized by inferior steepening and superior flattening of the cornea, making differentiating between warpage and keratoconus difficult. Differentiation

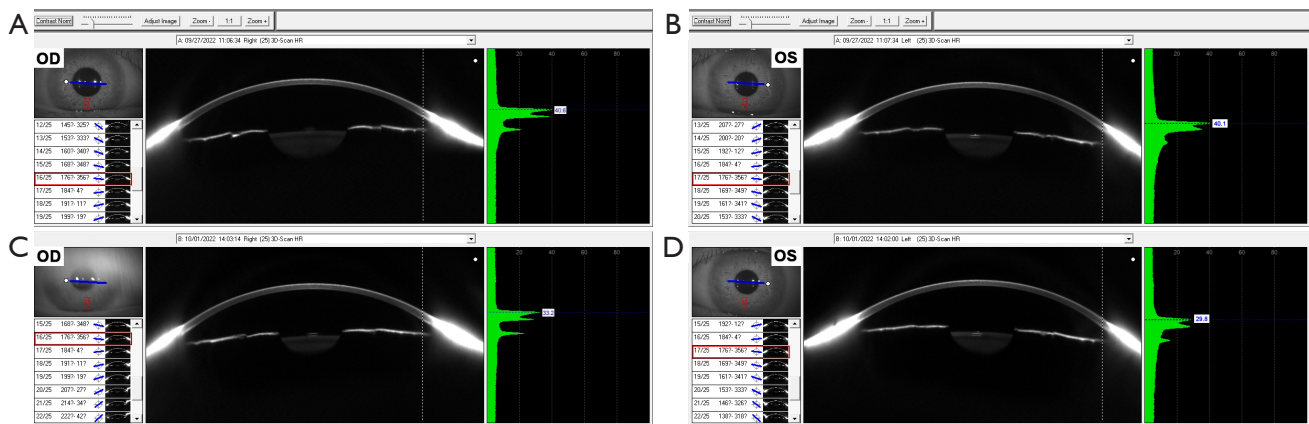


Figure 2 Corneal densitometry of the patient. (A) Corneal densitometry in the approximate 10 to 12 mm range (white dotted line) of the right cornea after lens discontinuation for 4 days. (B) Corneal densitometry in the approximate 10 to 12 mm range (white dotted line) of the left cornea after lens discontinuation for 4 days. (C) Corneal densitometry in the approximate 10 to 12 mm range (white dotted line) of the right cornea after lens discontinuation for 8 days; the anterior densitometry was reduced from 40.6 to 33.2. (D) Corneal densitometry in the approximate 10 to 12 mm range (white dotted line) of the left cornea after lens discontinuation for 8 days; the anterior densitometry was reduced from 40.1 to 29.8. OD, oculus dexter; OS, oculus sinister.

relies on the following observations: (I) in most cases, the irregular corneal contour of warpage returns to normal after discontinuing lens wearing; however, keratoconus-induced irregularities are irreversible. (II) Corneal thickness remains relatively stable in warpage; however, it progressively decreases as keratoconus develops. (III) Keratoconus often manifests as an elevation of the posterior surface located at the thinnest pachymetric point in the early stage of keratoconus, which is usually not present in the corneal warpage. (IV) The corneal epithelium thickness in the cone region (steepest) on optical coherence tomography is greater in warpage than in the keratoconus (7).

Contact lens use, especially prolonged use, causes extensive physiological and biochemical corneal changes. Corneal confocal microscopy in contact lens wearers suggests that the cell size of the superficial corneal epithelium increases, keratocytes count decreases, and blebbed endothelial cells form (8). Transmission electron microscopy has demonstrated that condensed chromatin in the nucleus of apoptotic keratocytes can induce light scattering in the cornea, affecting its transparency (9). Metabolomic and proteomic analyses of corneal lenticules from SMILE procedures performed on contact lens wearers revealed several inflammatory proteins and metabolites (10,11). Although these microscopic changes cannot be observed under slit lamps, they may affect the subtle whole corneal transparency and lower the patient's visual acuity.

Cosmetic contact lenses comprise a central transparent

optical zone and a peripheral pigmented area, making the corneal diameter appear larger and the iris exhibit different colors. Pigments in tinted cosmetic lenses are embedded within the matrix or located on the front or back surface, roughening the lens surface and causing friction that can damage the cornea and conjunctiva (12,13). Moreover, the elastic modulus of cosmetic contact lenses is stiffer than are conventional ones, as pigment content increasing lenses' thickness and rigidity (14); meanwhile, the rigidity of cosmetic contact lenses may influence them to have a higher rate of corneal warpage similar to that of rigid contact lenses (15). Pigments can induce visual acuity impairment, HOA induction, contrast sensitivity reduction, and toxicity to the epithelium (16). In one study, cosmetic lenses with pigment had a lower oxygen transmission than did the other hydrogel contact lenses, which can limit oxygen transmissibility and lead to considerable hypoxia and acidosis. These metabolic challenges are also associated with a higher incidence of corneal warpage (17).

Toxicity-stressed corneal epithelial cells in cosmetic contact lens wearers are seriously distorted or remodeled, exacerbating irregularities on the corneal surface, thus increasing irregular astigmatism and aberrations in the front cornea. According to the aberration results, our case was characterized by coma-dominant HOAs, especially vertical coma. This is similar to a prior study (18), which confirmed that after discontinuation of lens wear, parameters such as refraction, irregular astigmatism, and HOAs return to the

baseline. In our patient, astigmatism and vertical coma in the front cornea significantly reduced from the first visit to the last before surgery. As previously reported (19), in coma-dominant HOA situations, visual disturbances cannot be corrected by use of spherocylindrical lenses alone, which may be why the BCVA in the right eye was less than 20/20 on the first visit.

Scheimpflug corneal densitometry is a quantitative measure of corneal transparency, and its value increases with age (20). One study (21) reported that central anterior corneal densitometry values were significantly higher in silicone hydrogel contact lens wearers than in healthy controls. In the present case, the central anterior densitometry values were equivalent to those of silicone hydrogel contact lens wearers in Ozek *et al.*'s study (21), but the peripheral values were higher than those for both the silicone hydrogel contact lens wearers and healthy controls (approximately 20). This could be explained by the close contact of the pigmented area in cosmetic lenses. As the discontinuation time increased, the lens-induced effect gradually reduced, especially in the pigmented area; however, further research is needed to confirm this hypothesis. To our knowledge, this is the first longitudinal observation of corneal densitometry changes in wearers of cosmetic lenses.

In conclusion, the present case indicates that extended cosmetic contact lens use can cause obvious corneal warpage, which is clinically different from the warpage caused by traditional clear contact lens. Surgeons should wait for all available parameters to stabilize after lens use discontinuation and make an accurate diagnosis before performing refractive surgery.

Acknowledgments

Funding: None.

Footnote

Conflicts of Interest: All authors have completed the ICMJE uniform disclosure form (available at <https://qims.amegroups.com/article/view/10.21037/qims-23-641/coif>). The authors have no conflicts of interest to declare.

Ethical Statement: The authors are accountable for all aspects of the work in ensuring that questions related to the accuracy or integrity of any part of the work are appropriately investigated and resolved. All procedures

performed in this study were in accordance with the ethical standards of the institutional and/or national research committee(s) and with the Helsinki Declaration (as revised in 2013). Written informed consent was obtained from the patient for publication of this case report and accompanying images. A copy of the written consent is available for review by the editorial office of this journal.

Open Access Statement: This is an Open Access article distributed in accordance with the Creative Commons Attribution-NonCommercial-NoDerivs 4.0 International License (CC BY-NC-ND 4.0), which permits the non-commercial replication and distribution of the article with the strict proviso that no changes or edits are made and the original work is properly cited (including links to both the formal publication through the relevant DOI and the license). See: <https://creativecommons.org/licenses/by-nc-nd/4.0/>.

References

1. Stapleton F, Lim CHL, Kweon S, Tan D, Mehta JS; ACSIKS group. Cosmetic Contact Lens-Related Corneal Infections in Asia. *Am J Ophthalmol* 2021;229:176-83.
2. Ophthalmic Optics Group, Ophthalmology Branch, Chinese Medical Association. Expert Consensus on the Specification of Femtosecond Laser Small Incision Lenticule Extraction (2018). *Chin J Ophthalmol* 2018;54:729-36.
3. Hartstein J. Corneal warping due to wearing of corneal contact lenses. A report of 12 cases. *Am J Ophthalmol* 1965;60:1103-4.
4. Hashemi H, Firoozabadi MR, Mehravaran S, Gorouhi F. Corneal stability after discontinued soft contact lens wear. *Cont Lens Anterior Eye* 2008;31:122-5.
5. Rayess Y, Arej N, Abdel Massih Y, Antoun J, Waked N. Influence of soft contact lens material on corneal warpage: prevalence and time to resolution. *Can J Ophthalmol* 2018;53:135-8.
6. Severinsky B. A case of severe refractive changes induced by Galyfilcon A silicone hydrogel contact lenses. *Int J Ophthalmol* 2016;9:175-7.
7. Tang M, Li Y, Chamberlain W, Louie DJ, Schallhorn JM, Huang D. Differentiating Keratoconus and Corneal Warpage by Analyzing Focal Change Patterns in Corneal Topography, Pachymetry, and Epithelial Thickness Maps. *Invest Ophthalmol Vis Sci* 2016;57:OCT544-9.
8. Efron N. Contact lens-induced changes in the anterior

- eye as observed in vivo with the confocal microscope. *Prog Retin Eye Res* 2007;26:398-436.
9. Doughty MJ, Jonuscheit S. Corneal structure, transparency, thickness and optical density (densitometry), especially as relevant to contact lens wear-a review. *Cont Lens Anterior Eye* 2019;42:238-45.
 10. Deng M, Li M, Liu L, Shi Y, Sun L, Ma X, Zou J. Proteomic profiling of human corneal stroma from long-term contact lens wearers reveals activation of inflammatory responses. *Cont Lens Anterior Eye* 2023;46:101820.
 11. Li M, Liu L, Qu C, Shi Y, Sun L, Zhou X, Zou J. Metabolomic Analysis in Corneal Lenticules From Contact Lens Wearers. *J Refract Surg* 2020;36:317-25.
 12. Jung JW, Han SH, Park SY, Kim EK, Seo KY, Kim TI. Effects of Pigment Location in Tinted Contact Lenses on the Ocular Surface. *Optom Vis Sci* 2016;93:997-1003.
 13. Lau C, Tosatti S, Mundorf M, Ebare K, Osborn Lorenz K. Comparison of the Lubricity and Surface Roughness of 5 Cosmetic Contact Lenses. *Eye Contact Lens* 2018;44 Suppl 2:S256-65.
 14. Kim SH, Lee J, Jang YJ, Lee KB, Lee Y. ToF-SIMS and AFM Characterization of Brown Cosmetic Contact Lenses: From Structural Analysis to the Identification of Pigments. *J Anal Methods Chem* 2020;2020:6134627.
 15. Phillips CI. Contact lenses and corneal deformation: cause, correlate or co-incidence? *Acta Ophthalmol (Copenh)* 1990;68:661-8.
 16. Jung JW, Kim SM, Han SH, Kim EK, Seo KY, Kim TI. Effect of the pigment-free optical zone diameter of decorative tinted soft contact lenses on visual function. *Br J Ophthalmol* 2016;100:633-7.
 17. Schornack M. Hydrogel contact lens-induced corneal warpage. *Cont Lens Anterior Eye* 2003;26:153-9.
 18. Hiraoka T, Okamoto C, Ishii Y, Okamoto F, Oshika T. Recovery of corneal irregular astigmatism, ocular higher-order aberrations, and contrast sensitivity after discontinuation of overnight orthokeratology. *Br J Ophthalmol* 2009;93:203-8.
 19. Zhou W, Stojanovic F, Reinstein DZ, Archer TJ, Chen X, Feng Y, Stojanovic A. Coma Influence on Manifest Astigmatism in Coma-Dominant Irregular Corneal Optics. *J Refract Surg* 2021;37:274-82.
 20. Zhang J, Hu H, Nie D, Sun L, He W, Liu X. Age-related changes in Scheimpflug corneal densitometry and their correlations with corneal topographic measurements in a healthy Chinese population. *Quant Imaging Med Surg* 2023;13:1631-41.
 21. Ozek D, Karaca EE, Kazanci B, Evren Kemer O. Evaluation of Corneal Densitometry and Endothelial Layer in Soft Contact Lens Users. *Optom Vis Sci* 2021;98:592-6.

Cite this article as: Xu Y, Wu S, Shen F, Wang X, Xiao Q. Corneal warpage caused by cosmetic contact lenses: a case description. *Quant Imaging Med Surg* 2024;14(1):1255-1260. doi: 10.21037/qims-23-641